

Assessment of Mitral Regurgitation Severity by Different Echocardiographic Methods in Comparison with Left Ventricle Angiography

Rafid B. Altaweel¹ MBChB FIBMS, Muthanna H. Al-Quraishi² MBChB FICMS

¹Section of Cardiology, Dept. of Medicine, College of Medicine, Al-Nahrain University, ²Ibn-Albitar Cardiac Surgery Center, Baghdad, Iraq.

Abstract

- Background** Proximal isovelocity surface area method and mitral regurgitant jet estimation (with its ratio to left atrium) are reliable methods for estimation of mitral regurgitation severity aiding in management strategy, precluding the use of other invasive procedures for assessment (e.g. left ventricular angiography).
- Objective** To study the usefulness of proximal isovelocity surface area and regurgitant jet size (with its ratio to left atrium) to determine the severity of mitral regurgitation in comparison with left ventricle angiography.
- Methods** Forty patients with mitral regurgitation planned to do left ventriculography to assess mitral regurgitation severity were studied. Estimation of mitral regurgitant jet (and its ratio to left atrium) by color tracing of maximal jet area and estimation of effective regurgitant orifice, regurgitant volume and regurgitant fraction by proximal isovelocity surface area method were reported within 24-48 hours after angiography.
- Results** The effective regurgitant orifice, regurgitant volume and regurgitant fraction in correlation with angiographic grades were $46.67 \pm 27. \text{mm}^2$ ($P < 0.0001$); 55.35 ± 27.67 ml ($P < 0.0001$) and 57.41 ± 20.63 % ($P < 0.0001$) respectively. The thresholds for severe mitral regurgitation (grade 4) were 60 mL, 52%, and 42.5 mm^2 for regurgitant volume, regurgitant fraction, and effective regurgitant orifice, respectively. Significant correlation ($P = 0.021$) of mean mitral regurgitant/left atrium ratio with the corresponding angiographic grade in central mitral regurgitation, while no significant correlation ($P = 0.799$) was found in eccentric mitral regurgitation.
- Conclusion** Proximal convergence method and estimation of mitral regurgitant size (ratio to left atrium) by color tracing of maximal jet area (in central jet) allows accurate estimation of the mitral regurgitation severity.
- Keywords** Proximal isovelocity surface area method, effective regurgitant orifice, mitral regurgitant volume

List of Abbreviation: MR = mitral regurgitation, PW = pulsed wave, CW = continuous wave, LA = left atrium, LV = left ventricle, EROA= effective regurgitant orifice area, RVol = regurgitant volume, RF = regurgitant fraction, PISA = proximal isovelocity surface area, VTI = velocity time integral, SV = stroke volume, CSA = cross-sectional area, LVOT = Left ventricular outflow tract, RAO = right anterior oblique, MVP = mitral valve prolaps, MV= mitral valve, A = area, V = volume, RAO = right anterior oblique, ROC = receiver operator curve.

Introduction

Mitral valve regurgitation has long been recognized as an important cause of morbidity and mortality, where those with severe

regurgitation observed clinically experience excess mortality and high morbidity⁽¹⁾. Consequently, determining the degree of regurgitation by doppler echocardiography is a crucial part of the clinical evaluation of patients with mitral regurgitation^(2,3).

To define the degree of regurgitation quantitatively, new methods and new concepts using Doppler echocardiography have allowed the measurement of regurgitant volume (RVol),

regurgitant fraction (RF) ^(4,5,6) and effective regurgitant orifice (ERO), a measure of lesion severity ^(6,7).

Proximal isovelocity surface area (PISA) measurement is used in echocardiography to estimate the area of an orifice through which blood flows. The PISA method is based on 1) the properties of flow dynamics and 2) the continuity principle ⁽⁸⁾.

When a liquid (in this case blood) is forced from a large chamber into an orifice at a constant flow, its particles accelerate towards the orifice until the velocity is greatest at the narrowest point of the orifice. This acceleration occurs along a series of concentric “hemispheres” or “hemishells” whose center is at the orifice itself. Those hemispheres are contained in an area referred to as the flow convergence area ⁽⁸⁾ as shown in figure 1.

The volume of a liquid going through a conduit per unit time, called the flow rate, equals the cross-sectional area of that conduit times the velocity of the liquid: Flow rate = area × velocity. Liquids, by definition, are essentially incompressible. Therefore, the continuity principle dictates that in the absence of a leak in the conduit or additional input, the flow rate is constant along the length of the conduit ⁽⁹⁾. If the cross-sectional area decreases, the velocity must increase to compensate and *vice versa*. The same holds true for the heart and, assuming there is no shunt, the flow rate throughout the heart is constant. What changes is the area and velocity of the column of blood as it flows through the various parts of the heart. As the area changes, the velocity of the blood must change also, according to the continuity equation:

$$A_1 \times V_1 = A_2 \times V_2 \text{ where } A = \text{area, } V = \text{velocity}^{(8)}.$$

The first step in the PISA method is to demonstrate the mitral regurgitant (MR) jet by color flow Doppler and to calculate the flow of blood within the flow convergence area. The flow convergence area is the colored area on the ventricular side of the mitral valve in systole. This area contains an infinite number of

concentric hemispheres along which the blood accelerates towards the regurgitant orifice ⁽⁸⁾.

By Doppler convention, the MR jet is displayed in shades of red, as blood cells accelerate, the color goes from dark red to bright red, to orange, to yellow. When the cells reach the aliasing velocity (also known as the Nyquist limit), the color suddenly changes to blue. This is the point of interest, at which the velocity is known with certainty. (The Nyquist limit is defined as the velocity at which the color flow switches from red to blue or blue to red.) Radius is measured from the orifice to point of colour change. If the flow convergence is not a true hemisphere, the angle subtended by the flow convergence at the orifice has to be measured and divided by 180 to get a correction factor. The next step consists of measuring the maximum velocity of blood at the mitral regurgitant orifice using continuous wave (CW) Doppler of the MR jet. As usual, one must make sure that the Doppler beam is lined-up with the MR jet

Finally, one calculates the EROA using the initial formula ⁽⁸⁾:

$$A_1 \times V_1 = A_2 \times V_2$$

$$\text{EROA} \times V_{\text{max (CW)}} = 2\pi r^2 \times \text{Nyquist Limit}$$

$$\text{EROA} = \frac{2\pi r^2 \times \text{Nyquist Limit}}{V_{\text{max (CW)}}} \times \frac{\alpha}{180}$$

Putting in mind that (α) is the angle correction factor; (r) is the radius of the hemispheric flow convergence. Knowing that Volume = area × VTI, one can trace the velocity-time integral (VTI) of the MR jet on the CW signal, and one can calculate the mitral RV (RV_{MR}), using the following equation ⁽⁸⁾:

$$RV_{\text{MR}} = \text{EROA} \times \text{VTI}_{\text{MR}}$$

Once the RV is known, one can calculate the ratio of RV over total stroke volume, a value known as mitral regurgitant fraction ⁽⁸⁾.

$$\text{RF} = \text{RVol} / (\text{regurgitant vol} + \text{aortic stroke volume}).$$

$$\text{Aortic SV} = \text{CSA (at LVOT)} \times \text{VTI} = \pi d^2 / 4 \times \text{VTI} = 0.785d^2 \times \text{VTI}^{(8)}.$$

The area of the regurgitant jet relative to the size of the left atrium (LA) has been shown to

correlate well with regurgitant severity determined with angiography when the jet is not eccentric where the flow jet is directed against the atrial wall and appears smaller than a free jet of the same regurgitant volume (Coanda effect)⁽¹⁰⁾. It was estimated that MR/LA ratio best correlating to angiographic grade is as follows⁽¹¹⁾: <20% = mild, between 20-40% = moderate and >40% = severe.

The goal of our study is to assess the validity of proximal isovelocity surface area method (PISA) and MR size (with its ratio to LA) as measures to determine the severity of mitral regurgitation instead of invasive methods.

Methods

A prospective study was conducted at Ibn Al-Bitar and Al-Nassirya Cardiac Centers from May 2011 to May 2012 on 40 patients known to have MR planned to do LV ventriculography to assess MR severity for possible subsequent surgical referral. Patients were subjected to a complete echocardiographic assessment within 24-48 hr's after angiography with the aid of an expert echocardiographer, and then comparative analysis of data collected from each patient was performed.

Angiographic Assessment

In each patient, left ventriculography was performed in the 30° right anterior oblique (RAO) projection with 40-50 ml of iohexol iodine contrast injected over 2-3 seconds at 15-20 mL/sec, 600 pounds per square inch (PSI) (a pressure stress unit). The angiographic severity of mitral regurgitation was graded according to a historically accepted grading scheme (Seller)⁽¹²⁾ (i.e. from 1-4).

Echocardiographic Analysis

A comprehensive Doppler echocardiographic examination was performed and analyzed as described previously, echocardiography machine used was Philips (Invisor C), and aliasing velocity range was between 40-64 cm/sec.

The mechanism of mitral regurgitation was determined on the basis of the two-dimensional

appearance of the left ventricle, subvalvular apparatus, and valve leaflets and the dimension of the mitral annulus. Organic mitral regurgitation was characterized by intrinsic valvular disease, and ischemic/functional mitral regurgitation was characterized by normal valves, enlarged annulus, and global or regional left ventricular dysfunction. Assessment of mitral regurgitation was performed by two methods:-

1- Measuring (ERO, RVol and RF) through proximal isovelocity area method using the 4-chamber view through apical axis with applying angle correction factor if the flow convergence hemisphere is restricted laterally by the mitral leaflet or ventricular wall.

2- Measuring the ratio of MR/LA size. The jet area was measured as the largest clearly definable flow disturbance in the apical view, and expressed as the maximal jet area. Beside that, any additional valvular lesions were described.

These data were used to classify MR from the severity point of view to mild, moderate, moderate to severe and severe as shown in table 1^(13,14):

RVol = regurgitant volume, RF = regurgitant fraction, ERO = effective regurgitant orifice area

Table 1. Classification of Mital Regugitant

Grade	RVol (mL)	RF %	EROA, mm ²
1	<30	<30	<20
2	30-44	30-39	20-29
3	45-59	40-49	30-39
4	≥60	≥50	≥40

RVol = regurgitant volume, RF = regurgitant fraction, EROA= effective regurgitant orifice area.

Patients

Patients included had pure chronic MR and were subjected to left ventricular angiography and quantitative Doppler echocardiography for quantification of mitral regurgitation severity by both PISA method and MR/LA size 24-48 hr between each other. Patients who were excluded from the study had associated aortic valve disease or mitral stenosis; had change in systolic blood pressure ≥30 mmHg between

(angiography and echo studies); had accidental discovery of MR by angiography (due to improper injection preparation) and who had multiple regurgitant jets by color Doppler.

Statistical analysis

Data were analyzed using SPSS version 16 and Microsoft Office Excel 2007. Numeric data were expressed as mean ± SD. Nominal data were expressed as number and percent. ANOVA test was used to compare means among groups. The candidate thresholds that were considered to best separate the continuous quantitative variables in correspondence with the angiographic grades were those with the highest sum of sensitivity and specificity and the lowest value of their difference. Chi-square test was used to study association among nominal variables. Receiver Operator Curve (ROC) was used to identify cut off values with their corresponding sensitivity and specificity. P-value less than 0.05 were considered significant.

Results

The 40 patients (21 men and 19 women) included were (20-82) years old (mean 56.18±2.06). Distribution of age showed most of age groups were in 6th and 7th decade. The mechanism of mitral regurgitation was ischemic / functional (n=15) or organic (n=25), in both genders MVP followed by ischemic cause were more prevalent. 70% (n=28) were in sinus rhythm, 30% (n=12) in atrial fibrillation. Systolic blood pressure was 118.12±15.91 mmHg at echocardiography and 120.50±16.74 mmHg at angiography (P = 0.518). The mitral regurgitation grade by angiography was 12.5% for grade 2, 32.5% for grade 3, 55% for grade 4.

The distribution of patients among the four angiographic grades and the values of RVol, RF, and ERO for each angiographic grade are summarized in the following figures (2-4) as there were notable overlaps between grades, as expected, but despite this, the differences between each angiographic grade in terms of RVol, RF, and ERO were significant (overall P <

0.001, P < 0.001, and P < 0.001 for RVol, RF, and ERO, respectively) as shown in table 2.

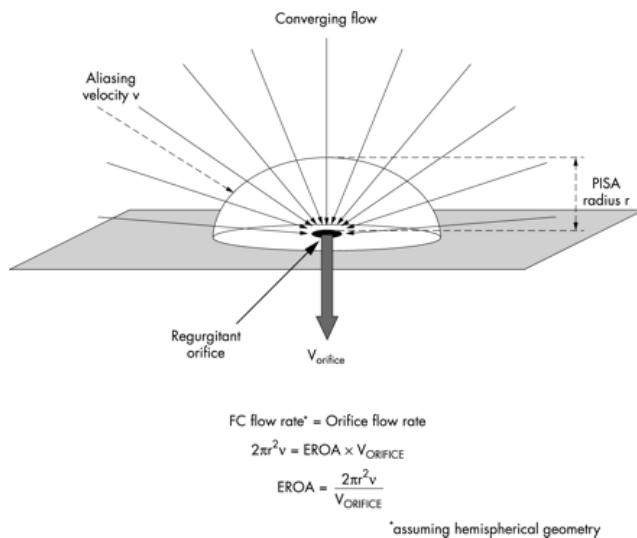


Fig.1 Diagram showing converging flow area of mitral regurgitation

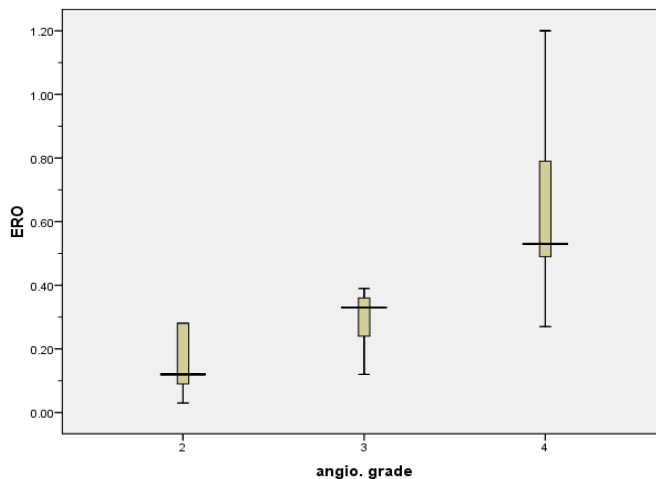


Fig. 2. Box plot of mean effective regurgitant orifice area for each angiographic grade

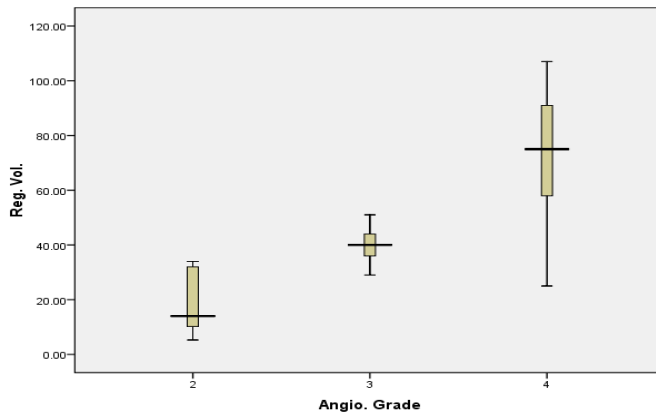


Fig. 3. Box plot of mean Regurgitant volume for each angiographic grade

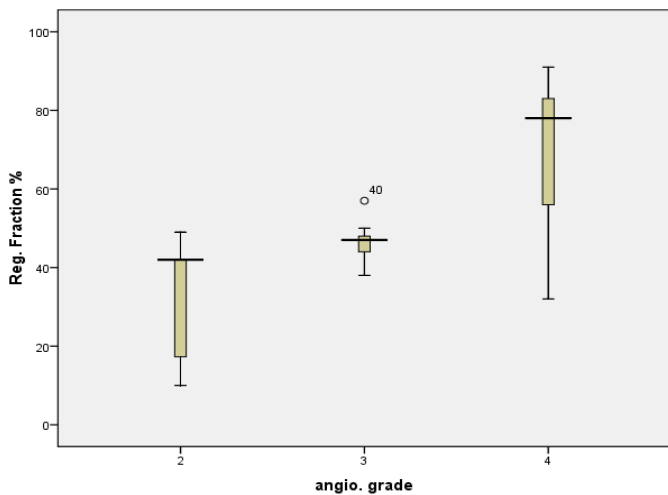


Fig. 4. Box plot of mean regurgitant fraction for each angiographic grade

Threshold values for ERO, RVol, and RF corresponding to each angiographic grade are listed in the table 3, with the descriptors of their diagnostic values. The thresholds that were finally selected as best separating the grades with the best sensitivity and specificity results. Regarding eccentric lesions, about 63% (n=25) were eccentric, 37% (n=15) were central MR, mechanism of MR in eccentric lesions correlated with MVP more than central lesions ($P < 0.05$). In comparing eccentric and central MR regarding correlation of angiographic and echocardiography parameters, it showed no significant difference between them, although about 3 individual cases of eccentric MR who had grade 4 by angiography showed limited

correlation with quantitative echocardiographic parameters (ERO, RV, RF) i.e., underestimation of real measures.

The minimum radius (of the hemispheric flow convergence) diameter on echo estimation that correlates best with grade 4 (severe) MR in both central and eccentric MR were eccentric 0.55 cm and central 0.83 cm.

Regarding MR jet and ratio to LA size (MR/LA) ratio in studied patients, it fell in two groups those with central jets and those with eccentric jets. The central MR; significant correlation ($P = 0.021$) of mean MR/LA ratio with the corresponding angiographic grade as a whole, especially in the severe grade (grade 4) as shown in figure 5.

The Eccentric MR; no significant correlation ($P = 0.799$) in total between the mean of MR/LA ratio to the angiographic grade especially in the severe grade (grade 4) as shown in figure 5. The least MR size that correlates with grade 4 in all patients was 9.6 cm^2 (sensitivity 72.7%, specificity 88.9%). The least MR size that correlates with grade 4 in patients with central MR was also around 9.6 cm^2 (sensitivity 85.7%, specificity 87.5%) i.e., comparable specificity and more sensitivity.

Regarding the correlation of MR area with ERO, Reg. volume and Reg. Fraction, it showed significant correlation with ERO, but not with other parameters ($P \leq 0.05$).

Table 1. Quantitative variables corresponding to each angiographic grade

Angiographic grade	1	2	3	4	P value
Number	40	5	13	22	
ERO mm^2	46.67±27.33	16.00±11.42	30.38±8.06	63.27±25.47	<0.001
RVol ml	55.35±27.67	19.10±13.07	40.00±6.30	72.66±24.37	<0.001
RF %	57.41±20.63	32.06±17.24	46.38±4.62	69.68±18.33	<0.001

ERO = Effective regurgitant orifice, RVol = Regurgitant volume, RF = Regurgitant fraction

Discussion

From the results one can see that the commonest cause of MR in both sexes was MVP (myxomatous MV), probably because of the small number of patients and because of our

exclusion criteria of patients selection, as we excluded any MV regurgitation with coexistent mitral stenosis and aortic valve disease (i.e. we excluded many rheumatic causes).

Table 2. Diagnostic value of the thresholds of Doppler quantitative variables corresponding to the angiographic mitral regurgitation grades

Parameter		Sensitivity	Specificity
Effective regurgitant orifice	Grade 2 versus 3	29 mm ²	69.2%
	Grade 2 and 3 versus 4	42.5 mm ²	81.8%
Regurgitant volume	Grade 2 versus 3	34.5 ml	100%
	Grade 2 and 3 versus 4	60 ml	72.7%
Regurgitant fraction	Grade 2 versus 3	43%	84.6%
	Grade 2 and 3 versus 4	52%	81.8%

Hemodynamic conditions (like systolic hypertension, LV contractility) should be standardized at echo and angiography and no significant difference (as in our study) should exist as any change in loading conditions between echocardiography and angiography could account for some of the misclassifications between quantification and angiographic grade (15).

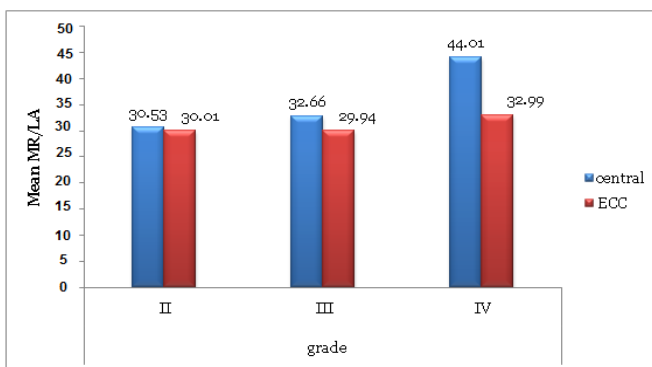


Fig. 5. Difference between central and eccentric MR regarding correlation between MR size and angiographic severity

Because most patients in our study originally had presumed moderate-severe MR and were sent for cath. Before possible surgery, grade 4 followed by grade 3 MR was found most of the time followed by grade 2. Grade 1 was not encountered as they were not sent for angiography from the beginning (regarded as mild), those MR found on angiography accidentally was not included because of the miss-preparation of injection parameters. Quantitative methods allow the measurement of RVol and RF to assess volume overload and the measurement of ERO area, a surrogate of lesion

severity (7). All angiographic grades showed significant differences in RVol, RF, and ERO, demonstrating that a statistical (in addition to visual) separation between grades is present and this is comparable to results achieved by Dujardin and colleagues (14) and in other previous studies (5,16) who showed a similar significant correlation of quantitative echo parameters in regard to angiographic grade. Table 2 reveals the cut off values of ERO, RV, RF separating each grade with best sensitivity and specificity obtained and as far we are concerned more with advanced degrees of MR we took the best cut-off values earned in the study that separates values equivalent to grade 4 from other grades, i.e., the best ERO value was 42.5 mm² (Sensitivity 81.8%, Specificity 100%), RVol. 60 mL (Sensitivity 72.7%, Specificity 100%), RF 52 % (Sensitivity 81.8%, Specificity 94.6%), which is nearly comparable to cutoff thresholds in other studies (14) and references (13).

If there are multiple regurgitant orifices, the flow convergence method may be completely inaccurate in estimating the EROA (8), so we excluded any patient with multiple jets MR from the study.

Angle correction factor α applied when the hemisphere of the flow convergence is limited by valve leaflet or ventricular wall (i.e., If the base of the hemisphere is not a flat surface) to make accurate results (17), but still it can be a limiting factor in applying PISA in quantitative measures as measurement of angle factor is not available in our echocardiography device software and needs off-line analysis and measurement by the operator. As color Doppler

parameters are adjusted, the hemispheres may become more flattened or more cone-shaped, even if the regurgitant orifice is circular. Again, the equation $2\pi r^2$ may not apply. It has been reported that the PISA hemispheres are closest to being true hemispheres when their radius optimized by adjusting the Nyquist limit⁽¹⁸⁾, which in most echocardiography machines is done by turning a knob identified as “pulse repetition frequency” or “color Doppler scale.” Regarding analysis of MR/LA size ratio data, fitness between MR/LA size ratio and angiographic grade goes more with central lesions than eccentric one, i.e., for same grade 4 mean ratio of MR size reaches 44% in central MR while it’s 32% for eccentric MR (theoretically should be more than 40%), i.e., there is underestimation and this goes with the fact that eccentric, wall-impinging jets appear significantly smaller than centrally directed jets of similar hemodynamic severity, mainly because they flatten out on the wall of the receiving chamber⁽¹⁹⁾. Also Enriquez-Sarano and associates⁽²⁰⁾ stated that mitral regurgitant jet eccentricity influence jet extent and the same regurgitant volume produces smaller jet areas for eccentric compared with central jets^(18,19). In our study, minimal MR area found to correlate well with severe angiographic grade was 9.6 cm² (as a total including central and eccentric MR) with sensitivity of 72.7% and specificity of 88.9% beside a sensitivity of 85.7% and specificity of 87.5% (if only central MR was involved). This was comparable to a study conducted by Spain and coworkers⁽²¹⁾ who revealed that maximal jet area greater than 8 cm² predicted severe mitral regurgitation with a sensitivity of 82% and specificity of 94%. We can see good correlation between maximal jet size and ERO ($P = 0.042$) but weak and non-significant correlation with RVol and RF ($P = 0.133$, $P = 0.863$, respectively). Our result agrees with what Enriquez-Sarano and colleagues⁽²⁰⁾ has found that weak correlations exist between regurgitant volume and jet area and regurgitant fraction and jet area/left atrial area ratio, also Spain and colleagues⁽²¹⁾ showed that jet area

measurements have limited correlation with regurgitant volume and fraction.

In conclusion proximal convergence method (PISA) and MR/LA ratio (in central jet) allows accurate estimation of the mitral regurgitation severity and correlates well with MR severity estimation by LV angiography.

Acknowledgments

We thank Dr. Muhened Alshiekh-ali for his kind assistance.

Declaration of interest

The author declare no conflict of interest

Author contributions

Dr Rafid did the echo and angiography studies and most of the statistical and fine touches of the study and Dr Muthanna collect the cases.

Funding

Self-funding

References

1. Ling LH, Enriquez-Sarano M, Seward JB et-al. Clinical outcome of mitral regurgitation due to flail leaflet. *N Engl J Med.* 1996; 335: 1417-23.
2. Enriquez-Sarano M, Tajik AJ, Schaff HV, et al. Echocardiographic prediction of survival after surgical correction of organic mitral regurgitation. *Circulation.* 1994; 90: 830-7.
3. Enriquez-Sarano M, Tajik AJ, Schaff HV, et al. Echocardiographic prediction of left ventricular function after correction of mitral regurgitation: results and clinical implications. *J Am Coll Cardiol.* 1994; 24: 1536-43.
4. Blumlein S, Bouchard A, Schiller NB, et al. Quantitation of mitral regurgitation by Doppler echocardiography. *Circulation.* 1986; 74: 306-14.
5. Enriquez-Sarano M, Bailey KR, Seward JB, et al. Quantitative Doppler assessment of valvular regurgitation. *Circulation.* 1993; 87: 841-8.
6. Rokey R, Sterling LL, Zoghbi WA, et al. Determination of regurgitant fraction in isolated mitral or aortic regurgitation by pulsed Doppler two-dimensional echocardiography. *J Am Coll Cardiol.* 1986; 7: 1273-8.
7. Vandervoort PM, Rivera JM, Mele D, et al. Application of color Doppler flow mapping to calculate effective regurgitant orifice area: an in vitro study and initial clinical observations. *Circulation.* 1993; 88: 1150-6.
8. Lambert AS. Proximal isovelocity surface area should be routinely measured in evaluating mitral

- regurgitation: A core review. *Anesth Analg.* 2007; 105(4): 940-3.
9. Weyman AE. Principles and practice of echocardiography. 2nd ed. Philadelphia: Lea and Febiger; 1994. p. 193
 10. Oh JK, Seward JB, Tajik AJ. Infective endocarditis: The echo manual. 3rd ed. Philadelphia, Lippincott Williams and Wilkins; 2006. p. 243-250.
 11. Helacke F, Nanda NC, Hsiung MC, et al. Color Doppler assessment of mitral regurgitation with orthogonal planes. *Circulation.* 1987; 75(1): 175-83.
 12. Feldman T, Grossman W. Profiles in valvular heart disease, Grossman's cardiac catheterization, angiography, and intervention. 7th ed. Philadelphia: Grossman & Baim's, 2006; p. 638-58.
 13. Connolly H, Oh J. Echocardiography, valvular heart disease. Braunwald's heart disease (a textbook of cardiovascular medicine), 9th ed. Philadelphia: Bonow RO; 2011. p. 234-240.
 14. Dujardin KS, Enriquez-Sarano M, Bailey KR, et al. Grading of mitral regurgitation by quantitative Doppler echocardiography, calibration by left ventricular angiography in routine clinical practice. *Circulation.* 1997; 96: 3409-15.
 15. Borgenhagen DM, Serur JR, Gorlin R, et al. The effects of left ventricular load and contractility on mitral regurgitant orifice size and flow in the dog. *Circulation.* 1977; 56: 106-13
 16. Giesler M, Grossmann G, Schmidt A, et al. Color Doppler echocardiographic determination of mitral regurgitant flow from the proximal velocity profile of the flow convergence region. *Am J Cardiol.* 1993; 71(2): 217-24.
 17. Pu M, Vandervoort PM, Griffin BP, et al. Quantification of mitral regurgitation by the proximal convergence method using transesophageal echocardiography. Clinical validation of a geometric correction for proximal flow constraint. *Circulation.* 1995; 92: 2169-77.
 18. Utsunomiya T, Doshi R, Patel D, et al. Calculation of volume flow rate by the proximal isovelocity surface area method: simplified approach using color Doppler zero baseline shift. *J Am Coll Cardiol* 1993; 22: 277-82.
 19. Zoghbi WA, Enriquez-Sarano M, Foster E, et al. American Society of Echocardiography: recommendations for evaluation of the severity of native valvular regurgitation with two-dimensional and Doppler echocardiography. *Eur J Echocardiogr.* 2003; 4(4): 237-61.
 20. Enriquez-Sarano M, Tajik AJ, Bailey KR, et al. Color flow imaging compared with quantitative Doppler assessment of severity of mitral regurgitation: influence of eccentricity of jet and mechanism of regurgitation. *J Am Coll Cardiol.* 1993; 21: 1211-9.
 21. Spain MG, Smith MD, Grayburn PA, et al. Quantitative assessment of mitral regurgitation by Doppler color flow imaging: angiographic and hemodynamic correlations. *J Am Coll Cardiol.* 1989; 13: 585-90.

Correspondence to Dr. Rafid B. Altaweel

E-mail: drarafid76@gmail.com

Received 16th Jan. 2014: Accepted 11th Aug. 2014