



Electronic apex locator determination of root canal length of permanent anterior teeth in children

Dr. Maha M.Misbah Al- Ameen. B.D.S., M.Sc.

Dr. Abeer M.H.Zwain. B.D.S., M.Sc.

Abstract

The success of endodontic treatment depends on the correct obtaining of working length, and in Pediatric Dentistry, this procedure needs child's cooperation and expose the children to x-ray radiation. The aim of the present study is to compare root canal length determined by tactile sensation, electronic apex locator YD-2 and digital radiograph with that determined by conventional x-ray which is the most used and reliable method.

The working length of 30 upper permanent central incisors, in children aged 10-12 years old, estimated by tactile sensation, electronic apex locator YD-2 and digital radiograph and the mean values of them compared by t-test with that obtained by conventional x-ray.

High significant difference found between the mean value of root canal length measurements obtained by tactile sensation with that obtained by conventional radiograph ($P < 0.01$), while no significant difference found between the mean of apex locator and digital radiographic readings with that obtained by conventional radiography ($P > 0.05$) indicating the similarity of mean values of these techniques.

The use of electronic apex locator and digital radiograph are quite comparable with conventional radiograph and could be useful in endodontic therapy for working length estimation in children.

Key words: apex locator, tactile sensation, digital radiograph.

Introduction

The successful endodontic treatment can be achieved when all the pulp tissue, necrotic material and microorganisms removed from the root canal, this can only obtained if the length of the tooth and the root canal is determined accurately⁽¹⁾. The Cemento Dentinal Junction (CDJ) is the anatomical and histological landmark where the periodontal ligament and the pulp end. Root canal preparation techniques aim to make use of this potential natural barrier

between the contents of the canal and the apical tissues⁽²⁾.

The procedure for establishment of working length should be performed with skill using techniques that have been proven to give valuable and accurate results and by methods that are practical and efficacious. One of the most common and reliable methods used in determining the working length is the radiographic method^(3, 4).

In pediatric endodontic therapy the use of radiographs should be considered carefully and exposure of

children to x-ray should be limited⁽⁵⁾. Moreover, conventional radiography produce gag reflex depends on the child's cooperation as well as the operator's proficiency.

The electronic apex locator is helpful in overcoming these shortcoming, the device were developed in 1962⁽⁶⁾ and have been widely used on permanent and primary teeth^(7,8,9,10), as electronic apex locator do not produce pain and avoid unnecessary radiation, so it is recommended for use in children⁽¹¹⁾. Digital radiography also reduces exposure to radiation and allows instant imaging⁽¹²⁾.

The aim of this study is to compare the root canal length of anterior permanent teeth in children determined by tactile sensation, electronic apex locator and digital radiography with that obtained by conventional radiography.

Materials and Methodes

The benefits of the research explained to the parents and a consent form obtained from them if they refuse to participate, then excluded from the research.

30 upper permanent central incisors indicated for endodontic treatment included in the present study, the age of the children was 10-12 years old, the teeth must be vital with no signs of periapical lesion, root resorption or pulp chamber calcification in the good quality diagnostic radiograph which was taken using bisecting angle technique⁽¹³⁾, an x-ray machine with closed cone was used and operated at 70 kVp at 8 mA, exposure time was 1.5 seconds, a film size 2 was used (Kodak ultra-speed, general electric/USA) . The reference point marked on this radiograph at the incisal edge and by graduated metal ruler the teeth length measured from the reference

point till the apex. Then the teeth were isolated with rubber dam and access opening performed with No. 10 round bur in a high speed hand piece, the pulp tissue was extirpated and the canals irrigated with 3% sodium hypochlorite and dried thoroughly with paper points⁽⁹⁾. Root canals' length was measured by the following methods:

- Tactile measurement of the canals must completed first using a No. 55 K-file which introduced into the canal until detection of tactile resistance, a rubber stop fitted into the file and adjusted so that it touch the reference point, the file then withdrawn and the tooth length measured by the same ruler and recorded⁽⁹⁾.
- The canal length then measured by electronic apex locator YD-2 (Changsha Zhongnan Stomological Medical Devices Corporation) according to the manufacture instructions(Figure 1); the outer surface of the tooth was cleaned and dried using cotton, as the low resistance pathways from file to the oral mucosa may cause false readings, the spring electrode of measuring cable was attached to the lower lip, the other spring electrode was clipped to the metal shank of No.15 K-file which inserted into the canal step by step, when the tip of apex location indicator turns yellow and alarm beeper interrupted, it means the file reaches the interface of physical root tip, continuos beeper indicate that the file exceeds the physical root tip hole. All the measurements made by the same operator and each tooth measured three times with the device and the mean value calculated⁽¹⁰⁾.
- Determination of the canal length by radiograph was done according to Ingle's method⁽³⁾ in which a file 1 mm length less than the tooth

length determined by the diagnostic radiograph inserted into the canal and another radiograph was taken with the same criteria and machine. The distances between the source and the tooth, and the tooth and the film were standardized. On the radiograph the difference between the end of the file and the apex was measured. This amount was added /subtracted to the original measured length, 1 mm subtracted from the tooth length to confirm with the cementodentinal junction. This value recorded as radiographic working length (Figure 2).

- Digital radiographic measurements were also taken simultaneously by replacing the film with digital sensor (Dimax/Procline CC2002, Planmeca) ⁽⁹⁾. The measurements were taken using the on- screen image (Figure 3).

Two readings were taken for each method. All the measurements made by the same operator. Root canal length estimated by tactile sensation, electronic apex locator and digital radiograph compared with that obtained by the conventional radiograph as it is the most used and reliable method ^(1, 3, 14, 15,16) and analyzed statistically by t- test at 5% significance level.

Results

The mean reading that was obtained using tactile measurement was **19.86±0.042 mm**. Apex locator measurement resulted in a mean reading of **19.94±0.030 mm**. Digital Radiography gave a mean reading of **19.9470±.011 mm**. These readings observed in (Table 1).

(Figure 4) represents the differences between the mean values of root canal lengths obtained by tactile sensation, apex locator and digital

radiography with that obtained by conventional radiograph which is **19.948±0.036 mm**.

Comparison of root canal length obtained by each technique with that obtained by conventional radiograph shown in (Table 2), high significant differences found between the mean value of root canal length measurements obtained by tactile sensation with that obtained by conventional radiograph ($P<0.01$), while no significant difference found between apex locator and digital radiographic readings with that obtained by conventional radiography ($P>0.05$).

Discussion

Due to technological advancements and hectic life styles, the incidence of trauma is on the rise between children ⁽⁷⁾. In Pediatric Dentistry, estimation of working length in anterior teeth indicated for endodontic treatment needs precise techniques that have been proven to give valuable and accurate results and by methods that are practical and efficacious. In Iraq this is the first study that evaluates different methods for estimation of working length in traumatized anterior teeth in children.

The difference found between the mean values of root canals length estimated using tactile sensation (**19.86±0.042mm**) and that found by conventional radiograph (**19.948±0.036mm**) was (**0.086±0.044mm**) as shown in (Figure 4 and Table 2), highly significant difference found between them ($P<0.01$), this finding is in agreement with other studies ^(9,17). Tactile sensation although useful in experienced hands, has many limitations; incomplete pulp extirpation, the anatomical variations in apical constriction location, size,

tooth type and age make working length assessment unreliable using this method⁽¹⁾.

The apex locator YD-2 employed in the present study is from the third generation that works through activation of human physiology and impedance characteristics of the measured data depending on the frequencies used. The mean value of apex locator readings was **(19.94±0.030mm)**, it differ from that obtained from conventional radiograph by **(0.00210±0.0078mm)**, no significant difference found between them ($P>0.05$). this finding is in consistence with that obtained by Ravanshad et al (2010) in which they concluded that using electronic apex locator are quite comparable if not superior to radiographic length measurement regarding the rates of acceptable and short cases after obturation of the canals with gutta percha^(14,16).

The accuracy of apex locators were tested in various studies, they differ in the comparison parameters, methods used to compare the device and brand of the device.

In testing the accuracy of electronic apex locator in primary teeth, the studies concluded that the device is a reliable method to determine the working length of primary teeth, since it showed great accuracy^(9, 10).

Regarding the usage of the device in determining root canal length of permanent teeth; the results indicated that electronic apex locator showed the highest accuracy and reliability for working length determination^(8, 17). This findings also confirmed by Soujanya et al (2006) irrespective of the canal contents⁽¹⁹⁾. In an Iraqi study they concluded that root ZX has a high clinical accuracy hence it can used as an adjunct to the traditional x-ray procedures⁽²⁰⁾.

In the other hand, Hulsmann et al (1989) demonstrated that an apex locator gave incorrect results in open apices and could be used as auxiliary devices only in controlling apical hard tissue closure in the treatment of teeth with open apex possibly because those authors used a first generation apex locator this finding is similar to that found by Venturi et al (2007) in which they concluded that root ZX provided inaccurate and unstable measurements mostly in low conductive conditions^(21, 22).

In Pediatric Dentistry digital radiography has many potential benefits; the images have good quality, decrease of radiation to the patients, in addition to that the apical zone could be magnified, store and transmit the image easily, ease of repetition, elimination of harmful processing solutions and dark rooms^(12, 23).

No significant difference found between the mean value of root canal length estimated by digital radiography **(19.947±0.011mm)** with that obtained by conventional radiograph **(19.948±0.036mm)** as ($P>0.05$) indicating the similarity of mean values of these techniques, this finding is in agreement with other studies^(9, 17).

The results of the present study supported that electronic apex locator and digital radiography can be recommended for use in estimation of root canal length in pediatric endodontic therapy. Further studies needed to compare these methods with the histological examinations of the cement dentinal junction position.

References

- 1- Gordon MP and Chandler NP. Electronic apex locators. *International Endodontic Journal* 2004; 37:425-437.
- 2- Kim E, Lee SJ. Electronic apex locator. *Dent Clin North Am* 2004;48:35-54.
- 3- Ingle JI and Bakland LK. *Endodontics*. 5th edition Elsevier :New Delhi;2003:513-25.

- 4- Katz A, Tamse A and Kaufman Y. Tooth length determination: A review. *Oral Surg Oral Med Oral Pathol Oral Radiol Endod* 1991;72:238-42.
- 5- Bagett FJ, Mackie IC and Worthington HV. An investigation into the measurement of the working length in immature incisor teeth requiring endodontic treatment in children. *British Dental Journal* 1996; 181:96.
- 6- Sunada I. New method for measuring the length of the root canal. *J Dent Res.* 1962; 41:375-87.
- 7- Damle SG. Text book of Pediatric Dentistry. 3rd edition Arya(Medi) Publishing House; 2009:493.
- 8- Kaufman AY, Keila S and Yoshpe M. Accuracy of a new apex locator: an in vitro study. *Int Endod J.* 2002; 35(2):186-92.[MEDLINE]
- 9- Subramaniam P, Konde S and Mandanna DK. An in vitro comparison of root canal measurement in primary teeth. *J Indian Soc Pedod Prev Dent.* 2005; 23:124-5.
- 10- Lucineide de Melo Santos, Jose Ivo Limeira dos Reis. Comparative analysis of the electronic and radiographic determination of root canal length of primary molars-An ex vivo study. *Braz J Oral Sci.* 2009; 8(4):189-192.
- 11- Katz A, Mass E and Kaufman AY. Electronic apex locator: A useful tool for root canal treatment in the primary dentition. *Journal of Dentistry for Children* 1996;63:414-7.[medline]
- 12- Arana E and Marti- Bonmati L. Digital Radiology. *J Oral Radiology* 2002; 10:30-3.
- 13- McDonald RE, Avery DR, Dean JA. *Dentistry for the Child and Adolescent*; 8th edition. St Louis Mosby; 2004:75.
- 14- Frank AL and Torabinejad M. An in vivo evaluation of Endex electronic apex locator. *Journal of Endodontics* 1993; 19:177-9.
- 15- Cox VS, Brown CE, Bricker SL and Newton CW. Radiographic Interpretation of endodontic file length. *Oral Surgery, Oral Medicine, Oral Pathology* 1991; 72:340-4.
- 16- Ravanshad S, Adl A and Anvar J. Effect of working length measurement by electronic apex locator or radiography on the adequacy of final working length: a randomized clinical trial. *J Endod* 2010;36(11):1753-6.[MEDLINE]
- 17- Shanmugaraj M, Nivedha R, Mathan R and Balagopal S. Evaluation of working length determination methods: An in vivo/ex vivo study. *Indian J Dent Res* 2007; 18:60-2.
- 18- Budur H, Odabas and Tulunogin O. Accuracy of two different apex locators in primary teeth with and without root resorption. *Clin Oral Invest* 2008; 12:137-41.
- 19- Soujanya, Muthu MS, Sivakumar N. Accuracy of electronic apex locator in length determination in the presence of different irrigants: An in vitro study. *J Indian Soc Pedod Prev Dent* 2006; 24:182-5.
- 20- Hani FI and Al- Huwaizi HF. A clinical study to evaluate the efficiency of two different types of apex locators. A thesis submitted to the College of Dentistry/ University of Baghdad in partial fulfillment of the requirement for the degree of master science in conservative dentistry 2004.
- 21- Hulsmann M, Pieper K. Use of an electronic apex locator in the treatment of teeth with incomplete root formation. *Endodontics and Dental Traumatology* 1989; 5(5):238-41.
- 22- Venturi M, Breschi L. A comparison between two apex locators: an ex vivo investigation. *Int Endod J* 2007; 40(5):362-73.
- 23- El-Samarrai S, Misbah M. Diagnosis of initial carious lesion by clinical and conventional radiographic methods in comparison to direct digital radiography. *J Bagh Coll Dentistry* 2007;19(1):77-80.

Table (1): Mean Readings of Root Canal Length \pm SD obtain by each technique

Mean Readings	Tactile Sensation	Apex locator	Digital Radiography
Reading 1(mm)	19.84 \pm 0.008	19.943 \pm 0.033	19.95 \pm 0.012
Reading 2(mm)	19.880 \pm .052	19.9490 \pm .028	19.944 \pm 0.01
Average reading	19.86 \pm 0.042	19.94 \pm 0.030	19.9470 \pm .011

Table (2) Comparison of root canal length obtained by each technique with that obtained by conventional radiograph

	Tactile Sensation	Apex locator	Digital Radiography
Mean readings \pm SD	19.86 \pm 0.042	19.94 \pm 0.030	19.947 \pm 0.011
Conventional Radiographic reading \pm SD	19.948 \pm 0.036	19.948 \pm 0.036	19.948 \pm 0.036
Differences between readings	0.086 \pm 0.044	0.00210 \pm 0.0078	0.0066 \pm 0.031
t-test	10.76	1.151	0.118
Sig	P<0.01 HS	P>0.05 NS	P>0.05 NS

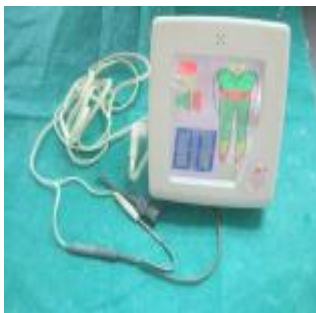

Figure (1): Apex locator device used in the research




Figure (2): Estimation of working length by conventional radiograph.

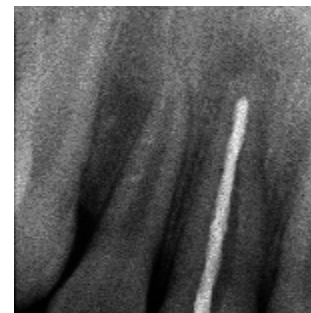

Figure (3): Estimation of working length by digital radiograph .

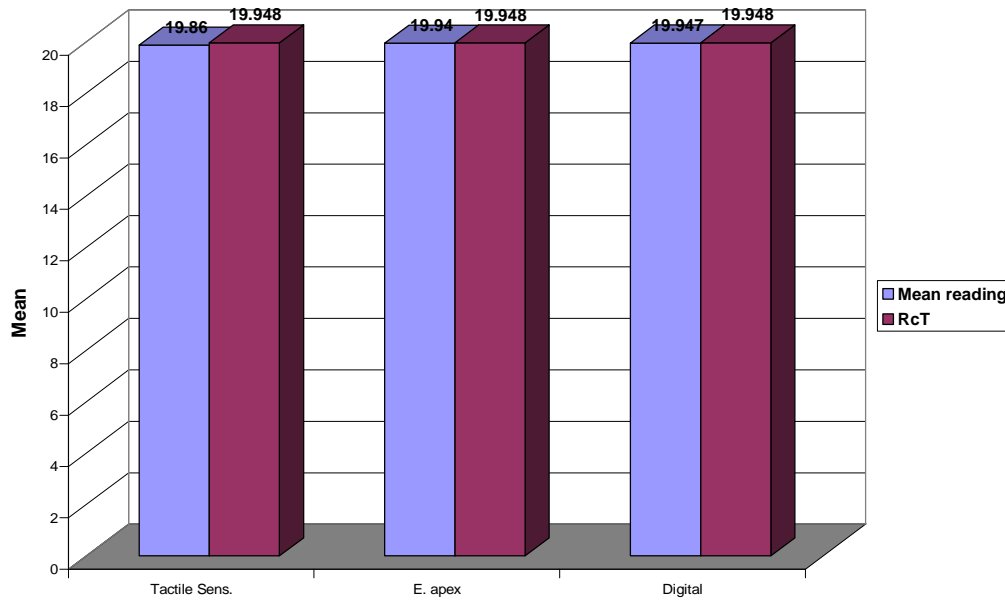


Figure (4): Differences between root canal lengths obtained by tactile sensation, apex locator and digital radiography with that obtained by conventional radiograph.