

CAROTID SYSTEM LIGATION IN SURGICAL MANAGEMENT OF SOME MAXILLOFACIAL HEMORRHAGIC LESIONS AND INJURIES

*Dr. Ghalib Abid Humaidi , BDS,FFDRCSI

ABSTRACT:

While carotid arteries ligation is uncommon procedure , but they are highly indicated in management of some hemorrhagic lesions and injuries in maxillofacial region . This will prevent possible fatal complications during surgical intervention due to uncontrolled hemorrhage .At the same time in some of these lesions and injuries urgent surgical therapy is required . Review of the anatomy , symptoms , treatment , diagnostic methods and complications is provided . As well , the successful treatment of those hemorrhagic lesions and injuries is discussed as reminder that such ligation is highly effective in controlling bleeding and saving patient`s life . Recommendations of the surgical management of those cases which necessitate ligation of carotid system are discussed .

Keywords: Carotid , ligation , hemorrhagic , lesions , injuries .

*Department of surgery Thi-Qar Medical college

INTRODUCTION:

Damage to major blood vessels in the neck is usually rapidly fatal , due to immediate blood loss . But occasionally a small tear in a major artery results in slow bleeding which might keep the patient alive for a limited time . In dealing with carotid artery damage it may be necessary to ligate part of the carotid system . ligation of the common carotid is not very effective for the control of bleeding distal to it , owing to the collateral circulation and backflow from the circle of Willis (Kazangian & Burrows 1918) .There is a risk of hemiplegia and aphasia after ligation of

the common carotid artery but neurological complications are much more likely if the internal carotid alone is occluded . Hand ley and Oldfield (1943) discuss the risks of hemiplegia after interruption of the carotid blood stream and consider that the danger is not great in patients under 40 years of age . Clarkson etal (1946) state that the low external carotid artery ligation should only be necessary when there is a need to remove a foreign body which has perforated the artery at some more distal point . In maxillofacial injuries it is uncommon to ligate the external carotid artery to control the bleeding

CAROTID SYSTEM LIGATION IN SURGICAL MANAGEMENT OF SOME MAXILLOFACIAL HEMORRHAGIC LESIONS AND INJURIES

when the artery is intact . N.L. Rowe (1979) explore and ligate the external carotid artery in the right side of the neck to control severe bleeding after surgical removal of granulomatous lesion lateral to the orbit . But with that he need to insert a heavily condensed surgiseal pack to stop blood flow from the collateral circulation and feed pack flow through ophthalmic artery . The three cases reported which necessitate ligation part of the carotid system are : Bullet injury to the internal carotid artery , Central giant cell tumor of the maxilla which was of the aggressive and highly vascular type and central hemangioma of the body of the mandible . The procedure was very effective to prevent excessive and fatal bleeding which might be happened without that ligation of major blood vessel in the neck . In the literature a case reported that a patient died from tooth extraction in the maxilla which was mobile and misdiagnose due to severe bleeding from a central hemangioma below the roots of the tooth removed . So removal of teeth in situations in which the root structures are involved with central hemangioma may produce death by one of several modalities . The patient may exsanguinate , develop shock or aspirate the high velocity and volume of blood .

ANATOMY:

The external carotid artery commences at the bifurcation of the common carotid , level with upper border of the thyroid lamina . At first somewhat medial to , it slopes upwards in front of the internal carotid artery . It give six branches in the neck . Three from in front , two from behind and one deep medial these are : 1- Superior thyroid artery arises at the commencement of the external carotid which is the first branch which aid to differentiate between external and internal carotid artery . Because the internal carotid artery give no branch in

the neck .
2- Lingual artery. 3-Facial artery. 4- Occipital artery . 5- Posterior auricular artery . 6-Ascending pharyngeal artery: arises just above the commencement of the external carotid from it`s deep aspect . The blood supply of the face could be : 1- Direct from the external carotid artery 2- Indirect from the external carotid artery in the opposite side through anastomosis 3- Back flow from internal carotid artery in the same side through the ophthalmic artery : which supplies the ethmoidal air sells , part of the lateral wall of the nose , external nose , eye lids and forehead . In all of which places its branches anastomose with branches of the external carotid (maxillary , facial , superficial temporal) thus establishing connexions between internal and external carotid systems directly and indirectly from collateral from the other side R.J. Last M.B.,B.S. (Adel) 1973 . The second point to differentiate the external carotid from the internal carotid that the external carotid commence slightly medial or deep to the internal carotid and twisted superficial to it directly after the bifurcation .

PATIENTS AND METHODS

Case 1 :

A 35 – year – old male attend the emergency department in Basrah military hospital who sustained a bullet injury in the left side of the face with continues unstopped bleeding from the mouth . By rapid examination of the case there was un inlet of a missile above the left corner of the mouth and slight swelling in the region of the left angle of the mandible . In examining the upper jaw there was perforation in the left premaxilla with the teeth destruction . There was a clear mobility in the left angle of the mandible with a

profuse bleeding from the region and there was no exit . By rapid analysis of the case and the direction of the missile a damage to one of major blood vessels was expected .There was no other associated injuries . The general condition of the patient did n`t help to send him for radiological examination . Blood and fluids prepared rapidly for him with immediate blood transfusion to control hypovolemic shock and transferred directly to the operating room .A low level slightly long submandibular incision is done to have a good access for , the bleeder to stop the bleeding , to the missile to be removed and to the angle of the mandible to fix the comminuted fracture . After delicate dissection the wide end of a bullet was seen just below the angle of the mandible and blood oozing around it . And from the direction of that bullet with its tip backward one can expect that one of major blood vessels was injured and the bullet act as a plug to minimize bleeding . And by gentle mobilization of the bullet in its place the bleeding increased vigorously, so that the bullet left in its place as a plug . Dissection continued around the bullet to detect the bleeder . Another vertical incision closed to anterior border of the sternocleidomastoid muscle to explore the region of carotid system clearly was done . and by careful dissection I found that the bullet was penetrating the internal carotid artery in a place which is difficult to repair and I decided to ligate the artery from its mesial and distal ends as a life saving procedure and the bullet removed safely . In ligation of the distal end of the internal carotid artery in that region (posterior to the angle of the mandible) one must be very careful from recoil contraction of the artery which might be pulled to the inaccessible place if it is not clamped properly . Blood transfusion continued and fixation of comminuted

angle of the mandible been done . And it was surprising that the patient in the second day after the operation was able to walk normally and he manage to come down from the first floor to the ground floor throw the stair by his own , without any sign of hemiplegia or aphasia

Case 2 :

A 21 – year – Old man attend the consultant clinic in Rasheed military hospital complaining from a swelling which was rapidly enlarging in the left maxilla of three months duration. Extra orally the swelling was very clear involving most of the left side of the maxilla from the canine fossa extended backward , medially and upward . the vision in the left eye was normal , no sign of anesthesia in the upper lip , no pain or tenderness in the region . By examining the left nostril the tumor was bulging through the lateral wall of the nose . In palpation the lesion was firm and no clear fluctuation . Intra orally the swelling was bulgy enough to involve most of the left maxilla . The surface mucosa was intact , reddish and highly vascular . The teeth are displaced with slight mobility in the premolar region , the cortical bone was very thin and part of it destroyed by the lesion . No signs of brouing or palsation . In aspiration it was unusual that the syringe filled spontaneously with pure blood and in pulling the needle out the blood continued coming out like when you aspirate from an artery . And there was a sign of endless blood under pressure aspirated from the area . Radiographic examination show a multi cystic lesion with a soap bubble appearance . Angiograph for external carotid artery show a highly vascular lesion , but there was no clear feeding artery . central giant cell tumor was the first in the diagnosis but central hemangioma and anaurysmal bone cyst were a possibility . Because the signs and symptoms are of a

CAROTID SYSTEM LIGATION IN SURGICAL MANAGEMENT OF SOME MAXILLOFACIAL HEMORRHAGIC LESIONS AND INJURIES

hemorrhagic tumor and as a life saving procedure the plane was a bilateral exploration of the external carotid arteries . With my colleagues Dr. Najih Al- Assady F.R.C.S.I. a vascular surgeon and in the operating room we ligate the external carotid artery in the left side and doing a stay suture on the right one , if the case necessitate its ligation as a life saving measure to control the collateral circulation . Bilateral ligation of the external carotid artery can be done if the case needed and gangrene of the tip of the tongue is the only possible complication . Inscisional biopsy was taken with only a few bleeding from the lesion and the case didn't need ligation of the right artery . The stay suture removed from right external carotid artery and both incisions were closed . After three days the result of biopsy was a highly vascular and aggressive type central giant cell tumor .3 days more all the tumor removed in the theater without any sign of bleeding from the region . And all the teeth were removed from the left side and primary closure is done . But after fallow up of the case 2-3 months later sign of recurrence appear in the palatal region as a granulomatous ulcer . Radical excision of all the lesion had been done without so much bleeding and the region packed opened to the maxillary sinus . No sign of recurrence noticed again , and an obturater was constructed to fill the gap and as a substitute for the missing teeth and fitted successfully in the region .

Case 3 :

A 12 – year – old boy was transferred from Al Karkh Al Jamhoory hospital to attained our clinic in Hammad Shehab military hospital both hospitals are in Baghdad . He has a history of severe bleeding from the gingival cufe of the lingual side of lower left first molar . The patient first handled in Bagooba hospital outside Baghdad

complaining from spontaneous bleeding from the gingva . And during rash manipulation from the dentist in that hospital he faced with severe bleeding from the region , And the only thing he did is a pressure pack and sending him to Al Karkh Al Jamhoory hospital which is nearly a 30 km far from Baghdad . And what they did for him in that hospital was only a zinc oxide eugenol pack in the operating room under general anesthesia . The boy was medically fit and in clinical examination there was nothing significance but only slight swelling in the left side of the mandible . Intraoral there was no bleeding and part of the pack seen .But if the pack dislodged the patient will face a fatal hemorrhage . So from that presentation the case most probably a central hemangioma of the body of the mandible . Blood investigations was normal while lateral oblique film of the left side of the mandible show an irregular cystic lesion which perforate the mandible . The lower second molar has only the crown formed . Angiography for the left external carotid artery confirmed a central hemangioma of the body of the mandible with a highly dilated inferior dental artery which was the feeding artery . So the plane was to do ligation of the left external carotid artery and blocking the inferior dental artery as well to prevent any possible collateral circulation . multi pints of blood was prepared for the patient . And in the operating room a low and long standard submandibular incision done to be enough to explore the external carotid artery and to reach the ramus of the mandible . Ligation of the artery done and through the same flap the lateral surface of the ramus exposed . A window was opened by a round bur and the inferior dental artery crushed inside the inferior dental canal and blocked with bone wax . And then the

zinc oxide eugenol pack removed intraoral without any bleeding from the region . Then the extra oral flap closed by layers and the only thing I did was a gentle irrigation for the lesion with no more manipulation in the area to prevent damage to the molar teeth . External pack used and good antibiotic cover . The patient did very well without recurrence of bleeding . Complete regression was taken place with normal bone formation in three years fallow up of the case .

DISCUSSION

Direct injury to the internal carotid artery , central hemangioma and highly vascular giant cell tumor all of them are severely hemorrhagic cases which could be fatal if they are not prepared and managed properly . Injury to the carotid arteries may cause a variety of sequelae , extravasations of blood resulting in vessel occlusion by external hematoma , late false aneurysm formation , or immediate intravascular thrombosis followed by either embolic phenomena or direct propagation of clot (Caldwell & Hadden 1948) . Either of the later complications will result in interruption of the cerebral circulation and consequent brain damage . Late aneurysm formation is a serious complication and presents diagnostic and surgical difficulties (Banks & Red path 1972) . Most reported cases occur within the first 2 months of injury (Elkin & Schumaker 1955) . Generally speaking that control of heamorrhage is usually note a major problem in maxillofacial injuries but in occasion it may be necessary to clamp and ligate larger vessels . Removal of teeth in situations in which the root structures are involved with central heamangioma may produce death . The patient may exanguinate develop shock , or aspirate the high velocity and volume of blood .

Identification of these lesions may be farly simple . There may be history of hemorrhage from the gingival cuffs around the teeth , loosing of the teeth accompanied by hemorrhage , mobility of teeth , palpable thrill over the lesion , or a bruit noted by stethoscopic auscultation . Or endless blood , sometimes under pressure , may be aspirated from the area . Overlying tissues may have color and contour changes . On the other hand any or all of these findings may be present . Radiological interpretation is not reliable . Obviously if there are otherwise clinically healthy teeth in un area of radiolucency , then further investigations is indicated to diagnose the radiolucent lesion . Therefore one should consider aspirating central radiolucent lesions prior to performing invasive surgical procedures including simple exodontics . In the event of tooth is removed and an otherwise undiagnosed central vascular lesion is exposed , the tooth may be replaced immediately in the alveolus as stopper and the patient should be transferred to an inpatient facility without delay for evaluation and definitive care . When performing a biopsy of central lesion of the jaws one should concenter aspiration . Operations on bone underlying soft tissue hemangiomas may not pose a problem , although , obviously , precautions should be considered to include typing and cross matching the patient `s blood and having several units on standby . Albrecht`s used the term hamartoma to describe those tumor like masses that are composed of a mixture of tissues normal to the part in which they are occurring and that are due to an anomaly in tissue developed . These are not true neoplasms : Their growth potential is limited , and growth ceases when the host has reached full maturity . Many hamartomas conform closely to this general description and

CAROTID SYSTEM LIGATION IN SURGICAL MANAGEMENT OF SOME MAXILLOFACIAL HEMORRHAGIC LESIONS AND INJURIES

hemangioma is one of them . They may grow rapidly and even alarmingly , but in time the growth rate diminishes and finally ceases or regress completely . Giant cell tumor of bone (osteoclastoma) found in patients between 20-40 years of age . the tumor destroys bone locally by pressure atrophy and in some cases by actual invasion . this produce the characteristic soap – bubble appearance seen radiologically . About 15 percent of giant cell tumor metastasis to the lung . The tumor usually seen in long bones , and is very rare in the jaws and the one which I did in the maxilla is one of them . The histological features of giant cell tumor are the many large multinucleated giants cells in a very vascular stroma in some cases . These tumors are sometimes aggressively invasive and after excision recurrence develop in about a third of the cases : Amputation may ultimately be necessary . It must be emphasized again that though a true osteoclastoma can in theory develop in the jaws , it must be very rare . There are two schools about the existence of giant cell tumor of bone : 1- This lesion represents a distinct entity separate from other bone lesions and occurs in both a benign and malignant form 2- The lesion represent a form of osteogenic sarcoma whose individual lesions vary in their degree of malignancy . Histological the tumor is characterized by large multinucleated giant cells of similar appearance to osteoclasts lying in a spindle cell stroma . Hemorrhagic areas are common . And the case which I did contain a scanty of those hemorrhagic areas seen in incisional biopsy done prior to the invasive surgery .And as a conclusion those hemorrhagic lesions and injuries should be assessed very carefully prior to surgical procedure to show the right surgical plane which include in some of those cases ligation

part of the carotid system in order to control a severe hemorrhage which could be fatal to the patient . And we must always remember that the blood supply to the face reach in three ways : 1- Direct blood supply from external carotid artery in that side . 2- Indirect from the collateral circulation from the external carotid artery in the opposite side . 3- Through a backflow of blood from the internal carotid artery through the ophthalmic artery in the same side. So sometimes ligation of external carotid artery is not enough to control bleeding like in the case done by Mr.N.L.Rowe in Queen Mary hospital in London in (1979) in which I was with him in the theater during my training course for fallow ship in the maxillofacial unit in that hospital . And the case was necessitate a good surge seal pack in the region in addition to the ligation . That was to control both the collateral circulation and back flow from internal carotid artery . And I think this procedure with additional pack might be needed more in hemorrhagic lesions of the maxilla than that of the mandible due to high vascularity , backflow and collateral circulation in the maxilla than that in the mandible .

ACKNOWLEDGEMENTS

I am grateful to Assistant professor Dr. Moayed Naji Majeed : MBChB ,DCH ,FICMS (Ped) Paediatric Department ,Dean of the College of Medicine Thi-Qar University for his guidance and encouragement in the preparation of this paper .I would like to thank assistant Professor Dr.Ali Naif Asee MBChB, CABS , F.I.C.M.S Department of Surgery college of Medicine Thi-Qar University for his help . And I would like also to thank my son civil engineer Saif for his computer work in typing this manuscript and photographic pictures .

Table 1:- The Results of ligation of carotid system in the management of hemorrhagic maxillofacial lesions and injuries

Type of injury	Type of lesion	The site	The major artery ligated	Bleeding after ligation	The result
Pent rating bullet injury sateled in the left internal carotid artery		entrance above the left angle of the mouth	Left internal carotid artery	Completely controlled	The patient walk normal without any sign of hemiplagia or aphasia
	Central giant cell tumor of bone	Most of the left maxilla	Left external carotid artery	Very few	Recurrence accurse treated successfully by complete amputation
	Central hemangioma of bone	Left body of the mandible	Left external carotid artery with occlusion of left inferior dental artery	None	Complete regression of the lesion with complete healing two years fallow up

**CAROTID SYSTEM LIGATION IN SURGICAL MANAGEMENT OF SOME
MAXILLOFACIAL HEMORRHAGIC LESIONS AND INJURIES**

**Figure (1.1): Penetrating injury from above the left corner of the
mouth rest in the left internal carotid artery**

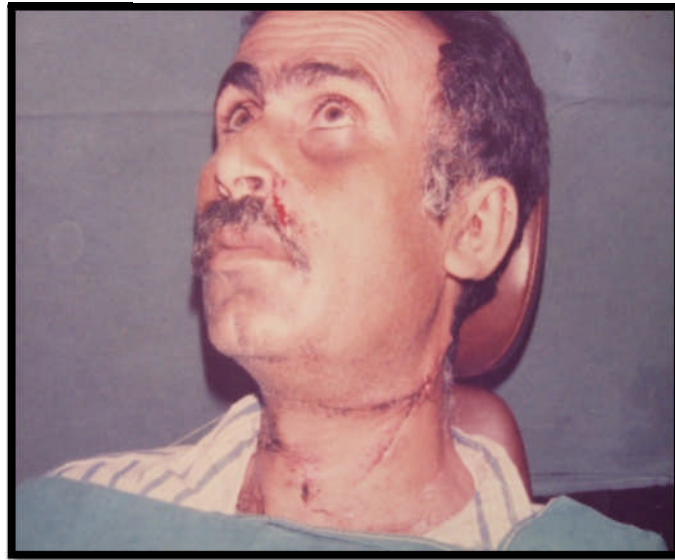

Figure (1.2):The same patient without signs of hemiplagea



**Figure 2-1:A large swelling in the left maxilla . Extra oral
(central giant cell tumor)**

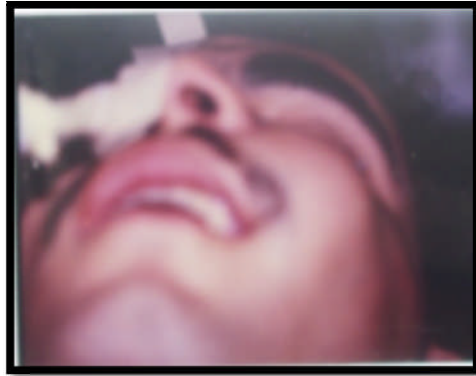

Figure 2-2:The same patient intra oral swelling

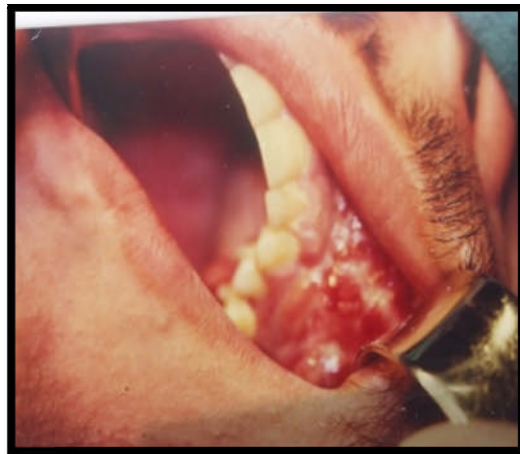
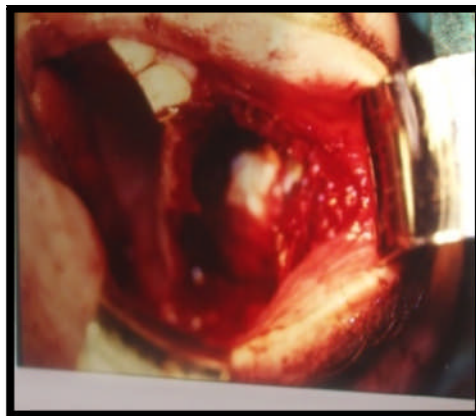
Figure 2-3:Excesion of the tumor with primary closure



**CAROTID SYSTEM LIGATION IN SURGICAL MANAGEMENT OF SOME
MAXILLOFACIAL HEMORRHAGIC LESIONS AND INJURIES**

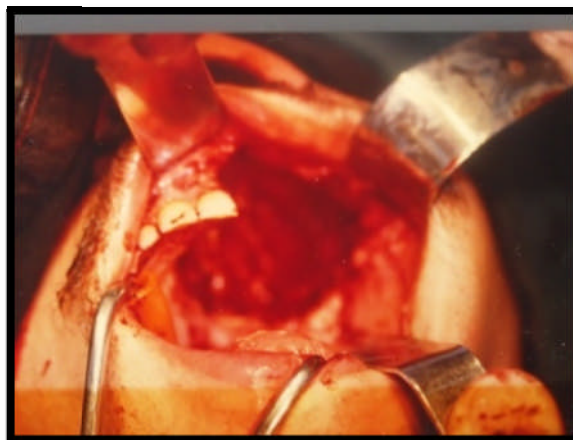
Figure 2-4: The same patient after complete healing

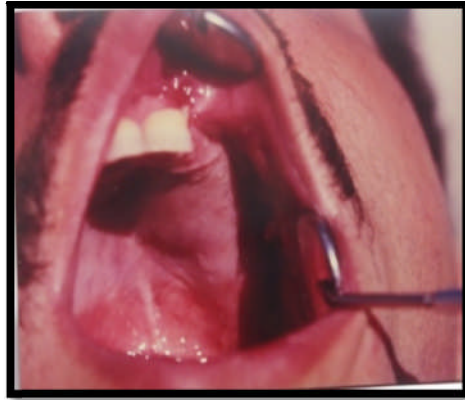

Figure 2-5: Recurrence occur after two months

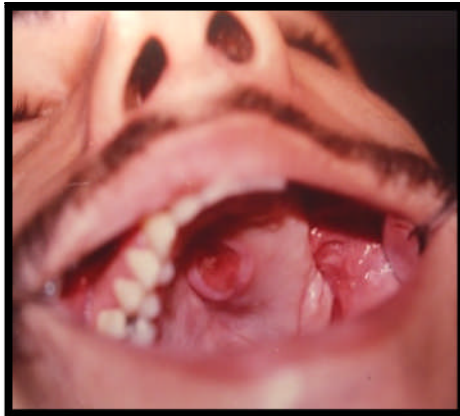

Figure 2-6: The same patient after radical removal of the tumor



REFERENCES

- 1-Allen,W.E.III,Kier,E.L,and Rothman , S.L.G,The maxillary artery :normal arteiographic anatomy , Am.J.Radiol . 118:517 , 1973.
- 2-Banks , P.,& Redpath , T.H.(1972) close carotid artery haemorrhage as complication of minor gunshot wounds of Face and jaws . Journal of oral surgery , 30 , 176 .
- 3-Battersby , T.G. : Cavernous hemangioma of the mandible , Br. Dental.g . 103 : 347 ,1957 .
- 4-BERTRAM COHEN, IVOR R .H. KRAMER Text book of Scientific Foundations of Dentistry LONDON WILLIAM AND HEINEMANN MEDICAL BOOK LTD (1976).
- 5-Buschke , F. , and Cantril , S.T. : Roentgenotherapy of benign giant , cell tumor of bone . Cancer , 3 : 293 , 1949 .
- 6-Caldwell , H.W., & Hadden, F. C. (1948) Carotid artery thrombosis: report of eight cases due to trauma Annals of internal Medicine , 28 , 1132 .
- 7-Emergency War surgery :Third United States Revision , 2004 (text books of military medicine)13/12/2004 by Ay Andy C.Szul , Lorrain P.Davis , Walter Reed Army Medical Center Borden Institute .
- 8-Gerwig, W.H., Zinnermann , B.,& Robels, N.L.(1966) Experimental determination of the thermal effects on blood vessels from high velocity missiles . Surgery . 59 , 1065 .
- 9-Gustav O. Kruger Text book of oral and Maxillofacial Surgery Sixth edition . The C.V.Mosby Company .
- 10-Handley , R.S.,& Oldfield , M. (1943) Gunshot Aneurysm of carotid artery . Lancet , II , 40 .
- 11-Hutter , R. V. P. , Worcester , G. N . , Gr , Francis , K. C, Foote , F. W. , Gr , and Stewart , F. W . : Benign and malignant giant cell tumors of bone . A clinicopathological analysis of the natural history of the disease . Cancer , 15:653 , 1962 .

CAROTID SYSTEM LIGATION IN SURGICAL MANAGEMENT OF SOME MAXILLOFACIAL HEMORRHAGIC LESIONS AND INJURIES

- 12-Idem:Cavernous Hemangioma of the soft palate .G. Oral Surg. , 6 . 85 , 1948 .
- 13- Idem : Giant cell tumors of the Jaw bones . Oral Surg. , Oral Med. & Oral Path, 6 : 1055 , 1953 .
- 14-Kazanjian , V.H.,& Burrows , H. 1918 The treatment of haemorrhage caused by gunshot wounds of the face and jaws . British Journal of Surgery , S, 126 .
- 15- Kennedy A. C. and Blumgart L. H text book of Essentials of Medicine and Surgery for Dental students SHURCHILL LIVINGSTONE EDINBURGH London and New York 1977 .
- 16- LaDow , C.S. and Tatoian, J.A., Jr : Treatment of central haemangioma of the maxilla by embolization ,J. Oral Surg. 43 : 622 , 1976 .
- 17-LICHTEN STEIN , L. (1966) "Bone tumors" , 3rd ed. St. Louis : Mosby .
- 18-LUCAS , R. B. (1972) . Pathology of tumors of the Oral Tissues , 2nd ed.,368 . Edinburgh : Churchill Living stone .
- 19- Macansh,J. D. , and Owen , M.D. : Central heomangioma of the mandible , J. Oral Surg. 30 : 293 , 1972 .
- 20- N.L.Rowe , G. LI . Williams Text book of maxillofacial injuries CHURCHILL LIVINGSTONE EDINBURGH LONDON MELBOURNE AND NEW YORK 1985
- 21-Peripheral Arterial Disease 17/3/2009 by Robert Dieter ,Jr . ,Raymond Dieter ,III,Raymond Dieter .
- 22- R.A.Cawson a Text book of Essentials of Dental Surgery and Pathology THRID EDITION CHURCHILL LIVINGSTONE (1978) .
- 23- R.J.Last M.B , B. S. (Adel.) ,A Text book of Anatomy Rtional and Applied (1973) .
- 24-Silvessterini m. ,Vernieri F.,Pasqualitti P. ,et al :Impaired cerebral Vasoreactivity and Risk of Stroke in patients with Asymptomatic Carotid Artery Stenosis .JAMA 2000; 383:2122-2127 .
- 25-Vascular Emergencies(European Vascular Course)4/4/2003 by Alain , MD Branchereau .
- 26-Vascular Surgery (Springer Specialist Surgery Series) 1/9/2003 by: Alun H.Davies ,Colleen M . Brophy ,john Lumley .

27-Vernieri F , Pasqualetti P,Matheis Met al :Effect of collateral flow and cerebral vasomotor reactivity on outcome of carotid artery occlusion .Storke 2001 ; 32 : 1552 – 1558 .

28-Walter G. B. , Hamilton M.C. Text book of Principles of pathology for Dental Students third Edition CHURCHILL LIVINGSTONE Edinburgh & London (1974) .

29-WILLIAM G. SHAFER, A Text book of oral Pathology SECOND IDITON W. B. SAUNDERS COMPANY PHILADELPHIA AND LONDON (1964)

عملية ربط شرايين الجهاز السباتي في التداخلات الجراحية لعلاج بعض الإصابات والحالات النزفية في منطقة الوجه والفكين

*د. غالب عبد حميدي زميل كلية الجراحين الملكية البريطانية

أخلاصه :

بينما تكون عملية ربط الشرايين السباتية هي من العمليات الخاصة ولا يلجا لها دائما لكنها ضرورية جدا في معالجة بعض الحالات والإصابات النزفية في منطقة الوجه والفكين وفي هذه العملية يمكن تفادي المضاعفات القاتلة التي يمكن أن تحدث في المداخلات الجراحية لمعالجة مثل هذه الحالات بسبب النزف الشديد الخارج عن السيطرة . وفي نفس الوقت يمكن ان تاتي مثل هذه الحالات كحاله طارئة وتحتاج الى تدخل جراحي سريع لانقاذ حياة المريض . توضيح الناحية التشريحية وخاصة لمجموعة الشرايين السباتية والعلامات السريرية والتشخيص وطرق العلاج والمضاعفات لمثل هذه الحالات سيتم عرضه. وكذلك العمليات الناجحة التي تم اجراؤها لهذه الحالات النزفية لكي تذكر العاملين في هذا الاختصاص ان مثل هذا الربط الى الشرايين السباتية له التأثير الناجع بالسيطرة على النزف الشديد الذي يرافق مثل هذه الحالات والتي يتم بواسطتها انقاذ المريض من هلاك اكيد . كذلك سنقدم بعض النصائح في العمليات الجراحية لاحتواء مثل هذه الحالات والتي تستوجب في بعضها ربط احد شرايين الجهاز السباتي والتي سيتم مناقشتها باسهاب .

*قسم الجراحة / كلية الطب / جامعة ذي قار / ذي قار