

Assessment of PTEN Deletion or Signal Reduction in Breast Carcinoma Using FISH Technique in A Sample of Iraqi Female Patients

Mohammed R.F. Al-Taie¹ MSc, Ban J. Qasim² PhD

¹Dept. of Pharmacy, Al-Esraa University College, Baghdad, Iraq, ²Dept. of Pathology and Forensic Medicine, College of Medicine, Al-Nahrain University, Baghdad, Iraq

Abstract

- Background** PTEN (phosphatase and tensin homolog) gene is located at the 10q23 region that regulates cell proliferation and survival mainly by regulating PI3K (phosphatidylinositol 3-kinase)-AKT (protein kinase B) signaling pathways. PTEN gene is one of the most frequently mutated tumor suppressor genes in human cancer. Loss of PTEN gene can cause overgrowth, proliferation, survival, and metabolism of tumor cells. In breast cancer, loss of PTEN gene is associated with the occurrence of tumor and is significantly correlated with its characteristics.
- Objective** To assess the frequency of PTEN deletion or signal reduction in breast cancer in a sample of Iraqi female patients using FISH technique and its relation with clinico-pathological parameters (age, tumor size, multicentricity, histopathological types, grade, pathological stage and lymph node status).
- Methods** This is a retrograde, case control study, which was conducted at the Department of Pathology and Forensic Medicine, College of Medicine, Al-Nahrain University for the period between October 2019 to November 2020. It involved 30 patients with breast cancer who underwent mastectomy and 30 patients with benign breast lesions.
- Results** PTEN gene deletion or signal reduction was observed in 8 (26.67%) out 30 breast cancer patients. There was a significant relation between PTEN gene deletion (or signal reduction) and larger tumor size, higher grade, advanced pathological stage, and metastasis to more than 4 lymph nodes.
- Conclusion** There was significance difference between cases and control groups regarding PTEN deletion or signal reduction. There was significant correlation between PTEN gene deletion or signal reduction and larger tumor size, higher pathological grade and advanced stage.
- Keywords** PTEN gene, breast cancer, FISH technique
- Citation** Al-Taie MRF, Qasim BJ. Assessment of PTEN deletion or signal reduction in breast carcinoma using FISH technique in a sample of Iraqi female patients. *Iraqi JMS*. 2021; 19(2): 152-162. doi: 10.22578/IJMS.19.2.4

List of abbreviations: BAD = BCL2 associated agonist of cell death, BC = Breast cancer, CENP-C = Centromeric protein C, FAK = Focal adhesion kinase, FFPE = Formalin fixed paraffin embedded, FISH = Fluorescent In situ Hybridization, GSK3 = Glycogen synthase kinase 3, H&E = Hematoxylin and Eosin, IDC = Invasive ductal carcinoma, ILC = Invasive lobular carcinoma, IRB = Intuitional Review Board, IRS = Insulin receptor substrate, LOH = Loss of heterozygosity, mTOR = Mammalian or mechanistic target of rapamycin, PI3K = Phosphatidylinositol-3-kinase, PKB or Akt = Protein kinase B, PTEN = Phosphatase and tensin homolog gene, TSC = Tuberous sclerosis

Introduction

The World Health Organization (WHO) reported that the incidence rates of breast cancer (BC) are steadily getting higher (1% to 5% increase every year) in countries of the Eastern Mediterranean Region (including Iraq) ⁽¹⁾. In Iraq, the Ministry of Health/ Cancer Registry Council reported that

BC ranks the first among the top ten malignant neoplasms affecting the Iraqi females in 2018; comprising 34.06% (6094 cases) of the total number of female patients with cancer in Iraq⁽²⁾. During 2018, 1727 women died from BC making it the second most common cause of mortality after lung cancer⁽³⁾.

Phosphatase and tensin homolog gene (PTEN) is located at chromosome 10. It is a tumor suppressor gene that regulates vital cell functions such as proliferation, cell motility, genomic stability and survival through controlling the function of phosphatidylinositol 3-kinase (PI3K)/protein kinase B (PKB, also known as Akt)/ Mammalian target of rapamycin (mTOR) signaling pathway⁽⁴⁾.

The PI3K proteins activate PKB that phosphorylates tuberous sclerosis protein 1 (TSC1) and TSC2 leading to dissociation of TSC1–TSC2 complex (which negatively regulates the activity of the kinase mTOR); Therefore, AKT results in the activation of mTOR complex 1 (mTORC1) and ultimately leading to increased protein and lipid synthesis and decreased autophagy, hence promoting cell growth and proliferation^(5,6). PTEN negatively regulates PI3K signaling and downstream PI3K family members, including AKT, leading to inhibition of growth and survival signals and suppressing tumor formation^(7,8).

Thus, PTEN inactivation leads to cells proliferation, promoting cell growth, migration and survival through multiple downstream effectors that enhance the growth of neoplasm⁽⁴⁾. PTEN gene is deleted frequently in various human tumor types, and alterations to PTEN gene were reported to have effect on prognosis in primary and metastatic neoplasms, including BC⁽⁹⁾. The frequency of PTEN deletions or reduced expression in BC varies from 4 % to 63 % in the literature^(9,10). Several studies have provided evidence that PTEN loss is significantly related to aggressive behavior of BC, including larger size of tumor, metastasis to lymph nodes, poor

differentiation and advanced pathological stage⁽⁹⁻¹¹⁾.

This study aims to assess the frequency of PTEN deletion or signal reduction using Fluorescent in Situ Hybridization (FISH) technique in BC patients in a sample of Iraqi patients and its relation with the clinico-pathological parameters (including patients' age, tumor size, multicentricity, histopathological types, grade, stage and lymph node involvement).

Methods

This is a case control study, which was conducted at the Department of Pathology and Forensic Medicine, College of Medicine, Al-Nahrain University. The study was approved by Institutional Review Board (IRB) of the College of Medicine, Al-Nahrain University.

A total of 30 formalin-fixed paraffin embedded (FFPE) blocks of breast tissue specimens from patients who were diagnosed with BC and underwent mastectomy during 2019 and 2020 were collected from Al-Imamein Al-Kadhimein Medical City and from the Oncology Teaching Hospital-Medical City. Thirty FFPE blocks of breast tissues from benign breast lesion were also collected from the same centers and were used as a control group.

Clinical and pathological information were collected from patients' pathology report. From each FFPE tissue blocks, two sections of 5 µm thickness each were obtained. One section was stained with hematoxylin and eosin (H&E) stain for revision of the diagnosis. The other section was placed on positively charged slide for FISH study of PTEN gene using ZytoLight FISH (PTEN/CEN 10 Dual Color) Probe.

Evaluation of PTEN gene had been carried out using Zeiss Axio Imager Z2 fluorescent microscope with 40X objective lens. Three filters had been used RED, DAPI and FITC filter for specimen evaluation. The final result of the slide was processed and produced by MetaSystems Isis software of the fluorescent microscope. The PTEN/CEN 10 dual color probe consists of ZyGreen labeled polynucleotides

which target PTEN gene region on chromosome 10, and ZyOrange labeled polynucleotides, which target the centromeric region of the same chromosome.

Hybridization signals of 50 non-overlapped nuclei were counted manually. Normal cells or cells without a deletion involving the PTEN gene region show, two green and two orange signals. Orange signals represent chromosome 10 centromeres. A cell with a deletion affecting PTEN gene region shows a reduced number of green signals. Presence of fewer PTEN signals than centromere 10 probe signals in >30% of tumor nuclei were considered as heterozygous deletion. Complete absence of PTEN signals in the tumor cells, with presence of centromere 10 signals in >20% of tumor nuclei was considered homozygous deletion⁽¹²⁾. Tissue spots lacking any detectable PTEN signals in all (tumor and normal cells) or lack of any normal cells as an internal control for

successful hybridization of the FISH probe were excluded from analysis⁽⁹⁾.

Results

Eight cases of BC out of 30 cases showed PTEN signal reduction or complete deletion, forming 26.67%. Seventy five percent of which (6 cases) showed reduced signal of PTEN gene (only 1 signal out of 2 was deleted) (Figures 1 and 2), while 2 cases demonstrated complete loss of PTEN signal (Figure 3). However, the remaining of the cases (22 cases (73.33%)) showed no deletion or signal reduction of PTEN signal (Figure 4). Regarding control group, none of the patients in the control group showed signal reduction or deletion in PTEN gene expression (Figure 5). There was significance difference between cases and control groups regarding PTEN deletion or signal reduction (P value=0.0024).

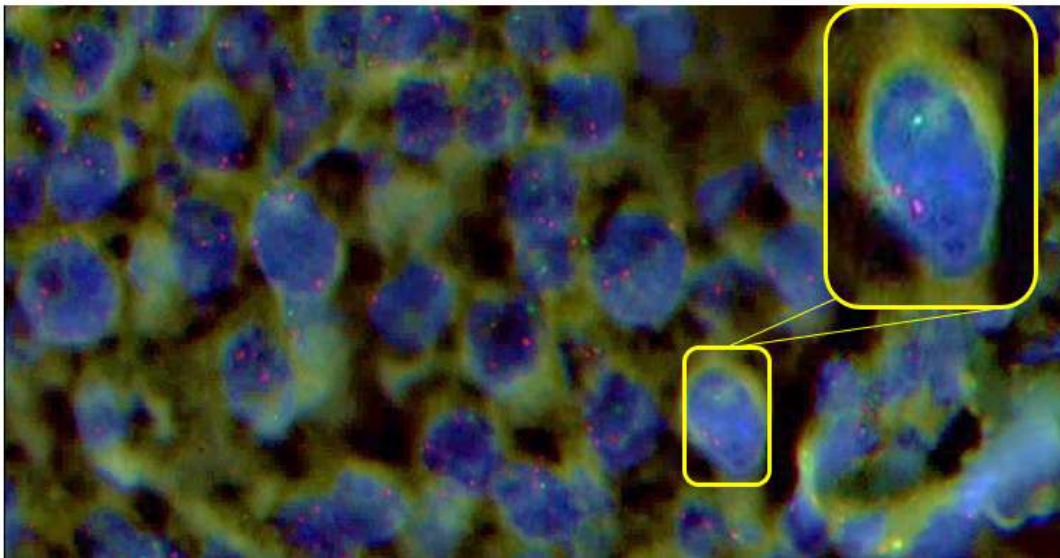


Figure 1. Invasive ductal carcinoma of the breast (grade 3) showing reduced signal of PTEN gene (partial deletion of the gene). Inset on right top corner showing a magnified cell with partial PTEN gene deletion (two orange signals and one green signal). This slide was displayed with 40X magnification.

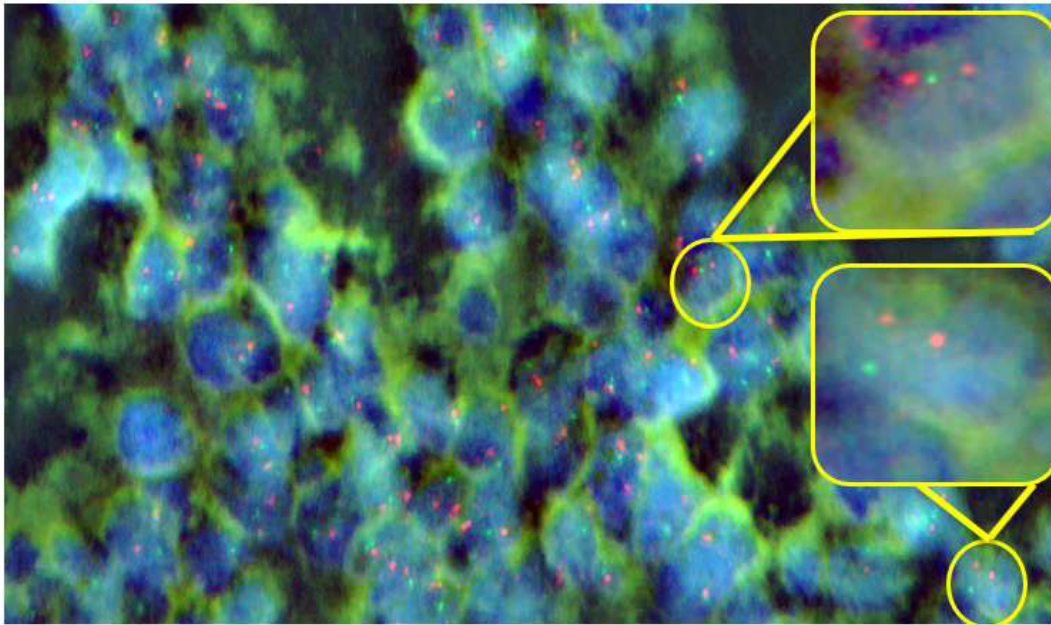


Figure 2. Invasive ductal carcinoma of the breast (grade 3) showing reduced signal of PTEN (partial deletion of the gene). The 2 insets are showing magnified cells with partial PTEN gene deletion (two orange signals and one green signal). This slide was displayed with 40X magnification

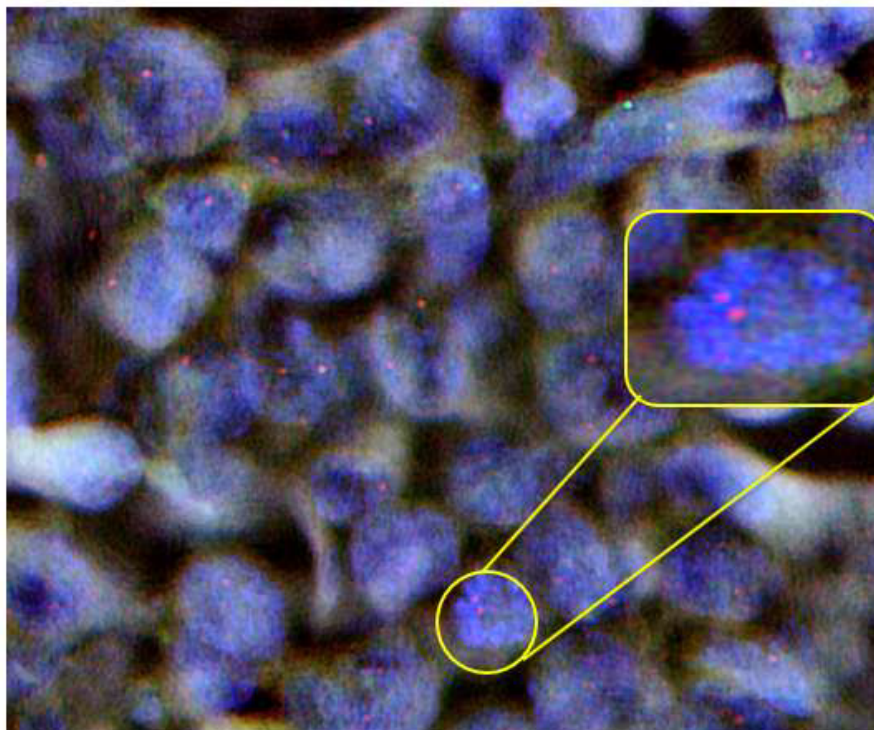


Figure 3. Invasive lobular carcinoma of the breast showing complete deletion of PTEN gene on chromosome 10. The 2 insets are showing magnified cells with two orange signals and loss of both green signals. This slide was displayed with 40X magnification

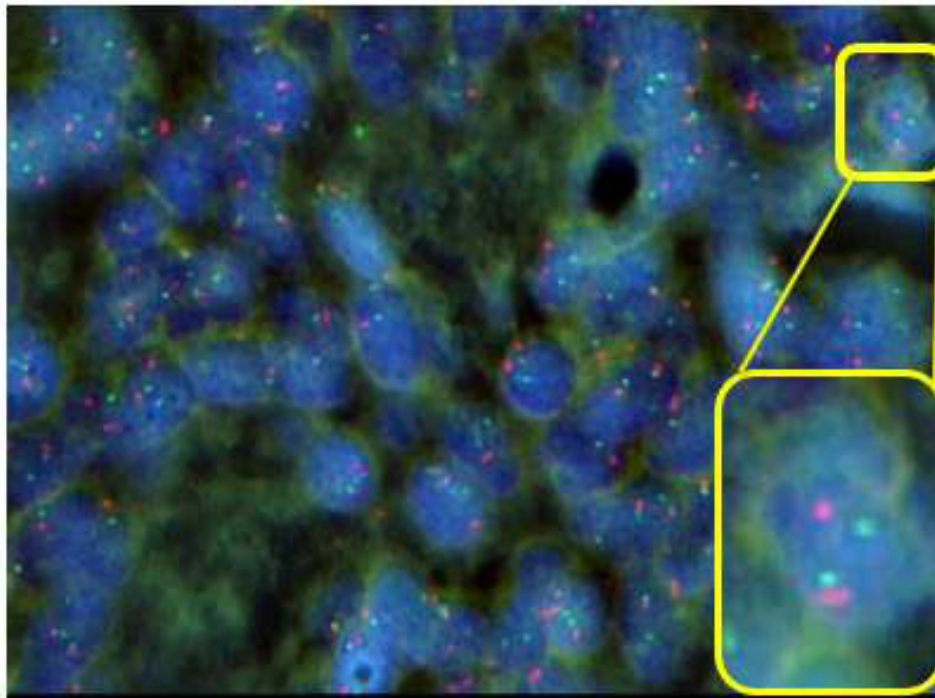


Figure 4. Invasive lobular carcinoma of the breast showing normal signal of PTEN gene. The inset on the right corner is showing a magnified cell with normal PTEN gene signal (two green signals and two orange signals). This slide was displayed with 40X magnification

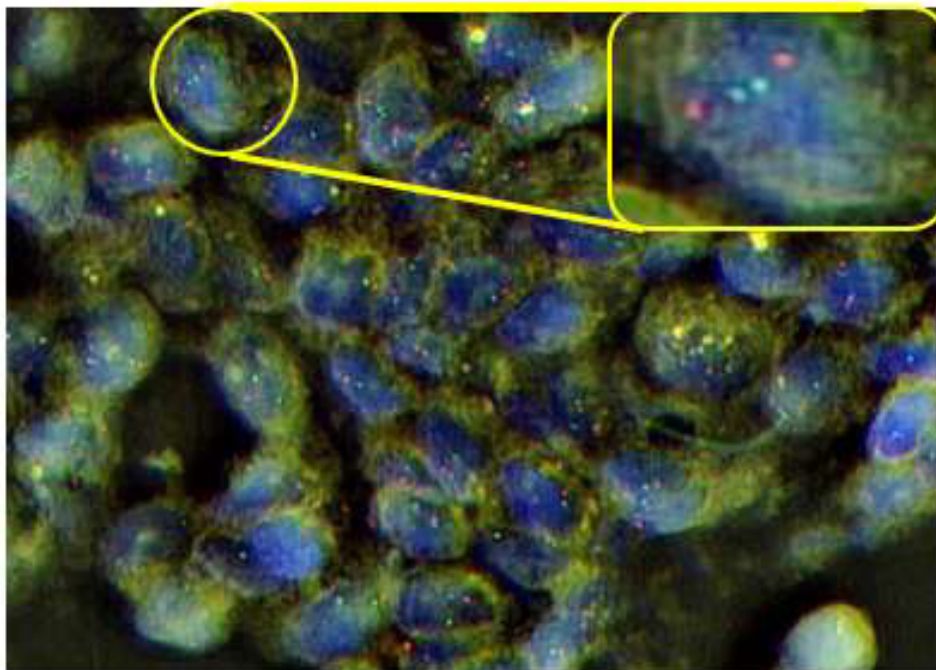


Figure 5. Fibroadenoma of the breast, showing normal signal of PTEN gene. The inset on the right corner is showing a magnified cell with normal PTEN gene signal (two green signals and two orange signals). This slide was displayed with 40X magnification.

Mean age of patients with PTEN deletion was 43.5 ± 11.12 years, while the mean age of BC patients with no deletion in PTEN gene was 55.63 ± 9.53 years. There was no statistically significant difference in mean age between deleted PTEN gene and non-deleted PTEN gene groups (P value=0.7664) (Table 1).

BC patients were categorized into three groups based on the tumor size (group 1: included patients with tumor size < 2 cm, group 2: ≥ 2 cm and < 5 cm, and group 3: ≥ 5 cm). Eight patients out of 30 cases (26.67%) were in group 1, group 2 had 16 patients (53.33%) and the remaining 6 cases (20%) of the cases were in group 3. Two out of 16 patients (12.5%) of group 2 displayed reduced signal of PTEN gene. Six out of six patients (100%) in group 3 showed a reduced or deleted signal of PTEN gene. There was a highly statistically significant correlation between reduced or deleted PTEN gene signal and tumor size (P value =0.0001) (Table 1).

Regarding multicentricity, only four out of thirty cases (2 cases were invasive ductal carcinoma (IDC) and the other 2 cases were invasive lobular carcinoma (ILC)); collected reported multicentric breast tumor forming a percentage of 13.33%. Two of them (50%) displayed PTEN gene deletion, the remaining 2 (50%) cases showed no reduction in PTEN gene signals. There was no statistical significance in the relationship between PTEN deletion and multicentricity (P value =0.26) (table 1).

Twenty six out of 30 cases (86.67%) were diagnosed as IDC (Figure 1) and six of them (23.07%) showed PTEN gene deletion (Figure 5 and 6). On the other hand, only 4 out of 30 cases (13.33%) were ILC (Figure 2) and 2 of them (50%) showed reduced or deleted signal in PTEN gene signal (Figure 7). There was no statistical significance in relation between the PTEN reduced or deleted signal with tumor pathological type (P=0.25) (Table 1).

Eighty percent (24 out of 30 cases) were diagnosed as grade II (moderately differentiated) and 4 of them (16.67%) showed

PTEN gene reduced or deleted signal. Twenty percent (6 cases) were diagnosed with grade III (poorly differentiated), half of them (4 cases) demonstrated PTEN deletion or signal reduction. No cases were presented with grade I in the case group. There was a statistical significance in the relationship between the PTEN gene reduced or deleted signal with tumor pathological grade (P=0.013) as shown in table 1.

Four cases out of 30 patients with BC were diagnosed with pathological stage I forming 13.33%, all of them showed normal PTEN gene signal. Most of cases were in stage II with 16 cases making 53.33% of the group, however only 2 of them (12.5%) showed deleted PTEN gene or reduced signal. Finally, 10 patients in the cases group presented with stage III (33.33%) and 6 of them (60%) revealed reduced or deleted PTEN gene signal. There was statistically significant difference in relation between the PTEN reduced or deleted signal with tumor pathological grade (P=0.012) (Table 1)

Fourteen patients were recorded with lymph nodes metastasis. From these patients, 6 of them were found to have a reduced signal of PTEN gene. This means that 75% (6 out of 8) of patients with PTEN gene deletion had positive lymph nodes metastasis. However, there was no statistically significant difference between PTEN deletion or signal reduction and lymph node metastasis (P value=0.0606) (Table 1).

All the patients with PTEN gene deletion or signal reduction and lymph node metastasis (6 out of 6 (100%)) were found to have metastasis in 4 or more lymph nodes. On the other hand, there were 8 patients with normal PTEN gene expression who had lymph nodes metastasis; 4 out of 8 (50%) had lymph node metastasis in < 4 lymph nodes, and the other 4 (50%) had lymph node metastasis in ≥ 4 lymph nodes. There was statistically significant difference between PTEN gene deletion and number of lymph nodes invaded (equal or more than 4 lymph nodes), P value=0.0404 (Table 1).

Table 1. Relationship between PTEN gene status and clinico-pathological characteristics of breast cancer patients

Feature		Breast cancer patients with normal PTEN gene	Breast cancer patients with Reduced or deleted PTEN gene	Total	P value
Age (mean ±SD)		55.63±9.53	43.5±11.12		0.76
Tumor size	Group 1	8	0	8	0.0001
	Group 2	14	2	16	
	Group 3	0	6	6	
Multicentric		2	2	4	0.26
Pathological type	IDC	20	6	26	0.25
	ILC	2	2	4	
Grade	Grade I	0	0	0	0.013
	Grade II	20	4	24	
	Grade III	2	4	6	
Pathological stage	Stage I	0	4	4	0.012
	Stage II	14	2	16	
	Stage III	4	6	10	
Lymph nodes invasion	Yes	8	6	14	0.0606
	No	14	2	16	
Number of lymph nodes invaded	<4	4	0	4	0.0404
	≥4	4	6	10	

IDC = Invasive ductal carcinoma, ILC = Invasive lobular carcinoma

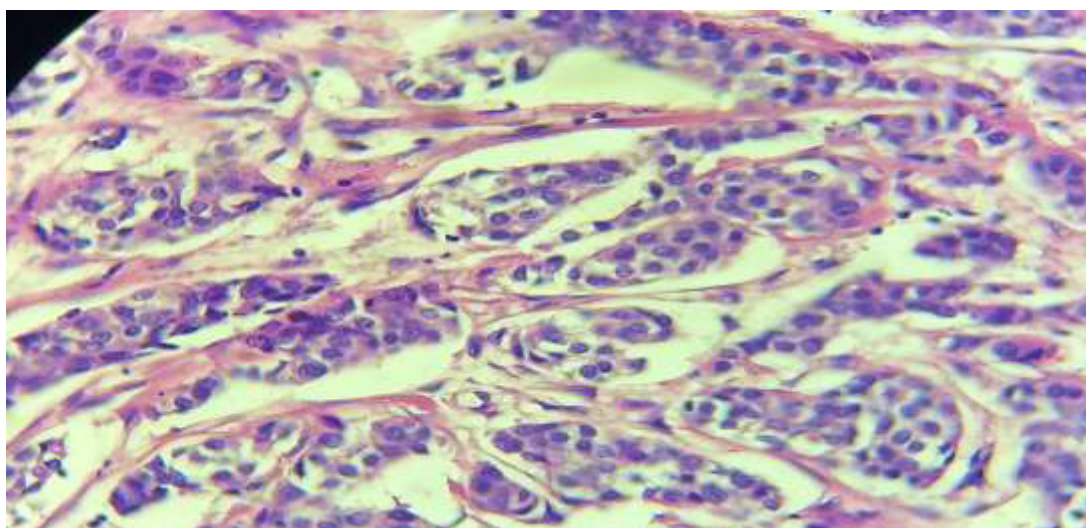


Figure 6. Invasive ductal carcinoma. Section showing malignant mammary cells forming nests. Malignant cells are large pleomorphic with large vesicular nuclei with prominent nucleoli. (H&E, double magnification of (40X) magnification)

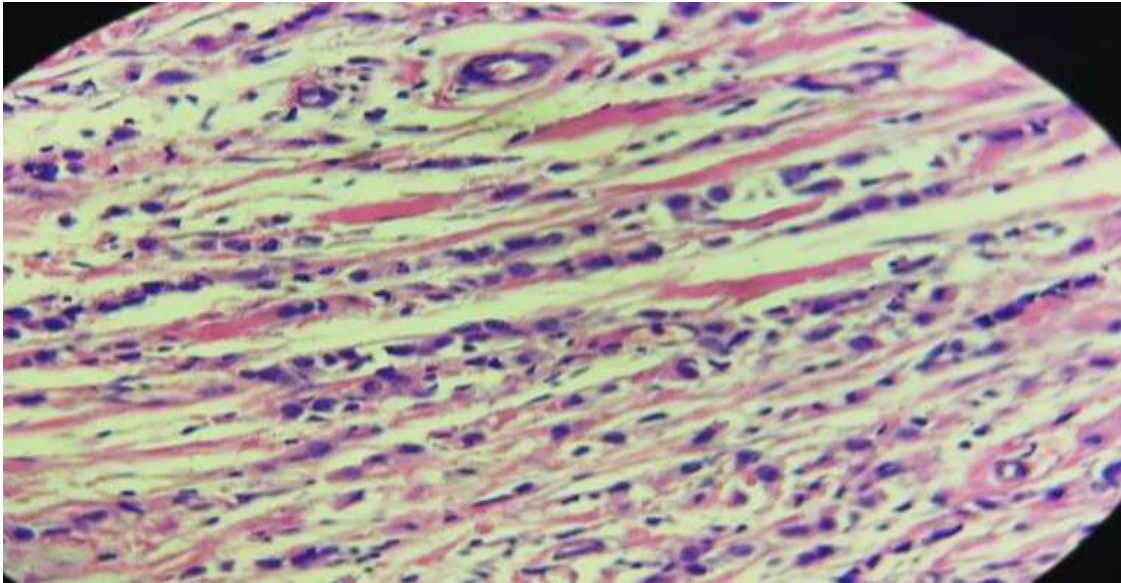


Figure 7. Invasive lobular carcinoma. Section showing breast tissue is invaded by malignant cells forming cords pattern. Malignant cells are arranged in a single line pattern (Indian file). Malignant cells are pleomorphic with different sizes with pleomorphic and hyperchromic nuclei. (H&E, 40X)

Discussion

This study showed a significant PTEN gene deletion or signal reduction in around quarter of the sample patients with BC (26.67% P value=0.0024). The percentage of PTEN gene deletion was varied among other studies; Lebok et al. (2015) 19%, Beg et al. (2015) 6.4%, Al-hamadawi et al. (2015) 58.8% and Bazzichetto et al (2019) 30-40%^(9,11,13,14). This variation in percentage of PTEN gene deletion in BC was mentioned in a meta-analysis which stated that PTEN deletion or reduced expression is present in 4% to 64% of BC patients⁽¹⁰⁾. These variations in the percentages can be attributed to sample sizes, genetic and racial differences, and techniques used to assess the gene deletion.

Many studies suggested that complete deletion to of PTEN gene or even gene inactivation (deletion to one copy of PTEN gene) can contribute to tumorigenesis or promote the progression of BC⁽¹⁵⁻¹⁸⁾. In other words, PTEN inactivation leads to high concentrations and activity of phosphatidylinositol 3,4,5-trisphosphate (PIP3) (which is normally present in low concentrations in quiescent cells and increased by stimulation of growth factors).

This will lead to high levels of Akt (proto-oncogene) which has antiapoptotic activity by inactivating proapoptotic factor BCL2 associated agonist of cell death (BAD) protein and caspase-9⁽¹⁵⁾.

The average age of BC patients with PTEN gene deletion or signal reduction was 43.5 years, which is approximately 12 years younger than those with no deletion (55.63 years). This means that PTEN deletion tends to occur in younger BC patients, however there was no statistical significance for this relation. This result goes with the findings of other studies; Kazim et al. in 2019 and Anders et al. in 2008^(19,20).

There was significant relation between PTEN gene deletion or signal reduction and tumor size >2 cm (P value=0.0001). This relation between PTEN gene loss and larger tumor size was established by a previous study done in Iraqi by Al-hamadawi et al. in 2015⁽¹³⁾. Other studies; Li et al. in 2017, Beg et al. in 2005 and Zhang et al. in 2013 recognized the relation between PTEN deletion and larger tumor size^(10,11,21). When PTEN gene is deleted or inactivated, Akt (which is normally inhibited by PTEN gene) would be active and this promotes

cell cycle progression in cancer and leads to continuous cells division and larger tumor size. This increased tumor size can be attributed to the effect of Akt on glycogen synthase kinase 3 (GSK-3) and mTOR signaling pathway. Akt inhibits GSK-3, which is thought to have a role in promoting cell cycle progression in cancer cells. On the other hand, Akt activates mTOR signaling pathway which is important in ribosomal protein synthesis ⁽²²⁾.

Only 2 cases out of 8 (25%) with PTEN deletion showed a multicentric tumor and both of the cases were ILC. There was no statistical significance in relation between PTEN and multicentric tumor (P value=0.26). Unfortunately, there are no data regarding the relation between PTEN gene deletion status and breast tumor multicentricity.

In this study, 75% of patients with deleted PTEN gene were diagnosed with IDC of no special type (NOS) and the remaining 25% were diagnosed with ILC. There was no statistical significance between PTEN deletion and tumor histological type (P value=0.25). Same results were found in a study done by Lopez et al. (2020), in which BC patients with low PTEN expression were 80% IDC, 14.3% ILC and 5.7% for the other types of BC and there was no statistical significance between PTEN deletion status and BC pathological type ⁽²³⁾. Li et al. in 2017 found the same result in which there is no association between PTEN gene loss and BC histological type ⁽¹⁰⁾.

The breast tumors with deleted PTEN gene were divided equally between grade II and III (4 cases in each grade). This means that patients with deleted PTEN gene present with higher grade tumors (grade II and III), and there was a statistically significant difference between PTEN gene deletion and higher tumor grade (P value=0.013). This relation was demonstrated in many previous studies Lebok et al. (2015), Li et al. (2017), Al-hamadawi et al. (2015), and Golmohammadi et al. (2016) ^(9,10,13,24).

It has been demonstrated that PTEN has a role in chromosomal stability and DNA repair and is negatively associated with mitotic index. Loss of PTEN gene function in tumors leads to chromosomal instability, impaired DNA repair and higher mitosis rate which yields to a

higher-grade tumor ⁽²⁵⁾. In addition to that, PTEN gene loss leads to aberrant chromosomal segregation during mitosis which leads to erroneous chromosome inheritance ⁽²⁶⁾.

In the current study, majority of patients with deleted PTEN gene presented with pathological stage III (6 out of 8 (75%)) and the remaining 2 cases (25%) were diagnosed with stage II. This means that patients with deleted PTEN gene tend to present with more advanced tumor stage and there was a statistically significant difference between PTEN gene deletion and higher tumor stage (P value=0.012). This was stated in previous studies, which found PTEN deleted tumors was associated with higher tumor stage; Lebok et al. (2015), Li et al. (2017), Al-hamadawi et al. (2015), Golmohammadi et al. (2016) and Chang et al. (2005) ^(9,10,13,24,27).

PTEN gene deletion leads to phosphorylation of focal adhesion kinase (FAK) which in turn leads to integrin-mediated cell spread, migration and focal adhesion formation. Another mechanism by which PTEN gene has a role in metastasis is that PTEN gene deletion leads to loss or decrease of E-cadherin, which is crucial for tumor invasion and metastasis ⁽²⁸⁾.

There was no statistical significance between PTEN gene deletion or signal reduction and lymph nodes metastasis (P value=0.6). However, there was statistical significance between PTEN deletion or signal reduction and metastasis to more than 4 lymph nodes (P value=0.4). Many studies showed that PTEN gene deletion was associated with lymph nodes metastasis; Li et al. (2007), Al-hamadawi et al. (2015), Chang et al. (2005), Chung et al. (2004) and Izzo et al. (2021) ^(10,13,27,29,30). However, no data were found regarding the relation between PTEN gene deletion status and number of lymph node that BC would metastasize to. Loss of PTEN gene function can weaken intercellular adhesion and promote cancer cell invasion including invasion to lymph nodes ⁽³¹⁾.

In conclusion, PTEN gene deletion or signal reduction was detected in 26.67% of BC cases. This may reflect the possible role of PTEN gene in the development of BC. There was a significant correlation between PTEN gene

deletion or signal reduction and larger tumor size, high number of lymph nodes metastasis (more than 4 lymph nodes), higher grade and advanced stage. This may be related to the loss of PTEN gene normal function by deletion resulting in impaired control of cell growth, increased cellular proliferation, loss of differentiation and cellular adhesion with enhanced migration and local invasion of BC. However, there is no significant relation between PTEN gene deletion status and age, multicentricity, pathological type and lymph node metastasis (regardless the number of lymph nodes) in patients with BC.

Acknowledgement

The authors thanks Ass. Prof. Dr. Bassam Hamid, Dr. Ahmed Zuhair, Ass. lecturer Fahim Mohsin and Dr. Khalid Walid.

Author contribution

Dr. Al-Taie bought the kit, stained the slides with H&E stain and FISH probe and wrote the paper. Dr. Qasim supervised the work, examined and confirmed the diagnosis of the slides and reviewed the paper.

Conflict of interest

The authors declare no conflict of interest.

Funding

Self-funding.

References

- Obeyed DHH, Ibrahim DRH, Ali DKM, et al. Annual Report Iraqi Cancer Registry 2015. In: Obeyed DHH, Ibrahim DRH, Abbas DMM, et al (eds). Iraqi Cancer Registry: Ministry of Health\Environment\Iraqi Cancer Board; 2018.
- Annual Statistical Report. In: Health/Environment Mo, council Cr, editors. Ministry of Health/Environment Website 2019.
- GCO/IARC. Iraq Fact Sheets. Global Cancer Observatory: International Agency for Research on Cancer; 2018.
- Majumder PK, Sellers WR. Akt-regulated pathways in prostate cancer. *Oncogene*. 2005; 24(50): 7465-74. doi: 10.1038/sj.onc.1209096.
- Janku F, Yap TA, Meric-Bernstam F. Targeting the PI3K pathway in cancer: are we making headway? *Nat Rev Clin Oncol*. 2018; 15(5): 273-291. doi: 10.1038/nrclinonc.2018.28.
- Linke M, Fritsch SD, Sukhbaatar N, et al. mTORC1 and mTORC2 as regulators of cell metabolism in immunity. *FEBS Lett*. 2017; 591(19): 3089-3103. doi: 10.1002/1873-3468.12711.
- Matsumoto CS, Almeida LO, Guimarães DM, et al. PI3K-PTEN dysregulation leads to mTOR-driven upregulation of the core clock gene BMAL1 in normal and malignant epithelial cells. *Oncotarget*. 2016; 7(27): 42393-407. doi: 10.18632/oncotarget.9877.
- Kechagioglou P, Papi RM, Provatopoulou X, et al. Tumor suppressor PTEN in breast cancer: heterozygosity, mutations and protein expression. *Anticancer Res*. 2014; 34(3): 1387-400.
- Lebok P, Kopperschmidt V, Kluth M, et al. Partial PTEN deletion is linked to poor prognosis in breast cancer. *BMC Cancer*. 2015; 15: 963. doi: 10.1186/s12885-015-1770-3.
- Li S, Shen Y, Wang M, et al. Loss of PTEN expression in breast cancer: association with clinicopathological characteristics and prognosis. *Oncotarget*. 2017; 8(19): 32043-54. doi: 10.18632/oncotarget.16761.
- Beg S, Siraj AK, Prabhakaran S, et al. Loss of PTEN expression is associated with aggressive behavior and poor prognosis in Middle Eastern triple-negative breast cancer. *Breast Cancer Res Treat*. 2015; 151(3): 541-53. doi: 10.1007/s10549-015-3430-3.
- Ettl T, Baader K, Stiegler C, et al. Loss of PTEN is associated with elevated EGFR and HER2 expression and worse prognosis in salivary gland cancer. *Br J Cancer*. 2012; 106(4): 719-26. doi: 10.1038/bjc.2011.605.
- Al-hamadawi HA, Al-Janabi AA, Al-Kashwan TA, et al. Low expression of PTEN gene is an important trigger event for progression of breast carcinoma. *Al-Kufa Uni J Biol*. 2015; 7(3): 205-14.
- Bazzichetto C, Conciatori F, Pallocca M, et al. PTEN as a prognostic/predictive biomarker in cancer: An unfulfilled promise? *Cancers (Basel)*. 2019; 11(4): 435. doi: 10.3390/cancers11040435.
- Di Cristofano A, Pandolfi PP. The multiple roles of PTEN in tumor suppression. *Cell*. 2000; 100(4): 387-90. doi: 10.1016/s0092-8674(00)80674-1.
- Trotman LC, Niki M, Dotan ZA, et al. Pten dose dictates cancer progression in the prostate. *PLoS Biol*. 2003; 1(3): E59. doi: 10.1371/journal.pbio.0000059.
- Alimonti A, Carracedo A, Clohessy JG, et al. Subtle variations in Pten dose determine cancer susceptibility. *Nat Genet*. 2010; 42(5): 454-8. doi: 10.1038/ng.556.
- Kwabi-Addo B, Giri D, Schmidt K, et al. Haploinsufficiency of the Pten tumor suppressor gene promotes prostate cancer progression. *Proc Natl Acad Sci U S A*. 2001; 98(20): 11563-8. doi: 10.1073/pnas.201167798.
- Kazim Z, Wahabi K, Perwez A, et al. PTEN Genetic and Epigenetic alterations define distinct subgroups in North Indian breast cancer patients. *Asian Pac J Cancer Prev*. 2019; 20(1): 269-76. doi: 10.31557/APJCP.2019.20.1.269.

20. Anders CK, Hsu DS, Broadwater G, et al. Young age at diagnosis correlates with worse prognosis and defines a subset of breast cancers with shared patterns of gene expression. *J Clin Oncol.* 2008; 26(20): 3324-30. doi: 10.1200/JCO.2007.14.2471.
21. Zhang HY, Liang F, Jia ZL, et al. PTEN mutation, methylation and expression in breast cancer patients. *Oncol Lett.* 2013; 6(1): 161-8. doi: 10.3892/ol.2013.1331.
22. Mundi PS, Sachdev J, McCourt C, et al. AKT in cancer: new molecular insights and advances in drug development. *Br J Clin Pharmacol.* 2016; 82(4): 943-56. doi: 10.1111/bcp.13021.
23. Lopez G, Noale M, Corti C, et al. PTEN Expression as a complementary biomarker for mismatch repair testing in breast cancer. *Int J Mol Sci.* 2020; 21(4): 1461. doi: 10.3390/ijms21041461.
24. Golmohammadi R, Rakhshani MH, Moslem AR, et al. Prognostic role of PTEN gene expression and length of survival of breast cancer patients in the North East of Iran. *Asian Pac J Cancer Prev.* 2016; 17(S3): 305-9. doi: 10.7314/apjcp.2016.17.s3.305.
25. Ressel L, Millanta F, Caleri E, et al. Reduced PTEN protein expression and its prognostic implications in canine and feline mammary tumors. *Vet Pathol.* 2009; 46(5): 860-8. doi: 10.1354/vp.08-VP-0273-P-FL.
26. Sun Z, Lu J, Wu M, et al. Deficiency of PTEN leads to aberrant chromosome segregation through downregulation of MAD2. *Mol Med Rep.* 2019; 20(5): 4235-43. doi: 10.3892/mmr.2019.10668.
27. Chang SH, Lee SN, CHO MS, et al. Loss of PTEN Expression in Breast Cancers. *Korean J Pathol.* 2005; 39(4): 236-41.
28. Stewart AL, Mhashilkar AM, Yang XH, et al. PI3 kinase blockade by Ad-PTEN inhibits invasion and induces apoptosis in RGP and metastatic melanoma cells. *Mol Med.* 2002; 8(8): 451-61.
29. Chung MJ, Jung SH, Lee BJ, et al. Inactivation of the PTEN gene protein product is associated with the invasiveness and metastasis, but not angiogenesis, of breast cancer. *Pathol Int.* 2004; 54(1): 10-5. doi: 10.1111/j.1440-1827.2004.01576.x.
30. Izzo L, Messineo D, DI Cello P, et al. Correlation between onco-suppressors PTEN and NM23 and clinical outcome in patients with T1 breast cancer. *In Vivo.* 2021; 35(1): 169-74. doi: 10.21873/invivo.12245.
31. Li K, Li GD, Sun LY, et al. PTEN and SHIP: Impact on lymphatic metastasis in breast cancer. *J Cancer Res Ther.* 2018; 14(Supplement): S937-41. doi: 10.4103/0973-1482.193894.

Correspondence to Dr. Mohammed R.F. Al-Taie

E-mail: mohammed.altae13@gmail.com

Received Apr. 1st 2021

Accepted May 10th 2021