

Evaluation use of Ultrasound guided Transverses Abdominal Plane Block and Paracetamol for Post-operative Analgesia in Appendectomy Patients

Background: A lot of pain relieve techniques were use postoperatively the transverses abdominal plan block is new regional anesthesia technique and paracetamol infusion one of these.

Objectives: the aim of this study to evaluate the effectiveness of the two methods in patients undergoes appendectomy.

Methods: Non- randomized clinical trial, started in the 1stfeb 2016 to 1st Feb. 2017 at Al-Jarah hospital Iraq – Baghdad, A 180 patients ASA I, undergone appendectomy. Age matched, 80 Patients were on ultrasound guided transverses abdominis plane block and 100 toke paracetamol .after wound closure 20 ml of 0.5% bupivacaine was infiltrated in to transverses abdominis neuro facial plan by posterior approach. 1000 mg of paracetamol (parol) were administered after induction of anesthesia as infusion in 20 min and pain score was assessed in postoperative period in 0 hr, 1 hr, 2hr, 3hr, 4hr by numerical rating scale (NRS) and visual analogue scale (VAS).

Results: Transverses abdominal plane block (TAP) under ultrasound guidance had significantly lower postoperative pain score according NRS and VAS in comparison to paracetamol (P-value less than 0.001) at 4hr post-operative after appendectomy.

Conclusion: Ultrasound-guided transverses abdominis plane block was easy, safe, reliable and effective analgesic postoperative appendectomy than paracetamol.

Keywords: Transverses abdominal plan block.

Introduction:

Controlled acute pain during the postoperative setting after abdominal surgery can be detrimental to the patient. A substantial component of the pain experienced by patients after abdominal surgery is derived from the abdominal wall incision⁽¹⁾. The abdominal wall consists of three muscle layers, and their associated fascial sheaths. The central abdominal wall also includes the rectus abdominis muscles and its associated fascial sheath. This muscular wall is innervated by nerve afferents that course through the transversus abdominis neuro-fascial plane⁽²⁾.

INDICATION FOR TRANSVERS ABDOMINAL PLAN (TAP) BLOCK

The TAP block is a simple procedure that can be used as an adjunct for postoperative pain control in abdominal, gynecologic⁽³⁾

Urologic surgery involving the T6 to L1 distribution. Surgical procedures investigated by randomized clinical trials include large bowel resection, caesarean delivery, abdominal hysterectomy, open appendectomy, and laparoscopic cholecystectomy⁽⁴⁾.

Contraindications & Complication:

Very few contraindications exist to performing a TAP block. Absolute contraindications include infection at the site of injection, patient refusal or inability to cooperate, & allergy to local anesthetics.⁽⁴⁾

Complication:

The TAP block is a relatively safe technique with only a few case reports of significant complications includes: Failure, intraperitoneal injection, local anesthetic toxicity, hepatic injury & bowel injury⁽⁵⁾.

PARACETAMOL (ACETAMINOPHEN)

Also known as acetaminophen is a medication used to treat pain and fever.⁽⁶⁾

MECHANISM OF ACTION

To date, the mechanism of action of paracetamol is not completely understood. The main mechanism proposed is the inhibition of cyclooxygenase (COX), and recent findings suggest that it is highly selective for COX-2.⁽⁷⁾

AIM OF THE STUDY

Compare the analgesic effect between Transverses Abdominis Plan (TAP) and paracetamol for post-operative appendectomy cases.

Patients and methods

Settings

Non randomized clinical trial study was conducted at AL- Jarah hospital inBaghdad – Iraq between the period 1st feb 2016 and 1st feb2017.

Sample

The study was approved by the scientific committee. All participants provided a written informed consent. The study included 180 patients,all patient given same anesthesia procedure and undergone appendectomy.

They were between the ages 18-40 year Patient's. The patients with history of allergy to local anesthetics. infection at the site of injection , bleeding tendency , pregnancy ,liver disease and patient refusal were excluded, demographic data including age and weight were recorded in already prepared data collecting sheet .

Procedures

All patients received a standard general anesthetic. Anesthesia was induced by rapid sequence induction. Using sleeping dose thiopental 3-5 mg/kg, succinyl choline 1 mg/ kg.

atracurium 0.6 mg/kg, fentanyl 1 mcg/kg, endotracheal intubation have been done. anesthesia was maintained with oxygen and isoflurane 1.2% , patient were ex tubeted after reversal with neostigmine and atropine .standard monitoring including electrocardiograph ,non-invasive blood pressure (NIBP) ,pulse oximeter and end –tidal Carbone dioxide monitoring , was done throughout

the surgery and early post –operative period ,and patients were placed in supine position

The measurement

During preoperative visit, patients received a visual analogue score (VAS) for pain , The assessments ranged from 0 (no pain) to 10 (unbearable pain). The use for VAS in for better assessment and analysis.

And using a numerical rating scale (NRS) from (0-10) .

As at specific times (0 hr, 1 hr, 2hr, 3 hr and 4hr).

The reading were recorded in data collecting sheet NRS evaluation regards as following (0: no pain , 1-4 : mild pain , 5-7 :moderate pain , 8-10: sever pain) and reading more than 4 used as cut .and describe it as follows :

No pain	Mild pain	Moderate pain	Severe pain
0	1-4	5-7	8-10

MAP= mean arterial blood presser

The method 1

Performing ultrasound guide block requirements: (during recovery period)

- Ultrasound machine with high frequency probe (12 l).
- Ultrasound probe cover.
- Antiseptic for skin disinfection.
- Sterile ultrasound gel.
- 20 ml syringe.
- One vial of 0.5 % bupivacaine (Bucaine 0.5%, 5mg /ml).
- One touhy needles (Epilog18G, 90 mm).
- One surgical gloves.
- Surgical gowns.

38 mm liner array US probe (13-6 MHz) was positioned in the mid – axillary line in axial plane half away between iliac crest and costal margin .The needle is introduced in plane of the ultrasound probe directly under the probe and advanced until it reaches the plane between the internal oblique and transverses abdominis muscle with tip in the mid axillary line. 2 ml of saline is injected to confirm

correct needle position after which 20ml of local anesthetic solution is injected with incremental aspiration and injection .the transverses abdominis plane is visualized

expanding with the injection.

method 2

1000 mg of paracetamol (Par Wave) were administered after induction of anesthesia infusion in 20 min.

Data collection:

After completion of the surgical procedure, and emergence from anesthesia, then the post-operative pain was recorded according (VAS) and (NRS). We ask our patients to rate the average pain over 0 hr, 1 hr, 2 hr, 3 hr, 4 hr. with vital singe and vomiting was recording. Tramadol intramuscularly was used for analgesic when needed.

DATA COLLECTION PAPER:

- Case number:
- Patient name:
- Age (year):
- Weight (kg):

Method 2 TAPS method 2- PARACETAMOL PAIN SCORE

Time(hr)	0 hr	1 hr	2h	3hr	4hr
Method 1					
Method 2					

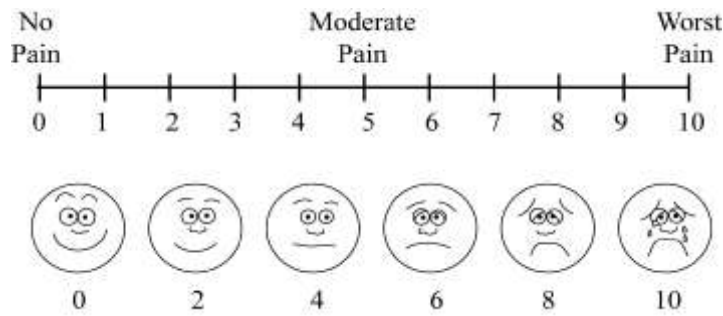
NRS

NO PAIN	MILD PAIN	MODERATE PAIN	SEVER PAIN
0	1-4	5-7	8-10

2-VITAL SINGE AND VOMITING

Time(hr)	0 hr	1 hr	2 hr	3 hr	4 hr
MAP					
PR					

VAS



The researcher changes the score to numerical score in order to use the mean and standard deviation in statistics.

Statistical analysis

Was performed using MINITAB software for windows versions 22 We use excel Microsoft software for input data and making of graphs. Probability value of less than 0.001 was considered to be statistically significant.

Results: Data are expressed as mean \pm SD. analysis of pain score and P R , MAP the two independent groups.

In table (1) had been shown , age and weight that there were no significant statistical difference between two study group.

Table (1) preoperative characteristic (mean \pm SD)

Charecharacteristic	Method 1	Method 2	P-value
Number(patient)	80	100
Weight(kg)	58.3 \pm 8.7	60.2 \pm 9.5	0.31
Age (year)	25.6 \pm 6.3	23.5 \pm 6.8	0.10

**the use of mean and standard deviation to overcome the differences in study population*

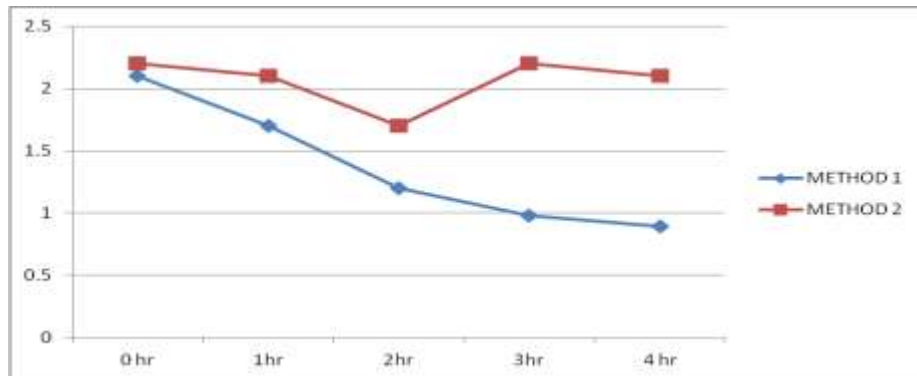


Figure: 1 relationship between pain scores of tow study method

**the researcher use graph not table for better visualization of the measurements during the study period .all time based measurement (trend) it's better to used trend graph . (P-value less 0.001)*

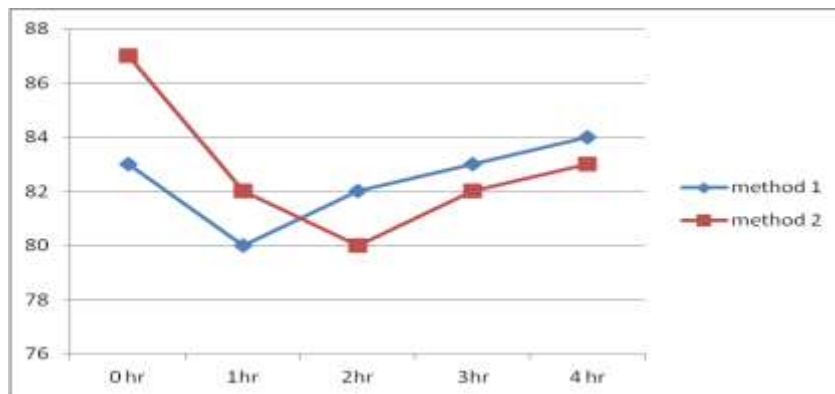


Figure: 2 show there was non-significant statistical difference in pulse rate between the types of study. (P-value above 0.05)

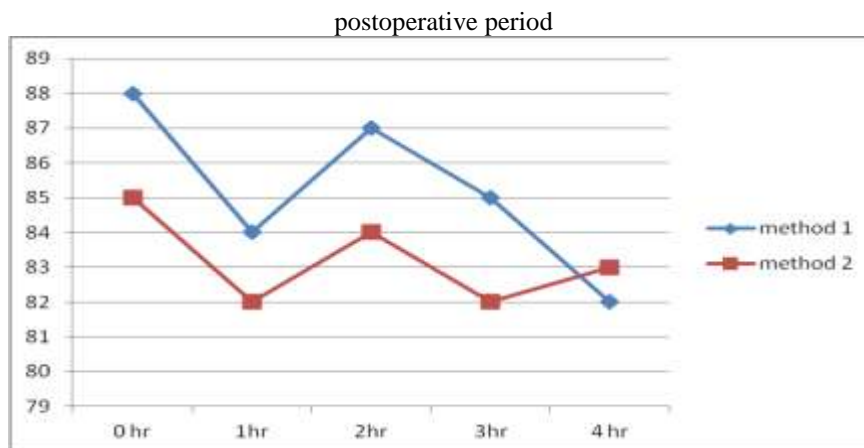


Figure: 3 show no significant statistical relationship in MAP between the study groups in 1hr and 2hr in (*P-value above 0.05*)

DISCUSSION:

Postoperative pain typically is considered a normal part of the recovery process following most forms of surgery. Such pain often can be controlled using typical measures such as pre-operative, non-steroidal, anti-inflammatory medications; local anesthetics injected into the operative wound prior to suturing; postoperative analgesics; and even intra-operative or post-operative injection of epidural analgesics, for some types of surgeries⁽⁸⁾.

All abdominal surgeries followed by postoperative pain appendectomy, one of this, because of multiple pre and postoperative nature of the problem, and surgery itself.

In this study groups in table (1) when matched in their age and Weight (study inclusion criteria) hoping for analysis the factors under study and trying to explore the differences between the two methods already used.

The finding from table (2) shows that there were some clinical differences in assessment of pain with statistical significant value. During the first 4 hours (0 hour, 1 hours, 2 hours, 3 hours, 4hours) in patients that received method 1 TAP block in compare with paracetamol method 2.

In article published in Egyptian journal of anesthesia 2015 Bhanulakshmi et al. investigated in a comparative study between ultrasound Guided transverses abdominals plane (TAP) block versus Intravenous diclofenac for post-operative analgesia in elective LSCS. That ultrasound guided TAP block can be performed easily and safely and more effective in lower abdominal surgeries for post-operative analgesia. And significantly reduced in requirement of opioids consumption and also decrease in pain scores in patients who received TAP block⁽⁹⁾.

Manze yu suggested TAP have the upper hand to block is comparable to LAI for short-term analgesia; it could also provide better long-lasting analgesia

especially at 24 h after surgery. Current evidence is insufficient to conclude that TAP block could reduce the requirements for postoperative morphine and associated side effects as compared to local anesthesia injection ,Further more researches are needed such RCTs (randomized control trails) should be performed to figure out the different benefit of these two methods.⁽¹⁰⁾.

Yu et al. were describing in their study compared transverses abdominals plane block (TAP) versus local anesthetic wound infiltration (LAI) in lower abdominal surgery. They found that TAP block is comparable to LAI for short-term analgesia; it could also provide better long-lasting analgesia especially at 24 h after surgery⁽¹¹⁾.

The transversus abdominis plane block is a novel technique for post operative analgesia especially in initial postoperative period. It has got potential to substitute the use of intravenous opioid analgesics and hence to avoid its complications. It has been proved to cater significant analgesic effect especially below T10 up to L1 level; hence, it is perfectly suited for use after lower abdominal and gynecological surgeries. Manjarin concluded⁽¹²⁾

in graph (2) (3) show there were no differences and non –significant statistical in pulse rate between both method and MAP in 1 hours and 2 hours MAP lowering in paracetamol in compare with TAP block.

Conclusion

Ultrasound guided TAP block is found to be safe and an effective modality of providing postoperative analgesia for appendectomy case with significantly less post-operative Compared with paracetamol.

References

1. Wall PD, Melzack R. Pain measurements in persons in pain. In: Wall PD, Melzack R, eds. Textbook of pain. 6th ed. Edinburgh, UK: Churchill Livingstone, 2010:409–426.

2. Netter FH. Back and spinal cord. In: Netter FH, ed. Atlas of human anatomy summit. New Jersey, USA: The Ciba-Geigy Corporation, 2009:145–55.
3. Kawahara R, the analgesia efficacy of ultrasound – guided transverse abdominis plan block ; a randomized controlled trail
*J.anaeth.clin.phamc.*2015 jan3191067-71.
4. Ripolles J ,analgesia efficacy of TAP braz
*J.aneath.*2015 jul .65(4) 255-80.
5. Milone M, Di Minno MN, Musella M, et al. “Outpatient inguinal hernia repair under local anesthesia: feasibility and efficacy of ultrasound-guided transverses abdominis plan block” [published online November 16, 2012]. *Hernia.* 2013; 17(6): 749- 55.
6. The American Society of Health-System Pharmacists. Retrieved 16 September 2016.
7. Hinz, B.; Cheremina, O.; Brune, K. (2008). "Acetaminophen (paracetamol) is a selective cyclooxygenase-2 inhibitor in man.". *The FASEB Journal.* 22 (2): 383–390. doi:10.1096/fj.07-8506com. PMID 17884974.
8. Coding for Postoperative Pain in ICD-10-CM
<https://www.icd10monitor.com/coding-for-postoperative-pain-in-icd-10-cm> cited at 18-2-2017.
9. Bhanulak shim M, Chander DS, Raj GV, “Comparative study between ultrasound guided transversus abdominis plan (TAP) block vs. intravenous diclofenac for postoperative analgesia in elective LSCS”. *J Evidence based med Hlthcare* 2015; 2 (37):5911-8.10.10.Nanze Yu,Xiao Long,Jorge R Lujan-ernandez,Julien Succar,Xin Xin⁴ and
10. Xiaojun Wang Transversus abdominis-plane block versus local anesthetic wound infiltration in lower abdominal surgery: a systematic review and meta-analysis of randomized controlled trials
*BMC Anesthesiology*201414:121
11. Qingduo guimrui li,lixian wang ,dong zang , Transversus abdominis plane block versus local anaesthetic wound infiltration for postoperative analgesia: A systematic review and meta-analysis
Int J Clin Exp Med. 2015; 8(10): 17343–17352.
12. Manjaree m. mshashi p., Transversus abdominis plane block: The new horizon for postoperative analgesia following abdominal surgery
Egyptian Journal of Anaesthesia Volume 32, Issue 2, April 2016, Pages 243–247
* MoH/ Medical City Teaching Hospital