

## Effect of Topical Flavonoid Fraction from *Artemisia annua* in Comparison with Tacrolimus on Induced Atopic Dermatitis in Mice

Mohammed F. Hameed<sup>1</sup> MSc, Ahmed R. Abu-Raghif<sup>2</sup> PhD, Enas J. Kadhim<sup>2</sup> PhD

<sup>1</sup>Dept. of Pharmacology and Toxicology, College of Pharmacy, Al-Nahrain University, <sup>2</sup>Dept. of Pharmacology and Therapeutics, College of Medicine, Al-Nahrain University, Baghdad, Iraq, <sup>3</sup>Dept. of Pharmacognosy, College of Medicine, Baghdad University, Baghdad, Iraq

### Abstract

- Background** Atopic dermatitis is a chronic inflammation of skin disease that is characterized by recurrent acute pruritus and dry skin. Mostly, atopic dermatitis is predominant in young children. The problems of increasing prevalence and high impact of disease on quality of patients and family's life, necessities identifying many atopic dermatitis prevention planes.
- Objective** To determine the effect of *Artemisia annua* flavonoids fraction in comparison with tacrolimus in atopic dermatitis like mice model.
- Methods** This study is a prospective, randomized, placebo and controlled animal designed. Thirty-two male Albino mice that six weeks age included in this study. The mice were randomly divided into four groups. Group I without treatment (Healthy). Group II only inducer, phthalic anhydride used. Groups II, III, and IV subjected to phthalic anhydride solution, which was applied on the dorsum of the back skin at 9 A.M. three times a week for four weeks. After three hours of phthalic anhydride application, treatment is used for group III (Tacrolimus 0.03% ointment), and group IV (flavonoids fraction 1.2 mg/kg ointment) topically once daily at 12 P.M. for three times a week for four weeks. Serum IgE and immunohistochemistry of skin tissue IL-4 score, and IL-13 score were measured.
- Results** High significant decrease in immunohistochemistry of skin tissue IL-4, and IL-13 in flavonoid fraction group were found.
- Conclusion** The flavonoid fraction has an effect on the skin immunohistochemistry parameters and probably on atopic dermatitis like mice model.
- Keywords** Atopic dermatitis, *Artemisia annua*, flavonoids
- Citation** Hameed MF, Abu-Raghif AR, Kadhim EJ. Effect of topical flavonoid fraction from *Artemisia annua* in comparison with tacrolimus on induced atopic dermatitis in mice. *Iraqi JMS*. 2019; 17(3&4): 231-237. doi: 10.22578/IJMS.17.3&4.10

**List of abbreviations:** A.M. = Before noon, AD = Atopic dermatitis, Ig = Immunoglobulin, IHC = Immunohistochemistry, IL = Interleukin, P.M. = After noon, Th = T helper, FLG = Filaggrin, TSLP = Thymic stromal lymphopoietin

### Introduction

Atopic dermatitis (AD) is a chronic inflammation of skin disease that is characterized by recurrent acute pruritus, eczematous rash and dry skin. Mostly,

AD is predominant in young children especially in those children with a genetic tendency to atopic march diseases<sup>(1)</sup>.

The problems of increasing prevalence and high impact of disease on quality of patients and family's life, necessities identifying many AD preventions planes. The avoidance of allergy is not beneficial with no emerging of regular approach<sup>(2)</sup>.

There is an evidence of psychological and physical trouble associated with AD. AD is characterized by erythema, skin xerosis, lichenification, and exudative topical damage. The most difficult presentation to control is pruritus which contributes effectively to disease worry. AD has been found to increase the probability of depression and anxiety and effect life quality<sup>(3,4)</sup>.

A probable effect of different ratios of genetic and non-inherited environment factors may be found. Early age onset AD in patients expected more liable to genetic effect, while in young babyhood and adult onset AD patients, the progress of the illness may be associated with more causes of environmental factors. In spite of that, few associations between filaggrin (FLG) mutations loss of function and the onset of AD in studies of early babyhood have been identified<sup>(5)</sup>.

The pathophysiology of AD is complex and involves genetic problems, immune abnormalities, skin barrier damage, the microbiome, and environmental triggers. Increased expression of the cytokine related to T helper (Th) 2 pathway occurs in AD, with IL (Interleukin)-4 and IL-13 are the major players in this disease<sup>(6)</sup>. The Th2 cytokines production can start activation of eosinophils, eosinophil inflow, and deposition of eosinophil substances, such as major basic protein in skin lesion<sup>(7)</sup>. In addition to that, cytokines of Th2 upregulate high affinity receptors of immunoglobulin (Ig) E on antigen presenting cells, example Langerhans cells, and more encourage synthesis of IgE antibodies. IgE-attached Langerhans cells in the existence of activated keratinocytes that secrete IL-25, TSLP, and IL-33, are highly effective crossing to regional lymph nodes then presenting the allergenic substance to naïve T cells and start a Th2 response<sup>(8)</sup>.

Treatment topically with glucocorticoids or calcineurin inhibitors is the main therapy for the management of AD, and the use of systemic anti-inflammatory use of glucocorticosteroids for short term,

cyclosporine use in adults and azathioprine used in some severe cases of AD<sup>(9)</sup>. However, problems with corticosteroid in long term use can cause side effects such as weak immune system, dependency, and skin thinning with darkening<sup>(10)</sup>.

Therefore, a safe and effective original AD treatment therapy is needed to establish better outcome with a least side effect. *Artemisia annua* used because of its various chemistry and biology effect of the constituents, and the national source of the plant material in Iraq. In the present study probable useful therapeutic effects of *Artemisia annua* flavonoids fraction, will be evaluated in AD as well as investigating possible difference in serum IgE, immunohistochemistry (IHC) of IL-4, and IL-13 in a mice model of AD and healthy groups.

## Methods

This study is a prospective, randomized, placebo and controlled animal designed. The study was done in the Department of Pharmacology in College of Medicine, Al-Nahrain University. Thirty-two male Albino mice that are six weeks age included in this study. The protocols for the animal experiment used in this study were carefully reviewed for ethical and scientific care procedures and approved by Institutional Review Board (IRB); Approval date 4/2/2018.

The mice were randomly divided into four groups (each group eight). Group I without treatment (Healthy). Group II only inducer, Phthalic Anhydride (Prepared by dissolving phthalic anhydride in 4:1 of freshly mixed acetone and olive oil)<sup>(11)</sup> given. Groups II, III, and IV subjected to 100 microliters of 5% phthalic anhydride solution which was applied on the dorsum of the back skin at 9 A.M. three times a week for four weeks to induce a state of that resemble atopic dermatitis. After three hours of phthalic anhydride application, treatment is used for group III (Tacrolimus 0.03% ointment)<sup>(12)</sup>, and group IV (flavonoids fraction 1.2mg/kg ointment) topically once daily at 12 P.M. for three times a week for four weeks). Flavonoids

fraction dose is calculated according to fraction representation percent in the plant <sup>(13)</sup>.

The plant *Artemisia annua* is collected from north of Iraq, dried and saved in AL Jadria Herbal Store according to the document from University of Baghdad, College of Science, Department of Biology Approval Number 8 in 12-4-2017. Five hundred grams of shad dried *Artemisia annua* leaves coarse powder were macerated in hexane for 24 hours and then dried at room temperature. The defatted plant materials were extracted with ethanol 80% in soxhlet apparatus. The ethanolic extract is evaporated using rotary evaporator at temperature not exceeding 40 °C. This Crude fraction was acidified with the addition of hydrochloric acid (5%) to reach pH 2 and then equal volume of ethyl acetate is added to get two separated layers. The ethyl acetate layer was evaporated to dryness using rotary evaporator under reduced pressure and then basified with 300ml of sodium Hydroxide 5% to reach pH 10 and extracted with chloroform in the separator funnel to get two separated layers. The aqueous basic layer was separated, evaporated to dryness and then acidified with hydrochloric acid 5% to reach pH 2 and finally extracted with ethyl acetate to get flavonoids fraction <sup>(14)</sup>.

Immunoglobulin E measured quantitatively by the enzyme-linked immunosorbent assay (ELISA) (Using mice serum IgE kit, catalog number: CSB-E07983m, Cusabio-China). After incubating the tested serum in an antigen-coated polystyrene plat or tube, enzyme specifically labeled anti-immunoglobulin is then added and this enzyme then remaining in the plate or tube after washing gives a measure to

the quantity of specifically related antibody in the serum <sup>(15)</sup>.

IHC study is done (Using IHC kit of IL-4 and IL-13 catalog number: Orb318722 and Orb10895 respectively, Biorbyt-USA) to determine IL-4 and IL-13 that present in the skin tissue lesion of mice, an IHC technique was initially standardized at the IHC Laboratory of the Department of Microbiology with the aid of consultation center in Department of Pathology, College of Medicine, Al-Nahrain University. The fundamental principle is the demonstration of antigens inside tissue sections by method of use specific antibodies. The immunoglobulin target molecule has special binding sites for each antigen and for other antibodies. Antigen-antibody attachment binding is measured with a colored histochemical change visible by fluorescent or light microscopy <sup>(16)</sup>.

Statistical analysis was done by analyzing data using computer facilities of Statistical Package for Social Sciences (SPSS) version 25 and tests of mean, standard deviation, and independent t-test were done.

## Results

It was found a high significant increase (P value  $\leq 0.001$ ) in serum IgE, IHC of IL-4, and IL-13 in AD induced non-treated group when compared to healthy group. Table (1), Figure (1), and Figure (2). When AD induced non-treated group compared with Tacrolimus group, a high significant decrease in serum IgE, IHC of IL-4, and IL-13 was found (Table 2). While when compared with flavonoid fraction group, a significant decrease in serum IgE and a high significant decrease in IHC of IL-4, and IL-13 (Table 3).

**Table 1. Comparison between healthy group and atopic dermatitis induced non-treated group**

Parameter	Healthy mean $\pm$ SD	Atopic dermatitis mean $\pm$ SD	p value
Serum IgE level	2.26 $\pm$ 3.06	22.88 $\pm$ 13.95	<0.001**
IHC IL-4 score	1.0 $\pm$ 0.0	4.0 $\pm$ 0.1	<0.001**
IHC IL-13 score	0.0 $\pm$ 0.0	4.0 $\pm$ 0.0	<0.001**

\*\* Denote high significant difference at P value  $\leq 0.001$

**Table 2. Comparison between atopic dermatitis induced non-treated group and tacrolimus group**

Parameter	Atopic dermatitis mean±SD	Tacrolimus mean±SD	p value
Serum IgE level	22.88±13.95	2.67±4.78	0.001**
IHC IL-4 score	4.0±0.1	1.5±0.55	<0.001**
IHC IL-13 score	4.0±0.0	1.0±0.0	<0.001**

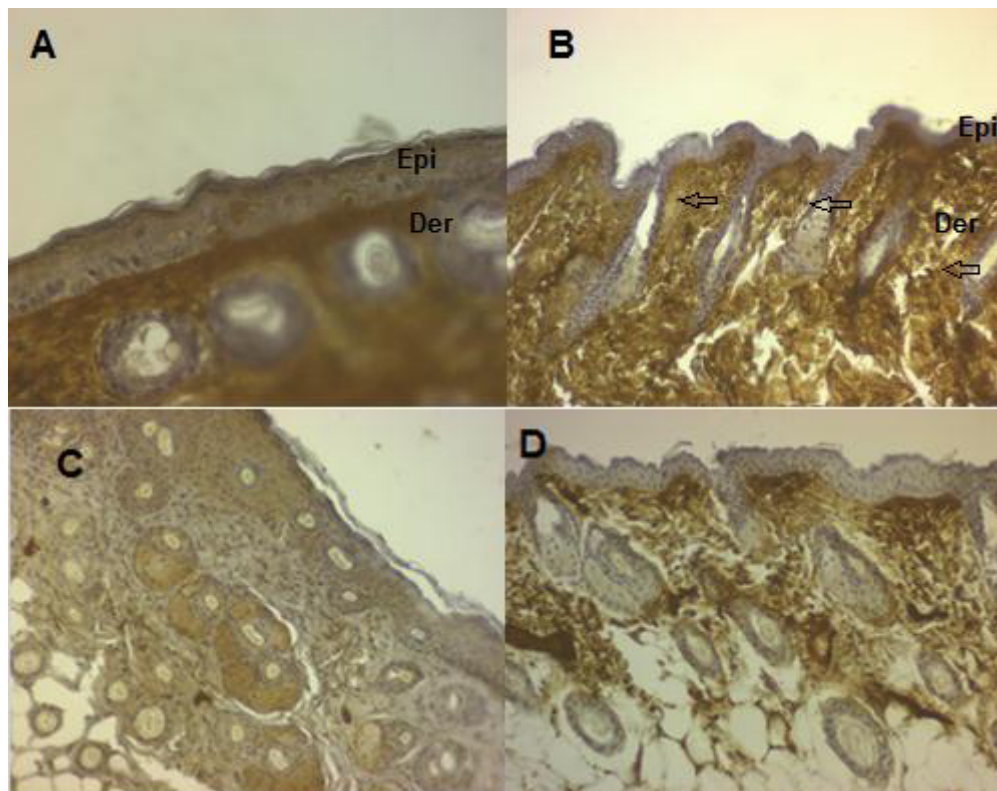
\*\* Denote high significant difference at P value ≤ 0.001

**Table 3. Comparison between atopic dermatitis induced non-treated group and flavonoid fraction group**

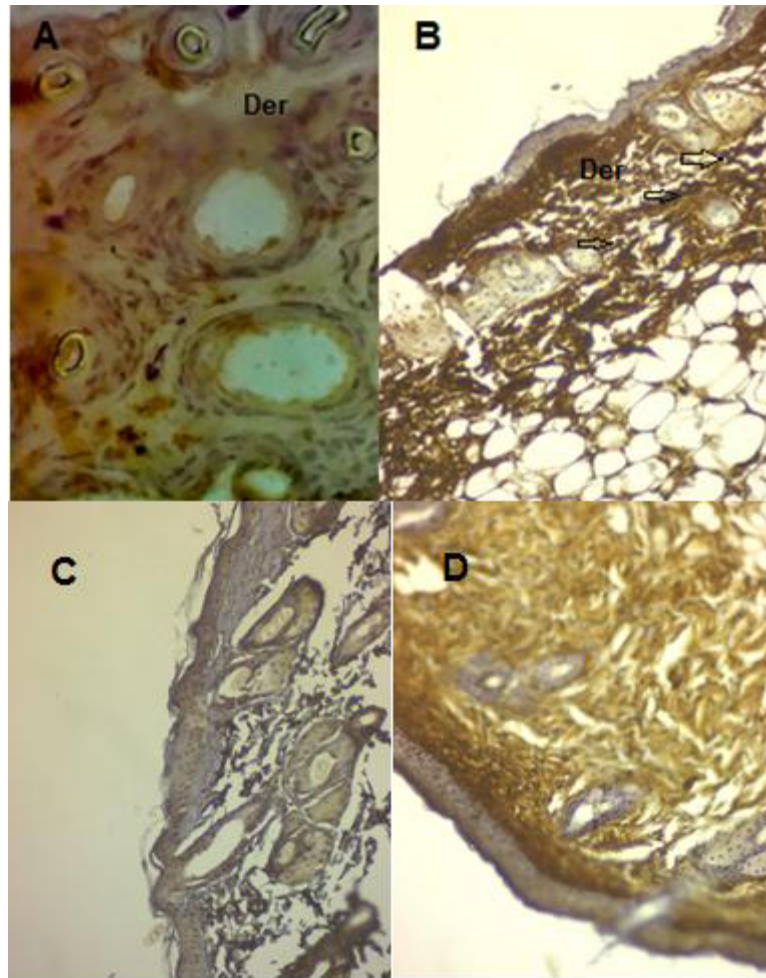
Parameter	Atopic dermatitis mean±SD	Flavonoid fraction mean±SD	p value
Serum IgE level	22.88±13.95	4.36±6.86	0.004*
IL-4 score	4.0±0.1	2.5±0.55	<0.001**
IL-13 score	4.0±0.0	3.0±0.0	<0.001**

\* Denote significant difference at P value ≤ 0.05

\*\* Denote high significant difference at P value ≤ 0.001



**Figure 1. Immunohistochemistry of IL-4 score of healthy group (A) (40x) and Atopic dermatitis Induced non-treated group (B) (20x), Tacrolimus group (C)(20x), and Flavonoid fraction group (D) (20x) showing IL-4 positive reactions (Arrow indicates dark brown)**



**Figure 2. Immunohistochemistry of IL-13 score of healthy group (A) (40x), Atopic dermatitis Induced non-treated group (B) (20x), Tacrolimus group (C)(20x), and flavonoid fraction group (D)(20x) showing IL-13 positive reactions (Arrow indicates dark brown)**

### Discussion

High significant increase in serum IgE was recorded in AD group when compared to healthy group. This result was comparable with a study showed that repeated skin application of phthalic anhydride solution lead to a significant increase in serum IgE levels in the induced non-treated group <sup>(17)</sup>, and it is clearly also show that the total IgE was higher in pediatric AD patients <sup>(18)</sup>. High significant increase were shown in IHC of IL-4 in the skin of AD group, which is the same result stated that the skin lesions show significant increased levels of IL-4 in mice model skin lesion of AD <sup>(19)</sup>. In the epidermis of transgenic mouse with overexpressing IL-4, the animal develop all the

specific symptoms of AD including pruritus, skin bacterial infection, increased skin inflammatory cells, and high IgE and IgG1 <sup>(20)</sup>. High significant increase was shown in IHC of IL-13 in the skin tissue of the mice of AD group. This is identical with the study that noted high significant elevation in IL-13 in the stratum corium in atopic dermatitis group when compared with healthy normal group <sup>(21)</sup>. High significant decrease in serum IgE was found in this study in tacrolimus treatment group, which is similar to the result of a study that showed tacrolimus significantly suppressed the increased serum IgE concentration <sup>(22)</sup>. Tacrolimus cause immunosuppression through decreasing

responses of T lymphocytes to foreign allergic antigens in addition to suppressing IL-2 cytokine transcription, which is the main pathway. It controls transcription of several genes that code for many inflammatory mediators like IL-2, tissue necrosis factor-alpha, granulocyte-macrophage colony-stimulating factor, interferon-gamma as well as other interleukins, which are required for immune responses development. Tacrolimus also suppress histamine release from mast cells<sup>(23)</sup>. It was found that high significant decrease in tissue IL-4 and in IL-13 in tacrolimus treated group when compared with AD induced non-treated group. Through signal transducer, the cytokines affect functions of epidermal barrier and transcription 6 activator. As an example, IL-4 and IL-13 decrease the expression of filaggrin, involucrin, loricrin, and desmoglein 3 in keratinocytes<sup>(24)</sup>. Moreover, IL-4 and IL-13 increase the function and expression of a kallikrein 7, chymotrypsin serine protease in epidermal keratinocytes. This leads to high protease activity, and finally epidermal barrier dysfunction<sup>(25)</sup>.

It has been found that after 4 weeks of treatment with topical flavonoid fraction, significant decrease in serum IgE when compared with AD induced non-treated group. The anti-inflammatory effect of flavonoid fraction may be due to its suppression of mitogen activated protein kinase signaling pathway and nuclear factor-kappa B<sup>(26)</sup>. Finally, it was found that high significant decrease in IHC of IL-4, and IL-13 in flavonoid fraction group. It is not sure obviously that flavonoids anti-inflammatory effects due to either their modulation of a single pathway. It is suspected that flavonoids hit on an attached network of transcription factors and kinases that can coordinately exert a defend response to the pathological stress that exposed by chronic inflammation<sup>(27)</sup>.

This study concluded that the flavonoid fraction has an effect on the skin IHC scores of IL-4 and IL-13 in mice and probably is an option in the treatment of atopic dermatitis in the future.

### **Acknowledgement**

The authors would like to thank the members of Medical Research Center, Department of Microbiology, Department of Pathology in College of Medicine, Al-Nahrain University for their help and cooperation.

### **Author contribution**

Hameed: collection and analysis of data, interpretation and discussion. Dr. Abu-Raghif: research reviewer and Dr. Kadhim: identification plant extract procedure.

### **Conflict of interest**

No conflict of interest.

### **Funding**

Self-funding.

### **References**

1. Mastrorilli C, Caffarelli C, Hoffmann-Sommergruber K. Food allergy and atopic dermatitis: Prediction, progression, and prevention. *Pediatr Allergy Immunol.* 2017; 28(8): 831-840. doi: 10.1111/pai.12831.
2. Foisy M, Boyle RJ, Chalmers JR, et al. Overview of Reviews The prevention of eczema in infants and children: An overview of Cochrane and non-Cochrane reviews. *Evid Based Child Health.* 2011; 6(5): 1322-39. doi: 10.1002/ebch.827.
3. Chiesa Fuxench ZC, Block JK, Boguniewicz M, et al. Atopic dermatitis in America study: A cross-sectional study examining the prevalence and disease burden of atopic dermatitis in the US adult population. *J Invest Dermatol.* 2019; 139(3): 583-90. doi: 10.1016/j.jid.2018.08.028.
4. Patel KR, Immaneni S, Singam V, et al. Association between atopic dermatitis, depression, and suicidal ideation: A systematic review and meta-analysis. *J Am Acad Dermatol.* 2019; 80(2): 402-10. doi: 10.1016/j.jaad.2018.08.063.
5. Henderson J, Northstone K, Lee SP, et al. The burden of disease associated with filaggrin mutations: A population-based, longitudinal birth cohort study. *J Allergy Clin Immunol.* 2008; 121(4): 872-7.e9. doi: 10.1016/j.jaci.2008.01.026.
6. Brunner PM, Guttman-Yassky E, Leung DY. The immunology of atopic dermatitis and its reversibility with broad-spectrum and targeted therapies. *J Allergy Clin Immunol.* 2017; 139(4S): S65-S76. doi: 10.1016/j.jaci.2017.01.011.
7. Leiferman KM, Ackerman SJ, Sampson HA, et al. Dermal deposition of eosinophil-granule major basic protein in atopic dermatitis. Comparison with onchocerciasis. *N Engl J Med.* 1985; 313(5): 282-5. doi: 10.1056/NEJM198508013130502.

8. Nygaard U, Hvid M, Johansen C, et al. TSLP, IL-31, IL-33 and sST2 are new biomarkers in endophenotypic profiling of adult and childhood atopic dermatitis. *J Eur Acad Dermatol Venereol.* 2016; 30(11): 1930-38. doi: 10.1111/jdv.13679.
9. Werfel T, Schwerk N, Hansen G, et al. The diagnosis and graded therapy of atopic dermatitis. *Dtsch Arztebl Int.* 2014 Jul 21; 111(29-30): 509-20, i. doi: 10.3238/arztebl.2014.0509.
10. Hajar T, Gontijo JRV, Hanifin JM. New and developing therapies for atopic dermatitis. *An Bras Dermatol.* 2018; 93(1): 104-7. doi: 10.1590/abd1806-4841.20187682.
11. Lee YJ, Kim JE, Kwak MH, et al. Quantitative evaluation of the therapeutic effect of fermented soybean products containing a high concentration of GABA on phthalic anhydride-induced atopic dermatitis in IL-4/Luc/CNS-1 Tg mice. *Int J Mol Med.* 2014; 33(5): 1185-94. doi: 10.3892/ijmm.2014.1685.
12. Han SB, Kim H, Cho SH, et al. Protective effect of Botulinum toxin type A against atopic dermatitis-like skin lesions in NC/Nga Mice. *Dermatol Surg.* 2017; 43: S312-21. doi: 10.1097/DSS.0000000000001170.
13. Islamuddin M, Chouhan G, Want MY, et al. Leishmanicidal activities of *Artemisia annua* leaf essential oil against Visceral Leishmaniasis. *Frontiers in Microbiology.* 2014; 5: 626. doi: 10.3389/fmicb.2014.00626.
14. Harborne JB. *Phytochemical methods: A guide to modern techniques of plant analysis.* New York: Chapman and Hall; 1973. p. 57.
15. The enzyme-linked immunosorbent assay (ELISA). *Bull World Health Organ.* 1976; 54(2): 129-39.
16. Ramos-Vara JA. Technical aspects of immunohistochemistry. *Vet Pathol.* 2005; 42(4): 405-26. doi: 10.1354/vp.42-4-405.
17. Ju Ho P, Jun Sung J, Ki Cheon K, et al. Anti-inflammatory effect of *Centella asiatica* phytosome in a mouse model of phthalic anhydride-induced atopic dermatitis. *Phytomedicine.* 2018; 43: 110-9. doi: 10.1016/j.phymed.2018.04.013.
18. Rasheed Z, Zedan K, Saif GB, et al. Markers of atopic dermatitis, allergic rhinitis and bronchial asthma in pediatric patients: Correlation with filaggrin, eosinophil major basic protein and immunoglobulin E. *Clin Mol Allergy.* 2018; 16: 23. doi: 10.1186/s12948-018-0102-y.
19. Spergel JM, Mizoguchi E, Oettgen H, et al. Roles of TH1 and TH2 cytokines in a murine model of allergic dermatitis. *J Clin Invest.* 1999; 103(8): 1103-11. doi: 10.1172/JCI5669
20. Chan LS, Robinson N, Xu L. Expression of interleukin-4 in the epidermis of transgenic mice results in a pruritic inflammatory skin disease: An experimental animal model to study atopic dermatitis. *J Invest Dermatol.* 2001; 117(4): 977-83. doi: 10.1046/j.0022-202x.2001.01484.x
21. Koppes SA, Brans R, Ljubojevic Hadzavdic S, et al. Stratum Corneum Tape Stripping: Monitoring of inflammatory mediators in atopic dermatitis patients using topical therapy. *Int Arch Allergy Immunol.* 2016; 170(3): 187-93. doi: 10.1159/000448400.
22. He H, Gao X, Wang X, et al. Comparison of anti-atopic dermatitis activities between DHMEQ and tacrolimus ointments in mouse model without stratum corneum. *Int Immunopharmacol.* 2019; 71: 43-51. doi: 10.1016/j.intimp.2019.03.015.
23. Sehgal VN, Srivastava G, Dogra S. Tacrolimus in dermatology-pharmacokinetics, mechanism of action, drug interactions, dosages, and side effects: Part I. *Skinmed.* 2008; 7(1): 27-30. doi: 10.1111/j.1540-9740.2007.06485.x
24. Ogg G. Role of T cells in the pathogenesis of atopic dermatitis. *Clin Exp Allergy.* 2009; 39(3): 310-6. doi: 10.1111/j.1365-2222.2008.03146.x.
25. Morizane S, Yamasaki K, Kajita A, et al. TH2 cytokines increase kallikrein 7 expression and function in patients with atopic dermatitis. *J Allergy Clin Immunol.* 2012; 130(1): 259-61.e1. doi: 10.1016/j.jaci.2012.03.006.
26. Wang X, Huang H2, Ma X, et al. Anti-inflammatory effects and mechanism of the total flavonoids from *Artemisia scoparia* Waldst. Et kit. In vitro and in vivo. *Biomed Pharmacother.* 2018; 104: 390-403. doi: 10.1016/j.biopha.2018.05.054.
27. Swanson H. *Flavonoids, inflammation and cancer.* Singapore: World Scientific; 2016. p 70.

---

**Correspondence to Mohammed F. Hameed**

**E-mail: mohammad\_hadaad2000@yahoo.com**

**Received Nov. 11<sup>th</sup> 2019**

**Accepted Dec. 9<sup>th</sup> 2019**