

Research Article

Effects of vitamin D deficiency on bone and root resorption post-orthodontic retention in rats

Asmaa Murshed Khamees^{1*}, Dheaa H. Al Groosh², Natheer H Al-Rawi³

1. Ph.D. student, Department of Orthodontic, College of Dentistry, University of Baghdad, Iraq.

2. Professor, Department of Orthodontics, College of Dentistry, University of Baghdad, Iraq.

3. Professor, Department of Oral and Craniofacial Health Sciences, University of Sharjah, UAE.

* Correspondence email: d.al-groosh@codental.uobaghdad.edu.iq

Received date: 25-12-2022

Accepted date: 02-02-2023

Published date: 15-06-2023



Copyright: © 2023 by the authors. The article is published under the terms and conditions of the Creative Commons Attribution (CC BY) license

[\(https://creativecommons.org/licenses/by/4.0/\)](https://creativecommons.org/licenses/by/4.0/).



Abstract: Background: Orthodontic therapy often causes external root resorption. Serum vitamin D (VD) level is important for tooth mineralization and bone remodeling. This study aimed to test the impact of vitamin D (VD) supplements on bone and root remodeling in a vitamin D (VD) deficient rat model following orthodontic retention. Methods and Material: 30 male Wistar rats were divided into three groups: a control group of 10 rats and two experimental groups of 10 rats, each with vitamin D deficiency (VDD) induced by a VD-free diet for 21 days. And a third group with VD supplement. All groups received active orthodontic treatment using a modified orthodontic appliance that applied 50 gm of force for 14 days to move the maxillary right first molar mesially, followed by seven days of retention and relapse. The VDD group received no intervention, while the VDS group received 40,000 IU/kg of systemic VD3 by intramuscular injection on the first and fifteenth day of orthodontic treatment. Histomorphometric analysis was performed to assess bone and cementum resorption and deposition. Results: The VDD group exhibited a significant increase in bone and root resorption and decreased bone deposition and cementum deposition ratio. In addition, bone deposition and the ratio of cementum deposition were substantially greater in the VDS group compared to the control group. Conclusion: VDD may increase bone and root cementum resorption and decrease deposition after orthodontic retention, which may play a significant role in relapse after retention. Before beginning orthodontic treatment, routine VD screening may be beneficial.

Keywords: Vitamin D, orthodontic, bone, cementum.

Introduction

Root resorption is a process of root tissue removal that may occur in different areas alongside the root, that is laterally and/or around the apex, and it may be found with severe tissue loss ⁽¹⁾. External root resorption is common during orthodontic treatment; however, it has no significant clinical consequences ^(2, 3) nor other health-related issues such as root fracture, periodontal illness, or early tooth loss ⁽⁴⁾. Root resorption could be either a physiological or pathological, and the latter may be referred to as orthodontic treatment ⁽⁵⁾. Orthodontic force enhances an inflammatory process that activates osteoclast cells, which cause the removal of bone and root tissues. This process is followed by a reparative process ⁽¹⁾. In addition, root resorption could be associated with other anomalies such as hormonal deficiency and alveolar bone density ^(6, 7).

Vitamin D deficiency (VDD), a common hormonal deficiency problem, ⁽⁸⁾ increases serum parathyroid hormone, which results in progressive bone loss and mineralisation defects. Epidemiologic studies showed that VDD was associated with low bone mineral density and fracture incidence ^(9, 10). Vitamin D (VD) serum level is an essential parameter in root and bone remodeling ⁽¹¹⁾. A correlation was observed

between root resorption and VD receptor gene polymorphism⁽¹²⁾. However, the relationship of VDD and root resorption was inconclusive, probably because of published data with short-term follow-up⁽¹³⁾.

In the resorption lacunae, fibroblast-like cells from the periodontal ligament invading these lacunae repair the resorbed cementum⁽¹⁴⁾. The first histologic evidence of repair is the presence of a thin, uncalcified cementoid⁽¹⁴⁾. These cells secrete noncollagenous matrix proteins, particularly bone sialoprotein and osteopontin, filling the cementoblasts to secrete collagen and form a thin cementoid repair matrix^(14,15). Subsequently, hydroxyapatite crystals grow between collagen fibrils for mineralisation⁽¹⁶⁾. The reparative cementum is a cellular intrinsic fibre type⁽¹⁴⁾. In contrast, the recently deposited cementum appears as layers (thin layer of acellular cementum) in rats, which covered some of the resorption lacunae⁽¹⁷⁾.

This study aimed to assess the amount of bone and root remodeling after orthodontic retention in a VDD-enhanced rat model and to evaluate the effect of VD supplements on VD-deficient rats.

Materials and Methods

1. Animal preparation

The study was approved by the scientific research and ethics committee at the Department of Orthodontics, College of Dentistry/University of Baghdad (Issue no: 177, date 16/1/2020). All experimental procedures were performed in Iraqi Center of Cancer and Medical Genetics Research. Male Wistar rats ($n = 30$) aged 8–10 weeks and weighing 220–300 g were used in this study. Firstly, the rats were acclimatised for one week before VD induction and subjected to 12/12 h of dark/light cycles at $21 \text{ }^\circ\text{C} \pm 2 \text{ }^\circ\text{C}$ with a relative humidity of $50\% \pm 10\%$. Rats were fed a laboratory standard diet and given water *ad libitum*⁽¹⁸⁾.

All the rats followed the same principle. They were weighed. The tail of the rats was coloured (every one special colour). Blood serum was collected by aspiration using a 5 mL sterile syringe (disposable syringe with a needle, 1 mL luer slip, JiangSu JiChun Medical devices, China) after anaesthetising with chloroform (Alpha Chemika, India). Serum VD was investigated and assessed using the VD antibody protein ELISA kit following the manufacturer's instructions (MyBioSource, USA).

Afterward, the rats were divided into two groups. The control group without intervention, and the experiment group in which the rats were fed a VD-free diet (Casein-free VD, Bio-Serv, USA) for 21 days^(19,20). After 21 days, serum VD was re-investigated, and rats suffering from VDD were divided into three groups:

1. The control group.
2. The VDD group continues deficiency during the treatment period.
3. The VDD group received vitamin D supplementation (VDS) by intramuscular injection on days 1 and 15. However, these doses elevated the VD serum level the same as the control group during orthodontic treatment.

2. Orthodontic treatment stages

The rats were anaesthetised after being weighed using intramuscular injection of ketamine (87 mg/kg; ketamine 10%, Alfasan, Woerden, Holland) and xylazine muscle relaxant (10 mg/kg; XYL-M2 injectable solution 25 mL, VMD, Arendonk, Belgium) at a 2:1 ratio⁽²¹⁾, that is in thigh muscle based on the animal housing guidelines in CCMGR. This process was applied in all orthodontic stages. Interproximal spaces were measured between the distal surface of the first molar and the mesial surface of the second molar by using an interproximal vernier (feeler gauge, ROSHTOO80, Japan), and this process was repeated two times by one operator⁽²²⁾.

An orthodontic ligature wire (0.010", Truforce stainless steel, Ortho Technology, USA) was inserted interdentally between the 1st and 2nd right maxillary molars⁽²³⁾ (unilateral orthodontic appliances were bonded,

and the left molar serves as the control side) ⁽²⁴⁾. Then, the first maxillary molar was ligated, and a hook, nickel–titanium closed-coil spring was formed (Dentaurum, Rematitan® LITE Tension Spring, Dentaurum). This hook was inserted, and the other end was attached to the hook formed on maxillary central incisors using a ligature wire (0.012 Kobayashi, Klardent, Sweden) after being etched with acid etch gel (37% Microdont, Brazil). The force delivered with 50 ± 5 gm was adjusted using a digital hand-held force gauge (Sr-1 kg Gray Digital Hanging Scale, American Weigh Scales, GA, USA) to move the 1st molar mesially. Bonding adhesive was applied (3M ESPE, Adper, single bond 2, USA), and composite filling materials (3M ESPE, Filtek, Z350 XT, Universal Restoration, USA) were adapted and cured according to the manufacturer's instructions (Fig. 1A) ⁽²¹⁾.

Vitamin D₃ (cholecalciferol 300000 I.U. \ 1 mL, Pisa, Italy) of 40,000 IU/kg was administrated slowly in left thigh muscle on day one and day 15 for the VDD group ⁽²⁵⁾. On day 15, the orthodontic spring was removed; spaces were measured, and a retainer was inserted for seven days. Afterward, relapse was allowed for another seven days (Fig. 1 B) ⁽²⁶⁾. Then, an overdose of anaesthesia was given, and the final space was measured.

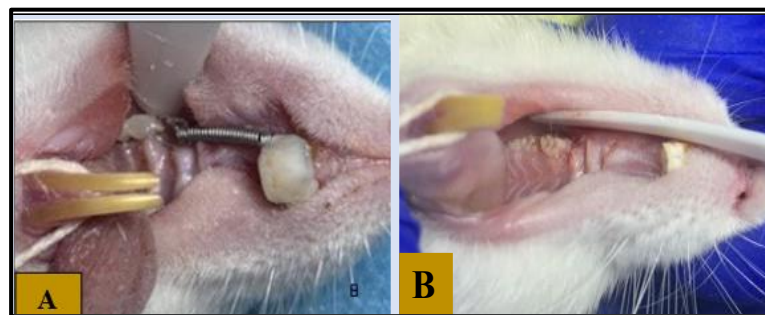


Figure 1: A; Orthodontic appliance bonding, B; Relapse

3. Histological preparation

All rats were sacrificed under an overdose of anaesthesia, and the maxilla was placed in 10% natural buffered formalin solution (formaldehyde, Scharlab S.L., Spain) for 24 h. The sample was rinsed for 21 days in 10% EDTA solution (pH = 7; BDH Chemicals Ltd. Poole, England), and the solution was continuously changed ^(21, 27). After decalcification, half of the maxilla ⁽²⁸⁾ underwent dehydration ⁽²⁹⁾ and then embedded in paraffin wax (Leica Biosystems, Richmond, USA) to obtain longitudinal sections of teeth with the adjacent tissue.

Two sections of 5 μ m thickness, including the mesial root of the maxillary first molar, were stained using haematoxylin and eosin stain (H&E, Leica Biosystems, Richmond, USA). The pressure and tension sides were photographed under a light microscope (OPTIKA, Microscopes, Italy) with 4 \times , 10 \times and 40 \times objective lenses ⁽²⁸⁾ equipped with a photomicroscope (Olympus, Tokyo, Japan). For inter-examiner calibration, the section was randomly selected two times and examined by the same histopathologist under a blind test ⁽³⁰⁾.

The bone area was sectioned to rectangles alongside the mesial root of the maxillary right molar, and bone resorption and formation in pressure and tension sides were calculated using Image J processing program (Image J.exe, LOCI, University of Wisconsin) that was developed at the National Institutes of Health ^(31, 32).

The resorbed and newly deposited radicular cementum was detected and measured under a light microscope similarly as bone. The resorption area of cementum appears as lacunae, and the severity of root resorption was evaluated on the basis of the semiquantitative scale, in which the number, depth and area of each resorption lacuna were calculated (Fig. 2 A) ⁽¹⁷⁾.

The measurement of the level of lacuna repair in cementum was dependent on the grading system, and the thickness of the repair cementum was measured in micrometre using a line as the perpendicular distance from the deepest area in the lacuna until the outer surface of the deposited layer. The image above analysis was used for this purpose (Fig. 2 B) ⁽³³⁾.

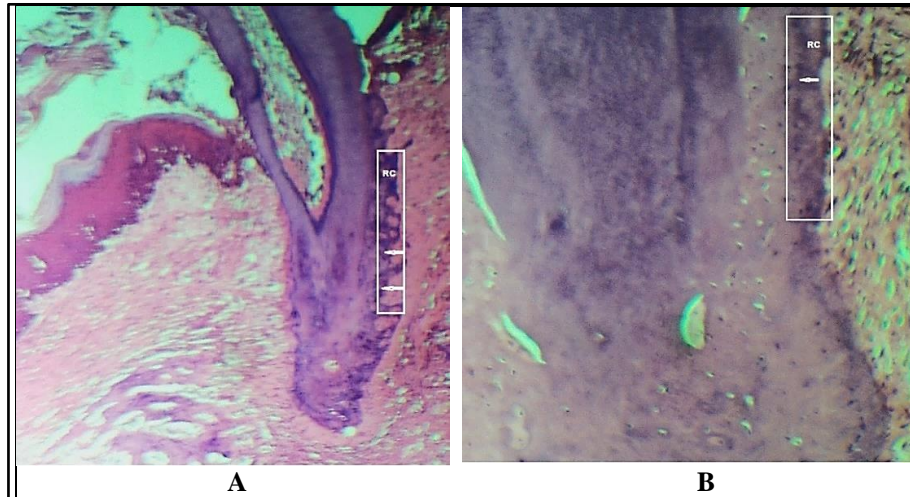


Figure 2: A, Resorbed cementum (RC) represented in marked rectangular, white arrows show the thickness of resorption. B, Recent deposit cementum (RC) represented in marked rectangular, white arrow shows the thickness of deposit cementum.

Statistical analysis

The collected data were statistically evaluated by using statistical package for social sciences (IBM® SPSS® version 25). The Shapiro–Wilk test was used to assess the normality of data. ANOVA and Games–Howell tests were used to compare the bone and cementum (resorption and deposition).

Results

In the VDD group, data revealed a significant decrease in bone formation and an increase in bone resorption. However, bone resorption and formation were comparable between the VDS group and the control group (Table 1).

Table (1): Comparison between the bone resorption and deposition among the control, VDD and VDS groups using ANOVA and Games-Howell tests.

Side	Group	Descriptive statistics				Comparison			
		No	Mean (μm^2)	SD (μm^2)	F-test	p-value	Groups	p-value	
Bone Resorption	Control	10	173.5	7.84	112.2	0.000[S]*	VDD	0.000 [S]*	
	VDD	10	261	24.24			Control	VDS	0.091[NS]
	VDS	10	164	10.75			VDD	VDS	0.000 [S]*
Bone deposition	Control	10	199.5	6.85	171.4	0.000[S]*	VDD	0.000 [S]*	
	VDD	10	145.5	6.85			Control	VDS	0.773[NS]
	VDS	10	202	9.19			VDD	VDS	0.000 [S]*

SD: standard deviation; NS: Non-Significant; S: Significant at $P < 0.05$.

The pressure side data revealed that the alveolar bone surface was irregular, with incomplete mineralisation and few resorption cavities (Figs. 3A and B). Both the control and VDS groups experienced the same outcome. In the VDD group, however, the resorption cavity expanded (Fig. 3 C).

The tension side of the mesial root in control and VDS groups exhibited a tension periodontal ligament with a distinct reversal line between the basal and new bone (Figs. 4 D, E). In contrast, the tension side of the mesial root in the VDD group exhibited narrow new bone apposition that was separated from the basal bone by a reversal line (Fig. 4 F).

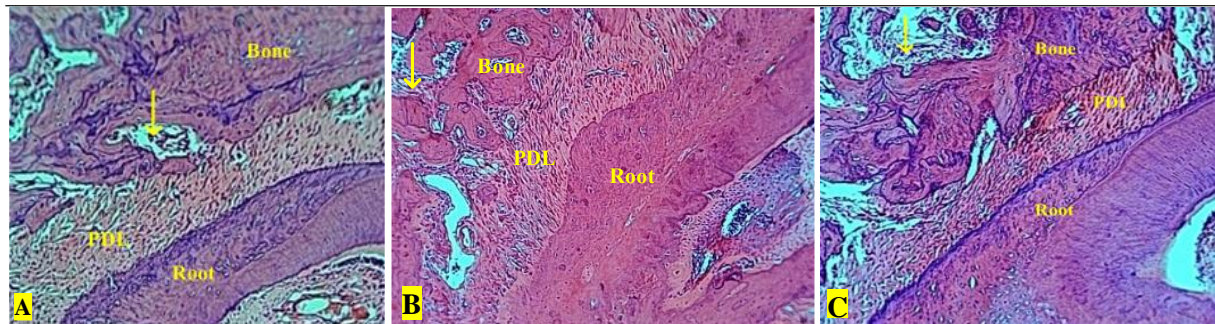


Figure 3: Pressure side area of the mesial root of the upper maxillary first molar. PDL: periodontal ligament, yellow arrow: resorption cavities, (A): Control; (B): VDD; (C): VDS group (H &E; 10x).

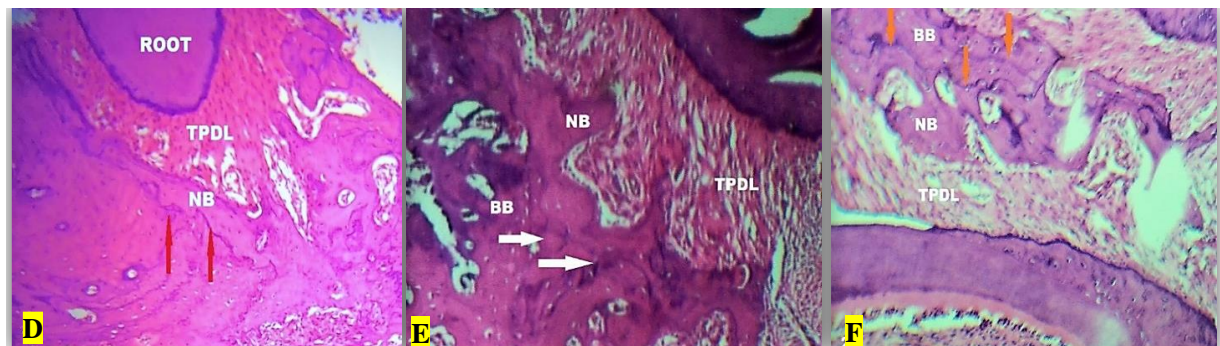


Figure 4: Tension side area of the mesial root of the upper maxillary first molar. Tension periodontal ligament (TPDL); new bone (NB); reversal line (arrows); basal bone (BB). Control (D); VDD (E), VDS (F) groups. (H &E; 10x).

Similar to bone reaction, root resorption and cementum deposition were significantly increased in the VDD group compared to the control and VDS groups. Table 2 shows no statistically significant difference between the control and VDS groups. Consequently, the ratio of cementum deposition to cementum resorption was decreased in the VDD group primarily (Table 3).

Table 2: Comparison between cementum resorption and deposition among the control, VDD and VDS groups using ANOVA and Games-Howell tests.

Side	Group	Descriptive statistics			Comparison				
		No	Mean(μm^2)	SD(μm^2)	F-test	p-value	Groups	p-value	
Cementum Resorption	Control	10	15	5.27	204.7	0.000[S]*	Control	VDD	0.000 [S]*
	VDD	10	63	9.49			VDS	0.052 [NS]	
	VDS	10	10.1	2.73			VDD	VDS	0.000 [S]*
Cementum deposition	Control	10	6.1	1.10	26.01	0.000[S]*	Control	VDD	0.001 [S]*
	VDD	10	20	8.16			VDS	0.765 [NS]	
	VDS	10	6.6	1.96			VDD	VDS	0.001 [S]*

SD: standard deviation; NS: Non-Significant; S, Significant at $p < 0.05$.

Table 3: Percentage of cementum deposition to cementum resorption with the same group

Groups	Sample No	Mean/ CR	Mean/CD	CD/CR %
Control	10	15	6.1	46 %
VDD	10	63	20	31.6%
VDS	10	10.1	6.6	68.4%

CR: Cementum resorption; CD: Cementum deposition

Discussion

Vitamin D deficiency is considered a common health-related problem that is faced by people of all ages worldwide ^(34, 35). It may be associated with low bone mineral density and bone activity ⁽⁹⁾. In orthodontics, retention is an important phase of the treatment ⁽³⁶⁾. However, the prevalence of relapse was reported, and only 30%–50% of treated patients maintained the initial acquired satisfactory alignment after 10 years. In addition, only 10% of treated patients maintained a satisfactory alignment after 20 years ⁽³⁷⁾. Although the mechanism of orthodontic relapse remains unknown ⁽³⁸⁾, bone turnover may influence the relapse ⁽³⁹⁾. Previous research has used the local administration of different medications or biologicals to decrease the relapse following active orthodontic treatment ^(21, 40–42). However, Arqub et al. (2021) reported that local administration may be associated with a short half-life of the agents and may require multiple administration. Therefore, this study adopted the systemic administration of VD ⁽⁴³⁾.

The data revealed a decrease in bone resorption and an increase in bone deposition (bone synthesis) in the control and VDS groups. The metabolites of $1\alpha,25$ -hydroxylated stimulate the expression of osteoblast signature genes, including receptor activators of nuclear factor kappa-B ligand (RANKL) and vitamin D receptors (VDR) ⁽⁴⁴⁾. The activation of VDR increases the expression level of receptor activator of nuclear factor kappa (RANK) on the osteoclast-progenitor cells surface, which stimulates osteoclastogenesis and bone resorption by binding RANK to RANKL. The expression of VDR on the osteoblast cell represents an activation pathway of bone resorption ⁽⁴⁵⁾. In addition, VD plays a role in skeleton mineralisation, which has an anabolic activity ingredient that plays an important role in bone synthesis stimulation ⁽⁴⁶⁾. This finding is consistent with the result of Kale et al. (2004), who found that the local administration of $1,25$ -dihydroxy cholecalciferol increased and facilitated tooth movement by regulating bone deposition and resorption ⁽⁴⁰⁾. Moreover, Kawakami and Takano-Yamamoto (2004) reported that the stability of teeth position was improved after orthodontic movement and local administration of VD ⁽⁴⁷⁾. Furthermore, many authors suggested that VD improves bone health and mineral metabolism ^(48, 49, 50).

The data displayed a significant decrease in root resorption with VDS and an increase in the VDD group. During orthodontic treatment, the generation of proinflammatory mediators under orthodontic forces, such as prostaglandins and leukotrienes, causes tooth movement ⁽⁵¹⁾ and cementum loss, which may lead to root resorption ⁽⁵²⁾.

This finding is consistent with the results of Seifi et al. (2013), who found that VDD during orthodontic treatment may play a key role in the pathophysiological process of root resorption ⁽⁵³⁾. In addition, Booij Vrieling et al. (2010) reported that active VD signals induce pathophysiological root resorption in cats ⁽⁵⁴⁾.

However, the abovementioned results were contrary to that of Tehranchi et al. (2017), who demonstrated no significant correlation between the VD serum level and external apical root resorption development

⁽⁵⁵⁾. Moreover, this result was inconsistent with that of Al-Attar and Abid (2022), who demonstrated a non-significant correlation between root resorption and VD serum level after the first three months of orthodontic treatment ⁽¹³⁾. A different method of root resorption assessment could be used, as the latter used a periapical radiograph with a digital sensor as opposed to the gold standard for histological investigation in the current study. Considering that root resorption is common, resorption lacunae were fully or partially repaired with new cementum ⁽¹⁴⁾. This acellular tissue in rats contrasts with the cellular intrinsic fibre cementum reported in humans ^(16, 17). The results show a significant increase in cementum deposition in VDD in comparison with other groups. In contrast, the ratio of cementum deposition to resorption cavities decreases in VDD in comparison with other groups. This result is consistent with the process of metabolic activity of VD by the indirect role of VD in the stimulation of osteoclastogenesis through regulating some secondary messengers for expression and interactions amongst inflammatory cells, cytokines, enzymes and clast cells ⁽⁵⁶⁾, which is consistent with the suggestion that VD deficiency and dietary VD redundancy have an indirect role in the pathophysiology of the regeneration of common permanent tooth in cats ⁽⁵⁴⁾.

Conclusion

After orthodontic retention, vitamin D deficiency may be elevated in bone and cementum resorption and decreased in bone deposition. Nonetheless, correction of VDD in rats is associated with bone and cementum remodeling, which may significantly reduce relapse after retention. Therefore, patients who are planning orthodontic treatment should undergo VD screening, and the VD serum level should be corrected before treatment.

Conflict of interest: None declared.

References

1. Andreasen JO, Andreasen FM. Textbook and color atlas of traumatic injuries to the teeth, 3rd edn. Munksgaard Publishers, Copenhagen.1993. DOI:10.25241
2. Chan EK, Darendeliler MA. Exploring the third dimension in root resorption. *Orthod Craniofac Res.* 2004; 7:64-70. [\(Crossref\)](#)
3. Zahrowski J, Jeske A. Apical root resorption is associated with comprehensive orthodontic treatment but not clearly dependent on prior tooth characteristics or orthodontic techniques. *J Am Dent Assoc.* 2011; 142:66-8. 5. [\(Crossref\)](#)
4. Rathe F, Nolken R, Deimling D, Ratka-Kr`uger P. Externe wurzelresorption [external root resorption]. *Schweizerische Monatsschrift fur Zahnmedizin.* 2006; 116 (3): 245–253.
5. Andreasen JO, Andreasen FM. *Essentials of Traumatic Injuries to the Teeth: A Step-by-step Treatment Guide*, John Wiley and Sons, Hoboken, NJ, USA, 2010. [\(Crossref\)](#)
6. Lopatiene K, Dumbravaite A. Risk factors of root resorption after orthodontic treatment. *Stomatologija.* 2008; 10:89-95.
7. Jung YH, Cho BH. External root resorption after orthodontic treatment: a study of contributing factors. *ISD.* 2011; 41(1): 17. [\(Crossref\)](#)

8. Fanari Z, Hammami S, Hammami MB, Hammami S, Abdellatif A. Vitamin D deficiency plays an important role in cardiac disease and affects patient outcome: Still a myth or a fact that needs exploration? *JSHA*. 2015; 27(4): 264–271. [\(Crossref\)](#)
9. Hatun Ş, Ozkan B, Bereket A. Vitamin D deficiency and prevention: Turkish experience. *Acta Paediatrica*. 2011; 100(9): 1195–1199. [\(Crossref\)](#)
10. Munns CF, Shaw N, Kiely M, Specker BL, Thacher TD, Ozono K, et al. Global Consensus Recommendations on Prevention and Management of Nutritional Rickets. *JCEM*. 2016; 101(2): 394–415. [\(Crossref\)](#)
11. Bouillon R, Suda T. Vitamin D: calcium and bone homeostasis during evolution. *Bone Key Reports*. 2014; 3, 480. [\(Crossref\)](#)
12. Fontana ML, de Souza CM, Bernardino JF, Hoette F, Hoette ML, Thum L, et al., Association analysis of clinical aspects and vitamin D receptor gene polymorphism with external apical root re sorption in orthodontic patients. *AJO-DO*. 2012; 142(3): 339–347. [\(Crossref\)](#)
13. Al-Attar A, Abid M. Effect of vitamin D3 on the alignment of mandibular anterior teeth: a randomized controlled clinical trial, *International J Dent*. 2022; 6555883 (11): 2022. [\(Crossref\)](#)
14. Jäger A, Kunert D, Friesen T, Zhang D, Lossdörfer S, Götz W. Cellular and extracellular factors in early root resorption repair in the rat. *Eur J Orthod*. 2008; (30): 336–345. [\(Crossref\)](#)
15. Brudvik P, Rygh P. The repair of orthodontic root resorption: an ultrastructural study, *Eur J Orthod*. 1995;17, (3): 189–198. [\(Crossref\)](#)
16. Bosshardt DD, Zalzal S, Mckee MD, Nanci A. Developmental appearance and distribution of bone sialoprotein and osteopontin in human and rat cementum. *Anatomical Record*. 1998; 250(1):13–33. [\(Crossref\)](#)
17. Turkkahraman H, Yuan X, Salmon B, Chen CH, Brunski JB, Helms JA. Root resorption and ensuing cementum repair by Wnt/ β -catenin dependent mechanism. *AJO-DO*. 2019. [\(Crossref\)](#)
18. Al-Harbi NO, Nadeem A, Al-Harbi MM, Zoheir KMA, Ansari MA, El-Sherbeeney AM, et al Psoriatic inflammation causes hepatic inflammation with concomitant dysregulation in hepatic metabolism via IL-17A/IL-17 receptor signaling in a murine model. *Immunobiology*. 2017; 222(2): 128–136. [\(Crossref\)](#)
19. Hokugo A, Christensen R, Chung EM, Sung EC, Felsenfeld AL, Sayre JW, et al. Increased prevalence of bisphosphonate-related osteonecrosis of the jaw with vitamin D deficiency in rats. *JBMR*. 2010; 25(6): 1337–1349. [\(Crossref\)](#)
20. Stavenuiter AWD, Arcidiacono MV, Ferrantelli E, Keuning ED, Vila Cuenca M, ter Wee PM, et al. A Novel Rat Model of Vitamin D Deficiency: Safe and Rapid Induction of Vitamin D and Calcitriol Deficiency without Hyperparathyroidism. *BioMed Research International*. 2015; 1–5. [\(Crossref\)](#)
21. Alnajar HAAM, Al Groosh DH. The effects of calcitonin on post-orthodontic relapse in rats. *Clinical and Experimental Dental Research*. 2020; 7(3): 293–301. [\(Crossref\)](#)
22. Franzen TJ, Brudvik P, Vandevska-Radunovic V. Periodontal tissue reaction during orthodontic relapse in rat molars. *Eur J Orthod*. 2011; 35(2): 152–159. [\(Crossref\)](#)

23. Yadav S, Assefnia A, Gupta H, Vishwanath M, Kalajic Z, Allareddy V, et al. The effect of low-frequency mechanical vibration on retention in an orthodontic relapse model. *Eur J Orthod.* 2015; 38(1): 44–50. [\(Crossref\)](#)
24. Verna C, Dalstra M, Melsen B. The rate and the type of orthodontic tooth movement is influenced by bone turnover in a rat model. *Eur J Orthod.* 2000; 22(4): 343–352. [\(Crossref\)](#)
25. Derakhshanian H, Javanbakht MH, Zarei M, Djalali E, Djalali M. Vitamin D increases IGF-I and insulin levels in experimental diabetic rats. *Growth Hormone & IGF Research.* 2017; 36, 57–59. [\(Crossref\)](#)
26. Li X, Li M, Lu J, Hu Y, Cui L, Zhang D, et al. Age-related effects on osteoclastic activities after orthodontic tooth movement. *Bone & Joint Research.* 2016; 5(10):492-499. [\(Crossref\)](#)
27. Plut A, Sprogar Š, Drevenšek G, Hudoklin S, Zupan J, Marc J, et al. Bone remodeling during orthodontic tooth movement in rats with type 2 diabetes. *AJO-DO.* 2015; 148(6), 1017–1025. [\(Crossref\)](#)
28. Al-Duliamy MJ. Enhancement of Orthodontic Anchorage and Retention by Local Injection of Strontium: An Experimental Study in Rats. Master Thesis, College of Dentistry, Baghdad University, Iraq. 2011. [\(Crossref\)](#)
29. González-Chávez SA, Pacheco-Tena C, Macías-Vázquez CE, Luévano- Flores E. Assessment of different decalcifying protocols on Osteopontin and Osteocalcin immunostaining in whole bone specimens of arthritis rat model by confocal immunofluorescence. *Int J Clin Exp Pathol.* 2013; 6(10): 1972–1983.
30. Hudson JB, Hatch N, Hayami T, Shin JM, Stolina M, Kostenuik PJ, et al. Local Delivery of Recombinant Osteoprotegerin Enhances Postorthodontic Tooth Stability. *Calcified Tissue International.* 2012; 90(4), 330–342. [\(Crossref\)](#)
31. Schneider CA, Rasband WS, Eliceiri KW. NIH Image to ImageJ: 25 years of image analysis. *Nature methods.* 2012; 9, 671-675. [\(Crossref\)](#)
32. Razouki NA, Ghani BA. Histological Evaluation of Effect of beta-Tricalcium Phosphate on Bone healing in Alloxan-Induced diabetes. *JBCD.* 2016; (325): 1-7. [\(Crossref\)](#)
33. Mehta SA, Deshmukh SV, Sable RB, Patil AS. Comparison of 4 and 6 weeks of rest period for repair of root resorption. *Prog Orthod.* 2017 Dec;18:1-8 [\(Crossref\)](#)
34. Al-Daghri NM. Vitamin D in Saudi Arabia: prevalence, distribution, and disease associations. *J Steroid Biochem Mol Biol.* 2018; (175):102–107. [\(Crossref\)](#)
35. Hantoosh HA, Mahdi MH, Imran BW, Yahya AA. Prevalence of vitamin D deficiency in Iraqi female at reproductive age. *Med J Babylon* 2019;16:119-22. [\(Crossref\)](#)
36. Proffit WR, Fields HW, Larson B, Sarver DM. *Contemporary Orthodontics*, (6th ed.) St. Louis: Mosby. 2019.
37. Yu Y, Sun J, Lai W, Wu T, Koshy S, Shi Z. Interventions for managing relapse of the lower front teeth after orthodontic treatment. *Cochrane Database of Systematic Reviews.* 2010, Issue 10. [\(Crossref\)](#)
38. Qi J, Kitaura H, Shen WR, Kishikawa A, Ogawa S, Ohori F, et al. Establishment of an orthodontic retention mouse model and the effect of anti-c-Fms antibody on orthodontic relapse. *PLOS ONE.* 2019; 14(6): e0214260. [\(Crossref\)](#)

39. Maleeh I, Robinson J, Wadhwa S. Role of Alveolar Bone in Mediating Orthodontic Tooth Movement and Relapse. *Biology of Orthodontic Tooth Movement*. 2016: 1–12. [\(Crossref\)](#)
40. Kale S, Kocadereli İ, Atilla P, Aşan E. Comparison of the effects of 1,25 dihydroxycholecalciferol and prostaglandin E2 on orthodontic tooth movement. *AJO- DO*. 2004; 125(5): 607–614. [\(Crossref\)](#)
41. Vieira GM, Falcao DP, Fernandes de Queiroz SB. A novel analysis via micro-CT imaging indicates that chemically modified tetracycline-3 (CMT-3) inhibits tooth relapse after orthodontic movement: a pilot experimental study. *Int J Dent*. 2019; [\(Crossref\)](#)
42. Azami N, Chen PJ, Mehta S, Kalajzic Z, Dutra EH, Nanda R, et al. Raloxifene administration enhances retention in an orthodontic relapse model. *Eur J Oral of Orthodontics*. 2020; [\(Crossref\)](#)
43. Arqub SA, Gandhi V, Iverson MG, Ahmed M, Kuo CL, Mu J, et al. The effect of the local administration of biological substances on the rate of orthodontic tooth movement: a systematic review of human studies. *Progress in Orthodontics*. 2021; 22(1). [\(Crossref\)](#)
44. Atkins GJ, Anderson PH, Findlay DM, Welldon KJ, Vincent C, Zannettino ACW, et al. Metabolism of vitamin D3 in human osteoblasts: Evidence for autocrine and paracrine activities of 1 α ,25-dihydroxyvitamin D3. *Bone*. 2007; 40(6): 1517–1528. [\(Crossref\)](#)
45. Lutter AH, Hempel U, Anderer U, Dieter P. Biphasic influence of PGE2 on the resorption activity of osteoclast-like cells derived from human peripheral blood monocytes and mouse RAW264.7 cells. *PLEFA*. 2016; (111): 1–7. [\(Crossref\)](#)
46. Shevde NK, Plum LA, Clagett-Dame M, Yamamoto H, Pike JW, DeLuca HF. A potent analog of 1,25-dihydroxyvitamin D3 selectively induces bone formation. *PNAS*. 2002; 99(21): 13487–13491. [\(Crossref\)](#)
47. Kawakami M, Takano-Yamamoto T. Local injection of 1,25-dihydroxyvitamin D3 enhanced bone formation for tooth stabilization after experimental tooth movement in rats. *JBM*. 2004; 22(6): 541–546. [\(Crossref\)](#)
48. Stein SH, Tipton DA. Vitamin D and its impact on oral health – An update. *J Tenn Dent Assoc*. 2011; (91):30-3.
49. Anand N, Chandrasekaran SC, Rajput NS. Vitamin D and periodontal health: Current concepts. *J Indian Soc Periodontol*. 2013; (17):302-8. [\(Crossref\)](#)
50. Bastos Jdo A, Andrade LC, Ferreira AP, Barroso Ede A, Daibert Pde C, Barreto PL, et al. Serum levels of Vitamin D and chronic periodontitis in patients with chronic kidney disease. *J Bras Nefrol*. 2013; (35):20-6. [\(crossref\)](#)
51. Sabuncuoglu FA, Esenlik E. Influence of drugs on orthodontic tooth movement. *Pakistan Oral & Dental J*. 2010; 30(2):1126–1129.
52. Seifi M, Ravadgar M, Eslami B. Effect of acetaminophen, aspirin, and ibuprofen on the rate of orthodontic tooth movement and root resorption in rabbits. *J of Dental School*. 2004; (21):689–700. [\(Crossref\)](#)
53. Seifi M, Hamed R, Naziri M. The synergistic effect of Vitamine D and Prostaglandin E2 on orthodontic tooth movement in rats. *Iran J Orthod*. 2013; (8):1-5. [\(Crossref\)](#)

54. Booi-Vrieling HE, Ferbus D, Tryfonidou MA, Riemers FM, Penning LC, Berdal A, et al. Increased Vitamin D-driven signalling and expression of the Vitamin D receptor, MSX2, and RANKL in tooth resorption in cats. *Eur J Oral Sci.* 2010;(118):39-46. [\(crossref\)](#)
55. Tehranchi A, Younessian F, Sadighnia A, Abdi AH, Shirvani A. Correlation of Vitamin D status and orthodontic-induced external apical root resorption. *D R J.* 2017;14(6):403-411.
56. Zhang D, Yang YQ, Li XT, Fu MK. Expression of osteoprotegerin and the receptor activator of nuclear factor kappa B ligand in human periodontal ligament cells cultured with and without $1\alpha, 25$ -dihydroxyvitamin D3. *Archives of Oral Biol.* 2004;49(1):71-76. [\(Crossref\)](#)

العنوان: تأثير نقص فيتامين (د) على تآكل العظام والجذور بعد تثبيت تقويم الأسنان في الفئران
الباحثون: أسماء مرشد خميس¹, ضياء حسين الكروش²
الخلاصة:

الخلفية: ليس من غير المألوف تآكل الجذر الخارجي أثناء علاج تقويم الأسنان ، فقد اقترح أن مستوى فيتامين (د) في المصل ضروري لامتصاص وبناء الأنسجة الصلبة مثل العظام والأسنان، وقد هدفت هذه الدراسة إلى تقييم نسبة تكوين العظام والجذور فيما بعد التثبيت من علاج تقويم الأسنان في نموذج الفئران المصابة بنقص فيتامين (د) وتقييم تأثير مكملات فيتامين (د) على إعادة تكوين العظام والجذور.

المواد وطرق العمل: تم تقسيم الجرذان البالغة ثلاثون ذكر نوع Waster إلى ثلاث مجموعات. مجموعة التحكم 10 فئران ومجموعتين تجريبية (كل واحدة 10 فئران) المصابة بنقص فيتامين (د) الناجم عن اطعام الفئران غذاء مخصص خالي من فيتامين (د) لمدة 21 يوماً. خضعت جميع المجموعات لعلاج لتقويم الأسنان باستخدام جهاز تقويم أسنان معدل تم تركيبه لتطبيق 50 جم من القوة لتحريك الأضراس الأولى اليمنى للفك العلوي الأيمن لمدة 14 يوماً ، والتثبيت 7 أيام ، والانتكاس 7 أيام. مجموعة نقص فيتامين (د) دون تدخل ، بينما تلقت المجموعة المكملة بفيتامين (د) 40000 وحدة دولية / كجم من فيتامين (د) عن طريق الحقن العضلي في اليوم الأول والخامس عشر من فترة العلاج التقويمي. تم إجراء فحص الانسجة لتقييم تآكل ووبناء العظام والملاط.

النتائج: كان هناك زيادة معنوية في تآكل العظام والجذور وانخفاض بناء العظام ونسبة بناء الملاط في مجموعة نقص فيتامين (د). بينما كانت نسبة تكوين العظام والملاط أعلى بكثير في المجموعة المكملة بفيتامين (د) وكذلك في مجموعة التحكم.

الاستنتاج: قد يؤدي نقص فيتامين (د) إلى ارتفاع تآكل العظم والجذر، وكذلك تقليل بناء العظم والجذر بعد فترة تثبيت التقويم التي قد تلعب دوراً مهماً في زيادة الانتكاس بعد فترة التثبيت. قد يكون الفحص الروتيني لفيتامين (د) مفيداً قبل البدء في علاج تقويم الأسنان.