

Maternal Stromal Endometrial Cells of Pregnant Goat Uterus:A Light Microscopic Study

خلايا سدى بطانة رحم الماعز الحوامل: دراسة بالمجهر الضوئي

Akram Yousif Yasear; Kadhim Madjeed Haddao

**Department of Basic Medical Sciences, College of Dentistry,
University of Karbala, Iraq**

Abstract

As part of working on the normal histology of the placenta of goat, the present work was aimed to presents normal modification and fate of maternal stromal cells of the pregnant endometrium which were in a form of fibroblast like cells. Fifteen pregnant goat's uteri were collected representing early pregnancy (day 20), mid pregnancy (days 66 and 85), and late pregnancy (days 100 and 125). Sample for light microscopy were fixed in Karnovsky's fluid and embedded in resin; semithin sections were stained with 1% toluidine blue.

Few days after implantation at day 20 there was no pronounced modification in the maternal endometrial stromal cells. The actual changes happened after the penetration of the fetal chorionic villi deep into endometrium which was represented by caruncles. The climax of modification was seen in the present work at day 66 of pregnancy. The maternal stromal cells cytoplasm increased in size, their nuclei have euochromatin suggesting synthetic ability for them. Most of the cells were disposed between the maternal blood vessels and the synepitheliochorial layer. After the elapse of second half of pregnancy the maternal stromal cells vanished from the scene of the placentome, allowing too much needed reduction in the space for rapid feto-maternal exchange of material across the blood circulation of the two sides.

Key words: Goat placentome, maternal stromal cells.

الخلاصة

يعد العمل الحالي جزء من سلسلة أبحاث حول الصورة النسجية الطبيعية لدراسة السخد في الماعز. ويهدف البحث إلى إبراز التحويرات الطبيعية وذل مصير خلايا سدى الام في بطانة الرحم الحامل والتي تكون في الأساس بشكل يشبه الخلايا المولدة لـ الليف. تم جمع خمسة عشر رحما من الماعز الحوامل تمثل الفترة المبيرة من الحمل 20، والفترة الوسطى منه عند اليومين 66 و 85 وكذلك الفترة المتأخرة من الحمل عند اليومين 100 و 125. لفحص العينات تحت المجهر الضوئي تم تثبيت العينات في محلول كارنوفسكي Karnovsky وتم طمرها بمادة الراتنج لغرض الحصول على مقاطع رقيقة والتي تم صبغها بمحلول 1% التولودين الأزرق toluidine blue 1%.

أظهرت النتائج عند اليوم العشرين من الحمل عدم وجود تحويرات واضحة في خلايا سدى بطانة رحم الماعز الحامل، فيما أظهرت النتائج تغييرات حقيقية حدثت بعد اختراق زغابات الجنين عميقا في بطانة الرحم والتي تكون عادة في أجزاء من بطانة الرحم عند اللحميات الرحمية. كانت ذروة التحويرات في خلايا السدى للام عند اليوم السادس والستون من الحمل، وكانت هذه التحويرات متمثلة بزيادة حجم الساييتوبلازم في هذه الخلايا، ولنواتها كمية من الـ euochromatin مما يعني القابلية على التصنيع. كما ظهر ان تموضع الخلايا السدوية للام كان ما بين أوعية الرحم الدموية والتركييب المواجه لنسيج الجنين المسمى بطبقة synepitheliochorial. لم تتمكن من تحديد أي وجود لخلايا سدى الأم خلال فترة النصف الثاني من الحمل وهذا الامر له فوائد منها تقليص الفسحة الفاصلة ما بين نسيج الأم والجنين مما يسهل عملية التبادل الغذائي فيما بينهما.

Introduction

Modification and histodifferentiation in the maternal endometrial stromal cells are a prerequisite for successful pregnancy. In mammals with invasive implantation and haemochorial placentation such as the human (1,2,3), rodents (4), and monkeys (2,5); the original endometrial cells which are usually in a form of fibroblast-like cells, are differentiated, under the influence of pregnancy hormones, to become decidual cells which play very important role in maintaining the pregnancy from the time of implantation till the end of pregnancy. The process of differentiation of these cells is called decidualization (6,7). Decidualization in these animals is manifested by increase in the size of the cells. Their cytoplasm is acquiring well developed organelles suggesting an increase in synthetic ability (8,9). In addition to that there is a decrease in the intercellular spaces between them leading to the appearance of specialized junctions between the plasma membrane. The tight junctions are a mean of junctions between these cells. This kind of junctions is important to restrain trophoblastic invasion after the luminal uterine epithelium is breached (8,10). As such, the decidual tissue provides balance between maternal and fetal invasion \ development to ensure successful completion of gestation (8). Recently goat placenta has been described as synepitheliochorial placenta (8) because binucleate trophoblastic giant cells (BN) migrate from fetal chorionic trophoectoderm across the microvillar junction between the fetal villi and maternal crypts, and fuse with the uterine epithelium to form a hybrid tissue covering the maternal tissue of the caruncles (8).

No overt endometrial stromal cellular alterations have been reported in the goat and no decidual reaction results from the changes in the uterine epithelium from cellular to syncytial (8). However, with the aid of immunofluorescence analysis, the maternal endometrial stromal cells at the site of implantation in the goat have expressed a reaction for osteopontin during early implantation in the ewe. Osteopontin was considered to be a gene marker for decidualization (11).

The aim of the present study is to shed more light on the modifications and fate of the maternal stromal cell proper of endometrium during different stages of pregnancy, which are essential to know the synchronization between the fetal and maternal tissues required for the success of pregnancy.

Materials and Methods

Fifteen goats were used in this work. They were obtained from local slaughter house during the period from 2012 to 2015. Pregnancy dating was estimated from fetal crown rump length (19) viz: days 20(n=2), 60(n=3), 85 (n=4), 100 (n=4), 125 (n=2). The two uteri of day 20 were obtained incidentally and after naked gross and histological examinations they were found to represent an early stage of pregnancy approximately day 20 after conception. The Fifteen uteri were removed within 15 minutes after slaughtering. The middle uterine artery of each uterus was cannulated and the organ was flushed with about 150mL weight /volume NaCl saline solution. This was followed by a Karnovsky's fixative for about 15 minutes (12), which is consisting of 2% paraformaldehyde: 2% glutaraldehyde solution in 0.1 M phosphate buffer pH 7.2. Nearly 5 mm thick pieces were excised by cutting vertically down from the surface of several placentomes. The collected samples were further immersed fixed in the same fixative for 60-90 minutes at 4°C. The samples then dehydrated in ascending grades of alcohol, cleared in propylene oxide and embedded in epon\ araldite mixture. One micron serial sections were cut using an LKB III ultratome and put on glass slides to be stained with 1% toluidine blue for light microscopy examination (13).

Results

At day 20 of fetal age the trophoectodermal layer which represented the fetal side of the placentome was tightly adherent to the uterine epithelium, which has become partially syncytial forming synepitheliochorial layer (Figs. 1 A and B). Binucleate fetal cells were notably present on the fetal side (Fig. 1B). The maternal stromal cells at this stage of early pregnancy were in a form of fibroblast like cells (Figs. 1 A and B). They were disarrayed in the caruncular endometrial tissue some of them were placed as a layer separating between the maternal capillaries and the synepitheliochorial layer (Figs. 1A and B). The densely stained nuclei of these cells were occupying most of the cytoplasm (Fig. 1 B). At this stage the intercellular spaces were wide between the maternal stromal cells. No fetal chorionic villi were noted advancing toward the maternal tissue and the trophoectoderm which represented the embryonic side was anchoring in parallel way into the endometrial epithelial tissue.

At day 66 of the fetal age the whole caruncular tissues were largely involved in intimate contacts with chorionic villi (Fig. 2). Concomitant with the penetration of fetal chorionic villi, the maternal stromal cells were separating between maternal blood vessels and the synepitheliochorial tissue (Fig.2). The maternal stromal cells have become much larger and the intercellular spaces between them were greatly diminished. Their nuclei were having predominance of euochromatin (Fig. 2). In contrast to the previous stage their cytoplasm was considerably larger expressing the activation of these cells (Fig.2). The maternal stromal cells have formed a well tight layer separating between the synepithelial layer and the maternal blood vessels (Fig.2). The chorionic villi have penetrated into maternal caruncular tissue (Fig.2).

By day 85 of pregnancy the maternal stromal cells no longer recognized to separate between the maternal blood vessels and the synepitheliochorial layer (Fig.3). The only cells seen to intervene between the synepithelial layer and the maternal blood vessels were the pericytes as a perivascular cells. In the following stage of pregnancy examined in this work, i.e. days 100; and 125 days post coitum (dpc), the extracellular spaces separating between the synepitheliochorial tissue and the maternal blood vessels contained no traces for maternal stromal cells (Figs. 4 and 5). In these periods of pregnancy there was extensive branching of the chorionic villi which were received into reciprocal maternal crypts (Figs. 4 and 5). There was also indentation of the maternal blood vessels to the synepitheliochorial tissue to reduce the distance between the maternal circulation and fetal circulation (Fig.6).

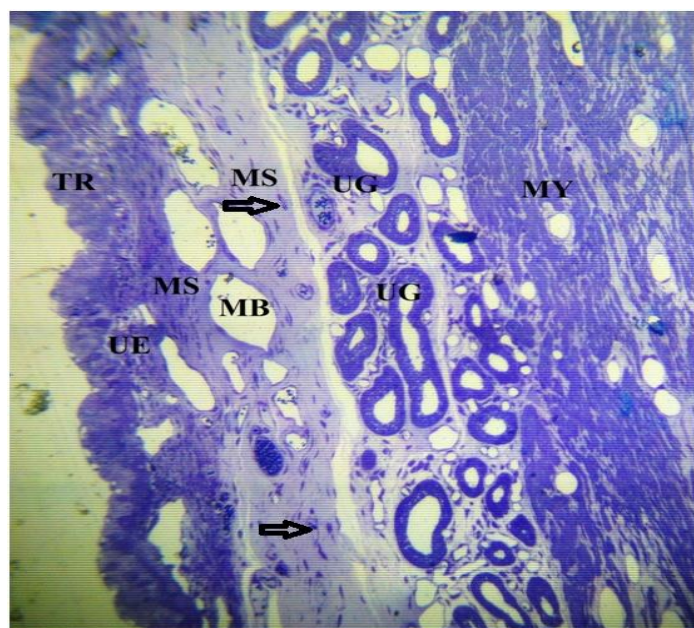


Fig. 1 A: Semithin section stained with toluidine blue of goat uterus showing the trophoectoderm (TR) of the recently implanted blastocyst at estimated day 20 of pregnancy. The maternal stromal cells are disarrayed (MS and arrows) with wide intercellular spaces between them in the deeper layer of the endometrium, compared with those in subepithelial region which have lesser spaces between them. Uterine glands (UG) and maternal blood vessels (MB) are wide and clearly demonstrated. (MY) myomaterium, (UE)uterine epithelium. X 400.

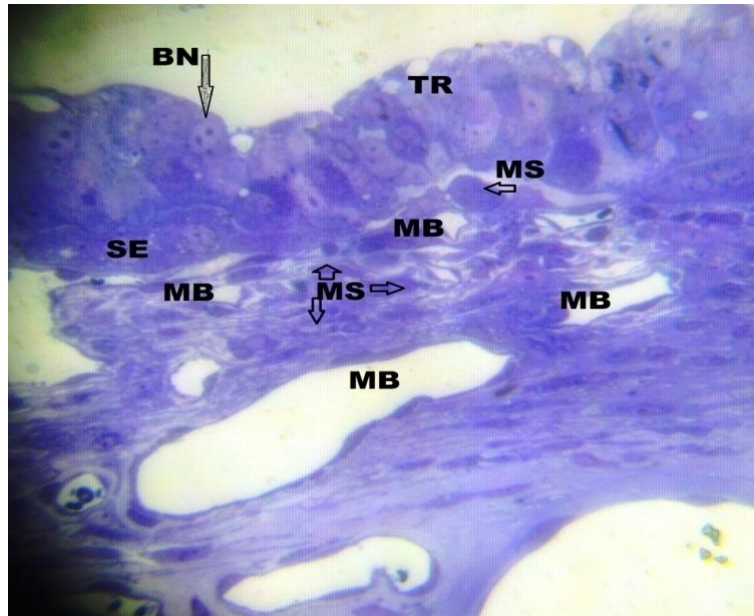


Fig. 1 B: Same Semithin section of figure 1 A showing the fetal binucleated cell (BN and arrow) as part of trophoectoderm (TR); recently formed synepithelial layer; maternal blood vessels (MB);the maternal stromal cells (MS and arrows) are considerably compacted with each other, they are interposing between the maternal blood vessels and the synepithelial layer. Toluidine blue staining, X 800.

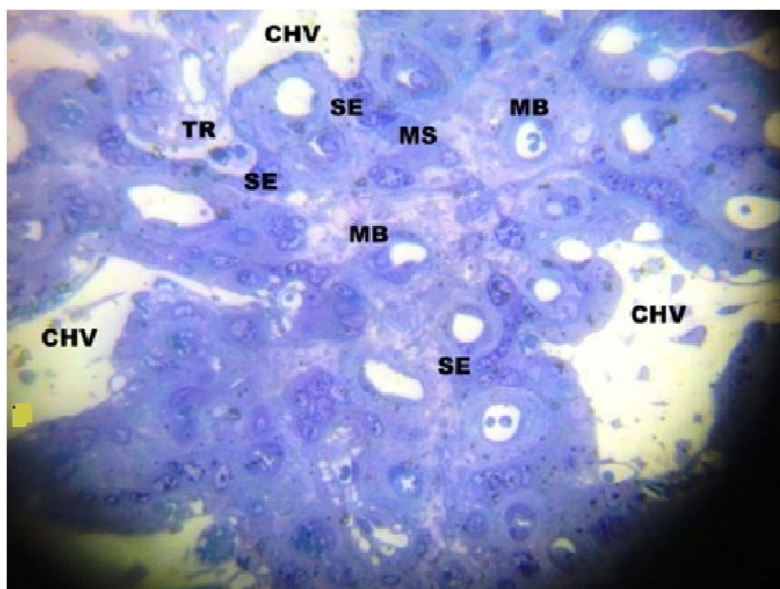


Fig. 2: Day 66 of pregnancy of Goat placentome showing the increase in the size of the maternal stromal cells (MS) and the elaboration of branching of chorionic villi (CHV) compared with the early pregnancy is well indicated. Note the abundance of the euchromatin in their nuclei. The maternal blood vessels (MB); synepitheliochorial layer (SE) and the trophoectoderm (TR) are outlined in the image. Semithin section stained with toluidine blue staining. X 800.

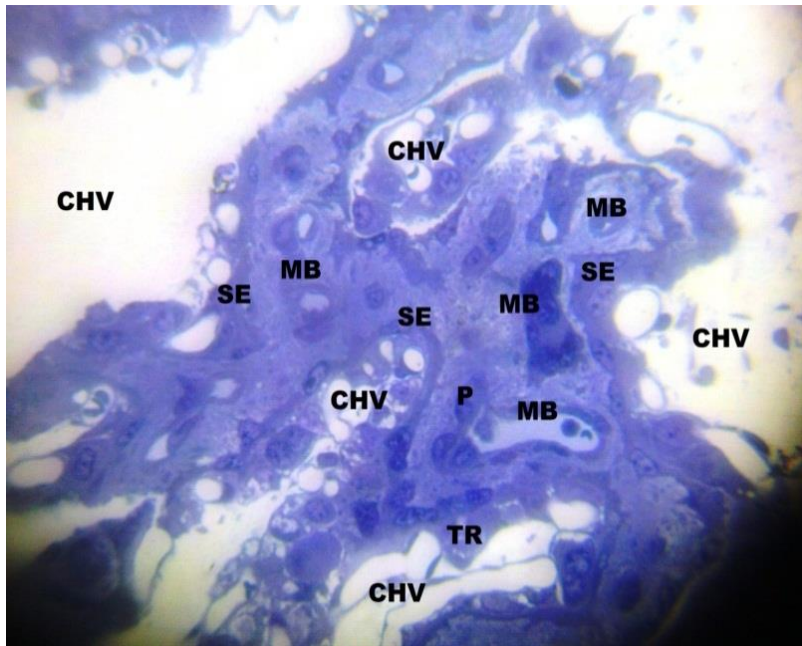


Fig. 3: Histological section showing the extensive branching of the chorionic villi (CHV) characteristics of this time of pregnancy (day 85). Note disappearance of the maternal stromal cells which supposed to intervene between the synepitheliochorial layer (SE) and the maternal blood vessels (MB). The pericytes (P) as perivascular cells is seen abutting the endothelial cells of maternal blood vessels. Semithin section stained with toluidine blue. X800.

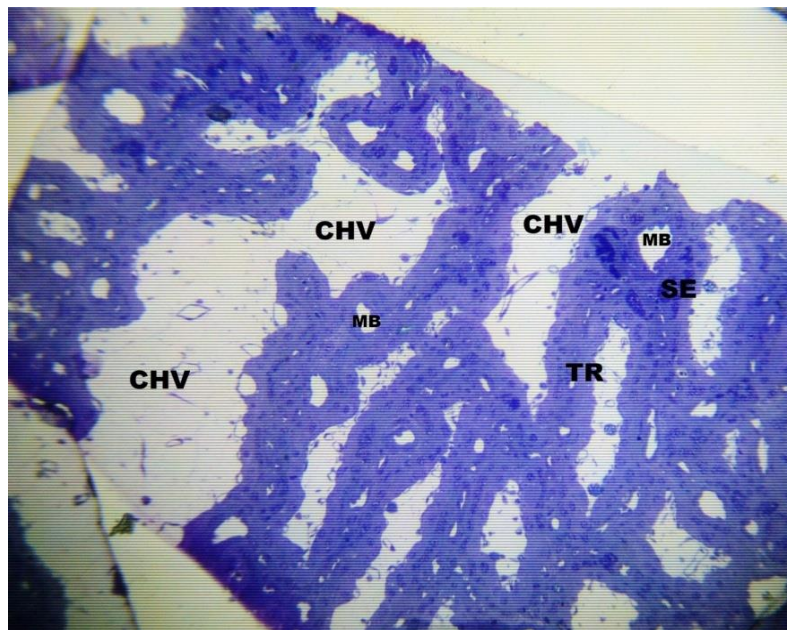


Fig. 4: Histological section of placente at day 100 of pregnancy to demonstrate the extensive branching of the chorionic villi (CHV) which received into reciprocal maternal crypts. Maternal blood vessels (MB); synepitheliochorial layer (SE); and the trophoectodermal (TR) are demonstrated. Semithin section stained with toluidine blue. X 400.

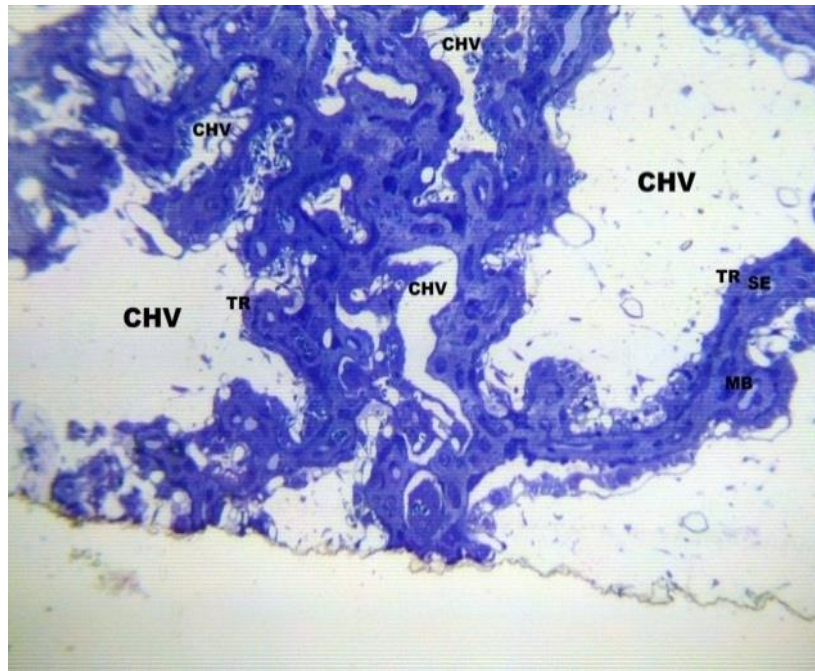


Fig. 5: stained section from day 125 of pregnancy showing the elaboration and extensive branching of the fetal chorionic villi (CHV). Maternal crypts are represented here by the synepitheliochorial tissue (SE) which house maternal vessels (MB), (TR) Trophoectoderm. Semithin section stained with toluidine blue. X400.

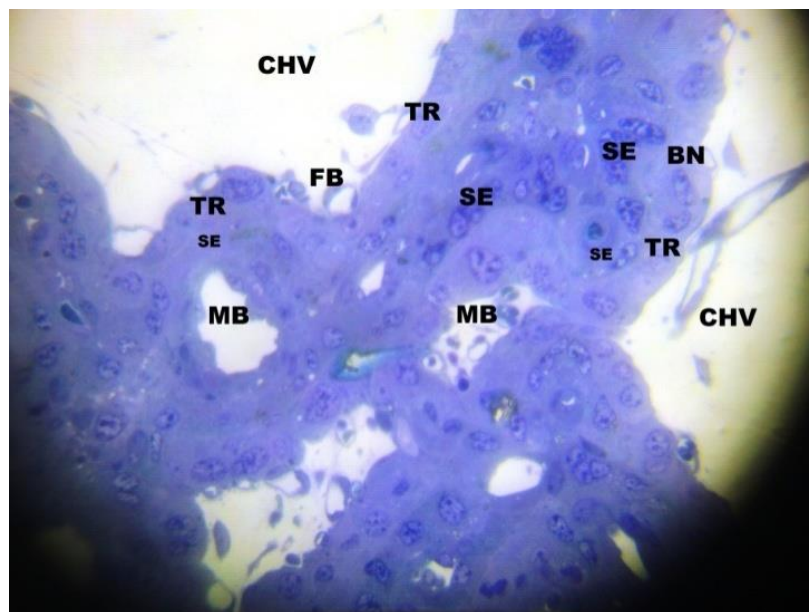


Fig. 6: Histological section section of placentome of pregnant goat at day 125 of pregnancy to demonstrate the disappearance of maternal stromal cells from the area located between the synepitheliochorial layer (SE) and the maternal blood vessels (MB). Note also the huge space occupied by the fetal chorionic villi (CHV) and the indentation of fetal capillaries (FB) to the trophoectodermal layer (TR). Semi thin section stained with toluidine blue. X800.

Discussion

The results of the present study had indicated that temporal correlations exist between the penetrations of chorionic villi into the caruncular maternal tissue. The penetration of these villi and their subsequent ramifications were accompanied by migration of certain fetal cells called binucleated cells (BNC) from fetal side towards the maternal side of the placentome (8, 14).

Histologically, the present study had demonstrated that the modification of the maternal stromal cells of the pregnant goat uteri was triggered by the migration of these cells which had happened alongside the advancement of fetal villi towards the maternal caruncular tissue. It had been demonstrated that the migration of these cells was to achieve two consignments: firstly, to establish the synepitheliochorial placentation of the goat and to deliver the content of their secretory granules towards the maternal side of the placenta (8,14,15). Several substances in the maternal circulation had been mentioned to be originated from these granules, one of them was caprine placental lactogen (15,16). In fact, we have to point out that the histodifferentiation of the maternal stromal cells at day 66 of pregnancy, which suggested a synthetic ability for these cells, was represented in the current study by the increase in the size of the cells; euchromatic content of their nuclei; elaboration of the cytoplasm especially after the elapse of the mid period of the pregnancy compared to day 20 of pregnancy which was considered part of implantation period which had occurred few days earlier i.e. at day 16; and decrease and sometimes absence of extracellular spaces between the maternal stromal cells. Such arrangement was analogous to the behavior of the stromal cells which become decidual cells in animals with haemochorial placentation. In these species of animal, the stromal endometrial cells used to be elicited, to become decidual cells, after receiving hormonal stimuli from trophoblastic cells which had invaded the maternal tissue (4,9).

The absence of maternal cells as a possible layer to intervene between maternal blood vessels and the synepitheliochorial layer was noted to occur from day 85 to day 125 of the present study. Several studies on ruminant placentation (8,15,16), as clear in this work, had pointed out that the second half of pregnancy was usually characterized by increase the demand for rapid feto-maternal nutritional exchange through the maternal and fetal circulation. The prerequisite for the reduction of the distance between the maternal and fetal circulation was achieved by absence of maternal stromal cells and indentation of the maternal blood vessels, which were here mostly in a form of capillaries, into both the trophoectoderm and the synepitheliochorial layer.

One of the interesting observations in the present study was the appearance of pericytes as a perivascular cells around maternal blood vessels at the level of capillaries. We had to point out that one of the functions attributed to the pericytes was to enhance the trafficking of nutritive material from the inside of the capillaries to the outside. Here it was helped by the embracing of the pericytes and their foot processes to the endothelial cells and the presence of contractile filaments in the cytoplasm of the pericytes (17). In this work as in previous studies on goat placenta (17) had presented an increase in percentage of capillaries with pericytes during the second half of pregnancy in the goat. In fact, there was no chance of any possible increase in the size of the fetus without the presence of a concomitant increase in the number of capillaries and the reduction in the distance between the fetal and maternal circulation (18,19). The appearance and disappearance of the stromal cells from the scene of the placentome in the goat remain an enigma. It was well established that the placentomal tissues have increased tremendously as the pregnancy was advancing (2).

In summary the present study revealed a central role played by the maternal stromal cells in the first half of pregnancy in the goat, while their disappearance during the second half of pregnancy was required to accelerate the feto-maternal exchange of nutrition by reducing the distance between the fetal and maternal circulation.

REFERENCES

1. Wynn, R. M. (1973). Ultrastructural development of the human deciduas. Am. J. Obstetric Gynecol.; 18:652-670.
2. Steven, D. H. (1975). Comparative placentation. pp 123-185 Ist. Edition. New York: Academic Press.
3. Soma, H.; Murai ,N., Tanaka, K.; Oguro, T.; Kokuba, H., Yoshihama; I.; Fujita; K., Mineo, S.; Toda, M.; Uchida, S.; Mogoe, T.(2013) Review: Exploration of placentation from human beings to ocean-living species. Placenta.;34 Suppl:S17-23.
4. Finn, C. A. (1977). The implantation reaction. In Wynn, R, M, editor. Biology of uterus. New York: Plenum Press. pp. 245-308.
5. Eveline, P.C.; De Ruk, T. and Esch, V. (2008). The Macaque placenta: A mini review. Toxo. pathol.; 36:108S-118S.
6. Vercruyse, L.; Caluwerts, S.; Luyten, C.; Pinenborg, R. (2006). Interstitial trophoblastic invasion in the deciduas and mesometrial triangle during the last third of pregnancy in the rat. Plac.; 27:22-33.
7. Parr, M. B.; Tung, H. N. and Parr, E. L. (1986). The ultrastructure of the rat primary decidual zone. Am. J. Anat.; 176:423-436.
8. Wooding, F.B.P. and Burton, G. (2008). Comparative placentation: Structure, Function and evolution. 2nd Edition. PP: 35-80;185-202. Springer, Verlage, Berlin.
9. Dunn, D.L.; Kelly, R.W. and Critchley, H.O.D. (2003). Decidualization of the human endometrial stromal cell: an enigmatic transformation. Reproductive Biomedicine.7(2):151-161.
10. Kleinfeld, R.G.; Morrow, H. and DeFeo, V.J. (1976). Intercellular junctions between decidual cells in the growing deciduoma of the pseudopregnant rat uterus. Biol. Reprod. 1976. Dec;15(5):593-603.
11. Zhao, Y.; Xu, H.; Narisu, Z.Z.; Mao, J.; Guan, D. and Chang, Xie. C. (2015). Polymorphisms of *osteopontin* gene and their association with placental efficiency and prolificacy in goats. J. of Applied Animal research, vol. 43(3) pages 272-278.
12. Karnovsky, M.J. (1965). A formaldehyde- gluteraldehyde fixative of high Osmolarity for use in electron microscopy. J. Cell Biol. ,27(2):137A-138A.
13. Nishiyama, H. *et al.* (2010). Atmospheric scanning electron microscope observes cells and tissues in open medium through silicon nitride film. J. Struct. Biol. 169, 438–449.
14. Wooding, F.B.P. (1982) The role of binucleate cells in ruminant placental structure. J. Reprod. Fertil. ,31: 31-39.
15. Igwebuike, U.M. (2006). Trophoblast cells of ruminant placentas: A mini review. Anim. Reprod. Sci.,93(3-4):185-198.
16. Borghesi, J.; Mario, L.C.; Rodrigues, M.N.; Favaron, P.W. and Mgilino, M.A. (2014). Immunoglobulin transport during gestation in domestic animals and human. A review. Open J. of Anim. Sci. ,4:323-336.
17. Yasear, A.Y. and Zoubie, S. (2003). Morphological study on the pericytes of goat's placentomal capillaries. Egypt. J. Anat., 26(2):1-11.
18. Bartels, N. and Baumann, F. (1972). Preplacental gas exchanges. In Respiratory gas exchange and blood flow in the placenta. Eds. Longo, LD and Bartels, N., U.S. government Printing office. Washigton, D.C., pp:1-12.
19. Frith, A.L.; Naved, R.T.; Persson, L.A.; Rasmussen, K.M. and Frongillo, E.A. (2012). Early participation in a prenatal food supplementation program ameliorates the negative association of food insecurity with quality of maternal-infant interaction. J. Nutr.;142(6):1095-2011.