

## **The investigation of the presence *Esherishia coli* associated with broilerarthritis in Kerbala governorate**

**التحري عن وجود اشريشيا القولونية المصاحبة لالتهاب مفاصل دجاج اللحم في محافظة كربلاء**

**Hayder Ali Muhammid<sup>a</sup>**

**<sup>a</sup>Department of Microbiology, College of Vet. Medicine, Kerbala University, Kerbala, Iraq.**

**E-mail: [drhayder93@gmail.com](mailto:drhayder93@gmail.com)**

### **Abstract**

The study was conducted to investigate the etiology of the bacterium *Esherishia coli* by culturing, antimicrobial susceptibility test and diagnosing the bacteria that exist in synovial secretion in an infected broiler arthritis. A total of 35 ankle joint discharge were collected from broiler 18-22 days ages suffering from arthritis isolated from broiler chicken at Kerbala governorate, Iraq, through period of four months beginning from December 2014 till the end March 2015, in an attempt to detect the bacterium *Esherishia coli*. The results showed that out of thirty-five ankle joint samples, there were fourteen bacterium isolates as *Esherishia coli*. In conclusion, the incidence of some arthritis in broiler chicken contain *Esherishia coli* that may play important risk in arthritis, Simultaneously, as in the case of the use of antibiotics, Ciprofloxacin has been considered as an effective treatment for *Esherishia coli* in vitro susceptibility, but no resistant 100% for Amoxycyline against all *Esherishia coli* isolates.

### **الخلاصة**

أجريت هذه الدراسة للتحري عن وجود المسبب لبكتيريا اشريشيا قولونية بواسطة الزرع، اختبار للمضادات الحياتية وتشخيص هذه البكتيريا الموجودة في إفراز الزليلي في فروج اللحم المصاب بالتهاب المفاصل. تم جمع ما مجموعه 35 عينة من مفصل كاحل فروج اللحم من عمر يتراوح 18-22 يوم يعانون من التهاب المفاصل في محافظة كربلاء، العراق، اثناء مدة أربعة أشهر ابتداء من ديسمبر 2014 حتى نهاية مارس 2015، في محاولة للكشف عن البكتيريا اشريشيا القولونية. وقد أظهرت النتائج أن من بين خمس وثلاثون مفصل كاحل، كانت أربعة عشر بكتيريا معزولة ك اشريشيا القولونية. الاستنتاجات، ان الإصابة ببعض التهاب المفاصل في الدجاج اللحم يحتوي على اشريشيا القولونية التي يمكن أن تلعب دور مهم في التهاب المفاصل، في نفس الوقت كما هو الحال بالنسبة لاستخدام المضادات الحيوية، فقد اعتبر سيبروفلوكساسين كعلاج فعال حساس ضد بكتيريا اشريشيا القولونية في المختبر ، ولكن لا يوجد مقاومة 100٪ للاموكسيسيلين ضد كل اعداد اشريشيا القولونية المعزولة.

### **Introduction:**

The genus *Escherichia* composed of several species, but only *E. coli* is an important pathogen of animals. This species, the major facultative gram-negative species comprising the normal flora of the gastrointestinal tract, may be the cause of septicemic disease in foals, calves, piglets, puppies, and lambs; and enterotoxigenic diarrhea in newborn farm animals; It may also be opportunistic in almost all animal species (1). lameness and leg weakness were prominent economic and welfare concerns among chicken producers, Lameness in chickens have several causes including bacterial and viral infections of cartilage and bones (2). Bacterial arthritis in poultry after septicemia or localized is reported to be associated with *Erysipelothrix*, *Listeria*, *Mycoplasma*, *Staphylococcus*, *Enterococcus* and *Escherichia* (3, 4). Infections of *Escherichia spp.* may result in a respiratory disease from air sac infection, a septicemic blood disease from generalized infections, an enteritis from intestinal infection or a combination of any or all of these conditions like *Mycoplasma gallisepticum* infections causing air sac disease syndrome (5), this study was aimed to

detect some bacterial like *E.coli* which play important as causative agent in the ankle joint of the broiler chickens.

### **Materials and methods**

The specimens were collected from two farms and consisted of broiler chickens . At one of the series of broiler chickens, avian infectious synovitis was suspected. For the confirmation of diagnosis, this study had performed anatomical and bacteriological examinations. The anatomical examination was made in the farm and the bacteriological exam was made in laboratory department of Microbiology at Kerbala University, The anatomical examination was made on chicken cadavers by using sharp tool to see the first symptoms of arthritis at the 18-22 days ages according to ankle joint color, size and shape (6), while synovial secretion was labeled and transmitted by sterile container directly to laboratory.

### **Samples Collection:**

A total of 35 ankle joint opening specimens were collected from broiler suffering from arthritis who were presented to Kerbala farm, 200 µl of synovial secretion was placed in 5 ml of nutrient broth, labeled and transported to the laboratory in portable container, then incubated for 18-24 hrs at 37 °C. This study was conducted during the period that extended from December 2014 to March 2015.

### **Isolation of *Escherichia coli*:**

A loopful of nutrient broth culture was streaked on surface of Eosin Methylene Blue, MacConkey agar plates and then incubated at 37 °C for 24 hrs . The biochemical characters of lactose fermenting bacteria was determined by using IMViC test such as Triple Sugar Iron Agar, Ciment Citare, Voges-Proskauer and Indole test according to the Jose *et al.*,(7).

### **Antimicrobials Susceptibility Testing:**

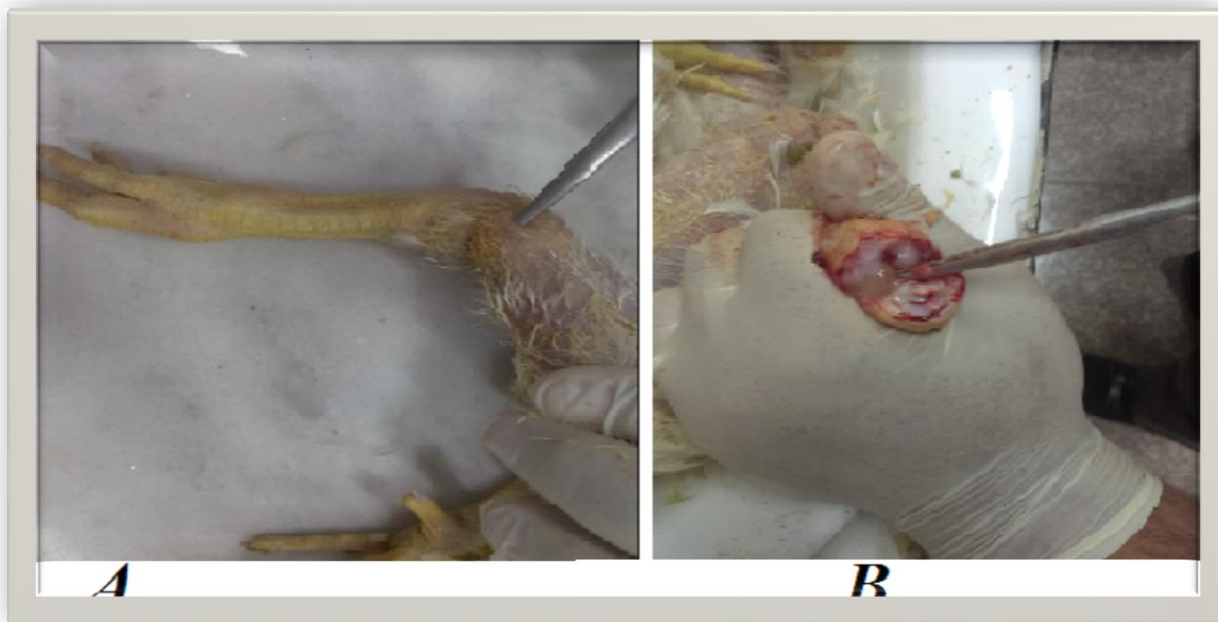The antimicrobial susceptibility testing for bacterium colonies were done by the agar discs diffusion method after solution of of Macferland Standard was prepared according to the Baron *et al.*,(8). by using five antimicrobial disc like (Amoxicillin, Gentamycin Chloromphenicol, Ciprofloxacin and Neomycin).

### **Statistical analysis**

The chi-square test was recommended by Daniel (9) for statistical analysis to show if there is any significant differences.

### **Results and Discussions:**

*Escherichia coli* infections were widely distributed among poultry of all ages and categories, They are primarily related to poor hygienic conditions, neglected technological requirements and immunosuppressive diseases. Of the total samples, 14/35 (40%) were culture positive for *Escherichia coli*. A common sequel of navel infections were arthritis in farm, The study showed the destination of macroscopically examining as one Leg of broiler was swelled in ankle joint At the level of ages 18-22 days, the gross lesions was represented as 'pus forming, white to red crystals' areas of gaseous exudates around the broiler joint (10) when it's opening by a sterile sharp object (figure1).

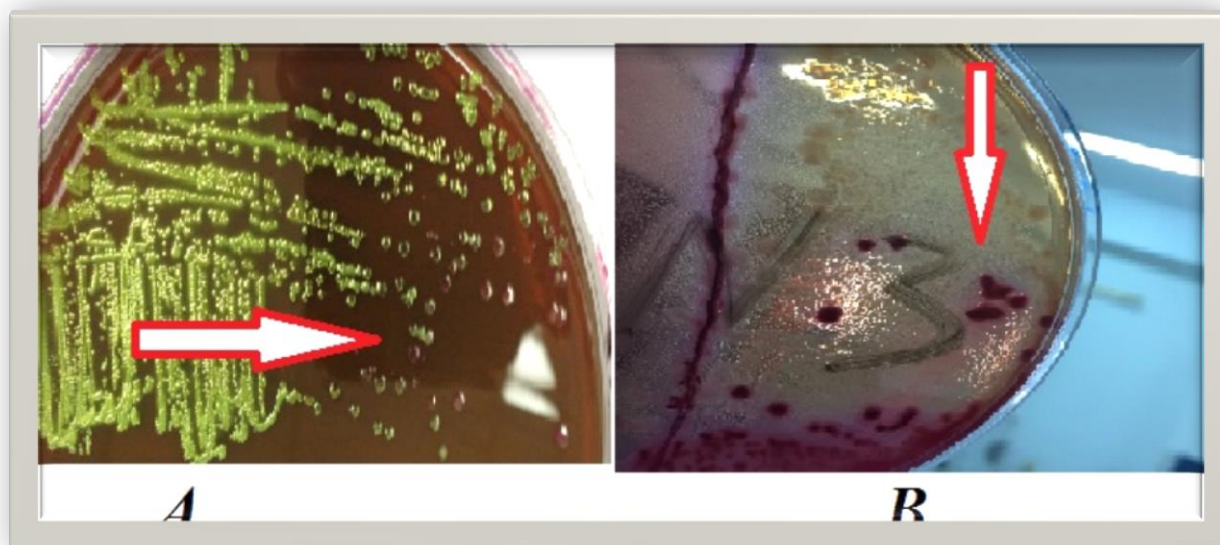


**(Figure 1) A: broiler, 18 days old. Note enlargement of ankle joint in the proximal end of femur B: proximal femoral degenerative changes with pus discharge.**

there's more than one expectation point about the causes of swelling of ankle joint may be the retention of fluid in leg tissues which is known as peripheral edema. It can be caused by a problem with the circulatory system, the lymphatic system or the kidneys due to fluid buildup after sitting or standing for a long time (11).

They are many factors which varying greatly in seriousness that can cause leg swelling, one of the most important thing is bacterial infection, e.g. *E.coli*, It is very likely that these bacteria colonize the physes of growing bones and provoke an inflammatory response that is further causing osteomyelitis (12).

Recent systematic studies of cause s of lameness in birds was reared in Iraq, therefore in this study commercial broilers showed that long bone deformities, on other hand the results showed during the screening process of culturing methods that out of 35 ankle joint samples, forty percentage were positive for *E.coli*, using the conventional culture methods on enrichment and selective media, The colonies of *E.coli*. on EMB agar were small, smooth, circular, and this colonies was grew with a metallic sheen appearances (Figure 2 A), while was pale in color with black center, circule, convex and smooth on Macconkey agar (Figure 2 B) (13) Although the use of all these media for the detection of presumptive coliform organisms e.g. *E.coli* was based on the fermentation of lactose, the characteristic reaction varies with each medium depending on the basic ingredients.



**(Figure 2) A: the arrow showed colonies of *E.coli* On EMB agar as metallic sheen colonies, B: the arrow showed colonies of *E.coli*. on M.A agar as Pink colonies with lactose fermentation colonies.**

The biochemical tests for all isolates showed positive results to Indole, carbohydrate fermentation, , methyl red and also the results confirm as negative reactions for citrate utilization, Voges-Proskauer test, (8).

By using the disc diffusion method, 14 isolates of *Escherishia coli*. were tested for their antimicrobial susceptibility toward 5 antibiotics, All tested isolates showed high susceptibility (100 %) toward ciprofloxacin and high resistance (100 %) against amoxicillin and half of isolates was sensitive to Gentamicin. On the other hand, these isolates revealed varying percentages of susceptibility and resistance toward other antibiotics like gentamicin and neomycin.

antibiotic	Sensitive		X <sup>2</sup> value
	isolates	%	
Ciprofloxacin	14	100	Cal.X <sup>2</sup> =34.8
Neomycin	9	64.2	Tab. X <sup>2</sup> =29.4
Amoxicillin	0	0	df= 4
Gentamicin	7	50	Significant
Chloramphenicol	11	78.5	(p<0.01)

**Table (1): Antimicrobials susceptibility testing of *Escherichia coli*. toward certain antibiotics using discs diffusion method.**

All bacterial isolates testing were found to be very sensitive to ciprofloxacin due to the mode of action of all quinolones involves inhibition of bacterial DNA synthesis by blocking of the DNA gyrase and lead to Supercoiling inhibition results for ciprofloxacin(14) but demonstrated some resistance against certain Neomycin depending on protein inhibition drugs and some of strain resistant against it may be associate the resistance were under the control of transmissible plasmids or the presence of markers for class 1 integrons (15). Pathogenic *Escherichia coli* isolates obtained from diseased poultry exhibited multiple-antibiotic resistance to tetracycline, oxytetracycline, streptomycin, sulfonamides, and gentamicin(16).

Regarding, Chloramphenicol it was a potent inhibitor of protein synthesis in microorganisms, It blocks the attachment of amino acids to the nascent peptide chain on the 50S unit of ribosomes by interfering with the action of peptidyl transferase(17).

There are many different mechanisms by which *Escherichia coli* might exhibit resistance to Amoxicillin, the most important of them were Microorganisms produce enzymes that destroy the active drug by producing B-lactamase (18). In conclusion, *E coli* was shown to be regarded as a causative agent arthritis in broiler chickens.

### **References:**

- 1- Lupp, C. and Finlay, B. B.(2005). Intestinal microbiota. *Curr. Biol.*, 15, 235-6.
- 2- McNamee, P. T.; McCullagh, J. J.; Thorp, B. H.; Ball, H. J.; Graham, D.; McCullough, S. J.; McConaghy, D. Smyth, J. A. (1998). Study of leg weakness in two commercial broiler flocks. *Vet Rec.* 143(5):131-135.
- 3- Armour, N. K.; Collet, S. R. and Williams, S. M. (2011). ‘*Enterococcus cecorum*-related arthritis and osteomyelitis in broilers and broiler breeders’, *The Poultry Informed Professional* 117, 1–7.
- 4- Aziz, T. and Barnes, H. J.(2007). ‘Is spondylitis an emerging disease of broilers?’, *World Poultry* 23, 44–45.
- 5- Sivaseelan, S. and Balasubramaniam, G. A.(2013).Predisposing effect of *E.coli* to *Mycoplasma gallisepticum* infection in layer chicken.*Shanlax International Journal of Veterinary Science.*1:1-5.
- 6- Walker, E. R.; Friedman, M. H.; Olson, N. O. and De Nee, P. B. (2005). Ultrastructural Study of Avian Synovium Infected with an Arthrotropic Reovirus. *Arthritis & Rheumatism.*20(6):1269-1277.
- 7- Jose L. A.; Adela, A.; Oscar, O.; Inmaculada, A. and Hemda, G.(1999 ). Comparison and Recovery of *Escherichia coli* and Thermotolerant Coliforms in Water with a Chromogenic Medium Incubated at 41 and 44.5°C. *APPLIED AND ENVIRONMENTAL MICROBIOLOGY* .65(8):3746–3749.
- 8- Baron, E. T. and Finegold, S. (1990). *Bailey and Scott’s Diagnostic Microbiology*. 8th ed. The Mosby Company . U.S.A.
- 9- Daniël, L.(2010). Calculating and reporting effect sizes to facilitate cumulative science: a practical primer for t-tests and ANOVAs, *Front Psychol*, 4: 863.
- 10- McNamee, P. T. and Smyth, J. A.(2000). Bacterial chondronecrosis with osteomyelitis (“femoral head necrosis”) of broiler chickens: a review. *Avian Pathol*29,477–495.
- 11- Chanock, A. M. and Lawton, M. P. C.(1981). The urogenital system. In Price, J.(eds). *The Kidney*, Philadelphia, Co. Pp1023-1055.
- 12- Jingrang, L. u.; Susan, S.; Charles H.; John J. M.; Barry, G. H. and Margie D. L.(2003). Evaluation of Broiler Litter with Reference to the Microbial Composition as Assessed by Using 16S rRNA and Functional Gene Markers. *Appl Environ Microbiol.* 69 (2): 901–908.
- 13- Leboffe, M. J., and B. E. Pierce. 2005. *A photographic atlas for microbiology laboratory*, 3rd ed. Morton Publishing, Englewood, CO.

- 14- Heddle, J. G.; Barnard, F. M.; Wentzell, L. M. and Maxwell, A.(2000). The interaction of drugs with DNA gyrase: a model for the molecular basis of quinolone action. *Nucleosides Nucleotides Nucleic Acids*. 19:1249–1264.
- 15- artinez-Freijo P.; Fluit, A. C.; Schmitz F.J.; Grek, V. S. C.; Verhoef, J. and Jones, M. E.(1998). Class I integrons in Gram-negative isolates from different European hospitals and association with decreased susceptibility to multiple antibiotic compounds. *J. Antimicrob. Chemother*, 42:689–696.
- 16- Lydia, B.; Cynthia, A.; Liebert, M. D.; Lee, A. O.; Summers, D. G. White, S. G. Thayer, G. and John J. M.(1999). Incidence and Characterization of Integrons, Genetic Elements Mediating Multiple-Drug Resistance, in Avian *Escherichia coli*. *Antimicrob Agents Chemother*. 1999 Dec; 43(12): 2925–2929.
- 17- Murray, I. A. and Shaw, W. V. (1997). O-acetyltransferases for chloramphenicol and other natural products. *Antimicrob. Agents Chemother*. 41:1–6.
- 18- Bush, K. (2003). Beta-lactam antibiotics: Penicillins. Pages 224–258 in *Antibiotic and Chemotherapy: Anti-infective agents and their use in therapy*. Finch, R. G. ; Greenwood, D.; Norrby, S. R. and Whitley, R. J., ed. Churchill Livingstone, Edinburgh , UK .