

# Histological modulation of adult rat's thyroid in response to anti-oxidant factor

Samia A. Eleiwe<sup>1</sup> MSc, Hayder J. Mobarak<sup>2</sup> PhD, A. A. Al-Taii<sup>2</sup> PhD.

---

---

## **Abstract**

**Background:** The pineal neurohormone namely melatonin regulates the bodily endocrine glands including thyroid gland, by controlling the function of pituitary gland.

**Objective:** To study the effects of different doses of dietary melatonin (as antioxidant) on male rat's thyroid, "histologically".

**Methods:** Melatonin was supplied to adult Wister albino rats, for successive 14 days. Rats were divided into 6 groups. Group I was the control. Group II, III, IV, V and VI were given a daily dose of 125, 250, 500, 750 and 1000 µg / kg body weight, respectively. After last day of treatment, animals were killed under effect of anesthesia and thyroid gland was taken for histological study.

**Results:** The results showed no significant effects on thyroid with the regarded as normal therapeutic dosages, whereas significant damaging effects were seen with the higher doses.

**Conclusion:** Dietary melatonin has no bad effect on adult rat's thyroid within therapeutic doses, but it had highly damaging changes in large doses.

**Keywords:** Thyroid, melatonin, anti-oxidant, and endocrine.

IRAQI J MED SCI, 2008; VOL.6 (1):74-80

---

---

## **Introduction**

Melatonin is the principal pineal neuro-hormone <sup>(1)</sup>. It regulates every bodily hormone by regulating the function of pituitary in a rhythmic manner <sup>(2)</sup>. The free radical theory of damaging events concluded that any stress process is caused by free radical oxidative agents, and this fact has been well investigated within the context of oxidant/antioxidant balance <sup>(3)</sup>. Melatonin is at the top of many dietary antioxidants; such as vitamin E, glutathione and strawberry extract. Antioxidants from food sources appear to be promising for prevention of most stressful events <sup>(4)</sup>.

Thyroid gland is an important member in the endocrine system, and

its diseases can lead to serious consequences for human health <sup>(5 & 6)</sup>, hence the study of protective role of anti-oxidative agent (such as melatonin) is continuous and could provide a new strategies for the management of many important thyroid related diseases, which might be extremely useful in the context of endocrine-therapy and pharmacology planning in favor of human wellness <sup>(7)</sup>.

## **Materials and methods**

Adult male Wister albino rats, 48 in number, were used in this work. They were kept in an animal room, with a temperature ranging between 20 -24 C°, the light - dark cycle was 12:12. They fed a control pellet diet with free access to food, except for one and half hour prior to melatonin containing meal. Dietary melatonin was provided as a single daily dose, 2 hours prior to sundown. Water was offered *ad libitum*.

Animals were divided into 6 groups, each consisting of 8 rats. Group

---

<sup>1</sup>Dept. Anatomy, Histology, and Embryology, College of Medicine Al-Mustansiriya University, <sup>2</sup>Dept. Anatomy, Histology, and Embryology, College of Medicine Al-Nahrain University.

Address Correspondences to: Dr, Ali Abdul-Sattar. Al-Taii

Received: 21<sup>st</sup> June 2007, Accepted: 29<sup>th</sup> October 2007.

I was the control: rats were provided with the same type of drug containing meal, but no drug was added (placebo), though, they were also deprived from food one and half hour prior to the time of treatment as other groups. Group II, III, IV, V and VI were given dietary melatonin as a single daily dose of 125, 250, 500, 750 and 1000 µg/kg body weight, in sequence, mixed with their food, for fourteen successive days. In this study the doses of drug was regarded to be given in a low or high dose according to previous studies<sup>(8, 9, 10 & 11)</sup>.

After the last day of treatment, all animals were killed by dissection under effect of diethyl ether. The whole thyroid gland was removed, separated from the surrounding connective tissues under a dissecting microscope, weighed by an electric sensitive balance and used for paraffin section, using Bouin's solution for fixation and (Haematoxylin & Eosin) for staining<sup>(12)</sup>, then 5 serial sections of 3 µm thickness from the mid- part of the organ were studied by light microscopy.

Histological study was done both as descriptive and morphometric. The morphometric analysis was estimated by using Zeiss Integrating Micrometer – disk Turret I of 25 point - system, used on a light microscope: which measures the relative surface area by counting the points superimposed through a disk put on the microscopic eye piece during slide examination, so the number of these points positively related to the relative measurement of the surface area<sup>(13 & 14)</sup>, the total points falling on each thyroid follicle's wall, as well as lumen, were calculated. From each section 5 fields were taken randomly examined at 150X magnification. All the values were taken as mean ± SD of 8 rats. The significance of difference between each of treated groups and its control was evaluated by student – t – test (15).

## **Results**

Descriptive and morphometric studies for all groups were done, as follows:

Body weight: There was no significant effect on the over all body weight ( $P > 0.05$ ) as shown in (table 1).

Thyroid weight was not affected significantly in group II, III, and IV whereas it was significantly affected (increased) in group V and VI (table 2). Morphometric results:

(1) The number of points (superimposed through the Micrometer – disk Turret) overlying the epithelial wall of the acini (follicles), was significantly unaffected till the dose of 500µg/kg, then it was significantly decreased at the dose of 750µg/kg, and a great increase was clear at group received 1000 µg/kg (Table3).

(2) The number of points superimposed on the lumen of the acini, followed an opposite manner to that of the wall (Table3).

The descriptive histological result:

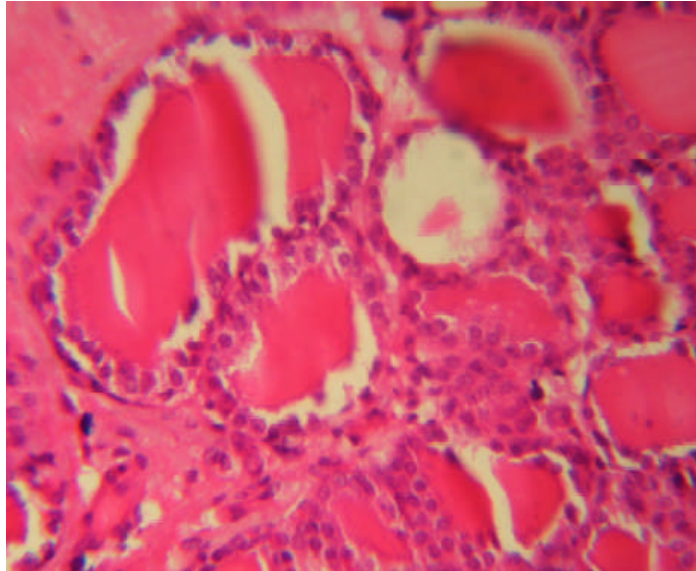
Cells of the epithelial wall of thyroid acini, in the groups treated with 125, 250, and 500µg/kg were almost very similar to those of the control group; so each acinus was bound by a single layer of specialized thyroid epithelium which rest on a thin basement membrane and enclosed a lumen filled with thyroid colloid (a pink staining homogenous material). Some acini had squamous epithelium; other acini had cuboidal or low columnar epithelium in the same given area (Fig.1).

In groups received 750 µg/kg dose, cells were seen commonly as flattened squamous epithelium lined the acini which were filled by pink thyroid colloid with no vacuoles at the peripheries of their lumens between the colloid and epithelial cells (Fig.2).

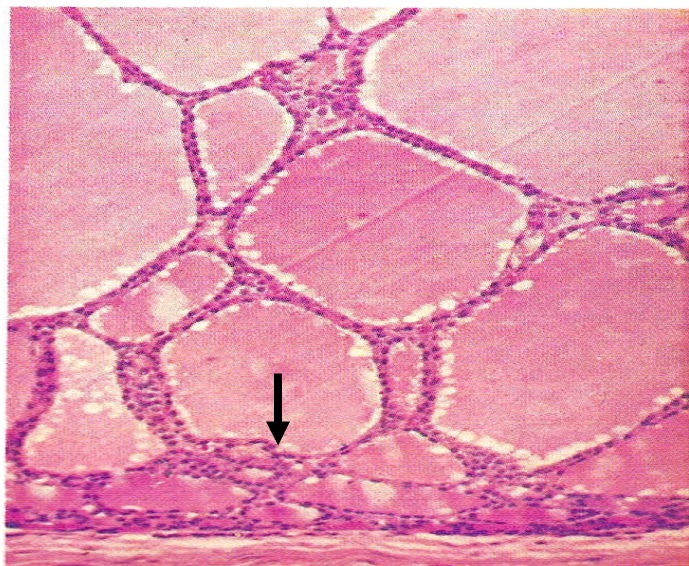
The group treated with 1000 µg / kg dose: The thyroid acini were viewed with thickened basement membrane.

There was abundance in the number of thyroid epithelial cells and they appeared to be taller (Fig.3). The acini were looked smaller with less amount

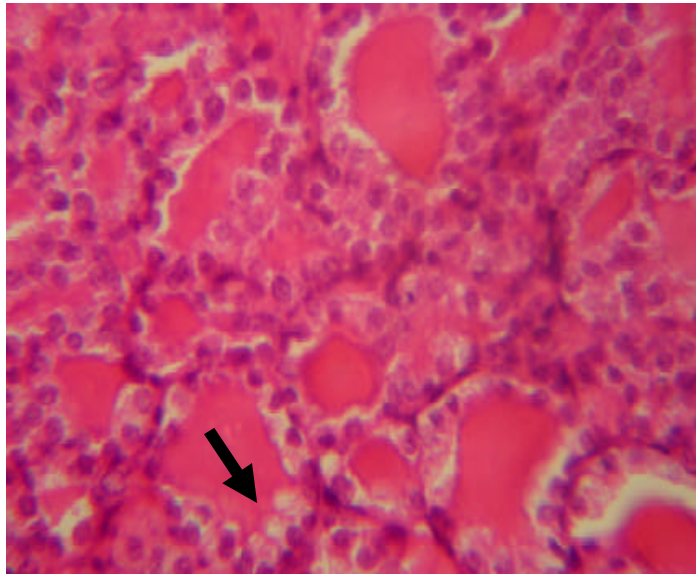
of colloid and the edges of the colloid were scalloped (Fig.4).



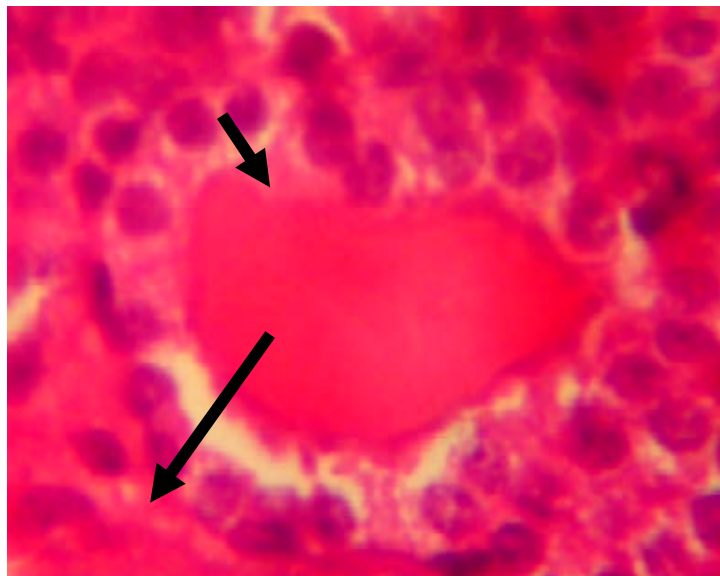
**Figure 1: Thyroid tissues in control group of male rat H&E stain X100**



**Figure 2: Thyroid acinus in male rat treated with 750µg/kg melatonin. The epithelial acinar cells are thin and almost squamous (arrow), H&E stain X100**



**Figure 3: Thyroid tissues in male rat treated with 1000 $\mu$ g/kg melatonin: edges of colloid are scalloped (arrow), H&E stain X100**



**Figure 4: Thyroid acinus in male rat treated with 1000 $\mu$ g/kg melatonin: the columnar epithelium rest on thick basement membrane (arrow), H&E stain X400**

**Table 1: The effect of dietary melatonin on body weight (Grams) of 8 wk old male rats.**

<i>dose of Daily melatonin (µ/kg) body weight</i>	<i>Body wt of rats at 1<sup>st</sup> day of experiment</i>	<i>Body wt of rats at last day of experiment</i>
Control	343.00±2.9	423.71±5.1
125	345.00±3.9	416.11±4.6 NS
250	343.25±2.9	425.24±5.1 NS
500	346.00±2.8	413.06±4.9 NS
750	345.25±4.6	418.25±9.7 NS
1000	345.50±5.1	416.57±8.2 NS

-Results were expressed in mean ± SD of 8 rats.

-All differences were statistically not significant =NS, (P>0.05) when compared with its control.

**Table2: Effect of melatonin on thyroid weight of adult male rats.**

<i>Daily dose of melatonin (µg/kg body weight)</i>	<i>Thyroid weight at autopsy (mg)</i>
Control	19.14±2.33
125	20.17±3.17 NS
250	21.09±3.09 NS
500	19.18±2.98 NS
750	24.13±4.46*
1000	25.16±5.13**

-Results were expressed in mean± SD of 8 rats

-The difference of each dose group was statistically significant when compared with its control (\* P<0.0003; \*\* P<0.0001; NS not significant).

**Table3: Number of points (seen through the Micrometer – disk Turret) overlying the thyroid acini wall and lumen of adult rats treated with dietary melatonin (in unit area of 0.0025mm<sup>2</sup>).**

<i>Daily dose of melatonin in µg/kg body wt</i>	<i>Points on thyroid acini wall</i>	<i>Points on thyroid acini lumen</i>
Control	14.18±1.14	8.86±1.22
125	14.91±1.41 NS	9.41±1.32 NS
250	14.26±1.21 NS	9.35±1.24 NS
500	14.67±1.12 NS	9.21±1.33 NS
750	11.27±1.22*	12.24±1.24***
1000	21.11±1.13**	6.12±1.14***

-Data were expressed as mean ± SD of 8 rats.

-When any dose-group was compared with its control, the differences were statistically significant (\* P<0.00004; \*\* P<0.00001; \*\*\* P<0.001 NS= non significant).

### **Discussion**

There were no changes in the body weight of rats in all groups, this might be explained by the fact that exogenous melatonin causes no effect on the overall body weight in rats<sup>(16 & 17)</sup>. This is probably because the food intake in rats does not affected by melatonin administration<sup>(18)</sup>. The effect of melatonin on thyroid tissues could be explained by the fact that melatonin acts through specific receptors in all body tissues<sup>(19)</sup>. Once melatonin reaches any bodily tissue it exerts its action immediately, and melatonin has a dose – dependent physiologic action<sup>(20)</sup> so this is why in the low doses 125, 250 and 500µg/kg, no significant effect was noticed, while with higher doses 750 and 1000 µg/kg there was an obvious histological modification which leded certainly to a physiological disturbance, because the function of thyroid acini, is determined from its size, height of the lining epithelium and the amount of its colloid<sup>(1 & 5)</sup>. Those results could be explained by the fact that melatonin has damaging effects only when it is administered in high doses<sup>(20 & 21)</sup>.

The thickening of the basement membrane could be resulted from the increase in production of fibrocollagenous tissues, since melatonin hormone has special effect on fibroblasts<sup>(22 & 23)</sup>, which are the active collagen – secreting cells and the basic forming cells of the connective tissues<sup>(1)</sup>.

The group treated with the dose of 750µg/kg has the histological figure very similar to that of the hypothyroidism; i.e. large acini lined by a layer of almost flattened squamous glandular cells, together with abundance of colloid which are known histopathological features of hypothyroidism, and a decrease in the thyroid secretion level<sup>(1, 5 & 6)</sup>. The cause for that hypothyroidism might be

the vast stimulation of thyroid gland by that high dose of melatonin which stimulated the hypothalamic- pituitary- thyroid axis, thence a large quantity of thyroid hormone especially thyroxin was secreted and accumulated within the thyroid acini that gave a view quite similar to thyroid hypofunction status<sup>(5 & 6)</sup>. In group V and VI (table 2): in both groups the gland weight was increased although they showed different histological picture, which could be explained by the fact that any thyroid disorder may induces its enlargement whether there is hypothyroidism or hyperthyroidism<sup>(1 & 6)</sup>.

The shrink and regression in the amount of thyroid colloid was so clear at dose of 1000µg/kg, that might be discussed by the fact that melatonin over dosage may stimulate the anterior pituitary to produce thyroid stimulating hormone (TSH) which leads to massive stimulation of thyroid gland to secrete its hormones, mainly thyroxin (T4) and tri-iodothyronine (T3), so this would give the histological appearance very similar to thyroid tissues of group VI (8). The acini were looked smaller with less amount of colloid and the edges of the colloid were scalloped (Fig.4) indicating an active reuptake of thyroid secretion (5). All the destructive and damaging effects could be due to sustained time of treatment, because the effect of melatonin may differ with duration of administrated course<sup>(24)</sup>. In this study the doses of 125, 250 and 500µg/kg were regarded as therapeutic doses since no destructive effects were highlighted with those doses, and it is well documented that any drug would be considered to be given within therapeutic dose if that dose has no bad effect<sup>(25 & 26)</sup>. In this study the doses of drug was regarded to be given in a low or high dose according to previous studies<sup>(8, 9, 10, & 11)</sup>.

## **References**

1. Standerling S, Ellis H, Healy J C, Johnson D, and Williams A . Editors: Pineal gland in: GRAY'S Anatomy. 39<sup>th</sup> ed. Elsevier Churchill Livingstone. 2005; P 384-5.
2. Bubenik G A, Pang S F, Cockshut J R, Smith P S, Grovum L V, Friendship R M, and Hacker R R. Circadian variation of portal, arterial and venous blood levels of melatonin in pigs & its relationship to food intake and sleep. *Journal of pineal Research*. 2000; 28 (1): 9-15.
3. Brotto L A and Gorzalka B B. Melatonin enhances sexual behavior in the male rat. *Physiological behavior*. 2000; 68 (4): 483-6.
4. Meydani M. Dietary antioxidants modulation of aging and immune-endothelial cell interaction. *Mech.-Aging-Dev*. 1999; 111, (3-3): 123-32.
5. Stevens A and Lowe J. Melatonin in. *Human Histology*, 2<sup>nd</sup> ed. Mosby, an imprint of times Mirror International Publishers Limited. 1997; P 258, 117-135, 85.
6. Kumar V, Abbas A K, and Fausto N. Melatonin in. *Robbins and Cotran Pathologic Basis of Diseases*, 7<sup>th</sup> Ed. Elsevier Saunders; 2005; P 880.
7. Karbownik M, Stasiak M, Zasada K, Zygmunt A, and Lewinski A. A Comparison of potential protective effects of melatonin, indole-3-propionic acid, and propylthiouracil against lipid peroxidation caused by potassium bromate in the thyroid gland. *J-Cell-Biochem*. 2005; 95 (1): 131-8.
8. Fernandez Alvarez C, Diaz Rodriguez E, Pazo Vinuesa D, Esquifino Parras A, Marin Fernandez B, Diaz, and Lopez B. In vitro pituitary responsiveness to LHRH in young and old female rats. Influence of melatonin. *Mech-Aging- Dev*. 1999; 7; 112(1): 75-83.
9. Mazepa R C, Cuevas M J, Collado P S, Gonzalez and Gallego J. Melatonin increases muscle and liver glycogen content in non exercised and exercised rats. *Life- Sci*. 2000; 66 (2): 153-60.
10. Song G H, Gwee K A, Moochhala S M, and Ho K Y. Melatonin attenuate stress-induced defecation: lesson from a rat model of stress-induced gut dysfunction. *Neurogastroenterol-Motil*. 2005; 17(5): 744-50.
11. Korde J P, Srivastava R S, Mishra S C, and Sharma A K. Time dependent immunomodulatory response of exogenous melatonin to killed *Pasteurella multocida* (P52 strain) vaccine in albino rats. *Indian-J-Physiol-Pharmacol*. 2005; 49 (2): 227-35.
12. Baker F J, Silverton R E, Pallister C J. Baker & Silverton's Introduction to Medical Laboratory Technology, 7<sup>th</sup> ed. UK; www Arnoldpublisher Comp. 1998; P. 182-242.
13. Aheme W A and Dunnill M S. Morphometry. Edward Arnold. London. 1982; p 33-45, 19-32.
14. Weibel E R, Kistler G S, and Scherle W F. Practical stereological methods for morphometric cytology. *J. Cell Biol*. 1966; 30: 23-37.
15. Daniel W W, Biostatistics. A Foundation for analysis in the health sciences, 8th ed. (Ed.W.W.Daniel) New York: John Wiley. 2005; P 273-295.
16. Maestroni G J M, and Conti A . Anti-stress role of melatonin-Immuno-opioid network: Evidence for a physiological mechanism involving T-cell derived immuno-reactive beta-endorphin and met-enkephalin binding to thymic opioid receptors. *International J. of Neuroscience*. 1991 ;( B), 19 (61): 289-298.
17. Cajochen C, Krauchi K, and Wirz, Justice A. Role of melatonin in the regulation of human circadian rhythm and sleep. *Neuroendocrinol*. 2003; Apr; 15 (4): 432-7.
18. Wolden Hanson T, Mitton D R, McCants R L, Yallon S M, Wilkinson C W, Matsumoto A M, and Rasmussen D D . Daily melatonin administration to middle aged male rats suppresses body weight, intra-abdominal adiposity, and plasma leptin and insulin independent of food intake and total body fat. *Endocrinology*. 2000; 141 (4): 487-97.
19. Witt Enderby P A and Li P K. Melatonin receptors and ligands. *Vitam-Horm*, 2000; 58: 321-54.
20. Forsling M L, Wheeler M J, and Williams A J . The effect of melatonin administration on pituitary hormone secretion in man. *Clinical Endocrinology- Oxf*, 1999; 51(5): 637-42.
21. Kim J K and Lee C J. Effect of exogenous melatonin on the ovarian follicles in gamma-irradiated mouse. *Mutat-Res J*, 2000; 3: 449(1-2)33-9.
22. Fawcett D W. Fibroblasts and fibrocytes in. Bloom and Fawcett: A Text Book of Histology, 11 ed. Saunders Company: 1986; P155-61.
23. Wang Q, McEwen D G, and Ornitz D M . Subcellular and developmental expression of alternatively spliced forms of fibroblast growth factor- 14. *Mech-Dev*, 2000; Feb; 90 (2): 283-7.
24. Peltier M R, Robinson G, and Sharp D C. Effect of melatonin implants in pony mares 2. Long-term effects. *Theriogenology*, 1998; 15; 49(6): 1125-42.
25. Wolsky A. Drugs in. Research Animals and Concept of Applicability to Clinical Medicine. Vol.7, S. Karger: 1982; p 105.
26. Ebadi M. Drugs in. Pharmacology An Illustrated Review with Questions and Explanations, 3<sup>rd</sup> ed. A Little Brown Book, 1996; P231-45.