

Abdominal cocoon – A rare cause of sub acute intestinal obstruction – a case report.

Hasan K. Gatea*

FICMS

Faik T.Al-Gailani**

DMRD

Abstract

Fac Med Baghdad
2011; Vol. 53, No.1
Received Oct.2010
Accepted Nov. 2010

This is a case report of abdominal cocoon also referred to as sclerosing encapsulating peritonitis in 32 year – old female patient who presented to us with history of recurrent abdominal pain, constipation and vomiting one to two attacks per week, each attack continued for four to six hour and resolved spontaneously. Preoperative diagnosis depends on a high index of suspicion, ultra sound and CT scan examinations are the most helpful tool of investigation in these patients.

Treatment consist of excision of the encapsulating membrane with lyses of the inter loop adhesion.

Keywords: Abdominal cocoon (AC),Sclerosing encapsulating peritonitis(SEP)

Introduction:

Abdominal cocoon (AC) or sclerosing encapsulating peritonitis (SEP) is a rare condition of unknown cause in which intestinal obstruction results from the encasement of variable lengths (partial or total) of bowel by a dense fibro-collagenous membrane that give the appearance of cocoon leading to clustering of the small bowel, and thus may cause intestinal obstruction. It is commonly seen in young adolescent girls in tropical & subtropical region (1).

Foo et al reported 10 such cases in 1978 and introduced the term – abdominal cocoon to describe this clinical entity (2)

Case presentations

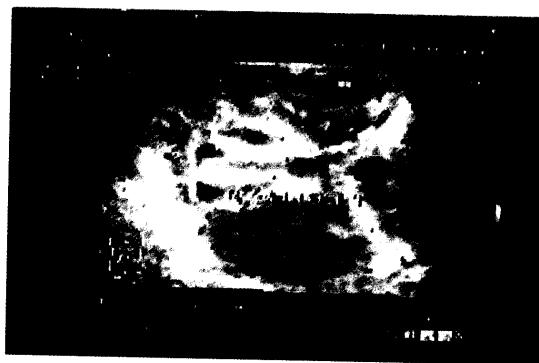A 32 year old female presented to Al.Mustansiria hospital in August 2010, complaining from intermittent attacks of vomiting and colicky abdominal pain for 7 days. She had history of four caesarian section. Last caesarian section was six months ago that was complicated by fever, ascites and left pleural effusion on the third day following surgery this complication settled rapidly with appropriate antibiotics. The fever subsided and ascites with pleural effusion disappeared gradually Two months after caesarian section the patient complained from recurrent abdominal colic and she felt abdominal mass when lying in prone position during sleep. Her investigations at that time revealed nothing abnormal. For the last two months the patient was admitted to the hospital many times complaining from intolerable abdominal pain one to two attacks per week ,each attack continue for four to six hour not responding to analgesia but resolved spontaneously. On examination, she was comfortable in bed and hamodynamically stable, her abdomen was not distended, non-tender with exaggerated bowel sound No palpable abdominal mass or organomegaly could be felt and no external hernias were present. Plain abdominal x-ray showed no air fluid level, sono- graphic examination of the abdomen revealed: Encapsulated dilated small bowel loops ,forming mass like appearance(13.8 X 10.9cm)at mid abdomen

to the right side ,suggesting peritoneal adhesion figure(1). Abdominal enhanced CT examination showed matted and dilated small bowel loops encased by a capsule figure (2).

Although symptoms of obstruction had abated, the history of multiple relapses, the patient's complaints for poor quality of life and multiple admissions, as well as the undefined origin of the underlying pathology led to an explorative laparotomy.

Laparotomy was revealed a fibrous capsule converging all the abdominal viscera, in which small bowel loops were encased totally with the presence of interloop adhesions. The liver, stomach, appendix, right and left colon, as well the sigmoid were also covered and the greater momentum looked hypo plastic and encased in fibrous tissue (figure 3), mild ascites was noted. Incision and excision of most of the thick membranes which were encasing the small bowl loops was performed without bowel resection figure (4). histopathological examination of the excised membrane showed marked fibrosis and extensive chronic inflammation with necrosis..

The diagnosis of idiopathic sclerosing encapsulating peritonitis (abdominal cocoon) was established by intraoperative findings and by ruling out any other..



condition explaining the patient's pathology.
Figure (1) Sonographic Picture

*Dept. of Surgery, College of medicine, Baghdad University, Iraq

** Dept. of radiology, Al-Mustansiria hospital

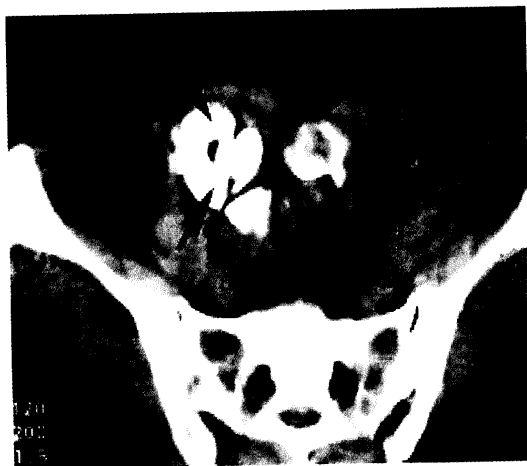

Figure (2) CT Section

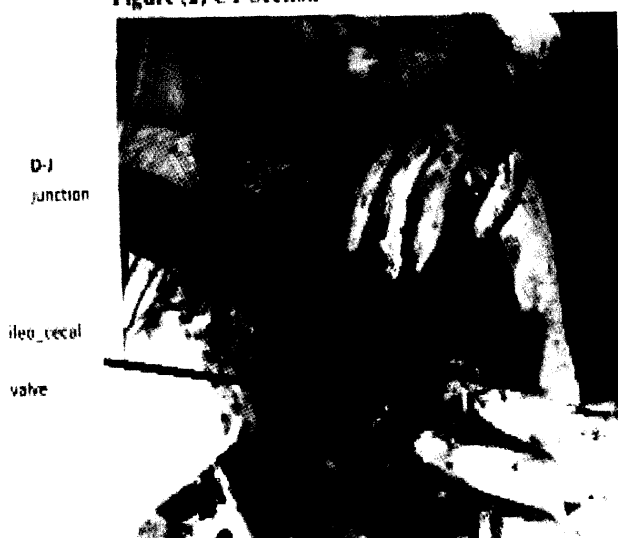


Figure (3)
The whole small bowel encased by thick membrane

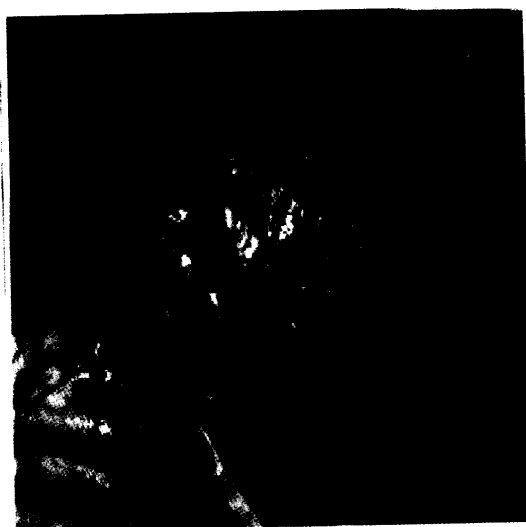

Figure (4)
After excision of the membrane and lysis of interloop adhesion

Discussion:

Abdominal cocoon is a rare acquired condition most often idiopathic that refers to partial or total encapsulation of the small bowel by fibro-collagenous membrane or cocoon with local inflammatory infiltrate leading to acute or chronic bowel obstruction (1,2) it is classified as primary and secondary. Injury to, or irritation of, the peritoneal mesothelium is considered to be the initial stimulus for SEP in susceptible individuals, this is followed by florid reactive hyperplasia of the mesenchymal cells, producing a thick layer of fibroconnective tissues (3)

The condition we report was characterized by history of ascites and fever responding to antibiotic which may act as initial stimulus for SEP, as well as that the gynecologist might have used povidine iodine in abdominal wash.

sclerosing peritonitis is seen in patients undergoing peritoneal dialysis(4). Several factors have been reported to be responsible for this condition: the use of hypertonic glucose, disinfectant such as chlorhexidine and povidine iodine, catheters (5) and B. adrenergic blocking agent were reported to be causes in other cases (6). Association with various tumors also described: with gastric cancer, ovarian thecoma, ovarian teratoma, pancreatic carcinoma and renal carcinoma where the sclerosing peritonitis might be a paraneoplastic phenomenon(7). A severe episode of peritonitis, particularly pseudomonad or fungal, often precedes the onset of encapsulating peritonitis (8).

Abdominal cocoon usually present with variety of clinical presentation, recurrent attacks of sub acute intestinal obstruction with colicky abdominal pain, progressive nausea and vomiting (9) should raise suspicion regarding the diagnosis with abdominal distension which usually present in a case of partial small bowel encapsulation due to proximal bowel dilatation or with out abdominal distension.

The four main clinical features that help identify abdominal cocoon pre – operatively as suggested by Yip include intestinal obstruction presenting with abdominal pain and vomiting occurring in a relatively young girl, without obvious cause, history of similar episodes that resolved spontaneously, and the presence of a non-tender soft mass on abdominal palpation, but rarely all four cardinal symptoms are found (10)

Clinically, most patients with abdominal cocoon present with features of acute or chronic small bowel obstruction secondary to kinking and/or compression of the intestines within the constricting cocoon(2)

Abdominal ultrasound examination may show loops of bowel entrapped in a capsule. The presence of a thick peritoneal layer anterior to the small bowel is characteristic (11,12) as in this patient we report.

The imaging features are not pathognomic .It has been observed that CT findings of a membrane enveloping loops of small bowel were seen in some paradouenal hernias, abdominal cocoon, and in peritoneal encapsulation. However, clinical and

pathological features of these entities are different.

This report is of a patient with an abdominal cocoon, and is intended to raise awareness of this diagnosis and its imaging characteristics. This should enable earlier preoperative diagnosis and prevent unnecessary bowel resection.

Reference:

- 1-Muktachand L. Rokade, Mitosh Rupard:
Abdominal cocoon. JcII 2007; 25.4 204 – 206
- 2-Foo KT, Ngkc, Raufi A, etal. *Unusual small intestinal obstruction adolescent girls; the abdominal cocoon. B,J Surg 1978; 65:427*
- 3-Aisling E. Courtney and Ciaran e. Doherty. *Fulminate sclerosing peritonitis immediately following acute bacterial peritonitis. Nephrol Dial Transplant (2006) 21(10) 532 – 534*
- 4-zuyoshiO, YoshihikoO, ToshinoriO, etal. *Sclerosing encapsulating peritonitis: regional changes of peritoneum. Nephron 2002;92:481-483*
- 5- Yamamoto S, Sato Y. *Sclerosing encapsulating peritonitis in two patients with liver cirrhosis. J Gastroenterol 2004; 39(2); 172-5*
- 6- Norihiro O., et al. *Abdominal cocoon in an aged man: Report of a case. Surgery Today 2007, 37: 258 – 260*
- 7- peritoneal sclerosis: *Semis Dial 2000; 13(5): 297-308*
- 8- pepels, etal. *Sclerosing peritonitis in a patient with SLE The nether land Journal of Medicine 2006; 64(9) 346-9*
- 9- Cohen O, Abrahamson J, Ben – Ari J, etal. *Sclerosing encapsulating peritonitis, primary and secondary forms. J Clin Gastroenterol 1996, 2: 201 – 6*
- 10- Yip WK, Lee SH. *The abdominal cocoon. Aust N Z J Surg 1992; 62: 638 – 642.*
- 11- Deeb Ls, Mourad FH, El-Zein YR, etal. *Abdominal cocoon in a man: preoperative diagnosis and literature review. J Clin Gastroenterol 1998, 26: 148-50*
- 12- Al-Abbasi A, Emad M. *Abdominal cocoon: an unusual cause of intestinal obstruction. Saudi Med J 2004 25(10): 1482 – 5*