

Immunopathological Study of *Fasciola Hepatica* and Hydatid Fluid Antigens on Hydatid Cysts development in Mice

Eman J. Al-Malki¹ MSc, Enaam B. Faleh² PhD, Eman Gh. Khalil³ PhD

¹College of Veterinary Medicine, Karbala University, ²College of Veterinary Medicine, Baghdad University, ³College of Engineering, Al Nahrain University

Abstract

Background Hydatidosis is a chronic cyst forming helminthic disease of human, domestic and wild animals. The immune responses play a pivotal role in limiting cystic larval development.

Objective To investigate the immunopathological effects of *Fasciola hepatica* antigens (FHAg) and hydatid cyst fluid antigens (HCFAg) on the immune response against hydatidosis in mice.

Methods One hundred mice were divided into 5 groups; the 1st three were immunized subcutaneously with 0.2 ml of HCFAg, FHAg and mixed antigen (MAG = HCFAg+FHAg), respectively. The last two regarded as control groups. On day 27 post immunization, the skin test was done for the 1st four groups. On day 30, half the animals of each group were sacrificed to perform E-rosette test, agar gel diffusion (AGD), and ELISA test. The rest of the mice with the 5th group were challenged with 2000 viable protoscolex / mouse. After 3 months, they were sacrificed for gross and histopathological examination.

Results The immunized group with MAG was hypersensitive prior to challenge the skin test, while E-rosette test indicated the highest ratio of active lymphocytes before and after challenge in comparison with other groups. The AGD test showed severe reaction between the sera of mice immunized with MAG against the FHAg against HCFAg and between sera of immunized group with FHAg against HCFAg and vice versa. The highest level of antibodies was recorded in the immunized group with MAG. Histopathological examination for the internal organs of immunized groups revealed granulomatous lesions, reduction in the number of cysts with lymphocytic hyperplasia and presence of degenerative protoscolices. Control infected group revealed growth of cysts in the internal organs, with degenerative and necrotic lesions.

Conclusion The 3 types of Ags stimulate humoral and cellular immunity was proved by immune-histopathological investigations. The MAG was highly immunogenic in comparison with each Ag alone. This antigenic activity may be due to the presence of synergistic interactions and cross-reactivity between the 2 parasites and this can be used as protective value against hydatidosis in the intermediate hosts.

Keywords Parasitic infections, immunological cross reaction, isolation parasitic antigens, *Fasciola hepatica* antigens, Hydatid fluid antigens.

List of abbreviation: CE = cystic echinococcosis, AE = alveolar echinococcosis, Ags = antigens, Ab = antibodies, HC = hydatid cyst, PSC = protoscolices, HCFAg = HC fluid antigen, FHAg = *Fasciola hepatica* antigen, MAG = mixed antigen, PBS = phosphate buffered saline, SFHFAg = soluble filtrated hydatid fluid antigens, SFHAg = sonicated *Fasciola hepatica* antigens, SSFHAgs = soluble sonicated *Fasciola hepatica* antigens, NO = nitric oxide.

Introduction

Echinococcosis is a zoonotic parasitic disease caused by the adult or larval stages of the cestodes belong to the

genus *Echinococcus* (family Taeniidae). Larval infection (hydatid disease, hydatidosis) is a chronic cyst forming helminthic disease of human beings as well as domestic and wild animals ⁽¹⁾. The important medical and public species are *Echinococcus granulosus*, and *Echinococcus multilocularis*, which cause cystic echinococcosis (CE) and alveolar echinococcosis (AE), both are serious diseases ⁽²⁾. The AE

especially with poor prognosis if careful clinical management is not conducted^(2,3).

The immune responses play a pivotal role in limiting cystic larval development. Lightowlers *et al*⁽⁴⁾ reported that the vaccine conferred a high degree of protection against challenge with different geographical isolates of *Echinococcus granulosus* (*E. granulosus*). Then results indicate that vaccine could have wide applicability as a new tool for use in hydatid disease control campaigns⁽⁵⁾.

In another experiment, Hashemi and Razmi⁽⁶⁾ reported that the antigens (Ags) of whole body of *E. granulosus*, might be a good candidate for immunization and diagnosis of hydatid cyst (HC) in an intermediated host. *Fasciola hepatica* (*F. hepatica*) has a wide distribution especially in Iraq, and sometimes there is mixed infection of hydatidosis and fascioliasis; and in an attempt to suggest a defined vaccine against HCs and *F. hepatica* infection, this study were designed⁽⁷⁾.

The aims of current study are to evaluate the role of *F. hepatica* Ags and hydatid fluid Ags against HC infection in mice by performing immuno-pathological studies plus the correlation and assessment of the immunological and the pathological changes with the 3 types of Ags that used for immunization to get a good candidate for immunization and diagnosis of HC in the intermediate hosts.

Methods

Laboratory animals

Total number of (100) mice (BALB/C) of both genders ranged 4-6 weeks old, and weighted between 19-24 g. They were divided into five groups; each group had 20 mice, 1st, 2nd and 3rd groups were immunized with HC fluid Ag (HCFAg), *Fasciola hepatica* Ag (FHAg) and mixed Ag (MAg) respectively, 4th and 5th groups were considered as control groups, both treated with phosphate buffered saline (PBS), then the fifth infected with HC and was left for 3 months.

Preparation of Ags

Hydatid cyst fluid antigens

According to Moosa and Abdel-Hafez⁽⁸⁾, four hundred ml of hydatid fluid was aseptically aspirated from 35 fertile HCs lodged in sheep livers. The fluid containing protoscolices (PSC) and membrane fragments was pooled and centrifuged at 5000 g for 30 minutes at 4 °C to precipitate PSCs. The supernatant was dialyzed and processed according to McVie *et al*⁽⁹⁾ to get HCFags. The protein concentration was measured using UV-visible spectrophotometer at wave lengths 280 and 260 nm, respectively, it was 3.3 mg/ml. HCFAg antigens was stored at -20 °C till use (immunization), and 20 ml of antigens was centrifuged with ultra cold centrifuge (13000 rpm for 30 minute), supernatant was called soluble filtrated HFAG (SFHFAG) was stored at -20°C till use for skin test.

Fasciola hepatica Antigens

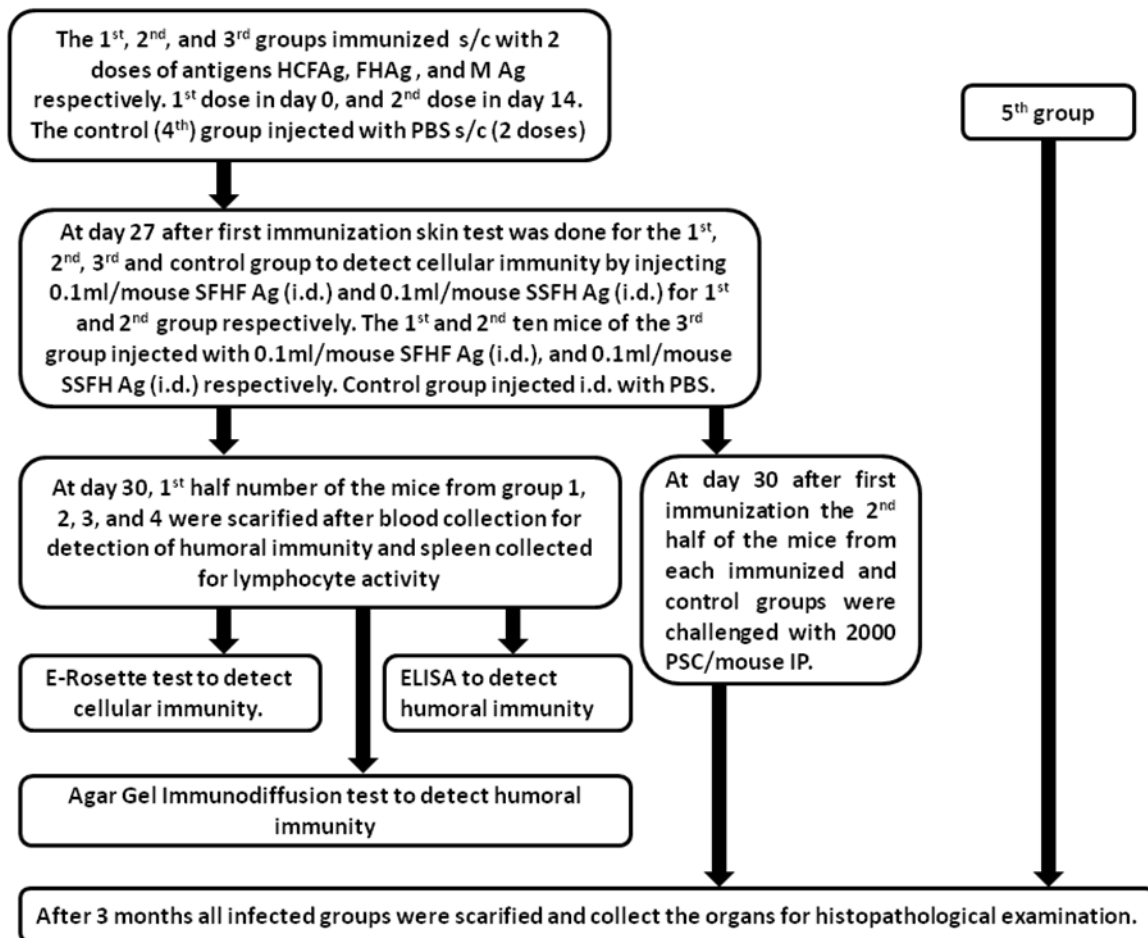
Thirty-five adult flukes were collected from livers samples of sheep infected with fascioliasis. The worms were identified morphologically according to Threadgold⁽¹⁰⁾. They were washed and homogenized in PBS pH 7.4 using an electrical homogenizer (ultra-turrax) and processed according to Abdel-Rahman *et al*⁽¹¹⁾ to get sonicated *Fasciola hepatica* antigens (SFHAg). Protein concentration was 4.1mg/ml using UV-visible spectrophotometer at wave length 280 nm, 260 nm respectively, then it was diluted with distal water in order to make its concentration 3.3 mg/ml. SFH Ags was stored in a deep freezer until use. Fifteen ml of the supernatant was centrifuged with ultra cold centrifuge at 13000rpm for 30 min, to get soluble sonicated FHAg (SSFH Ags) then was stored at -20 °C till use.

Preparation of protoscolices and estimating the challenge dose

PSCs were collected aseptically from 10 fertile *E. granulosus* cysts, size (4-6 cm) from the liver of infected sheep. The collected PSCs were washed in PBS (PH7.4) containing 100 µg/ml of gentamycin, then the viability and the quantity of PSCs was determined according to Morel⁽¹²⁾.

Experimental design

One hundred mice divided into five groups as shown in the box below:



Delayed type hypersensitivity test

Delayed type hypersensitivity test was done according to Ohta et al ⁽¹³⁾ for the all animals at 27th day post immunization as shown in fig.1.

Erythrocytes -Rosette test

This test was performed according to Braganza et al ⁽¹⁴⁾ to evaluate the viability and the activity of isolated T-lymphocytes from blood of immunized and control groups.

Agar gel diffusion test

This test was done according to Bombardier and Ggiordano ⁽¹⁵⁾. 50 µl of pooled sera from each group of mice were isolated from their blood samples, they were diluted serially (1:50, 1:100, 1:200) in carbonate-bicarbonate buffer. Also 10 µl from each antigen was diluted serially (1:2, 1:4, 1:8). Best dilutions for the sera and antigens that gave visible precipitate line in the agar gel diffusion test were used in enzyme linked immunosorbent assay (ELISA) ⁽¹⁶⁾.

Enzyme Linked Immunosorbent Assay

Determination of specific antibodies was carried out as described by Ferragut and Nieto ⁽¹⁷⁾, with simple modifications briefly, 96-well microtitration plate was coated with 200 µl/well of antigens (HCF, FH or Mix) diluted 1:8 in carbonate-bicarbonate buffer pH 9.6 and incubated over night at 4 °C in a humid chamber. Excess antigen was removed and washing the wells four times with PBS – Tween 20 pH 7.4, and blotting by using a filter paper, then blocking was done with 200 µl of 1% Bovine serum albumin in PBS at 37 °C for 1hr. Wells were dried, and added 200 µl/well diluted sera at a 1:200 dilution in PBS –T20 and incubated 2 hr at room temperature, the plate was washed with PBS – T20 as described above, 200 µl of freshly diluted conjugate (HRP-Goat anti mouse IgG) 1:10000 in diluent reagent 1% BSA-PBS was added in each well and incubated for 3hr at 37°C in humid chamber. The plate was washed as

described above to remove excess conjugate; 200µl of substrate solution (OPD and H₂O₂) was added to all well and left for 30 min in a dark place. The reaction was terminated by adding 50µl H₂SO₄ 2.5 M, the optical density was read on (630) nm with a by bio-tek micro plate reader (model 450).

Preparations of tissue sections

For histopathological study tissue samples were taken from internal organs of immunized and control groups. They were fixed in 10% formalin and processed routinely according to Bancroft and Steven⁽¹⁸⁾.

Statistical analysis

Data were analyzed statistically using the Microsoft Program (SPSS). Statistical analysis of data was performed on the basis of Two-Way Analysis of Variance (ANOVA) using a significant level of ($P < 0.05$). Specific group differences were determined using least significant differences (LSD) as described by Snedecor and Cochran⁽¹⁹⁾.

Results

The results of delayed type hypersensitivity showed a higher significant ($P < 0.05$) increase in the means of foot pad thickness of immunized groups as compared with the control. A higher increase of thickness detected in the mice treated with mixed antigen (HCFAg + FHAg) in comparison with immunized and control group as shown in table 1.

Table 1. Foot pad thickness of immunized and control groups at 27th day post immunization.

| Group | Skin test before challenge with PSCs | | |
|---------|--------------------------------------|------------------|----------------|
| | 24hr | 48hr | 72hr |
| Control | 1.8±0.1 A c | 1.8±0.1 A c | 1.8±0.1 A c |
| HCFAg | 2.4±0.2 B a | 3.7±0.2 A b | 3.4±0.2 A b |
| FHAg | 2.06±0.06 C b | 2.6±0.1 A b | 2.4±0.2 B b |
| MAg | 2.7±0.1 B a | 3.12±0.1 AB a | 3.4±0.2 A a |

HCFAg = Hydatid cyst fluid antigen, FHAg = *Fasciola hepatica* antigen, Mag = mixed antigen

The results of erythrocytes-Rosette test showed significant differences ($P < 0.05$) within the immunized groups, also between the immunized and the control groups, a higher stimulation (0.85 ± 0.05) observed in immunized mice with M Ag (Table 2).

Table 2. E-rosette formation after 18hr incubation in RPMI-1640 (before challenge)

| List | Group | E rosettes (% ± s.d.) |
|------|------------|-----------------------|
| 1 | FHAg | 0.37±0.05 |
| 2 | HCFAg | 0.59±0.06 |
| 3 | HCFAg+FHAg | 0.85±0.05 |
| 4 | Control | 0.25±0.06 |

HCFAg = Hydatid cyst fluid antigen, FHAg = *Fasciola hepatica* antigen

In the technique of agar gel diffusion test, diffusion of the antigen and anti-sera took place through the agar. Visible precipitin lines are formed in the gel at the point of equivalence. The results showed precipitin bands between sera of immunized mice with M Ag and the HCF Ags and FH Ags. Also precipitin bands observed between sera of infected mice with PSCs and HCF Ags and FH Ags (Fig. 1).

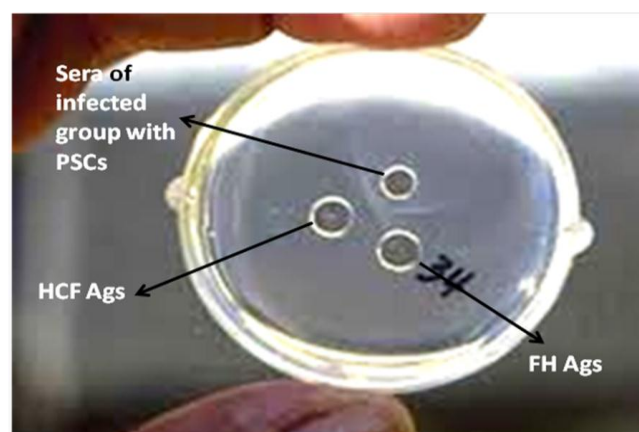


Fig. 1. Agar gel diffusion

ELISA of all immunized mice showed a strong response to the three antigens. The results reveal a significant difference ($P < 0.05$) between immunized and control groups. A higher level of

Abs (0.462 ± 0.009) is found in sera of mice immunized with M Ag (Table 3).

Table 3. Antibody titer (OD) in sera of immunized and control groups by ELISA

| List | Group | OD (mean±SE)nm/ml |
|------|---------|-------------------|
| 1 | FHAgS | 0.293±0.007 |
| 2 | HCFAgS | 0.272±0.004 |
| 3 | MAGS | 0.462±0.009 |
| 4 | Control | 0.06±0.004 |

HCFAg = Hydatid cyst fluid antigen, FHAg = *Fasciola hepatica* antigen, MAG = mixed antigen

Gross pathological changes

A number of secondary HCs were observed in mice 3 months post infection, unilocular white fluid filled cysts, measuring from 1-2mm mainly in liver and abdominal cavity (Fig. 2). No gross lesions were seen in the examined organs of immunized animals that were scarified after challenge except the presence of variable degrees of splenomegally and hepatomegally with congestion of some organs mainly in the immunized mice with MAG.

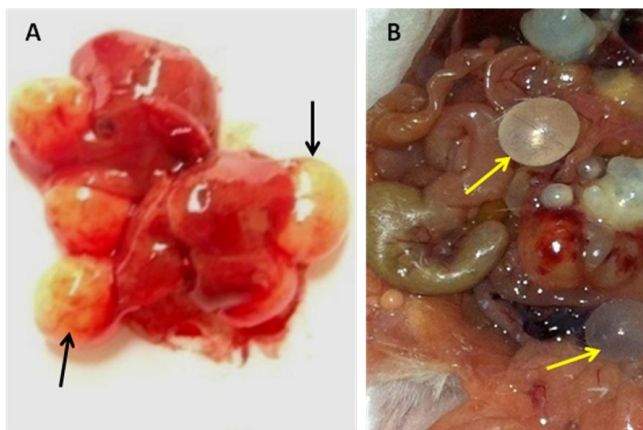


Fig. 2. Macroscopic examination of control group showed multiple unilocular, small secondary hydatid cysts on liver surface (A) and other internal organ (B) three months post challenge

Histopathological changes

In non-immunized infected animals (positive-control group) (Fig. 3) and immunized infected animals were found in different internal organs

as shown in fig. 2 through 10 which revealed appearance of HCs in the liver and other internal organs of control infected group, with focal and diffuse amyloid deposition in the spleen. The immunized groups revealed absence of cysts in the liver, presence of granulomatous lesions, appearance of degenerated PSCs, appearance of lymphoid proliferation in spleen and lung (BALT), suppurative pneumonia, and presence of extensive fibrous capsule in the spleen and kidney of mice immunized with M Ag.

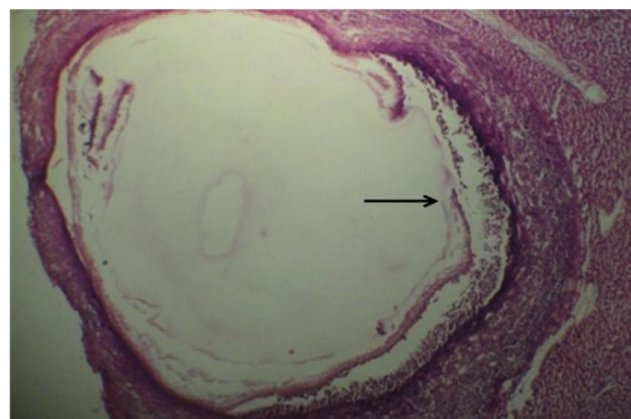


Fig. 3. Microscopical section in the hydatid cyst of control infected animal three months post challenge showed hydatid cyst with all three layers (germinative, laminated and adventitia (H&E X10)

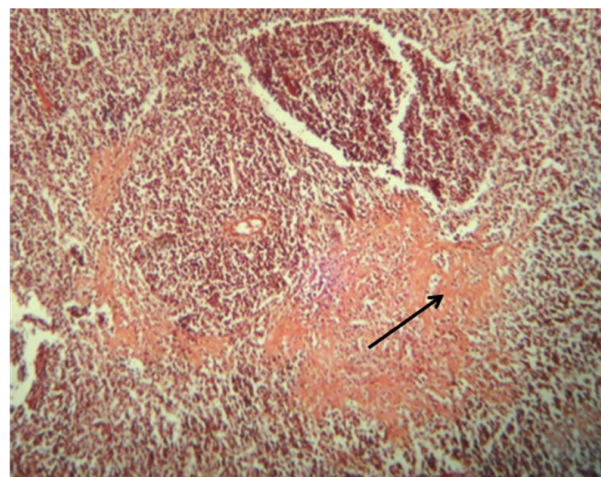


Fig. 4. Microscopical section in the spleen of control infected animals three months post challenge showed positive Congo red result (pale pink to red color) with focal and diffuse amyloid deposition (Congored X40).

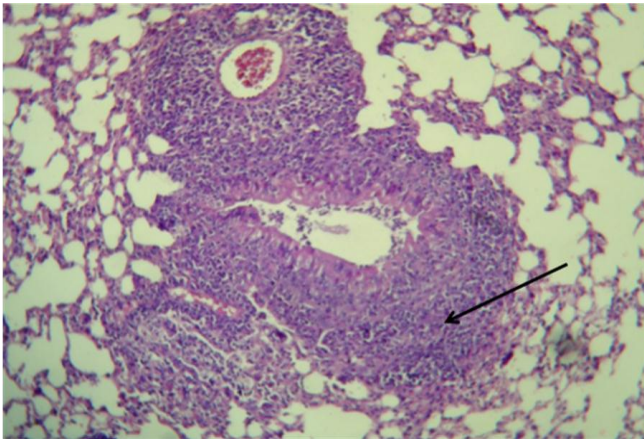


Fig. 5. Microscopical section in the lung of immunized mice with HCF Ags showed Hyperplasia peribronchiolar associated lymphoid tissue three months post-challenge (H&E X20).

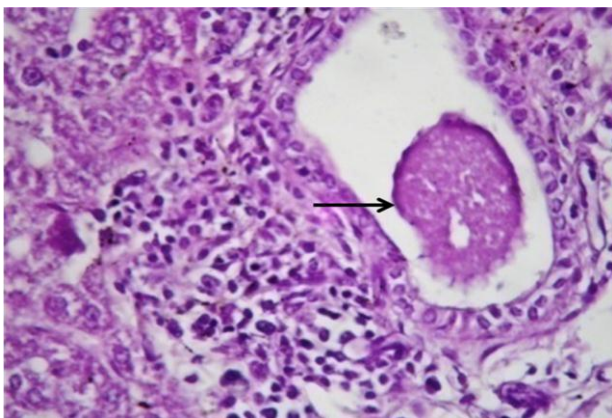


Fig. 6. Microscopical section in the liver of immunized animal with HCF Ags three months post challenge showed moderate MNCs aggregation in liver parenchyma mainly around dilated bile duct with appearance of degenerated protoscolex (H&E X40)

Discussion

Skin test (delayed type hypersensitivity-DTH)

We suggest that the parasitic Ags (immunization or mixed infection) synergistically interact with each other and probably an important influence on the immune system^(20,21). Also this could be due to presence of similar epitops in both parasitic Ags that is responsible for the cross-reactive effect against hydatidosis in sheep^(11,22). The formation of rosettes is a specific test for cells of T lineage. The results can be due to that

these antigens stimulate cellular immune response through activation of T-lymphocytes^(8,23).

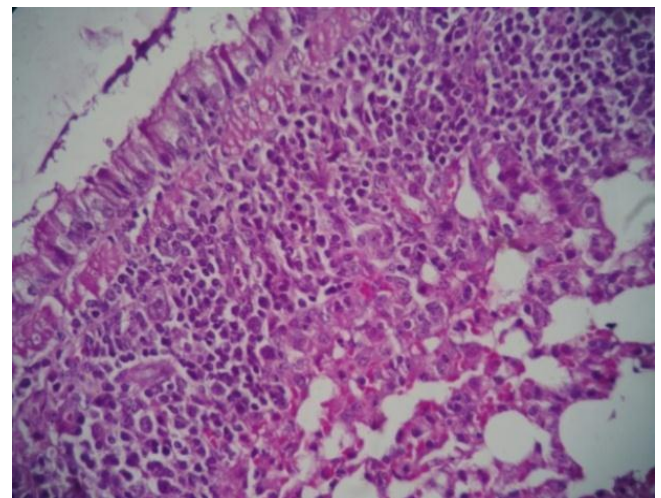


Fig. 7. Microscopic section in the lung of immunized animal with FH Ags showed suppurative pneumonia three months post challenge (H&E X40).

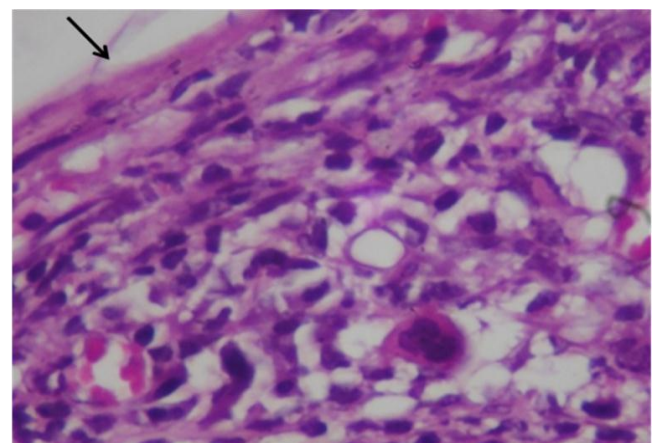


Fig. 8. Microscopical section in the spleen of immunized animal with M Ag, three months post challenge showed increase thickening of capsule with fibrosis together with congestion of red pulp (H&E X40)

The results of agar gel diffusion test may be due to the presence of common Ags in different parasites react against same antisera⁽²⁴⁾.

The results of ELISA were in agreement with Babba *et al*⁽²⁵⁾, Poretti *et al*⁽²⁶⁾, Lin *et al*⁽²⁷⁾, and Gaudier *et al*⁽²⁸⁾.

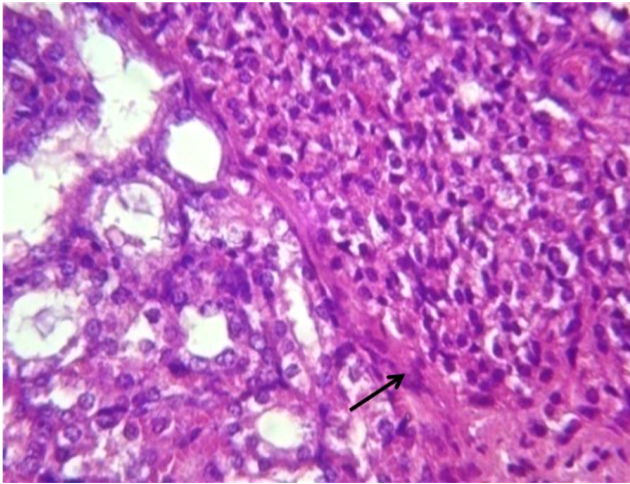


Fig. 9. Microscopical section in the kidney of immunized animal with M Ag three months post challenge showed increase Thickening of renal capsule with fibrosis (H&E X20)

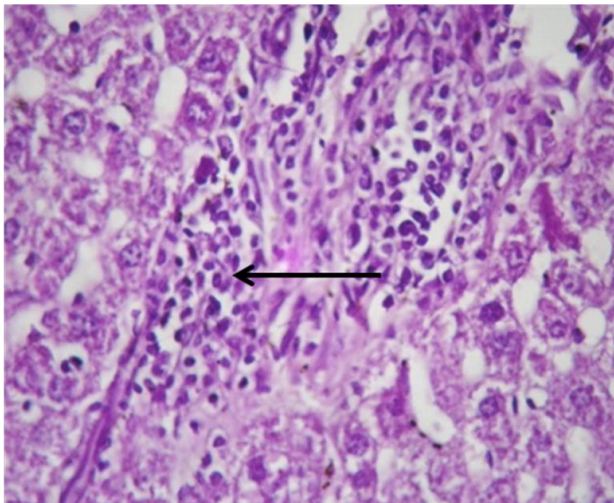


Fig. 10. Microscopical section in the liver of immunized animal with HCF Ag three months post challenge showed multifocal granulomatous lesion in liver parenchyma associated with vacuolar degeneration (H&E X40)

The results of this study proved a synergism and across reaction between two economically important zoonotic helminthes belong to different classes. This cross reaction was observed by ELISA in which Abs raised against one Ag cross reacted with the other antigens (11,20,21,22).

The appearance of HCs in the liver of control infected group associated with vacuolar and necrotic changes as well as atrophy of splenic

white pulp indicate that PSC reached the liver through the peritoneum where the parasite developed and overcome the host defense with its secretion of immune complexes that inhibit immune mechanism of infected host (29). The absence of cysts in the liver of immunized groups with HCF Ags and M Ag indicate that the immune response prevent the PSC to develop in the host (7). Vuitton (30) suggested that parasite may avoid the host immune system because of low immunogenicity by masking surface Ags as well as interfering with Ag-presenting mechanism.

As well as granulomatous lesion (Fig. 10) may also be seen in the examined organs at three months post challenge in the immunized groups due to the host defense mechanism which attempts to localize and destroy the PSC through inducing proliferation and aggregation of phagocytic cells mainly alternative activated macrophage which produce cytokines IL- 8 and IL-12. Also the present results reveal the appearance of degenerated PSCs in the liver of immunized group with HCF Ags (Fig. 6) this may be due to the crucial and important role of IL-12 in the inhibition of larval growth, and was originally termed natural killer cell (31). The appearance of lymphoid proliferation in spleen and lung (BALT) (Fig. 5) showed hyperplastic changes as a result to its persistent stimulation by HCF Ags especially 3 months P.I that revealed a good immune response following PSC infection which act as a mitogen stimulate lymphoid cells. Suppurative Pneumonia which was noticed in the present study (Fig. 7) may be due to the deposition of immune complexes as a result of pulmonary tissue injury (7,32).

The spleen revealed lymphoid depletion in the immunized group with *Fasciola hepatica* Ags, this may be due to the role of nitric oxide (NO), the FH excretory/secretory antigens decrease nitrate production by host peritoneal cells, a mechanism to avoid an immune response during the first stage of liver penetration. This could explain the transient suppression observed in spleen mononuclear cell proliferation response; on the other hand NO production could also be

one of the strategies of parasite to avoid potential killing effect of NO during peritoneal migration⁽³³⁾.

The presence of extensive fibrous capsule in the spleen (Fig. 8) and kidney of mice immunized with M antigen (Fig. 9) refers to the potential role of M antigen in activating and stimulating the host immune response and this capsule protects the host against PSCs effect that killed them before development so the results of kidney and spleen fibrosis would tend to cast doubt on the idea that the resistance developed against a challenge of PSC was due to physical barrier presented by extensive capsular fibrosis in kidney and spleen. In conclusion, this study showed that the three antigens (FHAg, HCFAg, and M Ag) stimulate both cellular and humoral immune response, and this is clear in the histopathological observations by preventing the development of HCs in the immunized group with 3 types of Ags. The mixed Ag gave high response for both humoral and cellular immunity. Using mixed Ag gave higher response or reactivity in skin test, E-rosette, ELISA and in agar gel diffusion, while other groups showed less response than the M Ag in comparison to control group due to the synergism and cross-reactivity between the two parasites.

Acknowledgment

I would like to thank Medical Research Unit staff, College of Medicine, Al-Nahrain University and Pathology staff in the College of Veterinary Medicine, Baghdad University.

Author contribution

Dr. Faleh suggests the study and reading the histopathological findings; Dr. Khalil performs the immunological part and Dr. Al-Maliki collects and identifies the parasites and preparing the antigens.

Conflict of Interest

No author declares any interest in publishing this article or competitive intentions.

Funding

Authors depend on self- funding.

References

1. Zhang S, Hue S, Sene D, et al. Expression of major histocompatibility complex class I chain-related molecule A, NKG2D, and transforming growth factor in the liver of humans with alveolar echinococcosis: new actors in the tolerance to parasites? *J Infect Dis.* 2008; 197: 1341-9.
2. Henkins RJ. Management of complicated hepatic hydatid cyst. *Ann Surg.* 1963; 158: 1020-34.
3. Zhang W, You H, Zhang Z, et al. Further studies on an intermediate host murine model showing that a primary *Echinococcus granulosus* infection is protective against subsequent oncospherical challenge. *Parasitol Int.* 2001; 50: 279-83.
4. Lightowers MW, Jensen O, Fernandez E, et al. Vaccination trials in Australia and Argentina confirm the effectiveness of the EG95 hydatid vaccine in sheep. *Int J Parasitol.* 1999; 29: 531-4.
5. Deger E, Hokelek M, Degerb A, et al. A new therapeutic approach for treatment of cystic echinococcosis: percutaneous albendazole sulphoxide injection without respiration. *Am J Gastroenterol.* 2000; 95(1): 248-54.
6. Hashemi Tabar GR, Razmi GR. Antibody response against hydatid fluid, protoscolex and whole body of *Echinococcus granulosus* antigens in lambs. *Iranian J Vet Res.* 2009; 10(28): 283-8.
7. Faleh BE. Parasitological pathological and immunological studies on hydatidosis in mice and goats and the use of heat in naturally occurring the treatment of lesions of hydatidosis in animals and man. PhD Thesis Veterinary College, University of Baghdad. 2002.
8. Moosa R, Abdel-Hafez SK. Serodiagnosis and seroepidemiology of human unilocular hydatidosis. *Parasitol Res.* 1994; 80: 664-71.
9. McVie A, Ersfeld K, Rogan MT. Expression and immunological characterization of *Echinococcus granulosus* recombinant antigen B for IgG4 subclass detection in human cystic Echinococcosis. *Acta Trop.* 1997; 67: 19-35.
10. Threadgold LT. Electron-microscope studies of *Fasciola hepatica*. III. Further observations on the tegument and associated structures. *Parasitology.* 1967; 57: 633-7.
11. Abdel-Rahman EH, Abdel-Megeed KN, Hassanain MA. Structural characterization and immunolocalization of egg antigens cross-react with *Toxocara vitulorum*, *Fasciola gigantica* and *Moniezia expansa* mature flukes. *J Egypt Soc Parasitol.* 2000; 30(2): 581-91.
12. Youssefi MR, Hosseini SH, Shayan P, et al. Immunization of dog with proteins under 30 kDa

- molecular weight of hydatid cyst fluid and protoscoleces of *Echinococcus granulosus*. Int J Vet Res. (2011), 5, 4: 212-6.
13. Ohta V, Saeki K, Yoneyama F, et al. Immuno modulating activity of thymosin fraction-5 and Thymosin- α 1 in immunosuppressed mice *Echinococcus*. Cancer Immunol Immunother. 1983; 15: 108-18.
 14. Braganza CM, Stathopoulos G, Davies AJS. Lymphocytes Erthrocytes (L.E) Rosettes as indicators of the heterogeneity of lymphocytes in variety of mammalian species. Cell. 1975; 4(1): 103-6.
 15. Bombardier S, Ggiordano F. An evaluation of an agar gel diffusion test with crude and purified antigens in the diagnosis of hydatid disease. Bolletin World Health Org. 1974; 51: 525.
 16. Muñoz C, Nieto A, Gayá A, et al. New experimental criteria for optimization of solid-phase antigen concentration and stability in ELISA. J Immunol Meth. 1986; 94: 137-44.
 17. Ferragut G, Nieto A. Antibody response of *Echinococcus granulosus* infected mice recognition of glucidic and peptidic epitopes and lack avidity maturation. Parasite Immunol. 1996; 18(8):393-402.
 18. Bancroft JD, Stevens A. Histopathological stains and their diagnostic uses. Edinburgh: Churchill Livingstone; 1975. p.131.
 19. Snedecor GW, Cochran WG. Statistical Methods. 6th ed. USA: Iowa state University press; 1973. p. 238-48.
 20. Brutus L, Watier L, valErie B, et al. Parasitic co-infections: Does *Ascaris Lumbricoides* protect against *Plasmodium Falciparum* infection? Am J Trop Med Hyg. 2006; 75(2): 194-8
 21. Kaya M, Bestas R, Girgin S, et al. Increased anti-*Echinococcus granulosus* antibody positivity in *Fasciola hepatica* infection. Turk J Gastroenterol. 2012; 23(4): 339-43.
 22. Abdel-Rahman EH, Abdel-Megeed KN, Abuel-Ezz NMT. Cross-reaction: A common trait among helminthes. J Egypt Soc Parasitol. 2003; 33(2): 457-71.
 23. Peng X, Li J, Wu X, et al. Detection of osteopointin in the pericyst of human hepatic *Echinococcus granulosus*. Acta Trop. 2006; 100: 163-71.
 24. Matossian RM. The immunological diagnosis of hydatid diseases. Trop Med Hyg. 1997; 71: 101-4.
 25. Babba H, Messedi A, Masmoudi S. Diagnosis of human hydatidosis: comparison between imagery and six serologic techniques. Am J Trop Med Hyg. 1994; 50: 64-8.
 26. Poretti D, Felleisen E, Pfister M, et al. Differential immune-diagnosis between cystic hydatid disease and other cross-reactive pathologies. Am J Trop Med Hyg. 1999; 60(2): 193-8.
 27. Lin R, Ding JB, Lu XM. Transient expression of *Echinococcus granulosus* Eg95 DNA vaccine and induction of immune response in mice. Parasitol Res. 2004; 10(3): 321-6.
 28. Gaudier JF, Caban-Hernandez K, Osuna A, et al. Biochemical characterization and differential expression of a 16.5-kilodalton tegument associated antigen from the liver fluke *Fasciola hepatica*. Clin Vaccine Immunol. 2012; 19(3): 325-33.
 29. Ali-Khan Z, Siboo R. Pathogenesis and host response in subcutaneous alveolar hydatidosis. II. Intense plasma cellular infiltration in the paracortex of draining lymph nodes. Z Parasitenkd. 1980; 62: 255-65.
 30. Vuitton DA. The ambiguous role of immunity in echinococcosis: protection of the host or of the parasite? Acta Trop. 2003; 85: 119-32.
 31. Al-Qaoud KM, Abdel-Hafez SK. The induction of T helper type 1 response by cytokine gene transfection protects mice against secondary hydatidosis. Parasitol Res. 2008; 102: 1151-5.
 32. Ali-Khan Z, Rausch RL. Demonstration of amyloid and immune complex deposits in renal and hepatic parenchyma of Alaskan alveolar hydatid disease patients. Ann Trop Med Parasitol. 1987; 81: 381-92.
 33. Cervi L, Rossi G, Cejas H, et al. *Fasciola hepatica*-induced immune suppression of spleen mononuclear cell proliferation: role of nitric oxide. Clin Immunol Immunopathol. 1998; 87(2): 145-54.

Correspondence to Dr. Eman Gh. Khalil

Tel.: + 964 7902555087

E-mail: eman2010gh@yahoo.com

Received 1st Jul. 2014; Accepted 22nd Dec. 2014