

The Laryngeal Mask Airway: technical guidelines and use in special situations

Ahmed Abdulameer Salih

Summary:

Recent advances in airway management have changed the practice of anesthesia. Among these changes has been the introduction and increasing use of the Laryngeal Mask Airway (LMA). The laryngeal mask airway (LMA) is a novel device that fills the gap in airway management between tracheal intubation and use of the face mask.

This study describes the LMA, different methods of LMA insertion, uses, advantages, problems, complications and contraindications of LMA.

During eight years of LMA use in Al-Yarmook teaching hospital in Baghdad, the device was used for wide spectrum of surgical procedures successfully. We report some special series of cases where LMAs were used in providing a patent airway include LMA use with IPPV (intermittent positive pressure ventilation), for patient with history of failed intubation, for children who require general anesthesia for ultrasonic shock wave lithotripsy, the use of reinforce flexible LMA for nasal surgery and the use of total intravenous anaesthesia with LMA. Also we describe two methods of blind endotracheal intubation through LMA.

KEYWORDS: Equipment: laryngeal mask airway, Anaesthesia techniques: airway management.

INTRODUCTION:

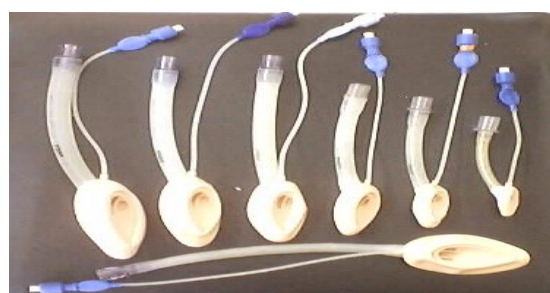
The laryngeal mask airway (LMA) is a novel device that fills the gap in airway management between tracheal intubation and use of the face mask. The LMA is inserted blindly into the pharynx, forming a low-pressure seal around the laryngeal inlet and permitting gentle positive-pressure ventilation. It allows the administration of inhaled anesthetics through a minimally stimulating airway. It is relatively simple to insert and may have a useful role in management of the difficult or failed intubation⁽¹⁾ The laryngeal mask airway (LMA) was developed and first used by Dr. Archie Brain⁽²⁾ (so some call it Brain airway⁽³⁾) in 1981. The LMA became commercially available in the United Kingdom in 1988⁽¹⁾. The LMA represents one of the most important revolutions in the management of airway during anesthesia.

The classical LMA (Figure 1a) consist of:

1. A transparent silicone tube of wide internal diameter, the proximal end is a standard 15mm connection⁽⁴⁾.
 2. An elliptical "spoon-shaped" mask with inflatable rim "cuff"⁽⁵⁾. The mask resembles a small face mask and is inflated via a pilot balloon with a self-sealing valve.
 3. There are slits at the junctions between the tube and the mask. These slits prevent the epiglottis from obstructing the LMA⁽⁶⁾.
- There are different sizes of the LMA (Figure 1b). Table 1 (below) shows the recommended LMA sizes (according to the weight of the patient), cuff inflation volume & the largest endotracheal tube (ETT) that can pass through each LMA.



(b)



(a)

Figure 1. (a) The components of the Classical Laryngeal mask airway. (b) Different sizes of LMA.

Department of Surgery College of Medicine Al-

Mustansirya University

Table 1. The recommended LMA sizes, cuff inflation volumes and largest endotracheal tube (ETT) that can pass through it

LMA Size	Patient Weight (kg)	Cuff Air Volume	Largest ETT
1	Up to 5	5	3.5
1½	5 - 10	10	4.0
2	10 -20	15	4.5
2½	20 - 30	21	5.0
3	30 – 50	30	6.0 cuffed
4	50 – 70	45	6.0 cuffed
5	70 – 100	60	7.0 cuffed
6	Over 100	75	7.0 cuffed

METHODS OF INSERTION OF LMA:

Standard method:

The deflated cuff is lubricated and inserted blindly into the hypopharynx, so that, once inflated, the cuff forms low-pressure seal around the entrance into the larynx. This requires an anesthetic depth slightly greater

than that for the insertion of an oral airway (7), but the LMA tolerated at lighter level of anesthesia than the ETT (2). Although insertion is simple, proper attention to detail will improve success rate (table 2 and figure 2).

Table 2 : Successful insertion of LMA depends upon attention to several details(1,7):

1. Choose the appropriate size (table 1) and check for leaks before insertion.
2. The leading edge of the deflated cuff should be wrinkle-free and facing away from the aperture (figure 2a).
3. Lubricate only the back side of the cuff.
4. Ensure adequate anesthesia before attempting insertion.
5. Place patient's head in sniffing position (figure 2b).
6. Use your index finger to guide the cuff along the hard palate and down into the hypopharynx until an increased resistance is felt (figure 2c), the longitudinal black line should always be pointed directly cephalad (facing the upper lip).
7. Inflate with the correct amount of air (table 1).
8. Ensure adequate anesthesia depth during patient positioning.
9. Obstruction after insertion is usually due to a down folded epiglottis or transient laryngospasm
10. Avoid pharyngeal suction, cuff deflation or LMA removal until pharyngeal reflexes fully recovered and the patient is awake (e.g. opening mouth on command).

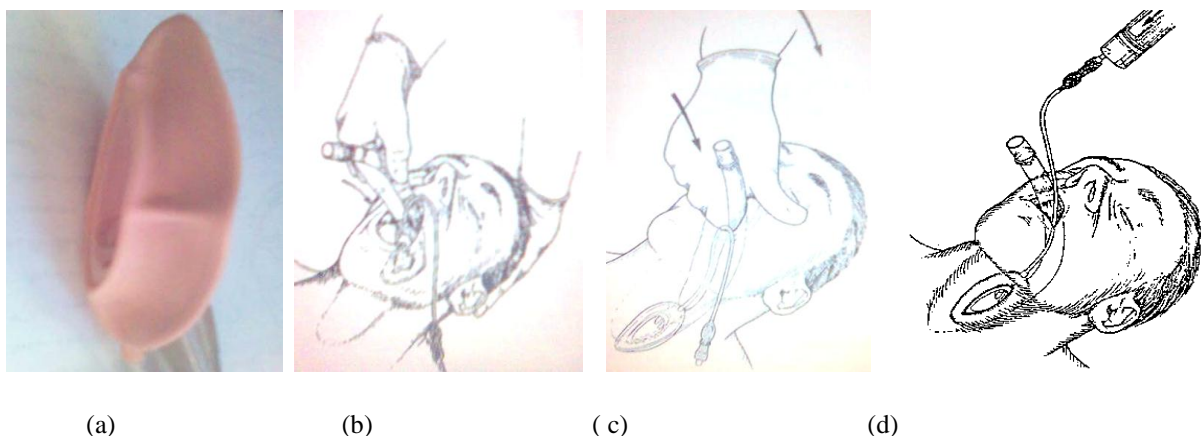


Figure 2. Recommended LMA insertion technique. (a) Deflate cuff, ensure no wrinkles near the tip. (b) Place patient's head in sniffing position and press the LMA against hard palate. (c) Advance mask while maintaining pressure against posterior pharyngeal wall. (d) Cuff inflation while the LMA in position (1, 7).

Other methods of inserting LMA:

- a. Under direct vision with the help of laryngoscope or fiberoptic bronchoscope (FOB) may prove beneficial in difficult cases (7, 8).
- b. If difficult, insertion may be easier with the aperture facing backward, and the mask then rotated when in the pharynx (9).
- c. An assistant grasp and draw the tongue forward using Magill forceps and then the LMA inserted by the anesthetist as in the standard method.
- d. It has been suggested that LMA insertion is easier when the cuff of the device is partially or completely inflated. Although this technique may offer some advantages for an inexperienced user, malposition of LMA is frequently encountered as well as partial airway obstruction; coughing or laryngospasm and the device frequently rest high in the larynx (2).

Uses and advantages of LMA:

LMA has been used safely and effectively in more than 100 million patients world wide and its clinical applications have greatly expanded to benefit virtually every subspecialty of anesthesia (2).

The use of LMA has been suggested;

1. To provide a clear airway without the need for anesthetist's hands to support a mask (4), or when holding a face piece may be difficult e.g. due to patient positioning or site of surgery (3).
2. To avoid the use of ETT during spontaneous ventilation (4), the LMA was found to be more effective as a ventilatory device than the facemask and to be less stimulant than the ETT (2).
3. For airway maintenance in difficult intubation in both previously suspected and known cases (7).
4. Emergency management of failed intubation, the LMA is a simple device that has been used to rapidly restore ventilation in the can not intubate / can not ventilate situation (8).
5. Cardiopulmonary resuscitation (3).
6. Assist blind intubation and FOB guided intubation in patient whose larynx could not be exposed by traditional rigid laryngoscope (8). However, the position of the LMA around the larynx has a perfect central position only 45% to 60% of the time. Passage of FOB and ETT through the LMA has nearly 100% chances of success in most series, while the blind passage of an ETT through the LMA has 26% to 97% failure rate on the first attempt and 10% to 70% overall failure rate (8). The passage of ETT

through the Intubating LMA "Fastrach" (a new modification of the classical LMA) has a better success rate (see below).

7. The LMA advocated for use in patient where pressure response to intubation would be detrimental. In patient with coronary artery disease or hypertension, who require GA for relatively short procedures; LMA insertion is associated with a lesser cardiovascular response than that seen during laryngoscopy and ETT insertion (2).
 8. Ambulatory surgery for healthy adult and children: the use of ETT can be avoided, thus reducing the anesthetic requirements and shortening the emergency and recovery times (2).
 9. For patient undergoing minor therapeutic or diagnostic procedures in location outside the operation room, e.g. radiation therapy, endoscopy and diagnostic and interventional radiology (2).
 10. The LMA is also very useful for surgical procedures involving the head and neck area (e.g. eye surgery, ENT surgery and minor plastic surgery). The LMA use for intraocular procedures offers the advantages of a smooth induction and cough-free emergence, thus minimizing the risk of intraocular hypertension (2).
11. Positive pressure ventilation (PPV) can be usefully and successfully delivered through the LMA in patients with normal lung compliance. Tidal volumes of 6 to 8 ml/kg should be applied, while keeping the airway pressure between 15 and 20 cm H₂O to prevent gastric insufflation and oropharyngeal leak (1).
- Problems and complication from LMA use:**
1. If the inflatable balloon is not positioned properly, a large gas leak occurs around the mask, impairing ventilation. This leak is exacerbated by high airway inflation pressure (4) (see above).
 2. The need to open the mouth widely to insert the device, thus obviating its use in any situation with temporomandibular joint dysfunction or oropharyngeal obstruction (10).
 3. Despite the presence of slits, if the epiglottis is folded downwards by the tip of the mask on insertion, the airway may be obstructed (6, 9).
 4. LMA may cause regurgitation and it does not protect against aspiration of gastric contents (2, 6).
 5. Unlike the ETT, rotation of the LMA may result in complete airway obstruction. So in order to assess the LMA's orientation when inserted, a black line is present along the tube,

which should face the upper lip of the patient, when the LMA is in position⁽⁶⁾.

6. Coughing, laryngospasm and even bronchospasm may occur^(2,5).
7. Post extubation stridor⁽⁵⁾.
8. Failed insertion⁽²⁾.
9. Kinking of the shaft of LMA⁽⁵⁾.
10. Pharyngeal and laryngeal trauma, so the inflation pressure of the cuff should not exceed 60 cm H₂O⁽²⁾.

Contraindications for LMA:

1. Patient with pharyngeal pathology (e.g. abscess)⁽⁷⁾.
2. Pharyngeal obstruction⁽⁷⁾.
3. A patient in whom regurgitation of gastric contents into the oesophagus is possible e.g. hiatus hernia⁽⁴⁾.
4. Patient with full stomach or with any condition leading to delayed gastric emptying e.g. pregnancy (but the LMA has been used for emergency caesarean section when intubation proved impossible, where a cuffed ETT in the oesophagus may help prevent regurgitation and aspiration)⁽⁹⁾.
5. Patient with high airway resistance (bronchospasm)⁽⁷⁾.
6. Patient with low pulmonary compliance (e.g. morbid obesity), requiring peak inspiratory pressure more than 20 cm H₂O.
7. Where the surgical access (e.g. to the pharynx) is impeded by the cuff of LMA.
8. Airway obstruction at or below larynx⁽⁵⁾.
9. Inability to extend the neck or open the mouth > 1.5 cm, making advancement of the LMA into the hypopharynx difficult (e.g., ankylosing spondylitis, severe rheumatoid arthritis, cervical spine instability)⁽¹⁾.
10. Inadequate depth of anesthesia to relax pharyngeal musculature⁽¹⁾.
11. One-lung ventilation⁽¹⁾.

Our experience with LMA in Al-Yarmook teaching hospital:

Although the LMA was introduced recently (mid 1998) in our hospital, we are using it widely in almost all the operation theatres. We use the LMA in orthopedics (e.g. anesthesia for upper and lower limbs surgery), urosurgery (e.g. anesthesia for cystoscopy and transurethral resection of the prostate), ophthalmology (e.g. anesthesia for cataract surgery), general surgery (e.g. anesthesia for head and neck operations, inguinal hernia surgery and anal surgery) and diagnostic radiology (e.g. MRI and CT-scan).

The following sizes are available: #1, #2, #2.5, #3, #4, #5 and #4R (reinforced flexible LMA) (see

figure 1(b)). We use LMA for all age groups from neonates to geriatrics.

The resident anesthetists are well trained in using the LMA, and even some assistant anesthetist had used the LMA successfully.

I had tried all the above mentioned methods of insertion of the LMA successfully, except that the use of the FOB for the insertion of LMA because it is not available in our hospital.

Use of LMA in special situation :

During my eight years experience with LMA, I had report the use of LMA in the following special series of cases:

1. To deliver IPPV through the LMA successfully in a series of 12 cases (ten males and two females)

in different age groups (25 -76 years) and types of surgery, using non-depolarizing muscle relaxant, the LMA #3 was used to maintain the airway, tidal volumes 6-8 ml/kg and keeping the airway pressure between 15 and 20 cmH₂O to prevent gastric insufflation and oropharyngeal leak. For example, we apply this technique in orthopedics for a 76 years old female with fracture of left neck of femur (Osten Moore surgery for replacement of the head of the femur), which was a prolong operation (more than 2½ hours). The LMA can be satisfactorily used for IPPV in patients with normal airway resistance and compliance who do not require high inflation pressures to produce normal tidal volumes⁽¹¹⁾.

Throughout its history, the LMA has provided a reliable method of assuring a patent airway. It has, however, encouraged the use of spontaneous breathing. Allowing a patient to breath without assistance has potential consequences that clinicians have attempted to avoid. Standard volume mode ventilators have proven difficult to manage with LMAs as a result of leaks, peak pressures, and gastric ventilation to name a few. Supporting patient ventilation with pressure modes may provide an answer. So we use the LMA to deliver IPPV with Pressure Controlled mode of ventilation. Initially an airway pressure of 13 cm H₂O is selected, and then the pressure is adjusted to deliver a suitable tidal volume with no leak.

Spontaneous breathing is the most popular mode of ventilation with the laryngeal mask airway (LMA), but provides less effective gas exchange than does positive pressure ventilation (PPV)⁽¹²⁾. Pressure support ventilation (PSV) is a form of partial ventilatory support in which each spontaneous breath is assisted to an extent that depends on the level of a constant pressure applied during inspiration⁽¹³⁾. PSV improves gas exchange in anesthetized intubated patients. PSV provides

more effective gas exchange than does unassisted ventilation with continuous positive airway pressure (CPAP) in anesthetized adult patients treated using the LMA⁽¹⁴⁾.

2. For a patient with history of failed intubation:

a 34 years old male 130 cm height (figure 3), with a history of failed intubation and then temporary tracheostomy was done for him to maintain anesthesia for splenectomy before three years ,tracheostomy was closed later on. On examination; there was no limitations of neck extension, thyromental distance= 6 cm, inter-

incisors distance= 4 cm and Mallampatti's test Grade 3(only the soft palate could be seen). This patient was listed for left inguinal hernia repair. Inhalational induction of anesthesia with halothane was done, when the patient was deep enough, airway management became difficult, laryngoscopy was done which reveal long epiglottis, that cause airway obstruction and the larynx can not be seen(Grade -3-). Then the tongue drawn gently out using Magill's forceps and the LMA #3 was inserted in position successfully and the operation went smoothly.

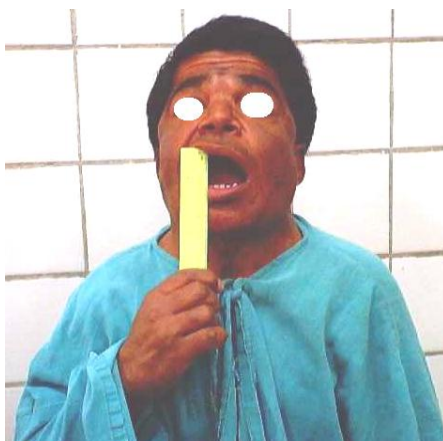

Figure 3. Patient with history of failed intubation

3. For children who require general anesthesia for ultrasonic shock wave lithotripsy: Our series of 18 case reports of using the LMA for children (4 - 12 years) who require general anaesthesia for ultrasonic shock wave lithotripsy; as this procedure require light level of anesthesia (just keep the child still) and there is an exposure to X- ray for the anesthetist who may be away from the patient, or were a shield. Some times the procedure take a lot of time which make mask anesthesia unsuitable. So, we find that general anesthesia with spontaneous breathing using halothane and LMA to maintain the airway is satisfactory.

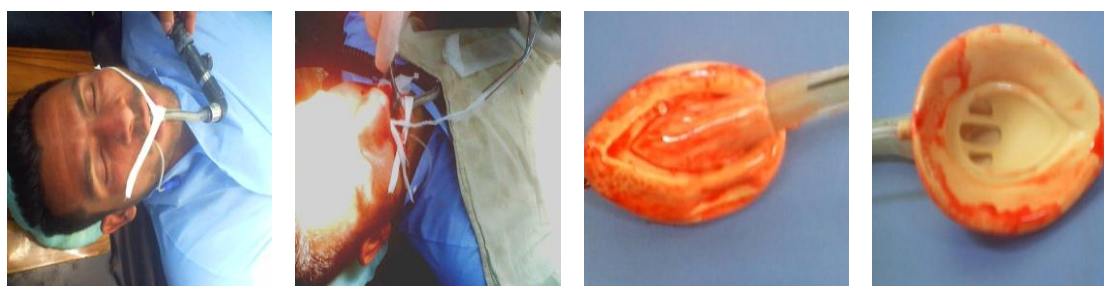
4. For nasal surgery using the reinforce flexible LMA (figure 4): We report a series of three cases.

E.g. a 25 years old male (70 kg) who underwent anaesthesia for reduction of nasal bone fracture. Thiopentone 250mg was used for the induction and halothane for the maintenance of anaesthesia , when the patient is deep enough a **Flexible LMA #**

4 was inserted successfully from the first attempt (without the need for using a skeletal muscle relaxant).Then the cuff is inflated, the LMA fixed in position and connected to Magill circuit (figure 5a) so that making the surgical access easy (fig.5b).The operation went smoothly, and after the ending of surgery gentle suctioning of the mouth above the LMA was done, and when the cough reflex returned and the patient awake the LMA removed and the recovery was smooth. Figures (4a & b) shows that the back of the mask stained with blood, but the anterior part of the rim of the mask is partially stained with blood and there is no blood in the central part of the mask that face the larynx. So that no episode of hypoxemia related to blood inhalation occurred⁽¹⁵⁾, and there is no need for the pharyngeal pack. Protection of the lower airways from secretions, fluid or blood, arising above the LMA, would appear to be confirmed⁽¹⁶⁾

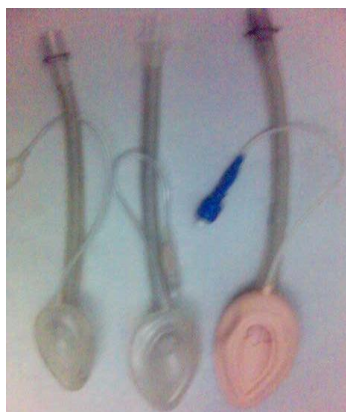

Figure 4. Reinforced flexible LMA.



(a)

(b)

(c)

(d)

Figure 5. The use of flexible LMA for nasal surgery. (a) Flexible LMA in position connected to Magill circuit. (b) During surgery. (c) The back of the mask stained with blood. (d) The anterior part of the rim of the mask is partially stained with blood, but there is no blood in the central part of the mask that face the larynx.

5. Total intravenous anaesthesia (TIVA) and LMA:

Our series of case reports include six adult patients (21 – 58 years) e.g. a 58 years old male (75 kg) presented for removal

Of lipoma in the left shoulder (day surgery). While in right lateral position anaesthesia was induced with fentanyl 1µg/kg and propofol 2mg/kg then LMA # 4 was inserted successfully from the first attempt with no need to use skeletal muscle relaxant, and anaesthesia was maintained using propofol drip starting at 10mg/kg/hr for 10 minutes (170 µg/kg /min) then reduced to 8mg /kg/hr (130 µg/kg

/min) .The operation went smoothly and the recovery was smooth and rapid.

Propofol is regarded currently as the most suitable anaesthetic agent for total intravenous anaesthesia (TIVA); it allows for rapid changes in anaesthetic depth and a rapid, clear-headed recovery⁽¹⁷⁾. Also, low context-sensitive half-time⁽¹⁸⁾ makes it theoretically the best available agent for long procedures under TIVA. Furthermore, propofol attenuates airway reflexes to the extent that the laryngeal mask airway (LMA) may be positioned easily without neuromuscular block⁽¹⁹⁾.

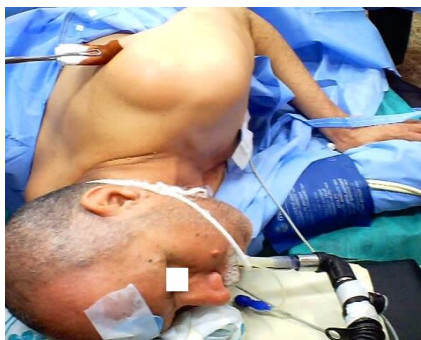

Figure 6. TIVA and LMA for day surgery.

6. Blind Intubation Techniques Using the LMA:

When the LMA is correctly inserted, its distal aperture sits directly over the laryngeal inlet, thereby allowing tracheal intubation by a variety of blind and fiberoptic techniques in awake or anesthetized patients. Because blind intubation can be accomplished rapidly with the LMA and does not require specialized equipment, it may play a role in both elective and emergent situations, even on awake patients. Placement of the LMA is facilitated if glottic reflexes can be obtunded by either deep anesthesia, topical anesthesia, or the use of muscle relaxants.

We report a series of four cases for whom blind intubation techniques using LMA. We use two different techniques that we describe down in details:

a. Blind intubation using a gum elastic bougie (GEB) through classical LMA: A 47years old female (85kg) was prepared for transabdominal hysterectomy. After induction of anaesthesia with sleeping dose of thiopentone and

pancuronium was used to facilitate the intubation procedure a classical LMA # 4 was inserted (Figure 7a). A gum elastic bougie (GEB) with an anterior angulation of its distal tip (figure 7b) was passed blindly through the LMA into the trachea of patient (figure 7c). Once the distal aperture of the LMA has been negotiated Pennant JH recommends rotating the GEB 180° to facilitate its passage into the trachea⁽¹⁾. The LMA was withdrawn and a tracheal tube “railroaded” over the GEB into the trachea (figure 7d). This maneuver permits removal of the LMA and the passage of any size of tracheal tube, and allows better surgical access to the oropharynx. The disadvantages are that the airway is neither protected nor controlled once the LMA has been taken out, and passage of a tracheal tube over the GEB may not be successful. The success rate in a study of 50 patients was 84–88%⁽²⁰⁾. Malpositioning of the LMA was the usual cause of failure to successfully pass the GEB. Other investigators have reported success using this technique⁽²¹⁾.


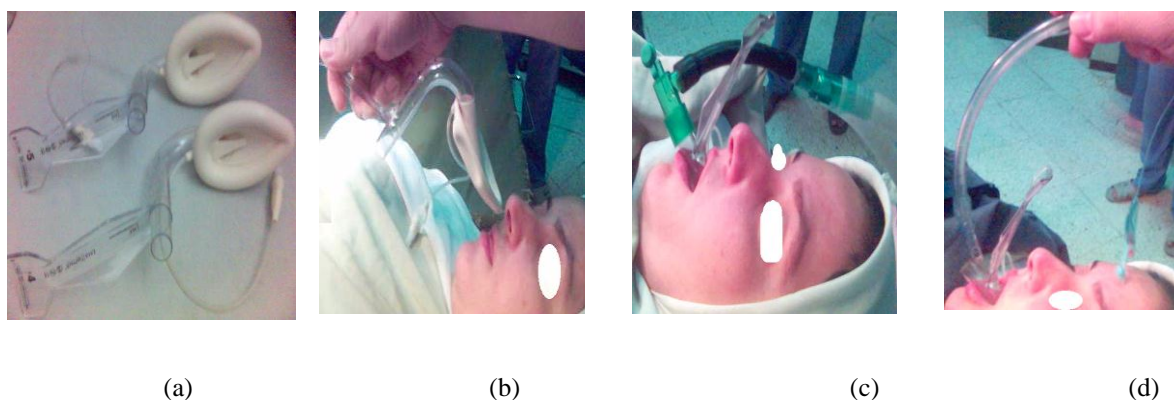


Figure 7. Blind intubation using a gum elastic bougie (GEB) through classical LMA. (a) a classical LMA was inserted and connected to ventilator. (b) A distal tip of GEB that has an anterior angulation. (c) A GEB was inserted to suitable depth through the LMA into the trachea. (d) The LMA was removed after deflating its cuff and then a cuffed endotracheal tube (ETT) railroaded over the GEB into the trachea. (e) The ETT in the proper position and connected to the ventilator.

b. Blind intubation through the Intubating LMA Fastrach (ILMA) (figure 8a): A 27 years old female (75kg) prepared for appendicectomy. Anaesthesia was induced with ketamine 100mg and sleeping dose of thiopentone, pancuronium was used for skeletal muscle relaxation, then LMA Fastrach #5 was inserted (figure 8b) and connected to the ventilator after inflation of the cuff (figure 8c) an uncut, lubricated, 6.5-mm cuffed tracheal tube blindly passed through the shaft of the LMA Fastrach with the tracheal tube inserted in a reversed curve, instead of the conventional normal curve (Figure 8d)⁽²²⁾, and into the trachea before the tracheal tube's cuff is inflated. Removing the LMA with the 6.5-mm tube in place is difficult, if there is no way of

stabilizing the tracheal tube as the LMA is withdrawn; the tight fit between the tracheal tube and the inner wall of the LMA shaft tends to result in extubation of the trachea. The use of a *stabilizing rod* to the tracheal tube (figure 8e & f) before removal of the LMA is helpful in this situation. A study performed on 100 patients reported 90% success using this blind intubation technique⁽²³⁾. Another study has demonstrated the safe and effective use of the LMA-Fastrach in 254 patients with Difficult Airway (DA). Insertion of the LMA-Fastrach and intubation through it were successful on the first attempt in a high percentage of patients with various types of DA⁽²⁴⁾.



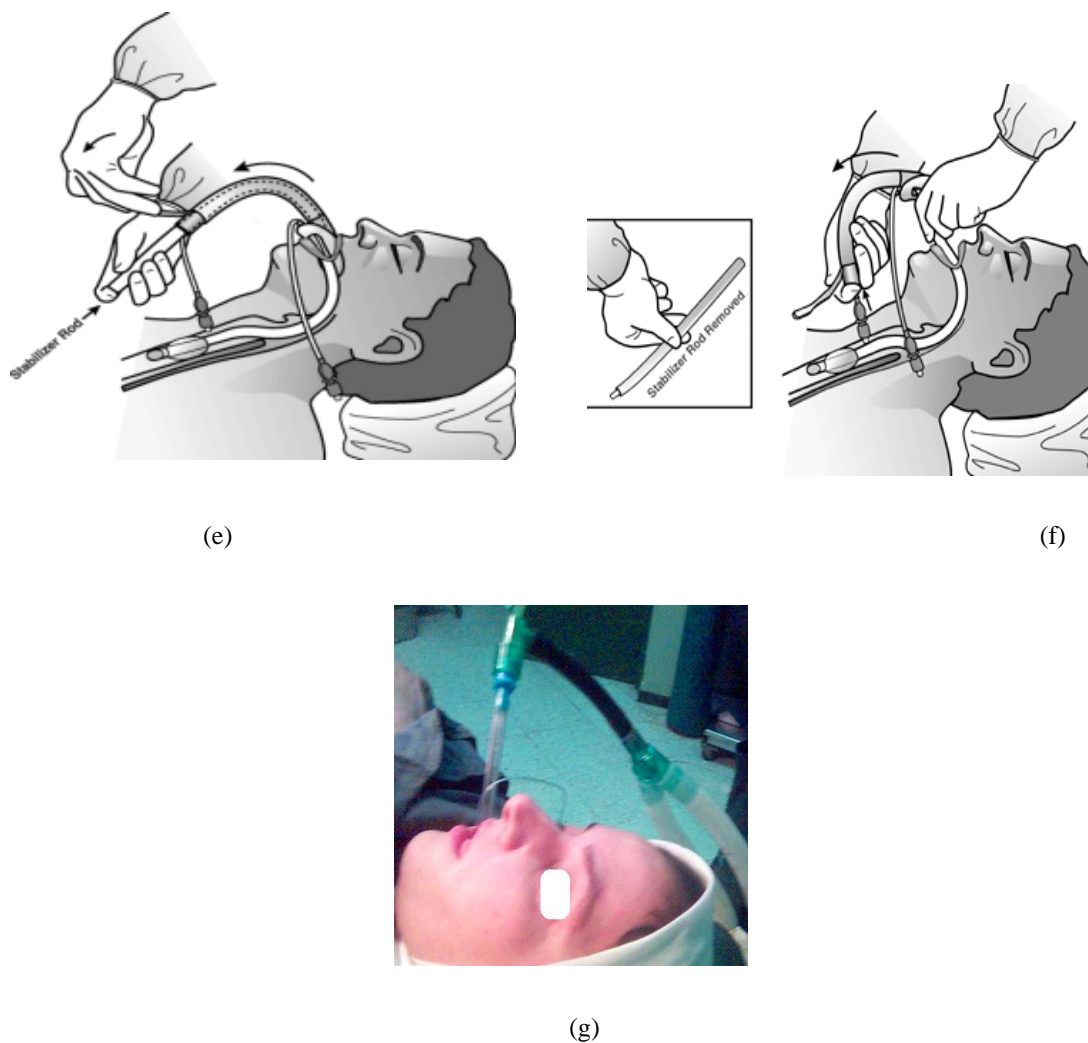


Figure 8. (a) ILMA (Fastrach). (b) ILMA Fastrach insertion. (c) ILMA Fastrach connected to ventilator. (d) ETT insertion through ILMA. (e)& (f) Using a stabilizing rod to ETT while removing the ILMA. (g) ETT in position connected through breathing circuit^{1/2} to ventilator.

CONCLUSION:

The LMA improve the quality of the practice of anaesthesia and proved to be suitable alternative to ETT in many situations.

REFERENCES:

1. Pennant JH, White PF. The Laryngeal mask airway Its use in Anesthesiology 1993;79:144-63.
2. Ferson D. LMA: its role in anesthetic practice. ASA refresher courses in Anesthesiology. Dallas 1999.
3. Yentis SM, Hirsch NP, Smith GB. Laryngeal mask. In: Anesthesia A-Z an encyclopaedia of principle and practice. 1st Edn. London: Butterworth-Heinemann, 1997; 268-9.
4. Aitkenhead AR, Smith G. The laryngeal mask. In: Textbook of anaesthesia. 3rd

- edition. London: Churchill Livingstone, 1996; 289-290.
5. Oh TE, Young KK. Airway management. In: Oh TE, ed. Intensive care manual. 4th edition. London Butterworth – Heinemann, 1998;217-27.
 6. Al-Shaikh B, Stacey S. Tracheal and tracheostomy tubes and airways. In: Essential of anaesthetic equipment. 1st Edition. London: Churchill Livingstone, 1996; 43-53.
 7. Morgan GE, Mikhail MS. Airway management. In: Clinical anesthesiology. 2nd edition. Connecticut: Appleton & Lunge, 1996; 50-72.
 8. Wilson WC, Benumof JL. Pathophysiology, evaluation, and treatment of the difficult airway. *Anesthesiology clinics of north America* 1998; 16-1: 29-76.
 9. Rushman GB, Davis NJH, Cashman JN. Anaesthetic equipment. In: Lee's synopsis of anaesthesia. 12th edition. Oxford: Butterworth- Heinemann, 1999; 103-31.
 10. Norton ML. The difficult airway. In: Healy TEJ, Cohen PJ, eds. Wylie and Churchill-Davidsen's A practice of Anesthesia. 6th Edn. London Edward Arnold. 1995; 735-51.
 11. Devitt, JH, Wenstone R, Noel AG, O'Donnell MP: The laryngeal mask airway and positive-pressure ventilation. *Anesthesiology* 80 1994
 12. Keller C, Sparr HJ, Luger TJ, Brimacombe J: Patient outcomes with positive pressure versus spontaneous ventilation in non-paralysed adults with the laryngeal mask. *Can J Anaesth* 45:564-7, 1998.
 13. Brimacombe J, Keller C, Hörmann C: Pressure support ventilation versus continuous positive airway pressure with the laryngeal mask airway. *Anesthesiology* 2000;92:1621-3.
 14. Groudine SB, Lumb PD, Sandison MR: Pressure support ventilation with the laryngeal mask airway: A method to manage severe reactive airway disease postoperatively. *Can J Anaesth*, 1995; 42:341-3.
 15. Choufane S, Lemogne M, Eurin B, Monteil JP. Laryngeal mask and reduction of nasal bone fractures. *Ann Otolaryngol Chir Cervicofac* 1997; 114: 226-7.
 16. Daum RF, O'Reilly RJ. The laryngeal mask airway in ENT surgery. *J Laryngol Otol* 1992; 106: 28-30.
 17. Dyer, R. A.; Llewellyn, R. L.; James, M. F. M. Total i.v. anaesthesia with propofol and the laryngeal mask for orthopaedic surgery. *Br J Anaesth* 1995; 74: 123-8.
 18. Hughes MA, Glass PSA, Jacob JR. Context-sensitive half-time in multicompartment pharmacokinetic models for intravenous anesthetic drugs. *Anesthesiology* 1992; 76:334-341.
 19. Hickey S, Cameron AE, Asbury AJ. Cardiovascular response to insertion of Brain's laryngeal mask. *Anaesthesia* 1990; 45:629-633.
 20. Allison A, McCrory J: Tracheal placement of a gum elastic bougie using the laryngeal mask airway (letter) *Anaesthesia*, 1990;45:419-420.
 21. Carey MF, Smith J, Cooney CM: Laryngeal mask to aid tracheal intubation (letter) *Anaesthesia*, 1991;46:1083.
 22. Lu PP, Yang CH, Ho AC, Shyr MH. The intubating LMA: a comparison of insertion techniques with conventional tracheal tubes. *Can J Anaesth* 2000;47:849-53.
 23. Heath ML, Allagain J: Intubation through the laryngeal mask: A technique for unexpected difficult intubation. *Anaesthesia* 1991;46:545-548.
 24. Ferson DZ, Rosenblatt WH, et al. Use of the intubating LMA-Fastrach in 254 patients with difficult to manage airways. *Anesthesiology* 2001;95:115-1181.