

Exteriorization of genital system of Awassi ewes with laparotomy in standing position

Abdul Sattar Faraj Majeed, Qusay Muhammed Aboud, Anmar Jasim Mohammed and Ahmed Emad Abood

College of Veterinary Medicine/ University of Fallujah

Abstract

The study were undertaken on 16 Iraqi Awassi ewes, presented in the farm of college of veterinary medicine, Al- Fallujah University/ Fallujah, during the end of February to the half of the march, 2018. The age of the animals ranged between 2 to 4 years. All the ewes were examined by ultrasonography by specialist in order to be sure that the animals not pregnant with B- mode system. All the animals has been synchronized with vaginal sponges impregnated in 40 mg flurogestone acetate (intervet, B.V. Boxmeer, Holland). The animals were put in a standing position clipping and shaving of the left flank area then the site washed with antiseptic and disinfected with tincture iodine. The animals anesthetized locally using 2% xylocaine hydrochloride using 10 ml subcutaneously and intra muscular. left flank sharp dissection about 10-12 cm were made through the skin, muscle and peritoneum. Exteriorization of the uterus and ovaries were done to detect the pregnancy through a symmetry of uterine horns and the enlargement of pregnant horn or to detect the numbers of follicles and corpora lutea after that the peritoneum and the muscles were sutured with catgut no.1 with lock stich pattern. The skin was sutured with silk no.1 using horizontal mattress interrupted pattern. Systemic long acting tetracycline were applied I.M (200 mg/ ml: 100mg/kg B.W) for one day and another for 3 injection. Local antibiotic spray was applied to treat the surgical wounds for 7 days. The suture materials of the skin were removed after 7 days of the operation. The animals were examined daily for general health condition (temperature, heart rate, pulse rate, appetite). The wound also examined for presence of swelling, hematoma, pus or infection or hernia Positive results were considered when the animal in a good general health condition and the wound showed normal healing without presence of swelling, hematoma, pus or infection or hernia. This technique is simple, easily done, save time and cost as well as reduce the surgical trauma with few suture materials. The study was the first of its kind all over the world in exteriorization of genital organs in standing position in ewes.

Keywords: Genital system, laparotomy, Awassi ewes

e-mail: af_majeed@yahoo.com, Qusaymoh988@yahoo.com, Anmar.vet.med@uofallujah.edu.iq

Received: 16-5-2018

Accepted: 15-7-2018

استخراج الجهاز التناسلي للنعاج العواسي عن طريق فتح البطن بوضع الوقوف

عبد الستار فرج مجيد ، قصي محمد عبود، انمار جاسم محمد واحمد عماد عبود

فرع الجراحة والتوليد/ كلية الطب البيطري/ جامعة الفلوجة

الخلاصة

أجريت الدراسة على 16 نعجة عواسي عراقية، تواجدت في حقل كلية الطب البيطري/ جامعة الفلوجة/ العراق، في بداية فبراير إلى نهاية شباط، 2018. تراوح عمر الحيوانات بين 2 إلى 4 سنوات تم فحص جميع النعاج عن طريق الموجات فوت الصوتية من قبل متخصص من أجل التأكد من أن الحيوانات غير الحامل. وقد تم توحيد الشبق في جميع الحيوانات باستخدام الإسفنجات المهبلية المشربة في 40 ملغ أسيتات فلوروجستون (intervet، B.V. Boxmeer، هولندا). تم وضع الحيوانات في وضع الوقوف وتم قصها وحلاقتها في منطقة الخاصرة اليسرى ثم غسل الموقع بمطهر وتطهير اليود. وحقت الحيوانات بالمخدر الموضعي باستخدام 2%

زيلوكائين هيدروكلوريد باستخدام 10 مل تحت الجلد وداخل العضلات. عمل جرح في الخاصرة اليسرى بطول حوالي 10-12 سم من خلال الجلد والعضلات والبريتون. تم إجراء عملية استخراج الرحم والمبايض للكشف عن الحمل من خلال تناظر قرون الرحم وتضخم القرن الحامل أو للكشف عن أعداد الحويصلات والأجسام الصفراء بعد أن تم خياطة البريتون والعضلات باستخدام خيط ممتص (رقم 1) خياطة (lock stich). تم خياطة الجلد باستخدام خيط حرير رقم 1 باستخدام نمط خياطة (Horizontal interrupted). تم حقن التتراسيكلين طويل الامد (M 200 ملغ/مل: 100 مغ/كغ ب) بين يوم وآخر لمدة 3 مرات. تم استخدام رذاذ مضاد حيوي لعلاج الجروح الجراحية لمدة 7 أيام. وتمت إزالة الخيوط الجراحية من الجلد بعد 7 أيام من العملية. تم فحص الحيوانات يوميا لمراقبة الحالة الصحية العامة (درجة الحرارة، معدل ضربات القلب، معدل النبض، الشهية). فحص الجرح أيضا لملاحظة وجود تورم أو ورم دموي أو صديد أو عدوى أو فتق. تم ملاحظة نتائج إيجابية وقد اعتبر الحيوان في حالة صحية عامة جيدة وأظهر الجرح الشفاء الطبيعي دون وجود تورم أو ورم دموي أو صديد أو عدوى أو فتق. وقد استنتج ان هذه التقنية بسيطة، يسهل القيام بها، توفيراً للوقت والتكلفة وكذلك الحد من الكلم الجراحية مع قلة استخدام مواد خياطة الجروح. وكانت هذه الدراسة هي الأولى من نوعها في جميع أنحاء العالم فيما يتعلق بتقنية استخراج الأعضاء التناسلية في وضع الوقوف في النعاج.

الكلمات المفتاحية: الجهاز التناسلي، فتح البطن، النعاج العواسية.

Introduction

Awassi ewes considered one of the most important breed in Iraq. The animals managed for production of meat, milk, wool and skin (1). It resist the high environmental temperature that leads to decrease their reproductive performance through the effects of temperatures on the uterus, hormones and fetus (2). In addition, awassi ewes may have a silent heat (3, 4). Research to increase reproductive performance in awassi ewes including: superovulation, synchronization, pregnancy diagnosis, IVF and embryo transfer. Laparotomy was one of the diagnostic tools used for examination and exteriorization of the genital system of the ewes. There are several approach used for laparotomy in large animals including ventral, ventro-lateral, paramedian, mid-line and flank incision (5). Most of the techniques were used in recumbent position and required more work, time and complications. Therefore, the aim of this study is to make laparotomy in standing position for Awassi sheep for superovulation, collection of oocytes and pregnancy diagnosis.

Keywords: Awassi ewes, laparotomy, superovulation, oocytes collection, pregnancy diagnosis.

Materials and Methods

The study were undertaken on 16 Iraqi Awassi ewes, presented in the farm of college of veterinary medicine, Al- Fallujah university/ Fallujah, during the end of February to the half of the march, 2018. The age of the animals ranged between 2 to 4 years. All the ewes were examined by ultrasonography by specialist in order to be sure that the animals not pregnant with B- mode system.

- **Oestrus synchronization:** All the animals has been synchronized with vaginal sponges impregnated in 40 mg flurogestone acetate (intervet, B.V. Boxmeer, Holland) were inserted into vagina using an applicator with obstetrical gel and antiseptic for 14 days before one day of sponges removal. The ewes injected with equine chorionic gonadotropine (eCG) (500 I.U) I.M, when the sponges removed the animals were injected with human chorionic gonadotropine (HCG) (intervet, B.V. Boxmeer. Holland)(200 I.U) I.M. Observation of the animals for 12-24 hr., have been taken to detect the signs of oestrus. The animals divided into two groups, the first group (no.= 8 ewe) were mated with a fertile ram when the ewe showed a sign

of estrus, then the animals followed for pregnancy detection with ultrasonography and laparotomy. While other group (2nd group) (no.= 8 ewe) subjected to laparotomy to detect the numbers of follicles and corpora lutea in the ovaries.

- **Surgical operations:** The animals were put in a standing position clipping and shaving of the left flank area then the site washed with antiseptic and disinfected with tincture iodine. The animals anesthetized locally using 2% xylocaine hydrochloride using 10 ml subcutaneously and intra muscular.

Left flank sharp dissection about 10-12 cm were made through the skin, muscle and peritoneum. Exteriorization of the uterus and ovaries were done to detect the pregnancy through a symmetry of uterine horns and the enlargement of pregnant horn or to detect the numbers of follicles and corpora lutea after that the peritoneum and the muscles were sutured with catgut no.1 with lock stich pattern. The skin was sutured with silk no.1 using horizontal mattress interrupted pattern. Systemic long acting tetracycline were applied I.M (200 mg/ ml: 100 mg/kg B.W) for one day and another for 3 injection. Local antibiotic spray was applied to treat the surgical wounds for 7 days. The suture materials of the skin were removed after 7 days of the operation. The animals were examined daily for general health condition (temperature, heart rate, pulse rate, appetite). The wound also examined for presence of swelling, hematoma, pus or infection or hernia Positive results were considered when the animal in a good general health condition and the wound showed normal healing without presence of swelling, hematoma, pus or infection or hernia.

Results and Discussion

The result of operations (for 16 ewe) performed in standing position showed that the animals in a good general health condition with normal body temperature, heart rate, respiratory rate, pulse rate with a good appetite. In addition, the wounds showed no complications that accompanied these operations such as swelling, hematoma, hernia, pus and infection. Many operations including some husbandry procedures and practices, for experimental purposes are performed on standing position. The standing position eliminates the dangers associated with forcible casting and restraint and prolonged recumbency. The technique is very simple, cheap and are not difficult to be learned and do not involve the use of expensive or complicated equipment. The flank laparotomy approach is the most widely used among small ruminants surgeons for accessing abdominal and reproductive organs. In a study by Abubakar *et al.* (6) to compare a laparotomy performed in midventral and flank approaches, he observed that the mid-ventral laparotomy approach could be conveniently and safely performed under septic precautions without fear of intra and postoperative clinical problems. Similar observations have been made by Majeed (7) and Majeed *et al.* (8) in local black Iraqi goats. There are many factors that can affect wound healing which interfere with one or more phases in this process (hemostasis, inflammation, proliferation and tissue remodeling or resolution) thus causing improper or impaired tissue repair (9). Laparoscopy requires expensive instruments that can also be used to other endoscopic procedures (10). Also the restriction of the scientific skills and practice should be required. Food-animal practitioners commonly perform local anesthetic techniques due to the dangers associated with general anesthesia. Local anesthetic techniques usually are simple, cheap and have relatively few side effects. Local anesthesia enabling protracted operations in standing animals. The xylocaine is the most widely used general-purpose local anesthetics in veterinary use. It possess reasonably rapid onset of action with good spreading properties. It may cause some local irritation and swelling. It is available in a variety of concentration or injection with and without epinephrine and in the form of solutions, creams, jellies, spray... etc. The duration of action is variable

(depending on uptake) but will be around one hour without epinephrine and two hours with epinephrine. The flank laparotomy approach is the most widely used among small ruminant surgeons for accessing abdominal and pelvic organs. Prolonged lateral recumbency in goats under anesthesia is associated with decrease in rumen stasis thereby predisposing the animal to bloat and toxemic lactic acidosis. It is done without intra and post- surgical complication. This technique is simple, easily done, save time and cost as well as reduce the surgical trauma with few suture materials(11). The study was the first of its kind all over the world in exteriorization of genital organs in standing position in ewes.

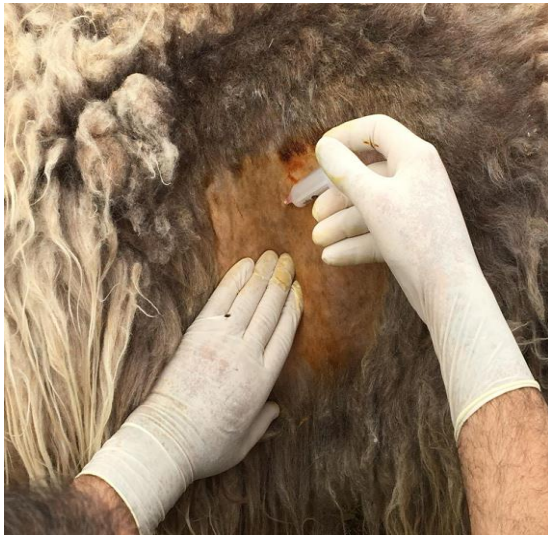

Fig. (1) local infiltration of lidocaine in site of operation (left flank region)

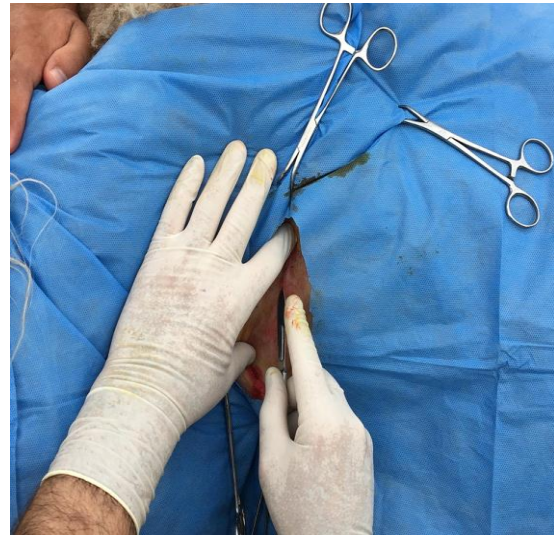

Fig. (2) Make an incision in the flank region under disinfected condition

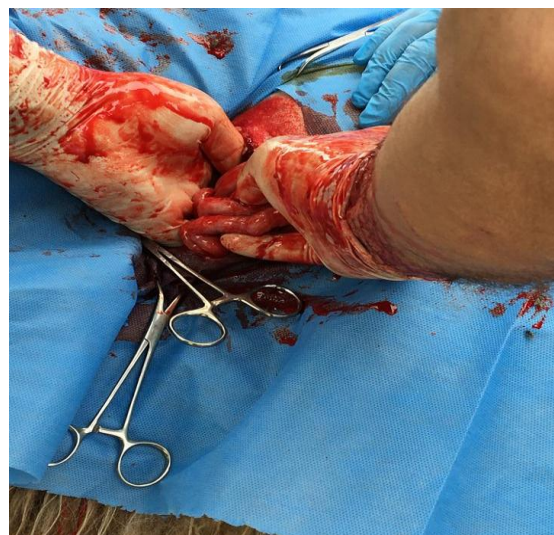
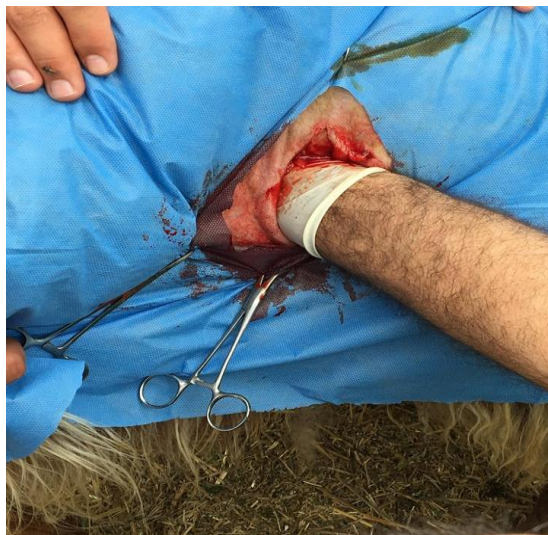
Fig. (3) Exteriorization of female genital system outside the body

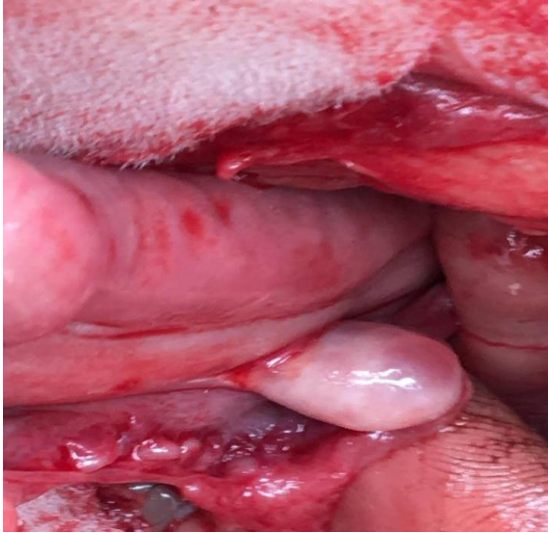

Fig. (4) Ovary have different size follicles

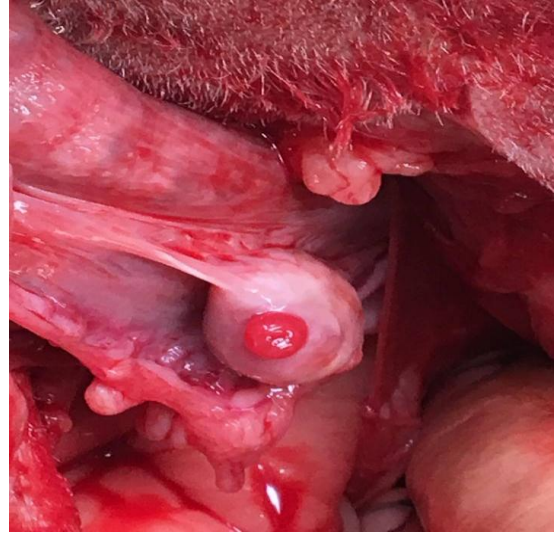


Fig. (5) Ovary have mature corpus luteum

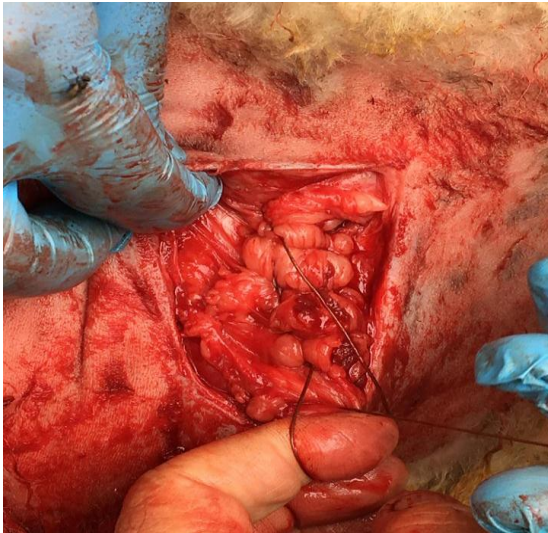


Fig. (6) Closed the site of operation using continuous lock stich pattern

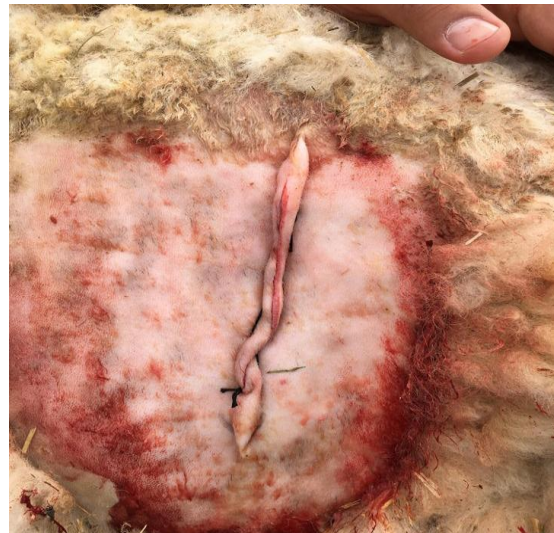

Fig. (7) Closed the skin using horizontal suture pattern

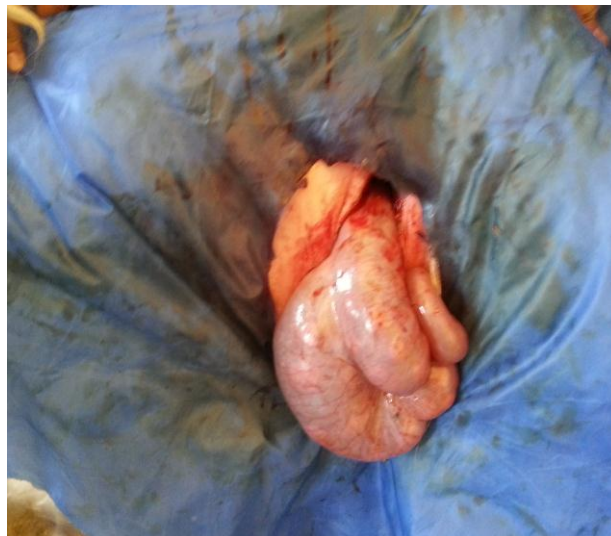

Fig. (8) Showed early pregnancy

References

1. Gordon, I. (2004). Embryo Transfer in Farm animals. Saunders, London.
2. Putney, D. J.; Malayer, J. R.; Gross, T. S.; Thatcher, W. W.; Hansen, P. J. & Drost, M. (1988). Heat stress-induced alterations in the synthesis and secretion of proteins and prostaglandins by cultured bovine conceptuses and uterine endometrium. *Biol. Reprod.*, 39(3), 717-728.
3. Noakes, D. E.; Parkinson, T. J. & England, G. C. (2009). *Veterinary Reproduction and Obstetrics*. 9th ed. London. Saunders Elsevier.
4. Azawi, O. I. & Al-Mola, M. K. M. A. (2010). Effect of season and mating system in Awassi ewes superovulated with FSH on fertilization rate and embryo recovery. *Iraqi J. Vet. Sci.*, 24(2): 75-79.
5. Hendrickson, D. A. & Baird, A. N. (2013). *Turner and McIlwraith's Techniques in Large Animal Surgery*, 4th Ed. John Wiley & Sons.
6. Abubakar, A. A.; Andeshi, R. A.; Yakubu, A. S.; Lawal, F. M. & Adamu, U. (2014). Comparative Evaluation of Midventral and Flank Laparotomy Approaches in Goat. *J. Vet. Med.*, PP. 1-7.
7. Majeed, A. F. (2012). In vitro fertilization in Black local breed Iraqi goats. A comparative study. Ph.D. Thesis. University of Baghdad.
8. Majeed, A. F.; Al-Timimi, I. H. & Al-Saigh, M.N. (2014). Effect of culture media on IVF in Iraqi goats. Researches of Second Scientific Conference of Faculty of Veterinary Medicine University of Kufa 12-13 Feb.
9. Guo, S. & DiPietro, L. A. (2010). Factors affecting wound healing. *J. Dent. Res.*, 89(3): 219-229.
10. Yanmaz, L. E.; Okumus, Z. & Dogan, E. (2007). Laparoscopic Surgery in Veterinary Medicine. *Vet. Res.*, 1(1): 23-39.
11. Li, Q. Y.; Guan, H.; Hou, J.; An, X. R. & Chen, Y. F. (2008). Technical note: Transfer of ovine embryos through a simplified mini-laparotomy technique. *J. Anim. Sci.*, 86(11): 3224-3227.