

Protective Effect of *Hypericum Triquetrifolium* Aqueous Extract on Biochemical and Histopathological Parameters in Hyperlipidemic Male Rats

Youns Saleh Mustafa¹, Kalthum Asaaf Maulood²

^{1,2}Department of Biology, College of Education, University of Salahaddin, Erbil, Iraq.

¹younsaleh87@gmail.com, ²Kalthum.maulood@su.edu.krd

Abstract

Hypericum triquetrifolium is an herbaceous perennial plant, numerous of the bioactive compound are present in it that is responsible for several biological functions. Aim of this research the protective effect of aqueous extract of *Hypericum triquetrifolium* on some biochemical parameters and histopathological study in hyperlipidemic male rats. Thirty-six male albino rats were divided into six groups, control group (fed with standard pellet), hyperlipidemia group, three, four and five groups hyperlipidemic rats treated with aqueous extract of *Hypericum triquetrifolium* in different dosage (1000,2000,3000) mg/kg body weight, respectively, and last group hyperlipidemic rats treated with rosuvastatin drug 10 mg/kg for 60 days. The results showed that the body weight, serum cholesterol, triglyceride, low-density lipoprotein, very low-density lipoprotein, cholesterol/high-density lipoprotein ratio, and hepatic enzymes increased significantly ($p < 0.05$) in hyperlipidemia group when compared with control group, but *Hypericum triquetrifolium* have ability to reduction the level of body weight, serum cholesterol, triglyceride, low-density lipoprotein, very low-density lipoprotein, cholesterol/high-density lipoprotein ratio, as well as the low dose of *H. triquetrifolium* nonsignificantly ($p > 0.05$), prevent to increase liver enzymes, conversely the level of liver enzymes in rosuvastatin group treatment increased when compared with other treated and untreated groups. Noticeable damage of histology in testis showed degeneration in the germinal layer and fat change in liver of hyperlipidemia and rosuvastatin group, the low dose of *H. triquetrifolium* has beneficial effect on sperm parameters and histology of testis and liver. The quantity of aqueous extract of *Hypericum triquetrifolium* and antioxidant power of this plant have an essential role in their activity.

Keywords: *Hypericum triquetrifolium*; Hyperlipidemia; lipid profile; liver enzymes; Sperm parameters.

DOI: <http://doi.org/10.32894/kujss.2019.14.4.5>

التأثير الوقائي للمستخلص المائي لنبات *Hypericum triquetrifolium*

على العوامل الكيموحيوية و دراسة التغيرات النسجية في ذكور جرذان مرتفعة

شحوم الدم

يونس صالح مصطفى¹ ، كلثوم عساف مولود²

قسم علوم الحياة، كلية التربية، جامعة صلاح الدين، اربيل، العراق.

¹younssaleh87@gmail.com, ²Kalthum.maulood@su.edu.krd

الملخص

Hypericum triquetrifolium هو نبات عشبي معمر، يوجد العديد من المركبات النشطة الحيوية فيه، و هو مسؤول عن العديد من الوظائف الحيوية، لدراسة التأثير الوقائي للمستخلص المائي لنبات *Hypericum triquetrifolium* على بعض العوامل الكيموحيوية و دراسة التغيرات النسجية في ذكور جرذان مرتفعة شحوم الدم. تم تقسيم ست وثلاثون جرذاً إلى ستة مجاميع، المجموعة الأولى مجموعة التحكم (تغذت على 'العلف الطبيعي')، مجموعة مرتفعة شحوم الدم (علف ذات دهن عالي)، المجموعة الثالثة و الرابعة والخامسة تغذت على 'المستخلص المائي لنبات *H.t.* و بجرعة mg/kg (1000, 2000, 3000) وزن الجسم على 'التوالي، المجموعة الأخيرة تغذت على 'العلف ذات دهن عالي مع عقار روسفاستاتين mg/kg (10) لمدة ستين يوماً. أظهرت النتائج ان وزن الجسم ومستوى الكوليسترول والجليسريدات الثلاثية والبروتين الدهني منخفض الكثافة والبروتين الدهني منخفض الكثافة جدا و نسبة الكوليسترول للبروتين الدهني عالي الكثافة والأنزيمات الكبدية ارتفعت وبشكل معنوي في مجموعة مرتفعة شحوم الدم عند مقارنته بمجموعة

التحكم، بينما المستخلص المائي للنبات قلل من وزن الجسم و نسبة الكوليسترول والجليسيردات الثلاثية والبروتين الدهني منخفض الكثافة والبروتين الدهني منخفض الكثافة جدا و نسبة الكوليسترول للبروتين الدهني عالي الكثافة، والجرعة المنخفضة من المستخلص تسبب في منع ارتفاع الأنزيمات الكبدية، على العكس ارتفع مستوى انزيمات الكبد في مجموعة الـ *Hypericum triquetrifolium* مقارنة بالمجموعات الأخرى. لوحظ ضرر في نسيج الخصية حيث أدى الى ضمور الطبقة الجرثومية في الخصية وتغيرات دهنية في الكبد في مجموعة مرتفعة شحوم الدم والبروتينات، والجرعة المنخفضة من المستخلص كان لها تأثير ايجابي على صفات الحيوان المنوي والتغير النسيجي للخصية والكبد. ان قوة ضد الأكسدة لنبات *H.t.* لها دور مهم في اظهار فعالية النبات.

الكلمات الدالة: *Hypericum triquetrifolium*، ارتفاع شحوم الدم، مستوى الدهون في الدم، انزيمات الكبد، صفات الحيوان المنوي.

DOI: <http://doi.org/10.32894/kujss.2019.14.4.5>

1. Introduction:

Hyperlipidemia is a metabolic disorder considered that the proportion of total cholesterol, triglyceride, and low-density lipoprotein in bloodstream are increased. Hyperlipidemia has been one causes of obesity, diabetes, and eventually renal failure and other cardiac diseases, for instance, coronary heart disease, arteriosclerosis or myocardial infarction [1]. Generally, the classification of Hyperlipidemia could be included either familial Hyperlipidemia or acquired Hyperlipidemia. The features of familial hyperlipidemia are triggered by particular genetic abnormalities such as familial hypercholesteremic by mutating genes that encoding LDL receptor in both hepatic and extra hepatic tissues which is due to an increase in the level of plasma LDL-C and elevated risk to heart disease [2]. However, the acquired hyperlipidemia is not inherited, mainly defect in lipoprotein lipase (LPL) activity via many diseases such as diabetes, hyperthyroidism and some kinds of liver disease that cause reduction excretion cholesterol to bile [3]. Herbal natural medicines are becoming progressively common in the population and have been much used because mostly

demonstrated it is natural, as well as assumed harmless than allopathic medicine, limited side effects, and easier availability. However, pharmaceutical research frequently focused at discovery drug therapies to prevent or treat many heart diseases that caused by hyperlipidemia [4]. The genus *Hypericum* has belonged to the Hypericaceae family, which comprise further than 500 species, spread in various location in the world such as Europe, Asia, and Africa [5]. Many species of the *Hypericum* genus in traditional used as medicinal plants. *Hypericum triquetrifolium* Turra is one of these species, *Hypericum triquetrifolium* is an herbaceous perennial plant, grow in many places of Iraq, contain numerous of the bioactive compound responsible to several biological functions comprise anti-inflammatory, antibacterial, anti-fungal, anti-tumor, antinociceptive, anti-depression, and Antisedative effect [6]. The common component of this plant is Hyperforin, hypericin, and pseudohypericin and flavonoids. The flavonoids compound such as kaempferol, rutin, hyperoside, quercitrin, quercetin [7]. The process against oxidation was represented antioxidant; usually, organisms developed a series of defense mechanisms after exposure to free radical, numerous constituents of the plant act as an antioxidant, especially phenol class. One of the crucial antioxidants is flavonoids, which represent a range of polyphenolic compounds naturally occurring in plants [8]. The study of Kladar, Srđenović [9] believed that the process of lipid peroxidation inhibited by the antioxidant potential of *Hypericum sp.* The ability of *Hypericum sp.* to reduce Fe^{3+} to Fe^{2+} is estimated based on a method by Lesjak et al. [10]. Problems with sperm production and maturation are the most prevalent factor of male infertility leading to in a low sperm count, impaired sperm morphology or decline sperm motility [11]. Many factors are affecting sperm production and maturation may be the environment, genetic or combine both, drugs can influence negatively on infertility, these effects might include incorporating spermatogenesis impairment and change of epididymal development or other impact induce sexual dysfunction through different mechanisms, maybe by variation hormones or no hormonal mechanism [12]. Statins also called HMG-CoA reductase inhibitors represented the group of medical therapy to decline cholesterol concentration by supperssing the enzyme HMG-CoA reductase, the synthesis of cholesterol take place in the liver by activity of HMG-CoA reductase enzyme [13]. The purpose of this research to evaluate the effect of *Hypericum triquetrifolium* on the hyperlipidemic male albino rat to treat hyperlipidemia and compared with lipid-lowering drug rosuvastatin and influence on the male reproductive system.

2. Materials and Methods:

2.1 Plant Material and Extraction

Hypericum triquetrifolium Turra freshly collected from Jadida Zab (a town of Erbil city located in the Northeast of Iraq) was used. Mainly, the aerial section of the plants is chosen with a large percentage of buds and flowers in September and October in 2018. The plant was identified by Assistant professor Abdulla Shakur, Salahaddin University-Erbil, College of Education. Department of Biology, the plant was air-dried indoors at room temperature to protect it from direct sunlight, The dried, milled aerial parts at the rate of 50 g/400 ml of water at 100 °C and the material were extracted aqueously by Soxhlet extractor. The extracted was concentrated under reduced pressure to dryness in a rotary evaporator and controlled at (45 °C) to yield 7gm of plant extract, the crude extracts were kept at the freezer until used depending method of Mohammed and Kheravii [14].

2.2 Experimental Animals:

Ethical guidelines were followed for handling and performing experiments on animals, adult male Wistar rats, *Rattus norvegicus* weighing (210 ± 30) grams procured from the animal house center (College of Education, University of Salahaddin-Erbil). They kept in spacious polypropylene cages (50 cm x 30 cm x 10 cm) bedded with wood sawdust in the animal house center, standard conditions to the animal room were applied such as temperature (24 ± 3 °C) light control (12 h light/12 h dark cycle). The rats feed on standard rat chow and water ad libitum.

2.3 Induction of Hyperlipidemia:

Induced hyperlipidemia did via feeding rat cholesterol-rich high-fat diet prepared according to the method of [15] by add 5gm of cholesterol, 5 gm deoxycholic acid and 150 butter to 700 gm of powdered rat chow diet.

2.4 Drug study:

Rosuvastatin drug 10 mg was used which manufactured by Turkey (ROSUFIX 10 mg) purchased from the clinical pharmacy in Erbil province.

2.5 Experimental design:

All rats randomly allocated to six groups of six rats of each group for 60 days fed high-fat diet except the control group.

Group 1: control group (Fed standard laboratory diet+ normal saline).

Group 2: Hyperlipidemia group (High-fat diet+ normal saline)

Group 3: Hyperlipidemia group (High-fat diet + 1000mg/kg bw of *H. triquetrifolium* extract)

Group 4: Hyperlipidemia group (High-fat diet +2000 mg/kg bw of *H. triquetrifolium* extract)

Group 5: Hyperlipidemia group (High-fat diet + 3000 mg/kg bw of *H. triquetrifolium* extract)

Group 6: Hyperlipidemia group (High-fat diet +10 mg/kg bw of rosuvastatin). The applied doses for all groups were orally administrated by gavage once daily.

2.6 Body Weight and Blood Collection:

The body weights of rats were recorded for the calculation the body weight gain. Rats fasted overnight before the day blood sample was obtained. The procedure in progress by anesthetizing the rats by an injected mixed of ketamine and xylazine, Then, The blood samples drawn by puncture of heart from each rat in each group and gathering in non-heparinized tubes, the blood centrifuged at 3000 rpm for 15 minutes to prepared serum and determination of biochemical parameters like lipid panel involving (cholesterol, triglyceride, high -density lipoprotein, Low-density lipoprotein, very low-density lipoprotein levels) and liver function assay involving (Alanine aminotransferase (ALT), Aspartate aminotransferase (AST), Alkaline phosphatase (ALP), Gama Glutamyl Transferase (GGT))were determined by colorimetric method using Roche diagnostic kits (Germany) using the Auto analyzer biochemistry Cobas Integra 400 plus. However, Serum testosterone concentration was determined by the colorimetric method using Roche diagnostic kit (Germany) via Auto analyzer biochemistry Cobas E411 [16].

2.7 Epididymal Sperm Analysis:

The suspension of epididymal sperm was prepared in 3 ml of phosphate-buffered saline (PBS) at the temperature 37 °C and pH 7.2. The caudal epididymis was cut and collected in a PBS tube, and the tube contains sperm enriched epididymal fluid. The spermatozoa were analyzed for their motility, concentration, and abnormalities [17].

2.7.1 Sperm Motility:

About 200 motile and non-motile spermatozoa were observed at 400X using a light microscope and counted. Sperm motility was assessed as a percentage of motile sperm [18].

2.7.2 Sperm Concentration:

The concentration of spermatozoa was prepared via diluting the sperm suspension with PBS (1:20), then mixed, after that a drop (10 μ l) of them transfer into the Neubauer hemocytometer in each side of the counting chamber. [19].

2.7.3 Sperm Abnormality:

For the analysis of morphological abnormalities, Thin smears prepared and stained by sperm suspension in one volume was mixed with two-volume of 1% eosin&nigrosen stain. Three hundred sperms/animals being scored [20].

2.8 Ferric Reducing Antioxidant Power (FRAP) Assay:

This test was performed based on the technique described by [21]. The FRAP solution was freshly prepared, and analysis was performed by placing 100 μ L of the plant extract and 2 mL of the FRAP reagent, the samples were continuously shaken and leave in the dark location for thirty minutes. Then the absorbance at 593 nm was recorded. The standard curve of ascorbic acid was prepared for comparison using various concentrations, as shown in Fig. 1.

$$FRAP \text{ value of sample } (\mu M) = Abs. (sample) \times \frac{FRAP \text{ value of standard } (\mu M)}{Abs. of standard}$$

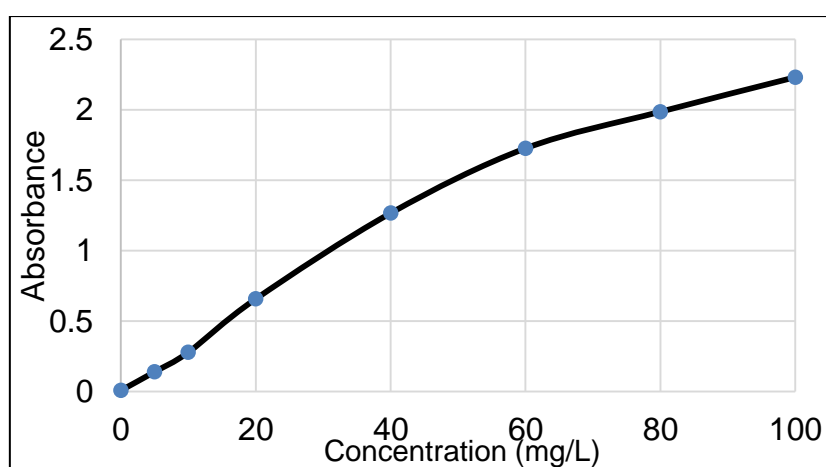


Fig. 1: The standard curve of ascorbic acid.

2.9 Histological Examination:

Animals in each group dissected, and the liver and testis were removed and fixed the tissue in 10% neutral buffered formalin solution, then the sections were prepared and stained with hematoxylin and eosin, then examined by using a light microscope [22].

2.10 Statistical Analysis:

Results are presented as mean \pm SE. All analyses were carried out using Statistical Package for Social Science (SPSS/Version 23.0) software. Data were analyzed using one-way analysis of variance (ANOVA) followed by Duncan Alpha test for comparison between groups. Probability values less than 0.05 were considered statistically significant.

3. Results:

Rats with high-fat diet group significantly ($p < 0.05$) enhanced the rate of serum cholesterol (TC), triglyceride (TG), low-density lipoprotein (LDL), very-low-density lipoprotein (VLDL) and cholesterol/high-density lipoprotein (TC/HDL) ratio as compared to the control group. However, the group of Rats that received rosuvastatin showed decreased the rate of TC, T.G, LDL, VLDL, and TC/HDL ratio significantly ($p < 0.05$) in comparison with hyperlipidemia group. In another three groups received an aqueous extract of *H.triquetrefolium* via three different doses (1000, 2000, and 3000 gm/kg bw) illustrated significant decline the rate of serum TC, T.G, LDL, VLDL, and TC/HDL ratio. Furthermore. The rate of serum high-density lipoprotein (HDL) illustrated no significant differences in all groups compared to the control group with notable elevation in all treated groups [*H.triquetrefolium* (1000, 2000, 3000 mg/kg bw) and rosuvastatin when compared with hyperlipidemia group (Table1)

Table 1: Mean \pm S.E effects of aqueous extract of *H.triquetrefolim* (1000, 2000, 3000 gm/kg) and Rosuvastatin on lipid profile in hyperlipidemic male rats and control group.

Parameter Group	TC (mg/dl)	TG (mg/dl)	.HDL(mg/dl)	.LDL (mg/dl)	VLDL(mg/dl)	TC/HDL ratio
G1	58.33 \pm 1.08 ^d	49.83 \pm 4.72 ^c	35.16 \pm 1.51 ^a	12.53 \pm 1.52 ^c	9.96 \pm 0.58 ^c	1.61 \pm 0.83 ^c
G2	118.66 \pm 3.94 ^a	146.10 \pm 6.25 ^a	33.83 \pm 2.32 ^a	56.26 \pm 3.45 ^a	29.23 \pm 1.25 ^a	3.60 \pm 0.15 ^a
G3	73.50 \pm 2.39 ^{bc}	67.16 \pm 4.28 ^b	37.50 \pm 3.03 ^a	22.56 \pm 8.8 ^{bc}	13.43 \pm 0.85 ^{bc}	2.02 \pm 0.17 ^{bc}
G4	77.66 \pm 4.70 ^{bc}	65.00 \pm 2.17 ^{bc}	36.68 \pm 4.19 ^a	26.58 \pm 4.19 ^b	13.00 \pm 0.43 ^b	2.26 \pm 0.28 ^b
G5	78.66 \pm 3.06 ^b	75.50 \pm 6.41 ^b	37.33 \pm 3.68 ^a	28.53 \pm 4.20 ^b	13.06 \pm 1.58 ^b	2.20 \pm 0.20 ^b
G6	69.50 \pm 3.37 ^c	71.16 \pm 11.08 ^b	37.66 \pm 3.15 ^a	17.50 \pm 2.96 ^c	14.33 \pm 2.21 ^b	1.85 \pm 0.03 ^{bc}

The altered letters mean statistical differences and same letters mean no statistical differences.

In the hyperlipidemia group, the activates of aspartate aminotransferase (AST) and alkaline phosphatase (ALP) increased significantly ($P < 0.05$), as well as the alanine aminotransferase (ALT) non-significant increase as compared to the control group. The administration of a low dose of *H.triquetrefolim* affected on level of ALT, AST, ALP non significantly ($P > 0.05$), middle and high dose showed a significant increase in the level of

AST. Also, the administration of rosuvastatin drug with a high-fat diet, exhibited further significant ($P < 0.05$) increase in the level of ALT, AST and ALP respectively when compared with hyperlipidemia and control group. Ultimately, there were non-significant differences of GGT among treated and non-treated groups with a slightly non-significantly increase in rosuvastatin and the high dose of *H.triquetrefolim* group. [Table 2.](#)

Table 2: Mean \pm S.E effects of aqueous extract of *H.triquetrefolim* and Rosuvastatin on serum liver function test in hyperlipidemic male rats and control group.

Parameter Group	ALT(IU/L)	AST(IU/L)	ALP (IU/L)	GGT (IU/L)
G1	42.16 \pm 2.75 ^c	134.66 \pm 5.49 ^c	116.33 \pm 3.49 ^c	4.05 \pm 0.20 ^a
G2	50.33 \pm 1.38 ^b	157.33 \pm 4.47 ^b	145.66 \pm 5.2 ^b	4.33 \pm 0.22 ^a
G3	47.66 \pm 2.81 ^{bc}	152.00 \pm 4.74 ^b	148.16 \pm 3.88 ^b	4.13 \pm 0.22 ^a
G4	54.33 \pm 3.17 ^{ab}	168.33 \pm 4.01 ^a	159.16 \pm 8.43 ^b	4.26 \pm 0.28 ^a
G5	53.16 \pm 2.98 ^{ab}	175.83 \pm 6.73 ^a	163.34 \pm 7.10 ^b	4.43 \pm 0.33 ^a
G6	59.33 \pm 2.52 ^a	167.82 \pm 5.65 ^a	228.81 \pm 9.79 ^a	4.85 \pm 0.40 ^a

The altered letters mean statistical differences, and the same letters mean no statistical differences.

On the other hand, the Table 3 indicated that the sperm count, motility in hyperlipidemia group declined significantly ($p < 0.05$) but abnormal sperm increased when compared with the control group. However, in treated groups with *H.triquetrefolim*, the sperm count increased significantly, motility increased nonsignificantly, abnormal sperm increased significantly in high dose when compared with hyperlipidemia group. Rosuvastatin drugs had a significant special effect on sperm count and abnormal sperm, as well as a nonsignificant effect on motility.

Table 3: The effects of aqueous extract of *H.triquetrefolim* and Rosuvastatin on sperm parameters in hyperlipidemic male rats and control group.

Group Parameter	G1	G2	G3	G4	G5	G6
Sperm count	141.8 \pm 13.29 ^a	110.13 \pm 14.63 ^b	128.15 \pm 9.4 ^a	127.21 \pm 5.57 ^a	123.56 \pm 6.15 ^a	117.50 \pm 6.81 ^a
Motility (%)	92.16 \pm 7.92 ^a	63.66 \pm 4.80 ^c	70.11 \pm 4.81 ^{bc}	76.11 \pm 8.13 ^{bc}	79.66 \pm 6.43 ^{ab}	74.83 \pm 3.61 ^{abc}
Abnormal sperm (%)	3.23 \pm 0.18 ^c	4.88 \pm 0.31 ^b	4.75 \pm 0.27 ^b	5.40 \pm 0.21 ^b	6.61 \pm 0.38 ^a	7.45 \pm 0.48 ^a

The altered letters mean statistical differences, and the same letters mean no statistical differences.

Bodyweight of rats changed along treated, and non-treated groups, the weight gain of hyperlipidemia group of rats elevated significantly ($p < 0.05$) compared with the control group. However, the treated groups had an adverse effect, especially in group 3 treatment, which reduced significantly, group 4 and group 5 decline nonsignificantly. However, Rosuvastatin group increased non-significantly when compared with hyperlipidemia groups Fig. 2.

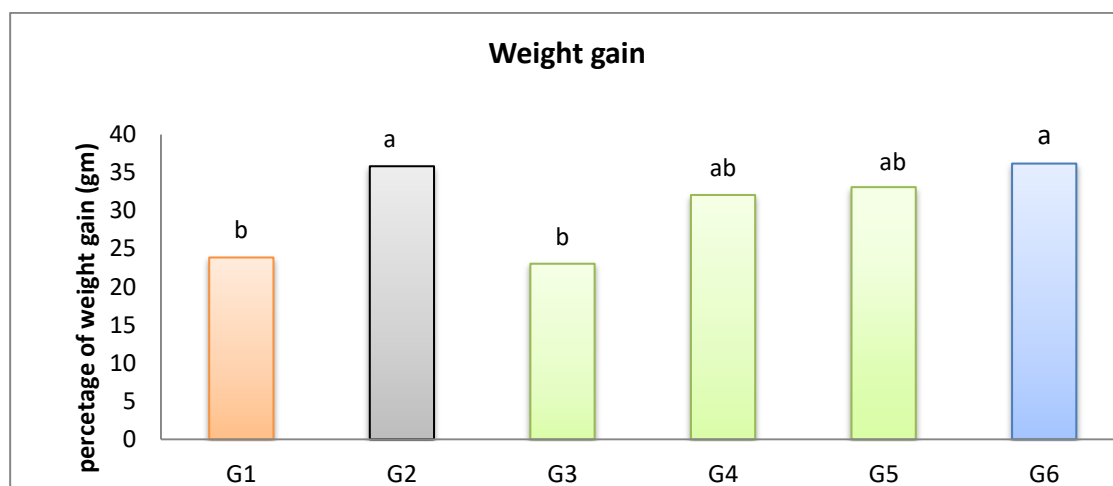


Fig. 2: Mean \pm S.E effects of aqueous extract of *H.triquetrfolim* and Rosuvastatin on body weight in hyperlipidemic male rats and control group.

There are significant differences in serum testosterone concentration among control group and hyperlipidemia groups alone or treated with rosuvastatin and *H. triquetrfolium*, and the results illustrated that the amount of serum testosterone significantly ($p < 0.05$) in hyperlipidemia group decreased compared with the control group. As well as rosuvastatin drug non-significantly decline the serum testosterone concentration compared with *H.triquetrfolim* groups and positive control group Fig. 3.

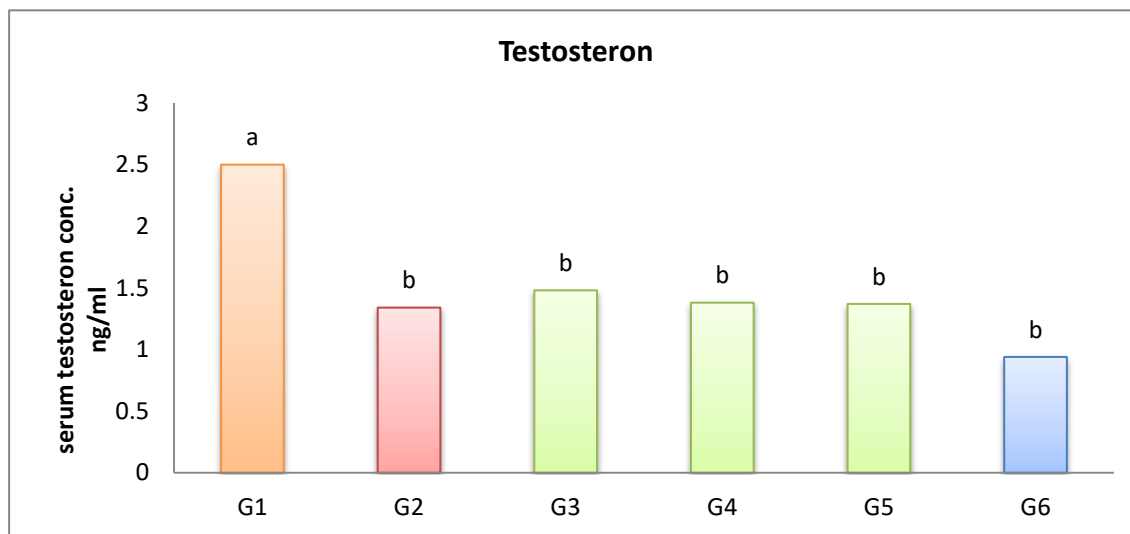


Fig. 3: Mean ± S.E effects of aqueous extract of *H.triquetrefolium* and Rosuvastatin on Testosterone concentration in hyperlipidemic male rats and control group.

The antioxidant activity of the *Hypericum triquetrefolium* extract and ascorbic acid were measured by FRAP assay and has been presented in Table 4. It showed that electron-donating groups increased reducing power. The *Hypericum triquetrefolium* indicates that they are the most operative electron donor, and the FRAP value 6787.7 $\mu\text{M/g}$ slightly decreased when compared with ascorbic acid.

Table 4: Anti-oxidant activity of the *Hypericum triquetrefolium* and ascorbic acid measured by FRAP assay.

Compounds	Absorbance	FRAP value		
		μM	$\mu\text{M/mg}$	$\mu\text{M/g}$
<i>Hypericum triquetrefolium</i> (aqueous extract)	1.887	67.877	678.77	6787.7
Ascorbic acid	2.327	83.705	837.05	8370.5

3.1 Histopathological Study :

Normal structure of seminiferous tubules in the testis of rats with a huge number of sperms in the lumen of the tubules with normal germinal layers in control group Fig. 4-A,

hyperlipidemia group showed different levels of degeneration in the germinal layer in the tubules, high-fat droplets were seen between the tubules Fig.4-B. *Hypericum triquetrifolium* in three different doses demonstrated extremely normal structure of seminiferous tubules with a lot of sperms in the lumen of some tubules Fig.4-C, in higher magnification Fig.4-D showed normal of germinal cell in the tubules when compared with hyperlipidemia group, and group 5 showed a degeneration of germinal epithelium layer Fig. 4-E. The section through the testis of Rosuvastatin group showed degeneration in the germinal layer with wide space between seminiferous tubules Fig. 4-F. The section through the liver of the control group showed normal hepatocyte Fig. 5-A. liver of hyperlipidemia group showed high-fatty change in the hepatocyte Fig. 5-B, section through liver of treated group (Hyperlipidemia + Ht 1000mg/kg bw) and (Hyperlipidemia + Ht 2000 mg/kg bw) showed few fatty change and hemorrhages between hepatocytes when compared with hyperlipidemia group Fig.5-C and D, liver of treated group (Hyperlipidemia + Ht 3000 mg/kg bw) showed few hepatocyte with fatty change Fig. 5-E with infiltration of cells in all groups of *H.triquetrifolim*, section through the liver of treated group (Hyperlipidemia +Rosuvastatin 10 mg/kg) showing fat deposition in the hepatocyte and degeneration of hepatocyte Fig. 5-F.

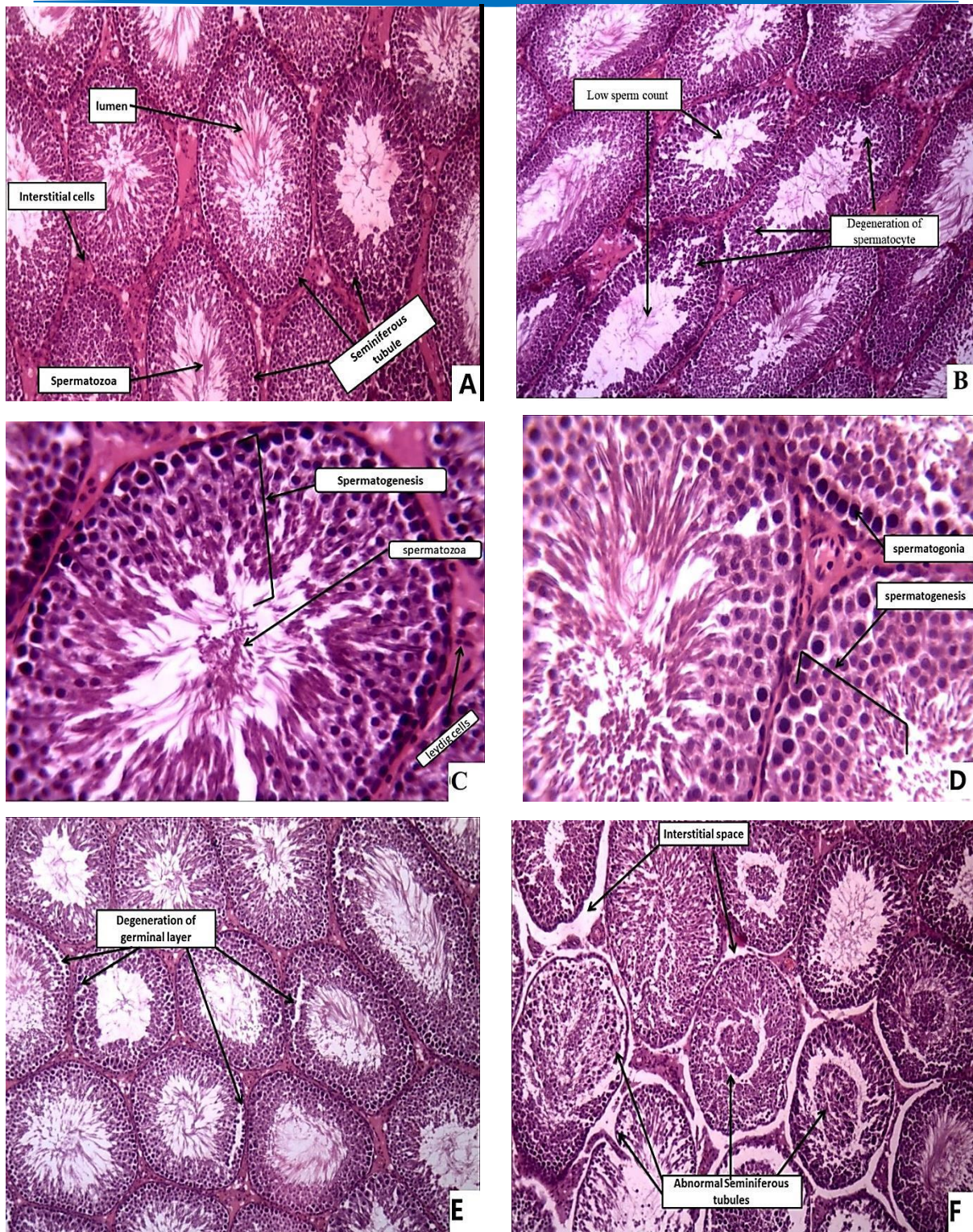


Fig. 4: Photomicrograph of rats testis: **A1:** control group, **B1:** Hyperlipidemia group, **C1:** Hyperlipidemia + Ht (1000 mg/kg), **D1:** Hyperlipidemia + Ht (2000 mg/kg), **E1:** Hyperlipidemia + Ht (3000 mg/kg), **F1:** Hyperlipidemia + Rosuvastatin Hematoxylin-Eosin

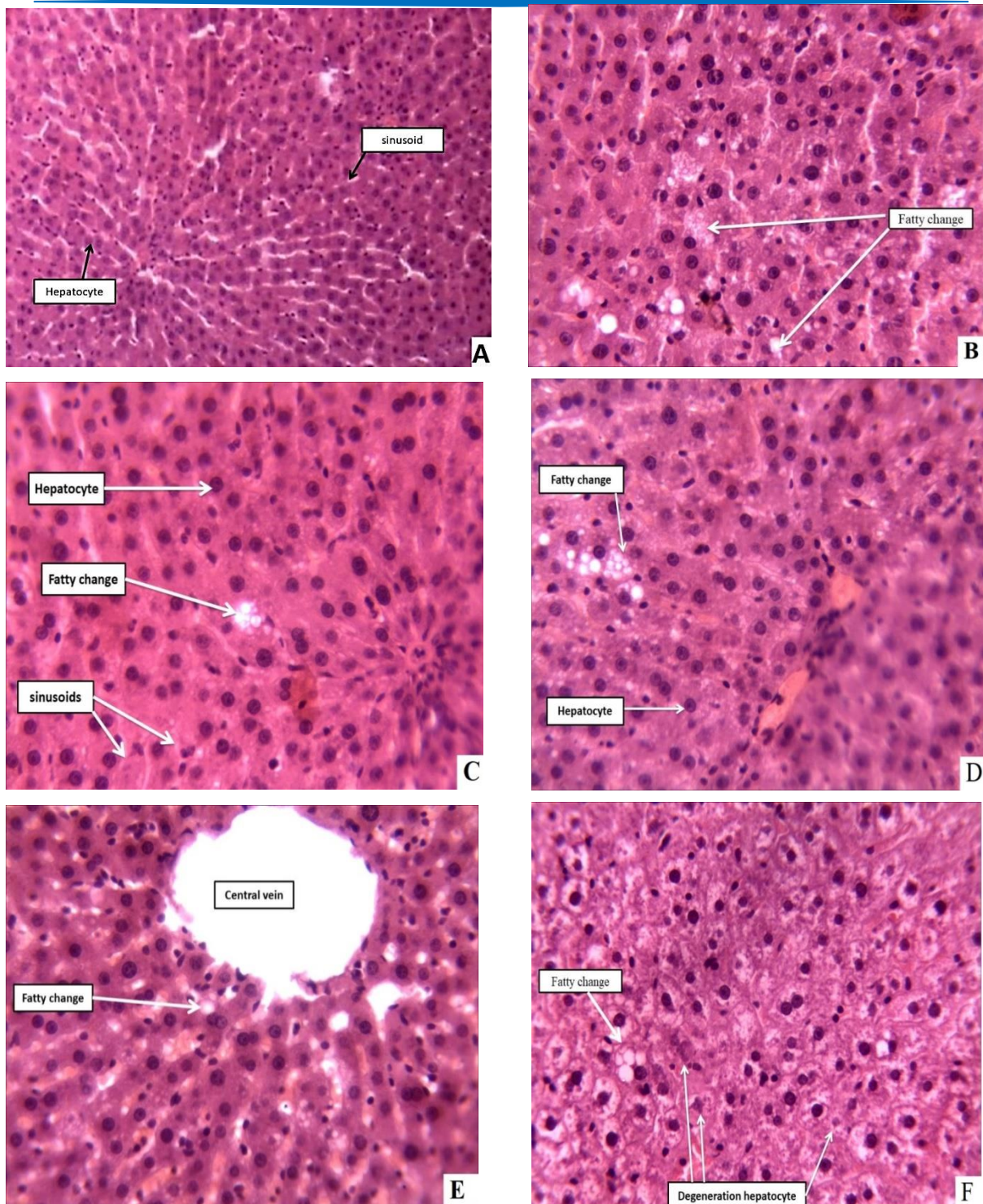


Fig. 5: Photomicrograph of rats liver: **A1:** control group, **B1:**Hyperlipidemia group, **C1:** Hyperlipidemia + Ht (1000 mg/kg) **D1:** Hyperlipidemia + Ht (2000 mg/kg), **E1:** Hyperlipidemia + Ht (3000 mg/kg) **F1:** Hyperlipidemia + Rosuvastatin Hematoxylin-Eosin stain,100 and 40x.

4. Discussion:

High-fat diet normally encourages an elevated calorie intake, high energy density, since associated with increasing body weight, circulating serum lipid profile as well as elevated adipose tissue, hepatic steatosis and glucose intolerance [23]. In our study the results illustrated that the group of rats receiving three various quantity of *Hypericum triquetrifolium* significantly affected to reduce the level of lipid profile comparison with induction hyperlipidemia rats, the LDL cholesterol extremely impressed through the low quantity of *H. triquetrifolium*. This finding is in agreement with the researcher, which elucidated the hydroalcoholic extract of *Hypericum perforatum* act as anti-atherosclerosis or hypolipidemia affect via dropping total cholesterol level [24]. Also, our study parallels with Husain, Chatterjee [25] which demonstrated the orally administrated of *Hypericum sp.* significantly decline the level of lipid profile via two possible underlying mechanisms such as blocked biosynthesis cholesterol via inhibition hydroxy-3-methyl-glutaryl-coenzyme or decline cholesterol absorption by binding the plant extract with bile acid.

In our study the TCH, TG and LDL, VLDL Ch/LDL ratio significantly reduced in group 6 compared with hyperlipidemia group, this finding agreement with many studies that illustrated the mechanism action of statin by blocking the active site of hydroxyl methyl glutaryl CoA reductase enzyme in the mevalonate pathway. This action due to blocked the conversion HMG-CoA to mevalonic acid, also may by increased cell surface LDL receptor expression [26]. The effect of statin therapy on TG metabolism, a clinical study revealed that statins could significantly decrease VLDL levels, along with inhibition cholesterol synthesis. Meanwhile, statin therapy can result in a 50% diminution in VLDL and LDL rate by their action to inhibited apoprotein B secretion into plasma [27].

In present study, determination of antioxidant activity of *H. triquetrifolium* depending on FRAP assay by compared with ascorbic acid recorded an important power activity, improved by using the low dose of *H. triquetrifolium* have activity to lowering serum level of liver enzymes and lowering fat droplets in liver tissue when compared with hyperlipidemia group, this finding parallel with Yildiz, Keskin [28] showed that the *H. triquetrifolium* reduced the level of serum liver enzymes when compared with Cyclophosphamide-Induced treated group. Meanwhile in other study illustrated hepatoprotective effect of hypericum act

as to decrease liver enzyme, and has antioxidant properties by decreased Malondialdehyde rate and increased catalase and glutathione peroxidase enzyme[29].

The activity of hepatic enzymes elevated significantly in rosuvastatin group comparison with hyperlipidemia, this finding parallel with Tzefos and Olin [30] which showed that the administration of statins related to many side effects, the most adverse effects are associated to hepatotoxicity by increasing the level of serum ALT and AST and myotoxicity. Serum alkaline phosphatase increased significantly in groups that daily received rosuvastatin (10 mg/kg), this finding was parallel to another study reported that orally administration of rosuvastatin for 21 days that cause increased AST and ALP rate, as well as, showed The serum ALP increased might be in response to the hepatocyte damage [31]. Bodyweight of rat changed along with treated and untreated groups, Jia, Liu [32] illustrated that the hyperlipidemia diet increases body weight after 28 days this finding is in agreement with our study, which noted that the overweight in hyperlipidemia group directly associated with the high-fat diet. HFD feeding is critical for obesity development because excess calorie intake can promote the development of a positive energy balance [33], HFD may due to weight gain by decreased leptin hormone delivered in adipose tissue [34]. The reduction body weight in our study might be associated with the main component of *Hypericum* such as flavonoids which can reduce the body weight; this outcome is parallel with Hsu, Wu [35]that showed the obese Wistar rats with rutin for eight weeks decline bodyweight by reduction fat storage in adipose tissue.

Furthermore. The orally administered of *Hypericum* for 15 days after prepared mixture with 0.3% carboxymethyl cellulose, showed that the *Hypericum* significantly inhibited weight gain in hyperlipidemia rats as well as improved insulin sensitivity [25]. Also, in our result, treatment with rosuvastatin increase body weight slightly compared with hyperlipidemia groups, this finding in agreement with Aguirre, Hijona [36] showed hyperlipidemia rats treated with rosuvastatin 6mg/BW showed the subcutaneous adipose tissue elevated which is related to increased adipose tissue size or maybe contribute the effect of statin in lipid metabolism by formed of fatty acid or increase the uptake of fatty acids from circulating triacylglycerol.

Hyperlipidemia usually associated with raising the circulating lipid and mainly correlated with poor quality and male infertility via the effect of testicular functions [37]. Lipid

peroxidation increased during hyperlipidemia and known as the main factor that may induce morphological alternation in spermatozoa via elevated production rate of reactive oxygen species, cause a pathological effect on sperm parameter [38]. In our study, in hyperlipidemia group, the sperm count, sperm motility, and level of testosterone decline, while the amount of abnormal sperm morphology raised when compared with the control group. This finding agrees with Zhu, Huang [39] showed that rabbit induces hyperlipidemia cause decreased level of serum testosterone by disorder effect on hypothalamus pituitary-gonadal axis and damage of spermatogenesis function. Other study showed significant reduction in testosterone may be due to increased degeneration of Leydig cells and may be attributed harmful influence on Leydig cells and Sertoli cell secretory role due to impaired effect on spermatogenesis, epididymal dysfunction, moreover, defect on epididymal properties may causing elevated sperm abnormality, significant reduction percentage of spermatozoa and motility [40]. A low dose of *Hypericum triquetrifolium* nonsignificantly decline sperm abnormality and increase sperm concentration and motility, but a middle and high dose of *H. triquetrifolium* recorded a significant increase in sperm count, abnormality, motility, as well as three doses nonsignificantly prevent the decline of serum testosterone level compared with hyperlipidemia group. However, the increased dose directly related to elevated sperm abnormalities. deleterious effect on histological testis in rats that treated with the higher dose of Hypericum in our study agreement with [Ganjalikhan Hakemi, Sharififar [41]] which showed that the source of the high dose of antioxidants and phenolic compounds have harmful effect on testicular parameters. On the other hand, our study noted that hyperlipidemia rats treated with rosuvastatin indicated that sperm abnormality significantly increased and level testosterone non significantly decreased compared with hyperlipidemia and control group but improved from motility and sperm count compared with hyperlipidemia, molecular study revealed that the HMG-CoA reductase inhibitor with statin has adverse effect on testicular steroidogenesis by inhibiting the activity of the 17-ketosteroid-oxidoreductase (17beta-hydroxysteroid dehydrogenase) enzyme, this enzyme known as key enzyme catalyze to conversion of dehydroepiandrosterone to androstenedione and androstenediol then converted to testosterone, this found reduction of testosterone not correlated with cholesterol level [42].

FRAP assay applied to evaluate the antioxidant activity of *H. triquetrifolium* compounds that are represented in Fig. 1. It illustrated that electron-donating groups increased reducing

power. Indicate that the component of hypericum they are most operative to electron donor and can decrease the peroxidation processes by declines the oxidized intermediates highly reactive molecules such as free radicals and reactive oxygen species in this essay. The higher reductive potential was determined by higher absorbance of the reaction mixture. This result supported by [43] the antioxidant activity of *H. triquetrifolium* depending other methods such as the 1,1-diphenyl-2-picrylhydrazyl (DPPH) method, reducing power in vitro and total antioxidant activity in vivo exhibited the extracted of *H. triquetrifolium* to be highly active in the DPPH radical scavenging assay, the high reducing power of extracts suggested that have a robust electron-donating capacity, furthermore ,notable have ability to decreased Fe^{2+} which is associated to lipid peroxidation, the extraction of hypericum considered a potential source of natural antioxidants.

The histological analysis testis of hyperlipidemia group rats illustrated that degeneration of germinal cell and slightly empty of lumen of seminiferous tubules compared with control group this parallel with [44] believed impaired high fat diet due to impaired spermatogenesis and histological change, this may be related to adverse effect on steroid hormones. But the hyperlipidemia groups treated with hypericum prevent histological testis damage especially low dose .conversely, rosuvastatin treated group by degeneration, abnormal somniferous tubules and increase interstitial space [45] recorded that the statin caused mild to moderate abnormal changes in the testicular tissue. However, of our study showed numerous macrovascular fat change in liver of hyperlipidemia group compared with control, it is parallel with [46] illustrated high fat diet due to disturbed the hepatic lipid metabolism such increased hepatic triglyceride accumulation may due to elevated triglyceride synthesis , decreased fatty acid oxidation or VLDL secretion, all of them are progressive to form liver steatosis or non-alcoholic fatty liver. But groups hyperlipidemia were treated with hypericum, the liver histology investigated decreased fat change of hepatocyte compared with hyperlipidemia groups and close normal appearance of hepatocyte this an agreement with [47] that revealed hypericum extract have hepatoprotective properties after intoxicated of liver with alcohol by prevent to damage of histology. the treated group with rosuvastatin showed most of hepatocyte due damage and fat accumulation, this result in agreement with [36] illustrated that the orally administrated 6 mg/kg rosuvastatin for 6 week lead to liver steatosis by more than 66 % of hepatocyte affected, as well as showed this fat accumulation by induced

rosuvastatin may related to increase *de novo* lipogenesis which is due to increase in liver triacylglycerol accumulation.

5. Conclusion:

The present study demonstrated the administration three dosages (1000, 2000, and 3000 mg/kg) of *Hypericum triquetrifolium* had a noticeable hypocholesterolemic effect by decline level of serum TC, TG, LDL, and body weight. Meanwhile had a beneficial effect to sperm parameters and hepatic enzyme compared hyperlipidemia and drug, furthermore, on the basis of result, the health benefits depended on the quantity of *Hypericum triquetrifolium* as well as has the antioxidant power activity to protective tissue, it had no detrimental effect on liver and testis histology compared with drug treatment.

References:

- [1] Xu Q-y, Liu Y-h, Zhang Q, Ma B, Yang Z-d, Liu L, et al., "*Metabolomic analysis of simvastatin and fenofibrate intervention in high-lipid diet-induced hyperlipidemia rats*", Acta Pharmacologica Sinica, 35(10), 1265 (2014).
- [2] Bunnoy A, Saenphet K, Lumyong S, Saenphet S, Chomdej S, "*Monascus purpureus-fermented Thai glutinous rice reduces blood and hepatic cholesterol and hepatic steatosis concentrations in diet-induced hypercholesterolemic rats*", BMC complementary and alternative medicine, 15(1), 88 (2015).
- [3] Onwe P, Folawiyo M, Anyigor-Ogah C, Umahi G, Okorochoa A, Afoke A, "*Hyperlipidemia: etiology and possible control* ", Journal of medical and dental sciences 14(93),100 (2015).
- [4] Mensah ML, Komlaga G, Forkuo AD, Firempong C, Anning AK, Dickson RA, "*Toxicity and Safety Implications of Herbal Medicines Used in Africa*", Herbal Medicine, 63 (2019).

- [5] Meseguer AS, Aldasoro JJ, Sanmartín I, " *Bayesian inference of phylogeny, morphology and range evolution reveals a complex evolutionary history in St. John's wort (*Hypericum*)*" , Molecular phylogenetics and evolution, 67(2), 379 (2013).
- [6] Rouis Z, Abid N, Koudja S, Yangui T, Elaissi A, Cioni PL, et al., " *Evaluation of the cytotoxic effect and antibacterial, antifungal, and antiviral activities of *Hypericum triquetrifolium Turra* essential oils from Tunisia*", BMC complementary and alternative medicine, 13, 24 (2013).
- [7] Roz N, Rehavi M," *Hyperforin depletes synaptic vesicles content and induces compartmental redistribution of nerve ending monoamines*", Life sciences,75(23), 50 (2004).
- [8] Orčić DZ, Mimica-Dukić NM, Francišković MM, Petrović SS, Jovin ED," *Antioxidant activity relationship of phenolic compounds in *Hypericum perforatum L**", Chemistry Central Journal, 5(1), 34 (2011).
- [9] Kladar N, Srđenović B, Grujić N, Bokić B, Rat M, Anačkov G, et al., " *Ecologically and ontogenetically induced variations in phenolic compounds and biological activities of *Hypericum maculatum subsp. maculatum, Hypericaceae**", Brazilian Journal of Botany, 38(4), 15 (2015).
- [10] Lesjak MM, Beara IN, Orčić DZ, Anačkov GT, Balog KJ, Francišković MM, et al., " *Juniperus sibirica Burgsdorf. as a novel source of antioxidant and anti-inflammatory agents*", Food Chemistry, 124(3), 6 (2011).
- [11] Boyle CA, Khoury MJ, Katz DF, Annest JL, Kresnow M-j, DeStefano F, et al., " *The relation of computer-based measures of sperm morphology and motility to male infertility*", Epidemiology, 46 (1992).
- [12] Semet M, Paci M, Saïas-Magnan J, Metzler-Guillemain C, Boissier R, Lejeune H, et al., " *The impact of drugs on male fertility: a review*", Andrology, 5(4), 63 (2017).



- [13] Koo BK," *Statin for the primary prevention of cardiovascular disease in patients with diabetes mellitus*", Diabetes & metabolism journal, 38(1), 4 (2014).
- [14] Mohammed BM, Kheravii SK," *Evaluation of genotoxic potential of Hypericum triquetrifolium extract in somatic and germ cells of male albino mice*", Research Opinions in Animal & Veterinary Sciences, 1(4), 9 (2011).
- [15] Belagali Y, Ullal SD, Shoeb A, Bhagwath V, Ramya K, Maskeri R," *Effect of vanillin on lipid profile in a model of hyperlipidemia, a preliminary study*", Indian Journal of experiental Biology, 51, 91(2013).
- [16] Kane J, Middle J, Cawood M," *Measurement of serum testosterone in women; what should we do*", Annals of clinical biochemistry, 44(1), 5 (2007).
- [17] Wyrobek A, Bruce W, "*Chemical induction of sperm abnormalities in mice*", Proceedings of the National Academy of Sciences, 72(11), 9 (1975).
- [18] Linder RE, Strader LF, McElroy WK," *Measurement of epididymal sperm motility as a test variable in the rat*", Bulletin of environmental contamination and toxicology, 36(1), 24 (1986).
- [19] Bairy L, Paul V, Rao Y," *Reproductive toxicity of sodium valproate in male rats*", Indian journal of pharmacology, 42(2), 4 (2010).
- [20] Hamadouche NA, Sadi N, Kharoubi O, Slimani M, Aoues A," *The protective effect of vitamin E against genotoxicity of lead acetate intraperitoneal administration in male rat*", Archives of Biological Sciences,65(4), 45 (2013).
- [21] Hidalgo M, Sánchez-Moreno C, de Pascual-Teresa S," *Flavonoid–flavonoid interaction and its effect on their antioxidant activity*", Food chemistry, 121(3), 6 (2010).

- [22]. Buncharoen W, Saenphet S, Chomdej S, Saenphet K," *Evaluation of biochemical, hematological and histopathological parameters of albino rats treated with *Stemona aphylla Craib. extract**", Journal of Medicinal Plants Research,6(27), 35 (2012).
- [23] Picchi MG, Mattos AMd, Barbosa MR, Duarte CP, Gandini MdA, Portari GV, et al., "*A high-fat diet as a model of fatty liver disease in rats*", Acta cirurgica brasileira, 26, 25 (2011).
- [24] Asgary S, Solhpour A, Parkhideh S, Madani H, Mahzouni P, Kabiri N," *Effect of hydroalcoholic extract of *Hypericum perforatum* on selected traditional and novel biochemical factors of cardiovascular diseases and atherosclerotic lesions in hypercholesterolemic rabbits: A comparison between the extract and lovastatin*", Journal of pharmacy & bioallied sciences, 4(3), 8 (2012).
- [25] Husain GM, Chatterjee SS, Singh PN, Kumar V," *Hypolipidemic and antiobesity-like activity of standardised extract of *Hypericum perforatum L. in rats**", ISRN pharmacology, 2011 (2011).
- [26] Lennernäs H, Fager G," *Pharmacodynamics and pharmacokinetics of the HMG-CoA reductase inhibitors*", Clinical pharmacokinetics, 32(5), 25 (1997).
- [27] Ginsberg HN," *Effects of statins on triglyceride metabolism*", The American journal of cardiology, 81(4), 5B (1998).
- [28] Yildiz SC, Keskin C, Ayhanci A," *Investigation of invitro Antioxidant and invivo Protective Effects of *Hypericum triquetrifolium* Seed Methanol Extracts against Cyclophosphamide-Induced Acute Myelotoxicity, Hemotoxicity and Hepatotoxicity in Rats*", (2018).
- [29] Bayramoglu G, Bayramoglu A, Engur S, Senturk H, Ozturk N, Colak S," *The hepatoprotective effects of *Hypericum perforatum L. on hepatic ischemia/reperfusion injury in rats**", Cytotechnology, 66(3), 8 (2014).

- [30] Tzefos M, Olin JL, " *3-hydroxy-3-methylglutaryl coenzyme A reductase inhibitor use in chronic liver disease: a therapeutic controversy*", Journal of clinical lipidology, 5(6), 9 (2011).
- [31] Dodiya H, Kale V, Goswami S, Sundar R, Jain M, " *Evaluation of adverse effects of lisinopril and rosuvastatin on hematological and biochemical analytes in wistar rats*", Toxicology international, 20(2), 170 (2013).
- [32] Jia Y-J, Liu J, Guo Y-L, Xu R-X, Sun J, Li J-J, " *Dyslipidemia in rat fed with high-fat diet is not associated with PCSK9-LDL-receptor pathway but ageing*", Journal of geriatric cardiology: JGC, 10(4), 361 (2013).
- [33] Amin KA, Nagy MA, " *Effect of Carnitine and herbal mixture extract on obesity induced by high fat diet in rats*", Diabetology & metabolic syndrome, 1(1), 17(2009).
- [34] Ainslie DA, Proietto J, Fam BC, Thorburn AW, " *Short-term, high-fat diets lower circulating leptin concentrations in rats*", The American journal of clinical nutrition, 71(2), 42 (2000).
- [35] Hsu CL, Wu CH, Huang SL, Yen GC, " *Phenolic compounds rutin and o-coumaric acid ameliorate obesity induced by high-fat diet in rats*", Journal of agricultural and food chemistry, 57(2), 31 (2009).
- [36] Aguirre L, Hijona E, Macarulla M, Gracia A, Larrechi I, Bujanda L, et al., " *Several statins increase body and liver fat accumulation in a model of metabolic syndrome*", J Physiol Pharmacol, 64(3), 8 (2013).
- [37] Lancellotti TES, Boarelli PV, Monclus MA, Cabrillana ME, Clementi MA, Espínola LS, et al., " *Hypercholesterolemia impaired sperm functionality in rabbits*", PloS one, 5(10), e13457 (2010).



- [38] Bansal AK, Bilaspuri GS," *Impacts of oxidative stress and antioxidants on semen functions*", Veterinary medicine international, 2010 (2010).
- [39] Zhu Z, Huang Y, Pan L, Xu H, Xia X," *The effects of dietetic hyperlipidemia on the development of testes and penises in male New Zealand rabbits*", Zhonghua nan ke xue= National journal of andrology,11(12), 7 (2005).
- [40] Bashandy AS," *Effect of fixed oil of Nigella sativa on male fertility in normal and hyperlipidemic rats*", Int J Pharmacol,3(1), 27 (2007).
- [41] Ganjalikhan Hakemi S, Sharififar F, Haghpanah T, Babae A, Eftekhar-Vaghefi SH, "*The Effects of Olive Leaf Extract on The Testis, Sperm Quality and Testicular Germ Cell Apoptosis in Male Rats Exposed to Busulfan*", International journal of fertility & sterility,13(1), 57 (2019).
- [42] Smals AG, Weusten JJ, Benraad TJ," *The HMG-CoA reductase inhibitor simvastatin suppresses human testicular testosterone synthesis in vitro by a selective inhibitory effect on 17-ketosteroid-oxidoreductase enzyme activity*", The Journal of steroid biochemistry and molecular biology, 38(4), 8 (1991).
- [43] Kızıllı G, Kızıllı M, Yavuz M, Emen S, Hakimoğlu F, "*Antioxidant Activities of Ethanol Extracts of Hypericum triquetrifolium. and Hypericum scabroides*",Pharmaceutical Biology, 46(4), 42 (2008).
- [44] Mu Y, Yan W-j, Yin T-l, Zhang Y, Li J, Yang J," *Diet-induced obesity impairs spermatogenesis: a potential role for autophagy*", Scientific reports,7, 43475 (2017).
- [45] Bustan AA, Jawad AM," *The effect of two types of statins (rosuvastatin and atorvastatin) on the fertility of male and female mice*", Journal of Advances in Medicine and Medical Research, 1 (2017).



-
- [46] Wang Y-M, Zhang B, Xue Y, Li Z-J, Wang J-F, Xue C-H, et al., "*The mechanism of dietary cholesterol effects on lipids metabolism in rats*", *Lipids in health and disease*, 9(1), 4 (2010).
- [47] Roman I, Cristescu M, PUICĂ C, "*Effects Of Hypericum Perforatum And Hypericum Maculatum Extracts Administration On Some Morphological And Biochemical Parameters In Rat Liver Intoxicated With Alcohol*", *Studia Universitatis Vasile Goldis Seria Stiintele Vietii (Life Sciences Series)*,21(2), (2011).