

Prevalence of intestinal parasites in *Rattus rattus* in some districts in Baghdad/ Iraq

Sh. A. Majeed

Zoonosis Diseases Research Unit- College of Veterinary Medicine/ Baghdad
University of Baghdad

Abstract

Sixty three 63 rats (*Rattus rattus*) were trapped from some districts in Baghdad governorate (Adhamiyah, Kadhimiya and Amreya), and examined in parasites laboratory for detecting intestinal parasites. The total infection prevalence of intestinal parasites was 45 (71.42%) out of 63 fecal samples with significant differences ($P < 0.05$). The study revealed the black rats were infected with three species of parasites (1 protozoa, 2 cestoda and 1 Acanthocephalan); *Giardia* spp. 38(60.31%), *Hymenolepis nana* 4(6.34%), *Hymenolepis diminuta* 2(3.17%) and *Moniliformis moniliformis* 1(1.58%). The intestinal parasites revealed significance prevalence value at ($P < 0.05$). There was differences of statistical between male and female for parasites infection that which higher rate 35 (83.33%) in males than 10(47.61%) in females. The results concluded that importance of rats in transmission of zoonotic parasites diseases to humans. Also used new methods for human prevention from rodents as well as, promotion and education to risk rodents for humans.

Key words: Rat (*Rattus rattus*), *Giardia* spp., *Hymenolepis nana*, *Hymenolepis diminuta*, *Moniliformis moniliformis*.

E. mail: Sh2012ah1980@yahoo.com

انتشار الطفيليات المعوية في جرذ (*Rattus rattus*) من بعض المناطق في محافظة بغداد/ العراق

شيماء احمد مجيد

وحدة بحوث الامراض المشتركة- كلية الطب البيطري/ جامعة بغداد

الخلاصة

تم اصطياد 63 جرذ من نوع (*Rattus rattus*) من بعض المناطق في محافظة بغداد (الأعظمية، الكاظمية والعامرية) وفحصت في المختبر للكشف عن الطفيليات المعوية. وكانت نسبة انتشار الطفيليات 45(71.42%) من أصل 63 عينة براز مع وجود اختلافات معنوية ($P < 0.05$). كشفت دراسة عن إصابة الجرذان السوداء بثلاثة أنواع من الطفيليات (1 protozoa، 2 cestoda، و 1 Acanthocephalan)؛ وكانت نسبة الإصابة بطفيلي *Giardia* spp. 38 (60.31%)، *Hymenolepis nana* 4 (6.34%)، *Hymenolepis diminuta* 2 (3.17%) و *Moniliformis moniliformis* 1 (1.58%) ويفروق معنوية ($P < 0.05$). كان هناك ارتفاع في الذكور بمعدل 35 (83.33%) مقارنة بالاناث 10 (47.61%) حيث كانت هناك فروق ذات دلالة إحصائية بين الذكور والاناث للإصابة بالطفيليات. نستنتج من النتائج إلى أهمية الجرذان في نقل الأمراض والطفيليات المشتركة للإنسان. كذلك استخدام طرق جديدة للوقاية من الامراض التي ينقلها الجرذ، اضافة عن ترويج وتعليم الانسان من خطر القوارض.

الكلمات المفتاحية: جرذ (*Rattus rattus*)، الطفيليات المعوية، *Giardia* spp., *Hymenolepis nana*, *Hymenolepis diminuta*, *Moniliformis moniliformis*.

Introduction

Rodents, particularly those living in contact with humans, play important role in public health and economy because they are important reservoirs for parasitic zoonosis such as trichinellosis and capillariosis (1). Rats are rodents that live around human (commensal rodentia). It may spread many diseases to human, cattle and pets. Some mechanisms of disease transmission by saliva, urine, and feces of their parasites (2). Many reported have been done of distribution of parasites among black rats in different countries of the world. Easterbrook *et al.* (3) examined 162 rats in Baltimore, Maryland, USA. Endoparasites detected were mainly *Nippostrongylus braziliensis* (71.6%) and *Hymenolepis diminuta* (34.4%). Siti Shafiyah *et al.* (4) recorded six genus of parasites in wild rats and the most common intestinal helminth parasite detected was *Nippostrongylus brasiliensis* (80.3%), followed by *Hymenolepis nana* (23.4%), *Capillaria hepatica* (13.9%) and *Hymenolepis diminuta* (2.9%). Intestinal protozoan detected was *Entamoeba histolytica E. dispar* (8.8%) in urban area of Kuala Lumpur, Malaysia. Elshazly *et al.* (5) reported that the overall prevalence of helminths was 52.8%, the commonest cestode detected was *H. diminuta* and the commonest nematode detected was *Capillaria hepatica* in studies the prevalence of helminths in rodents in Egypt. In Iraq, Rahemo *et al.* (6) examined Twenty-Five adult albino rats in College-Salahaddin University-Erbil Endoparasites detected were *Trichomonas muris* with the higher incidence of 56%, followed by *Scyphacia muris* 24%, *Giardia muris* 12%, *Hexamita muris* 8% and the least infection percentage was 4% for both *Entamoeba muris* and *Hymenolepis* spp. Karim and Al-Salihi (7) examined four adult *Sprague-Dawley* male rats in Diagnostic Study on accidental *Hymenolepis diminuta* Infection in Laboratory Rats present investigation 3/4 (75%) rats were found to be infected with tapeworms. The aim of this study was to survey of some zoonosis endoparasites in black rat (*Rattus rattus*) and their relationship between black rats and humans also to evaluate the risk for transmission to humans. We examined rat found in different habitats in Baghdad governorate.

Material and Methods

- Collection of samples

- **Animals:** during May to November/ 2015, sixty three black rats (*Rattus rattus*) were caught from some districts in Baghdad (Adhamiyah, Kadhimiya and Amreya), including old building and garbage, steel wire traps were used and baited with cheese and fresh vegetable and meat; these rats were collected the and were then brought to laboratory and examined immediately the following morning. Morphometric measurements were taken, together with records of length and weight body (4).
- **Traps:** trapped rats were killed humanely by anesthesia (9:1, ketamine and xylazine) per 100 gm. rat body weight after were caught from tail and interperitoneal injection as accorded by (8).

- Examination of samples

- **Simple smear:** All fecal and alimentary tract contents evacuated and used centrifugal flotation and sedimentation techniques were accorded by (9), and examined under microscope.
- **Sample staining:** by taken 2 mg of feces and mixing with a drop of Lugol's iodine wet mount on a glass microscope slide and placing a cover slip on the feces suspension for detection of parasitic eggs, cysts and larva describe by (10) and used power ($\times 10$), ($\times 40$) objective of microscope for examination.
- The helminths were isolated and put in 70% alcohol. Cestodes were stained with Semichon's carmine and fixed as a permanent slide accorded by (11). While, protozoa were cleared with Giemsa stain and fixed on a temporary slide accorded. The helminth species were described by (12, 13).
- **Statistical analysis:** by using parametric parameter Chi Square (χ^2) to compare between different parameters which are affecting on intestinal parasites. To analyze data using SPSS program (14).

Results and Discussion

A total of 63 black rats 45 (71.42%) were positive with intestinal parasites in all examined black rats fecal sample by direct, flotation and sedimentation techniques during the period from June to December 2015 (Table 1). The prevalence of intestinal parasites species showed in high rate of protozoa: *Giardia spp.* was 38 (60.31%) (Fig. 1, 2), while cestode include two species *Hymenolepis nana* and *Hymenolepis diminuta* were 4(6.34%), 2(3.17%) respectively (Fig. 3, 4), so low rate of *Moniliformis moniliformis* was 1(1.58%) (Fig. 5) at significant differences ($P<0.05$). (Table 2). Out of 42 black rats males, 35(83.33%) were positive while on the contrary, out of 21 black rats females, 10 (47.61%) were positive with significant differences ($P<0.05$) (Table 3).

Table (1) A total prevalence of intestinal parasites species in *Rattus rattus*

Animals	No. examined	No. of Positive Rats	Prevalence%
<i>Rattua rattus</i>	63	45	71.42

*($p<0.05$)

Table (2) Prevalence of intestinal parasites species in *Rattus rattus*

Class	parasites	No. of Positive Rats	Prevalence %
protozoa	<i>Giardia spp.</i>	38	60.31*
Cestode	<i>Hymenolepis nana</i>	4	6.34
	<i>Hymenolepis diminuta</i>	2	3.17
Acanthocephalan	<i>Moniliformis moniliformis</i>	1	1.58

*($p<0.05$)

Table (3) Prevalence of intestinal parasite species according to sex of *Rattus rattus*

Black rat sex	No. examined	No. positive	Prevalence %
Male	42	35	83.33*
Female	21	10	47.61
Total	63	45	71.42

*($p<0.05$)

Three genera of helminthes and one protozoa (*Hymenolepis nana*, *Hymenolepis diminuta*, *Moniliformis moniliformis* and *Giardia spp.*) in this study recorded from 45 (71.42%) of the black rats. This results is asymptotic with this observed by (4) who recorded that the prevalence of 137 samples, 112 (81.8%) samples were positive with intestinal parasites. Also (15) who referred that the prevalence of infection with intestinal parasites was 66.2%. In this study the parasites *Giardia spp.* is heavy intestinal infection of rats 38(60.31%). This protozoa was also reported by previous studies among wild rats in Saudi Arabia 7(14.2%) but the low rate (16) and in Baghdad/Iraq was 85(32.94%) (17). Also it was found in the *Rattus norvegicus* in Turkey (18). The prevalence of cestoda *Hymenolepis nana* was 4(6.34%) (The dwarf tapeworm) was the most common cestoda found in this study. Other previous studies also recorded this parasite in their studies among wild rats; in Iran were lower at rate (2.5%) (19) and it was (2.44%) in Sicily, Italy (20). While in Malaysia was higher at rate (23.4%) (4). Also in Saudi Arabia (20.4%) (16). Other cestoda found in small intestine *Hymenolepis diminuta* was 2(3.17%). This result was agreement with the other studies (21) and (4) who recorded that *Hymenolepis diminuta* was (3.8%) and (2.9%) respectively. while, disagreement with (15) who reported higher prevalence of *Hymenolepis diminuta* was (11.8%) also (19) who mentioned that *H. diminuta* infection rates of rats was (38.8%) and (20) who referred that *Hymenolepis diminuta* was (39.02%). The acanthocephalan *Moniliformis moniliformis* was also found in this study at rates 1(1.58%). *M. moniliformis* is also recognized as a zoonotic parasite of public health (22, 23, 24). This results agreement with (15) who recorded that *Moniliformis moniliformis* was (1.5%) while, disagreement with (19, 20) who found that *Acanthocephalan sp.* were (2.44%) and (11.3) in *Rattus rattus* respectively.




Fig. (1) Cyst of *giardia spp.* (x40)

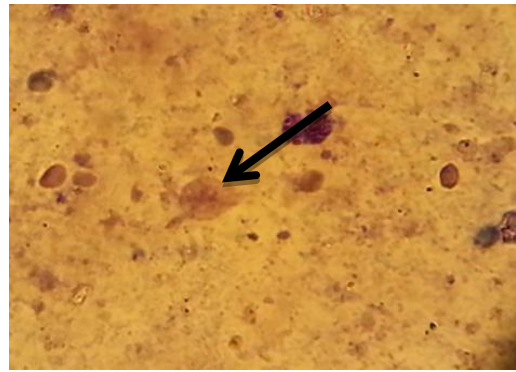


Fig. (2) Trophozoite of *giardia spp.*(x40)

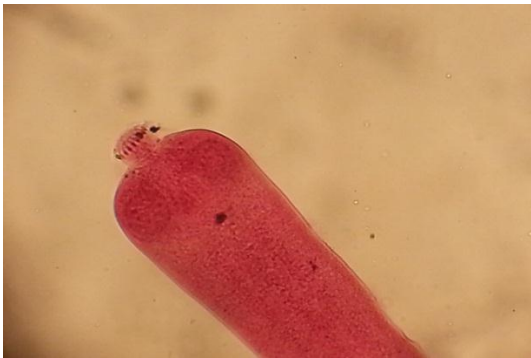

Fig. (3) *Hymenolepis nana* (x10)

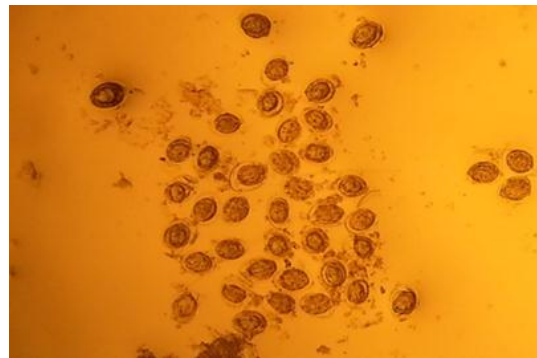


Fig. (4) Eggs of *Hymenolepis diminuta* (x10)

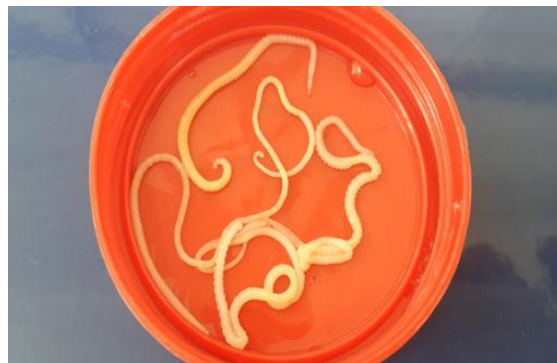

Fig. (5) Worm of *Moniliformis moniliformis*

Thus, when comparison with the previous studies, it was found that the prevalence of black rats intestinal parasites increase and decrease it may be attributed to several factors; number of animals, differ of area in many countries, geographical variabilities and number of samples which taken. The results of the present study revealed the differences in percentage of positive samples according to the sex. However, males showed higher percentage rate 35 (83.33%) than females black rats 10 (47.61%). The results of the current study are agreed with other scientific studies that were recorded by (4) who investigated that more male rats were captured (61%) compared to female (39%) in Malaysia and (15) who recorded that in male rats was 28 (73.7%) and in female 17 (56.7%) from Northern and Northeastern Thailand. This study detected that intestinal parasites are highly prevalent in rats in Baghdad governorate. Also the prevalence of black rats is that very importance and more dangerous due to transmit many parasitic zoonosis diseases and it could be a reservoir host to humans and animals lead to a great epidemiological important particularly in garbage collected and the increase in the number of slums in big cities contribute significantly to the spread of many zoonosis parasitic diseases in areas according to human close residence.

Reference

1. Stojčević, D.; Marinculić, A. & Mihaljević, Ž. (2002). Prevalence of *Capillaria hepatica* in Norway rats (*Rattus norvegicus*) in Croatia. Veterinarski arhiv 72 (3): 141-149.
2. Priyanto, D.; Rahmawati, A. & Ningsih, D. P. (2014). Identification of endoparasites in rats of various habitats. Health Science Indones, 5 (1): 49-53.
3. Easterbrook, J. D.; Kaplan, J. B.; Glass, G. E.; Watson, J. & Klein, S. L. (2008). A survey of rodent-borne pathogens carried by wild-caught Norway rats: a potential threat to laboratory rodent colonies. Lab. Anim., 42(1): 92-98.
4. Siti Shafiyah, C. O.; Jamaiah, I.; Rohela, M.; Lau, Y. L. & Siti Aminah, F. (2012). Prevalence of intestinal and blood parasites among wild rats in Kuala Lumpur, Malaysia. Trop. Biom., 29(4): 544-550.
5. Elshazly, A. M.; Awad, S. I.; Azab, M. S.; Elsheikha, H. M.; Abdel-Gawad, A. G.; Khalil, H. H. & Morsy, T. A. (2008). Helminthes of synanthropic rodents (Rodentia: Muridae) from Dakahlia and Menoufia, Egypt. J. Egypt. Soc. Parasitol., 38(3): 727-740.
6. Rahemo, Z. I. F.; Ahmed, R. K. & Koyee, Q. M .K. (2012). Intestinal Parasites of Experimental Rodents with Testing the Efficacy of Diagnostic Methods. Int. Res. J. Pharm., 2 (3): 77-81.
7. Karim, A. J. & Al-Salihi, K. A. (2014). Diagnostic Study on accidental *Hymenolepis diminuta* Infection in Laboratory Rats in Iraq. Mirror of Research in Veterinary Sciences and Animals (MRVSA), 3(3): 33-40.
8. Struck, M. B.; Andrutis, K. A.; Ramirez, H. E. & Battles, A. H. (2011). Effect of a short-term fast on Ketamine-Xylazine Anesthesia in Rats. J. Am. Assoc. Lab. Anim. Sci., 50(3): 344-348.
9. Beaver, P. C. & Jung, R. C. (1985). Animal agents and vectors of human disease (5th ed.) Philadelphia: Lea & Fibiger, P. 281.
10. Downes, F. P. & Ito, K. (2001). Compendium of methods for the microbiological examination of foods. 4th ed., Washington, DC, American Public Health Association.
11. Garcia, L. S. & Ash, L. R. (1979). Diagnostic parasitology clinical laboratory manual, 2nd ed., C.V. Mosby Co., St. Louis, P.174.
12. Yamaguti, S. (1958). The digenetic trematodes of vertebrates part I: Volume I. Systema helminthum. New York: Interscience Publishers Inc.
13. Anderson, R. C. (2000). Nematode parasites of vertebrates: their development and transmission. 2nd ed. New York: CABI Publishing.
14. SPSS. (2008). Statistical package for the social sciences, Version 16 and 17 (Win/Mac/Linux), User's guide SPSS Inc., Chicago III, USA.
15. Chaisiri, K.; Chaeychomsri, W.; Siruntawineti, J.; Ribas, A.; Herbreteau, V. & Morand, S. (2010). Gastrointestinal Helminth Infections in Asian House Rats (*Rattus tanezumi*) from Northern and Northeastern Thailand. J. Trop. Med. Parasitol., 33:29-35.
16. Al-Bashan, M. M. & Sabra, S. M. (2012). Prevalence of some enteric parasites in rats at Taif governorate with special reference to associated pathogenic bacteria. Afr. J. Microbiol. Res., 6(14): 3431- 3439.
17. Al-Robeey, H. M. A. (2007). Study of Giardia parasites in the wild rats. Al Qadisiya J. Vet. Med. Sci., 6(1): 91-94.
18. Beyhan, Y. E. & Hökelek, M. (2014). Giardia muris Infection in Laboratory Rats (*Rattus norvegicus*) and Treatment with Metronidazole. Turkiye Parazitolo Derg., 38: 181-184.

19. Kia, E. B.; Shahryary-Rad, E.; Mohebali, M.; Mahmoudi, M.; Mobedi, I.; Zahabiun, F.; Zarei, Z.; Miahipoor, A.; Mowlavi, G. H.; Akhavan, A. A. & Vatandoost, H. (2010). Endoparasites of Rodents and Their Zoonotic Importance in Germe, Dasht-e-Mogan, Ardabil Province, Iran. *Iranian J. Parasitol.*, 5 (4):15-20.
20. Milazzo, C.; Cagnin, M.; Di Bella, C.; Geraci, F. & Ribas, A. (2010). Helminth Fauna of Commensal Rodents, *Mus musculus* (Linnaeus, 1758) and *Rattus rattus* (Linnaeus, 1758) (Rodentia, Muridae) in Sicily (Italy). *Rev. Ibero-Latinoam. Parasitol.*, 69 (2): 194-198.
21. Hasegawa, H.; Kobayashi, J. & Otsuru, M. (1994). Helminth Parasites Collected from *Rattus rattus* on Lanyu, Taiwan. *J. Helminthol. Soc. Wash.*, 61(1): 95-102.
22. Sinniah, B. (1979). Parasites of some rodents in Malaysia. *Southeast Asian J. Trop. Med. Public. Health.*, 10:115-121.
23. Walter Beck, J. (1959). Report of a possible human infection with the acanthocephalan *Moniliformis moniliformis* (Syn. *M. dubius*). *J. Parasitol.*, 45: 510.
24. Moayedi, B.; Izadi, M.; Maleki, M. & Ghadirian, E. (1971). Human infection with *Moniliformis Moniliformis* (Bremser, 1811) Travassos, (1915 Syn. *Moniliformis dubius*), report of a case in Isfahan, Iran. *Am. J. Trop. Med. Hyg.*, 20:445-448.