



Macroscopical Anatomy and Radiographic Study of the Non-Lactating Udder of Adult Local Iraqi Cow (*Bos taurus*)

Salah H Al-Maliki* , and Mahdi A Atyia 

Department. of Anatomy and Histology, College of Veterinary Medicine, University of Baghdad, Iraq

*Correspondence:
almalikisalah@yahoo.com

Received: 23 March 2020
Accepted: 1 September 2020
Published: 28 December 2020

DOI:
[https://doi.org/10.30539/ijvm.v44i\(E0\).1030](https://doi.org/10.30539/ijvm.v44i(E0).1030)



This article is an open access distributed under the terms and conditions of the Creative Commons Attribution License (CC BY 4.0)

Cite:
Al-Maliki SH, Atyia MA. Macroscopical anatomy and radiographic study of the non lactating udder of adult local Iraqi cow (*Bos taurus*). Iraqi J. Vet. Med. 28 Dec. 2020; 44(E0):100-105

A B S T R A C T

The purpose of this study was to describe some anatomical and radiological features of the non-lactating udder of adult local Iraqi cow. Eight udder of local breed cow clinically appeared healthy and aged between 2-5 years were obtained from a local slaughterhouse located at Baghdad province. Five udders were used for anatomical study and the rest 3 udders were used for the radiological study. The study primed to describe the macroscopic anatomy of the udder and investigate the udder's normal blood supply using red-colored latex. The mammography method was to describe the duct system of the glandular tissue of the mammary gland which was performed using the iodine compound and barium sulphate as contrast media. The results showed that the udder was located in the inguinal region and covered by pigmented skin with fine hair and composed of four quarters. Each quarter has one teat which was long, cylindrical in shape, opened with one orifice; and internally has longitudinal folds in its mucous membrane. The blood supply of udder by the external pudendal arteries (left and right) branched into cranial and caudal mammary ones. The radiological study showed that the glandular tissue of udder was composed of complex ducal system which included the teat canal (long narrow), teat sinus (spindle-shaped cavity), lactiferous sinus (large round structure), lactiferous ducts, cistern ducts, interlobular duct, intralobular duct and alveoli (round sac like). In conclusion, this study is considered as an important contribution of describing the anatomical features, main blood supply and a pathway of the intraglandular duct system of the non-lactating udder in local cow breed which is necessary for surgical operations in several cases of the udder.

Keywords: Iraqi cows, Udder, teat, non-lactating, radiography

INTRODUCTION

Globally, cattle breeds are given a greatest interest in the farmer's work due to their high milk production and recurrent pregnancy and producing calf (1). Local Iraqi cow breed is one of the most important animals because of considering of them as a main source of milk and meat

production which are essential components of human nutrition.

In Iraq, the cattle are primary dairy animals, many dairy products are prepared from cow milk including thick cream, butter, cheese, and the cow milk is mixed with buffalo milk and marked as sterilized milk (2). The local Iraqi cow breed is highly resistance to local infectious

diseases, and it is the greatest interest in the Iraqi republic (3, 4).

The udder of cattle is located in the inguinal region and is consisted of four separated glands suspended at medial and lateral collagen lamina. The medial lamina is more elastic than the lateral lamina and more collagenous and is originated from the sub pelvic tendon while, the lateral lamina is multiple. The teat is long and cylindrical in shape with thick wall (5, 6).

The study of the arteries and their branches which supply the udder is considered as a very important idea to avoid puncturing the blood vessels during the surgical operation (7).

The radiography is a useful tool is used to evaluate the morphological characteristics of the udder and teats in cattle and to summarize the data related to ultrasound examination in cows (8, 9). The radiography is used to determine any blocking in the teat canal; read the length and diameter of the teat canal and determine the teat cistern diameter and teat wall thickness (9). Due to a lack of anatomical and radiological studies on the udder of local breed cow, this study was designed to provide best data on the udder to increase the milk production.

MATERIALS AND METHODS

Experimental Animals

The procedures used in this study were reviewed and approved by the scientific committee at the University of Baghdad's College of Veterinary Medicine in compliance with animal welfare ethical standards.

This study was designed to investigate the anatomical and radiological study of the non-lactating udder of apparently healthy local Iraqi cow aged between 2-5 years, eight udders (5 anatomical and 3 in radiological studies).

The udders collected from Al-shoala slaughterhouse in Baghdad province, immediately after slaughtering the animal. The udders were selected were free from any pathological lesions with avoiding inducing any accidental injury to the udder tissue.

Anatomical Study

For the anatomical study, 5 healthy udders of the collected udder cow were included. Dissecting and removing the udder from carcasses was the first step, then washing by tap water and kept in clean plastic containers.

The gross anatomy was recorded including weight, shape of its four quarters (fore and hind), the shape of the teat, teat canal, size of udder (using water displacing method) (10), the length and diameter of the base and apex of each teat.

For blood supply, the connective tissue was carefully dissected from one side (right or left) to reach the mammary artery using tap water, then the udders were

injected through the mammary artery with red colored latex (latex+ammonia+carmine stain) using 50 ml syringe and plastic catheter which was inserted inside the milk artery on one side of udder.

The glacial acetic acid was used with cotton to prevent any loss of latex may result from cutting small arteries. After completing the injection, the mammary artery was closed by using artery forceps and immersed in 10% formalin container for studying the blood supply after dissecting the udder.

Radiological Study

Three non-lactating udders of adult local Iraqi cow breed were collected to be used in radiological study. The udders were injected by contrast media through the teat orifice by several small dosages which started with injection 1ml, second injection 4 ml, third injection 10ml followed by 20ml and ended by 50ml then radiological examination was taken after each dosage to follow the routes of the ductal system of each gland.

Iodine compound also used barium sulphate were the contrast media which was used in this study using 50ml syringe; closure of the teat orifice was done by ligation then the radiological captures were taken.

The barium sulphate was usually used in living tissue but when it used in this study it showed more details of the ductal system in the udder of cows.

The contrast media was injected manually and carefully in several doses with radiological image to be taken after each dose until the intra glandular ductal system completely filled with contrast media.

X-ray digital machine with KV (80), time of exposure is 10 msec, and focus film distance FFD (80 cm) were used to examine the udders radiographically (11).

RESULTS AND DISCUSSION

Macroscopic Anatomy

The present findings showed that the udder in non-lactating local Iraqi cow (*Bos taurus*) was located in the inguinal region and composed of two halves (left and right). Externally, both halves were separated by median inter mammary groove (Figure1). Same result was reported by (12, 13) in small ruminants. Each half was consisted of two quarters (fore and hind) (Figure 1). This result was different from that observed in small ruminants in which each half was consisted of one quarter (12, 13).

The udder was covered by pigmented skin with fine hair until the base of the teat. In general, the shape of the udder in Iraqi cow was ellipsoidal, flattened horizontally and soft ventrally. The base of each quarter was slightly concave and sloped obliquely (Figure1). Similar finding was reported by (5) in the udder of local Iraqi cattle (*Bovidae caprinae*).

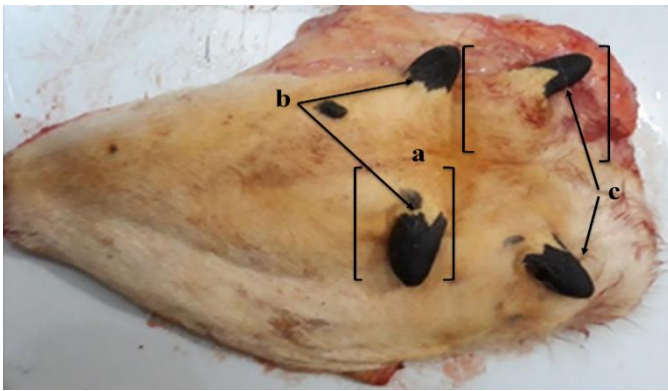


Figure 1. Photograph of ventral view in non-lactating udder of local Iraqi cow shows the external features: (a) intra mammary groove, (b) Fore teats of the fore quarters, (c) Hind teats of the hind quarters

The shape of the teat was short cylindrical, opened with one orifice, externally covered by pigmented skin with fine hair (Figure 1). Internally, the mucous membrane of the teat canal had longitudinal folds (Figure 2). This finding was similar to that of (5) in local Iraqi cattle (*Bovidae caprinae*) (6, 14, 15) and in cow (16) and in she camel.

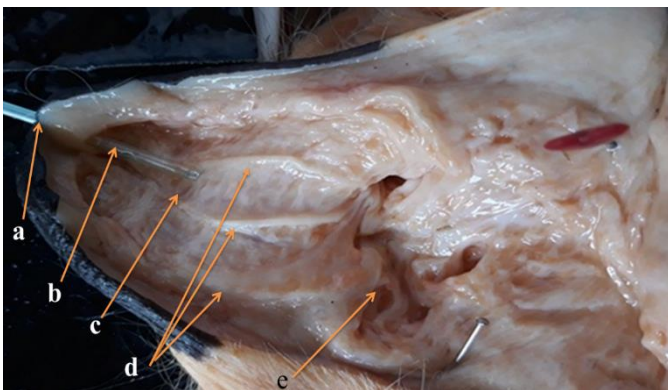


Figure 2. Photograph of opened teat of mammary gland of local Iraqi cow shows: (a) Teat orifice, (b) Teat canal, (c) Teat sinus, (d) lactiferous sinus, (e) Longitudinal folds

Comparing to other ruminants, the teat in she goat was conical in shape, wide at the base, and protrudes-like funnel in shape, internally the mucous membrane of the teat canal shows numerous longitudinal folds (12, 13). While in ewes, the teat is short, cylindrical and the mucous membrane had no longitudinal folds which appeared smooth (12).

The average weight of udder was about 1995 g, while the average volume was about 1900ml. In black local goats, the average weight was about 248.21 g, and the average volume of dry udder was about 245.00 mL (13). In general, the slightly differences in measurements between these findings and that of those authors might be due to the age or genetic made up and nutritional (17) in cow.

The average length of teat from the base to the apex and diameter of base and apex of the fore right teat were 4.26

cm, 2.64 cm, and 1.10 cm, respectively. While in the fore left teat, the above measurements were 4.65 cm, 2.62 cm, and 1.08 cm, respectively. In the hind right teat, they were 5.25 cm, 3.21 cm, and 1.18 cm, respectively. While in the hind left teat, they were 5.88 cm, 3.10 cm, and 1.15 cm, respectively (Table 1) but (16) noted in She-Camel, the average length and diameter of base and apex of the fore left teat were 3.65 cm, 2.59 cm and 0.84 cm, respectively. In the fore right teat, they were 4.26 cm, 2.65 cm, and 0.90 cm, respectively. In the hind left teat, they were 3.88 cm, 3.11 cm and 1.12 cm, respectively, while in the hind right teat 4.25 cm, 3.32 cm, and 1.20 cm, respectively (16).

Table 1. The biometric measurements of teats in non-lactating udder of Iraqi cow (cm) (Mean±SD)

Teat position	Teat length	Teat base diameter	Teat apex diameter
Fore right teat	4.26±1.667	2.64±0.145	1.10±0.947
Fore left teat	4.65±1.842	2.62±0.147	1.08±0.978
Hind right teat	5.25±2.165	3.21±0.411	1.10±0.947
Fore right teat	5.88±2.198	3.10±0.534	1.15±0.934

The present finding showed that the blood supply of udder by the external pudendal arteries (left and right) which branched into the cranial and caudal mammary branches (Figure 3).

The cranial mammary artery was anastomosed with caudal mammary artery to form a ring around the base of the udder (Figure 3). The caudal parts of the base of the udder were supplied by internal pudendal artery (Figure 3, 4). These findings were in agreement with (18) in the dog and similar as described by (19, 20) in the cow.

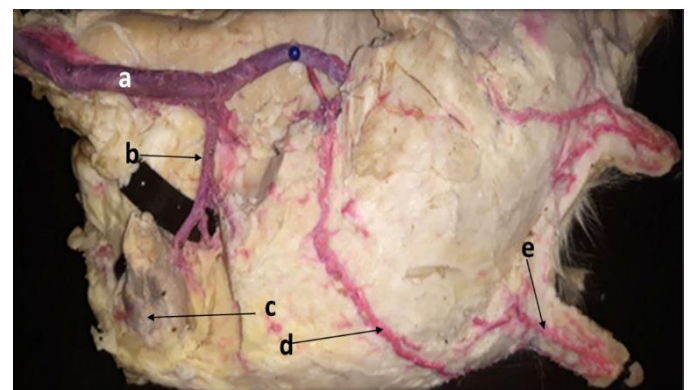


Figure 3. Photograph of udder of local Iraqi cow with injected blood vessels shows: (a) External pudendal artery, (b) Branch of supramammary lymph node, (c) Supramammary lymph node, (d) Caudal mammary artery, (e) Papillary artery

The diameter of external pudendal arteries (Figures 3, 4, and 5) and their branches in local Iraqi cow were smaller to that in Holstein Friesian cattle breed (21, 22). This fact might be due to the milk production amount of the udder according to the cattle breed.

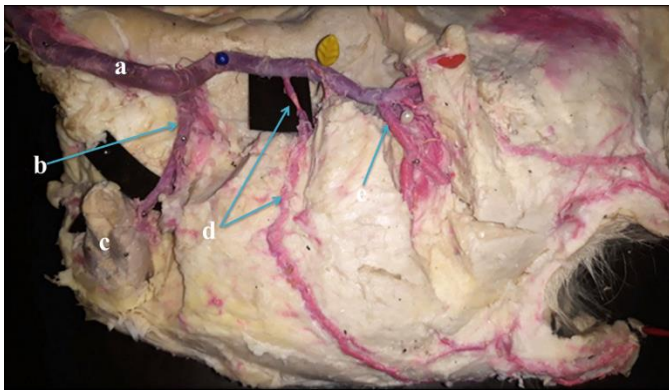


Figure 4. Photograph of Udder of local Iraqi cow with injected blood vessels shows: (a) External pudendal artery, (b) Branch of supramammary lymph node, (c) Supramammary lymph node, (d) Caudal mammary artery, (e) Cranial mammary artery

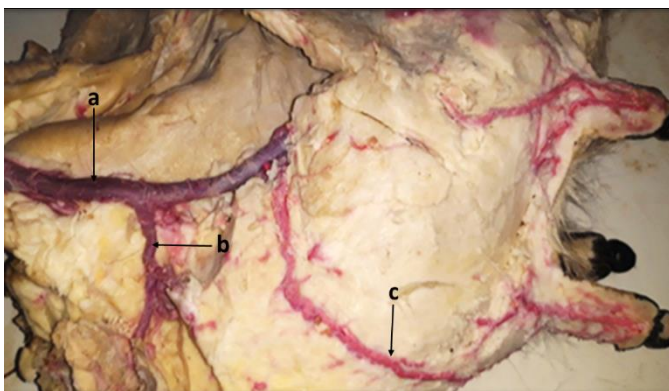


Figure 5. Photograph of Udder of local Iraqi cow with injected blood vessels showing: (a) External Pudendal artery, (b) Branch of supramammary lymph node, (c) Cranial mammary artery

Radiological Study

Mammography was a special term of radiographic anatomy used to describe the distribution of ductal system of mammary gland (11).

The mammography finding of the present study showed that at start of injection 1ml of contrast medium through teat orifice of one quarter, the contrast media move through teat canal (streak canal) which appeared long, narrow (Figure 6) similar observations were early found (12) in she goat, (16) in she-camel and (23) in one humped camel but in ewe, the teat canal appeared smooth, and this fact was recorded by (12).

The second injection 4 mL of contrast media for showing teat sinus (teat cistern) which appeared as spindle-shaped cavity pointed distally to the teat streak (Figure 7). Al-Hakeem (16) also noted two teat sinuses which appeared as spindle-shaped cavity pointed distally to the teat streak in she camel while the (23) recorded that teat cistern small rounded in one humped camel. The third injection 10ml the contrast media for showing the lactiferous sinus (gland cistern) which appeared as large round structure and connected distally to the teat sinus (Figure 8).

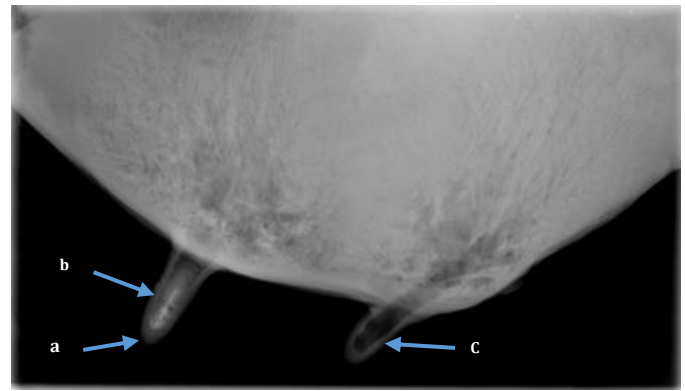


Figure 6. Radiographic picture of the fore quarter in non-lactating udder (1 mL of Iopromide contrast media) shows: (a) The teat orifice, (b) The teat canal, (c) Teat without contrast media




Figure 7. Radiographic picture of the fore quarter in non-lactating udder. (4 mL of Iopromide contrast media) shows: (a) The teat orifice, (b) The teat canal, (c) teat sinus

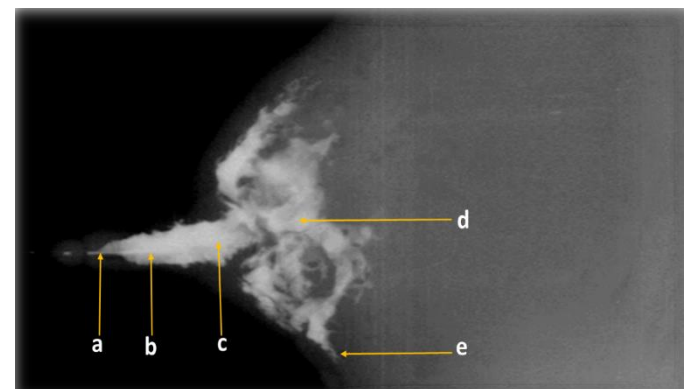


Figure 8. Radiographic image of the fore quarter in non-lactating udder (10 mL of barium sulfate contrast media) shows: (a) Teat orifice (b) Teat canal (c) Teat sinus (d) Lactiferous sinus (e) Lactiferous duct

Then injected 20 mL, the contrast media for showing lactiferous ducts and cistern ducts (Figure 9) similarly was also noted by (23) recorded that gland cistern appeared as large round structure in one humped camel but in one dose of contrast media, and Atyia MA (2009) noted the lactiferous sinus to appear irregular in shape of ewe but in she goat the lactiferous sinus clearly divided into two parts (12).

When the contrast media was increased due to high dose injection 50ml of the contrast media, the interlobular and intralobular ducts and round sac like alveoli were seen (Figure 10). This finding was similar to that of (5) in the udder of local Iraqi cattle and (23) in one humped camel same result.

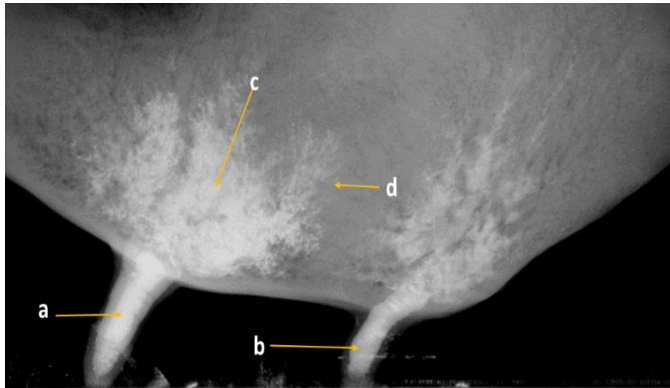


Figure 9. Radiographic image of the left halve in non-lactating udder (20 mL of barium sulfate contrast media) shows: (a) Teat canal of fore quarter (b) Teat canal of hind quarter, (c) Lactiferous sinus (d) Alveolus

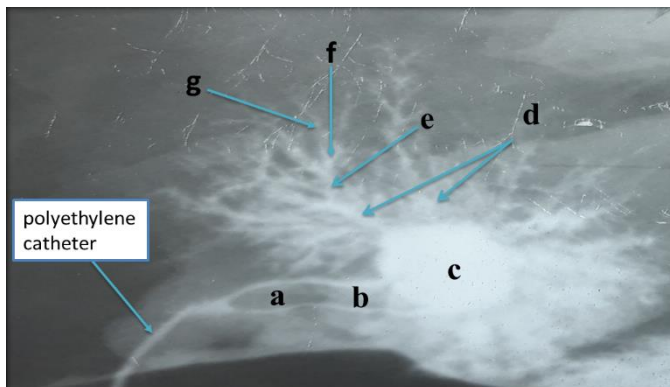


Figure 10. Radiographic image of the quarter in lactating udder (50 mL of Iopromide contrast media) shows: (a) Teat canal (b) Teat sinus (c) Lactiferous sinus, (d) Lactiferous duct, (e) Collecting duct (f) Interlobular duct (g) Alveoli

ACKNOWLEDGEMENTS

I would like to express my sincere gratitude and appreciations to dean of the College of Veterinary Medicine and to the vice dean for Postgraduate Studies and Scientific Research for helping me in completion this work.

FUNDING

Authors declare that above-submitted work was not funded by any governmental or private funding source nor supported by any financial projects.

CONFLICT OF INTEREST

The authors declare that there is no conflict of interest.

REFERENCES

- Zigo F, Adamova A, Vasil M, Elecko J, Ondrasovicova S, Zigova M, et al. The impact of mastitis on reproductive parameters of dairy cows. *Folia Veterinaria*. 2019; 63(3):72-78.
- AL-Sadi HI. Animal wealth in Iraq and means of improving it. *Iraqi J. Vet. Sci.* 1980; 28(1): 203-204.
- Al-Zubaid AAN, Yousif AA. Prevalence and antimicrobial susceptibility of *Salmonella* species isolate from slaughtered cows in Iraq. *Iraqi J Vet. Med.* 2012; 37(1): 96-101.
- AL-Shemmari IGM, Al-Judi AMH. Molecular identification by multiplex polymerase chain reaction of *Pasteurella multocida* in cattle and buffaloes in Baghdad. *Iraqi J. Vet. Med.* 2013; 38(1): 99-106.
- ALSadi SE, Fadeal TH. Anatomical and histological study in the udder of local Iraqi cattle (*Bovidae caprinae*). *Bas. J. Vet. Res.* 2018; 17(3): 446-448.
- Frandsen RD, Wilke WL, Fails ADTL, editors. *Anatomy and Physiology of Farm animals*. 5th ed. Philadelphia: Lee and Feibiger; 1992. p 80-270.
- Ducharme NG, Arighi M, Homney FD, Livesey MA, Hurtig MH, Pennock P. Invasive teat surgery in dairy cattle: part I-surgical procedures and classification of lesions. *Can Vet J.* 1987;28(12):757-62.
- El-Sayed EH, Hassan LR, Saifelnasr EOH, Ashmawy TAM. Ultra-structure study of mammary gland in Zaraibi goats during different stages of lactation. *Egyptian J. Sheep & Goat Sci.* 2013;8(2):33-45.
- Szencziowa I, Strapak P. Ultrasonography of the udder and teat in cattle: perspective measuring technique. *Slovak J. Anim. Sc.* 2012; 45(3): 96-104.
- Linzell JL. Measurement of udder volume in live goats as an index of mammary growth and function. *J Dairy Sci.* 1966;49(1):307-311.
- Thrall DE, Widmer WR. *Radiation Protection and Physics of Diagnostic Radiology*. In: Thrall DE. *Textbook of Veterinary Diagnostic Radiology*. 7th ed. USA: Elsevier, Inc; 2018. p. 2-21.
- Atyia MA. Anatomical histological and radiological study of the mammary gland in the small ruminant. *Bas. J. Vet Res.* 2009; 8(2):10-20.
- Al-Mayahi MS. Anatomical, histological and radiological study of gall bladder and biliary duct system (extra and intra hepatic) in small Ruminants [Thesis]. Baghdad, Iraq: University of Baghdad; 2008.
- Reece WO. *Functional anatomy and physiology of domestic animals*. 4th ed. Ch.5. Sensory organs Iowa, USA: Wiley-Blackwell; 2009. p.513-519.
- Dyce KM, Sack WO, Wensing CJ. *Textbook of Veterinary Anatomy*. 4th ed. Philadelphia. London. New: WB. Saunders Company; 2010. p.727-735.
- Al-Hakeem YA. Anatomical, histological and radiological study of lactating and non-lactating mammary gland of She-Camel (*Camelus dromedarius*) [Thesis]. Baghdad, Iraq: University of Baghdad; 2005.
- Tilki M, Inal F, Colak M, Garip M. Relationships between Milk Yield and Udder Measurements in Brown Swiss Cows. *Turkish J. Vet. Anim. Scien.* 2005; 29(2): 75-81.
- Hristakiev L, Georgiev GI, Altankova R, Georgiev GD, Sapundzhiev E. Histologic features of the dog's mammary glands blood supply. *TMVM* 2016; 1(1):15-20.
- Pandey Y, Taluja JS, Vaish R, Pandey A, Gupta N, Kumar D. Gross anatomical structure of the mammary gland in cow. *J. Entomol. Zool. Stud.* 2018; 6(4):728-733.
- Akers RM. *Lactation and the mammary gland*. Text of animal health. 3rd ed. Iowa State University. Press: Ames, Iowa; 2002. p.500-555.

21. Boujenane I. Effects of milking frequency on milk production and Composition of Holsteincows during their first Three Lactations. Iranian Journal of Applied Animal Science. 2019; 9(1): 25-29.
22. Campos MS, Wilcox CJ, Head HH, Webb DW, Hayen J. Effects on Production of milking three times daily on first lactation Holsteins and jersey in Florida. Journal of Dairy Science. 1994; 77(3): 770-3.
23. RizkHM, Khalifa EF, Abdelgalil A. Comparative morphometric overview between the two milk systems of the mammary gland of one humped camel (*Camelus dromedarius*). Research J.Pharma, Bio.l Chem. Scien. 2017; 8(3): 4-9.

دراسة تشريحية وشعاعية للغدة الثديية الغيرمدرة للحليب في الابقار (*Bostaurus*) المحلية العراقية البالغة

صلاح حسن المالكي و مهدي عبد الكريم عطية

فرع التشريح و الانسجة كلية، الطب البيطري، جامعة بغداد

الخلاصة

تم جمع ثمانية من الغدد اللبنية من الابقار المحلية العراقية البالغة باعمار (2-5) سنوات من مجزرة الشعلة في بغداد، بعد ذبح الحيوان تم فحص الضرع ووصف الشكل الخارجي تم تقسيمها الى مجموعتين، خمس عينات للدراسة التشريحية وثلاث عينات للدراسة الشعاعية. هدفت الدراسة الوصف الضرع تشريحيًا بضمنها الحلمات وكذلك دراسة التجهيز الدموي للضرع من خلال حقن مادة ملونة داخل الشرايين. كذلك هدفت الدراسة الى تحديد الجهاز القنوي للضرع شعاعيا بواسطة استخدام مركبات اليود وسلفات الباريوم كمواد تحقن داخل الجهاز القنوي. لوحظ من خلال الدراسة ان الضرع في الابقار العراقية البالغة يقع في المنطقة الاربعة ويكون مغطى بواسطة جلد مخضب يحوي على القليل من الشعر الدقيق. يتكون الضرع من اربعة ارباع وكل ربع يمتلك حلمة طويلة واسطوانية واحدة وتفتح بفتحة واحدة ولا تحوي حلمات الضرع داخلها على الطيات الطولية في غشائها المخاطي. لوحظ ان التجهيز الدموي للضرع في الابقار المحلية يتم من خلال الشريان الاستحياني الخارجي الذي يتفرع الى فرع لبنى امامي واخر خلفي. لوحظ في الدراسة الشعاعية ان النسيج الغدي للضرع يتكون من جهاز معقد من القنوات التي تتضمن قناة الحلمة التي تكون واسعة ودائرية. جيب الحلمة الذي هو عبارة عن تجويف حلزوني، جيب الحليب ويكون واسع ودائري. قناة الحليب صهريج الحليب، وكذلك قنوات دقيقة تنتهي بتكوين كيسى ودائري يسمى الحويصلات المسولة عن انتاج الحليب.

الكلمات المفتاحية: الابقار العراقية، ضرع، حلمة، غير مرضعة، تصوير شعاعي