

# Segmentation and Isolation of Brain Tumors Using Different Images Segmentation Methods

Ahlam A. Hussain \*<sup>1</sup>, Sarmad.H. Mahal<sup>2</sup> , Ban S. Ismael<sup>2</sup> 

<sup>1</sup>Department of Remote Sensing and GIS, College of Science, University of Baghdad, Baghdad, Iraq.

<sup>2</sup>Department of Astronomy and Space, Collage of Science, University of Baghdad, Baghdad, Iraq.

\*Corresponding Author.

Received 02/09/2022, Revised 07/05/2023, Accepted 09/05/2023, Published Online First 20/01/2024,  
Published 01/08/2024



© 2022 The Author(s). Published by College of Science for Women, University of Baghdad.

This is an open-access article distributed under the terms of the [Creative Commons Attribution 4.0 International License](https://creativecommons.org/licenses/by/4.0/), which permits unrestricted use, distribution, and reproduction in any medium, provided the original work is properly cited.

## Abstract

Brain tumors are an anomaly growth or mass of cells in or around the brain tissues. Brain tumors are two types either malignant (cancerous) or benign (noncancerous), all of these can affect children and adults. Tumors of the brain can impact human brain function if they grow large enough to press on surrounding tissues. Brain tumor is an inherently serious and life threatening. The brain tumor diagnosis is depending on the specialist, but it may give different diagnoses which may vary from one specialist to another depending on the accurate diagnosis of tumor size. To avoid that, in many cases computer is used as an aided method for the segmentation of brain tumor. Segmentation in image processing is the process of dividing regions into different parts depending on various criteria such as intensity, homogeneity and other. In this study, many segmentation techniques are used to segment the brain tumors of MRI images: Edge detection methods (Sobel, Prewitt, and Canny); thresholding methods using different threshold (T) values; and K-Means clustering methods with different numbers of cluster (K). From the results of segmentation methods, it is clear that, edge detection methods are failed to segment and isolate the region of tumor, thresholding segmentation method gives a good result when using  $T=150,200$  for some cases. While K-Means segmentation method is successful to segment and isolate the tumor of the brain for one case when using two clusters ( $K=2$ ).

**Keywords:** Brain's tumor, Edge detection, K-Means, Segmentation techniques, Thresholding.

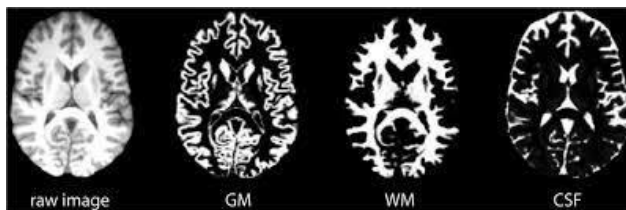
## Introduction

A tumor is abnormal cell growth in the body, it is a very dangerous disease which affected human life. So, it is important to detect tumors early to save life. Tumors may have occurred in various human bodies as the tumor of brain. A tumor of brain has various sizes as well as shapes, and they required different treatment procedures. More than 120 types of brain's tumor are existing classified as primary and metastatic. Primary brain tumors start in brain tissues. The secondary brain tumors start in other

body tissue and spread to brain. It is found the primary tumor is developing more in children. But the metastatic tumor is more common in adults. Tumors are categorized into the benign and malignant depending on the tumor's characteristics. The benign tumors are sluggishly growing and less aggressive while the malignant tumor is rapidly growing and life threatening <sup>1</sup>.

The image of a normal brain contains many tissues such as: White Matter (WM); Gray Matter

(GM); and Cerebrospinal Fluid (CSF) as illustrated in Fig. 1. To diagnose the structure of human's brain many medical imaging techniques are used: Computed Tomography (CT); Positron Emission Tomography (PET); and Magnetic Resonance Imaging (MRI) medical imaging, which provide information from a variety of excitation sequences about the brain tissues<sup>1,2</sup>. In this study MRI brain images are used.



**Figure 1.** Shows the MRI images with GM, WM, and CSF<sup>2</sup>.

### Magnetic Resonance Imaging (MRI)

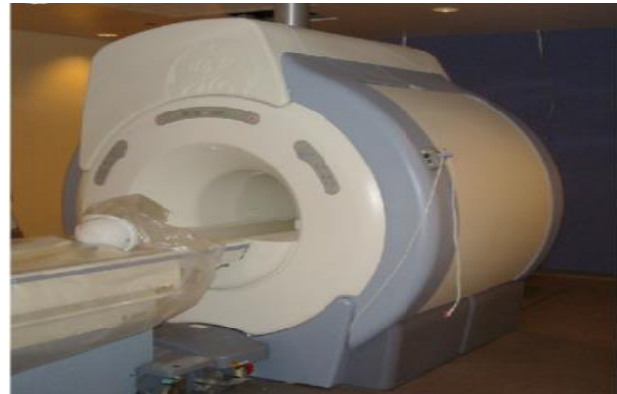The MRI is defined as the non-invasive method of imaging the internal structures and certain facets of function in the human's body. MRI using the Radio Frequency (RF) with the presence of strong magnetic fields to generate high three dimensions correctional MRI images of the human's body. The MR Image is obtained by placing the patient on a table as illustrated in Fig. 2 and applying the magnetic field that affects the nuclei of many atoms in the body (especially Hydrogen atoms) and aligns them with the external magnetic field. Then applied RF signal to the specific part that will be imaged. When the application of RF signal is stopped, the energy is

## Materials and Methods

### Segmentation Methods

In general, the segmentation process divides the image into various regions based on pixel characteristics. MRI brain image, the separating of tumor tissues from different normal tissues is done by manual segmentation process. Segmentation of brain's tissues is very important to detect and diagnose the brain diseases. But it's hard task due to the unpredictable anatomical brain's structure, existence of intensity inhomogeneity, partial volume effects, and noise. The disorders of brain can be identified exactly by the segmentation of the brain's

released from the human's body. The released signals are detected and used to construct the MR image by the computer<sup>3</sup>.



**Figure 2.** The MRI machine<sup>4</sup>.

### Brain Tumor Segmentation

The basic benefit of MRI is the visualization of soft tissues. But the MR images need enhancement due to the presence of noise. Then, the segmentation method isolates the brain tumor in MR images, after that, the segmented tumor's region analysis and classify as malignant and benign. To detect brain tumor, MR imaging is combined with automatic; manual; and semi-automatic brain segmentation. The manual segmentation is performed computer's software, but it has variation problems as it takes longer and gives inaccurate results that differ from one doctor to another. Semi-automatic methods are affected by personal interference, although automatic segmentation is depending on prior information for the detection of brain's tumor<sup>5</sup>

tissues, such as WM, GM, and CSF<sup>6,7</sup>. In this study many segmentation methods are used to segment MRI brain images are: edge detection, thresholding, and K-Means methods.

### Edge Detection Segmentation Method

Edge detection is simple method used in image processing to represent the sharp discontinuities of the image intensity (called edges). Edges are produced because of the rapid changes in the intensity of image's pixel, which represents boundaries of an object in an image. Different types of operations are available and classified into two

categories: first and second order derivatives<sup>6</sup>. First and second order derivative methods are used in this study to segment MRI brain images. The first order segmentation process is done by using a special mask to segment input image and generate a gradient image. Sobel and Prewitt<sup>6</sup> represent the first order operators and are called gradient operators. They are detecting edges by identifying the maximum and minimum pixel's intensity values, and inspecting the intensity distribution in the neighborhood of a given pixel, and then decided if a pixel is represented by edge<sup>8</sup>.

Sobel, Prewitt, and Canny<sup>6</sup> detectors are convolving the raw image with their special convolution masks to generate the segmented image (gradient), then use specific threshold values to detect edges<sup>9</sup>. A result of this procedure is based on threshold values<sup>10</sup>. MATLAB program implementation these operators using special threshold technique depending on the Root Mean Square to estimate noise in the image<sup>6</sup>.

### Thresholding Segmentation Method

Thresholding segmentation is one of the important segmentation methods. This segmentation method partitions the input image's pixels depending on their intensity level. The thresholding segmentation technique can be applied for images having dark objects on the white background and vice versa. The selection of the threshold value (T) is the important step in the thresholding segmentation, which can be done manually or automatically. Depending on image's features, three types of thresholding methods are available, these are: Global, Variable, and Multiple Thresholding<sup>11</sup>. In this study, the global thresholding method is used. The global thresholding method is applied using an appropriate T, and it will be constant for the whole MRI image. The resultant segmented image  $q(x,y)$  is obtained from the original image  $p(x,y)$  using Eq 1<sup>12</sup>.

$$q(x,y) = \begin{cases} 1, & \text{if } p(x,y) > T \\ 0, & \text{if } p(x,y) \leq T \end{cases} \quad 1$$

### K-Means Segmentation Method

K-Means segmentation process is a supervised clustering segmentation technique; this type of clustering includes human interaction to input the

cluster numbers (K). The segmentation process by K-Means is done by grouping the data vectors into predefined K. Firstly; the center of each cluster is selected randomly. Then pixels are assigned to the cluster depending on the nearest distance between pixel and the center of cluster (using Euclidian distance). When all pixels of image are clustering, cluster's mean is then calculated, and repeated this process until no changes result in cluster's mean<sup>13</sup>. The feature vectors (X) derived from I dataset be:

$$X = (x_i \mid i=1,2,3,\dots,l) \quad 2$$

The cluster centroids (C) is given by Eq 3.

$$C = (c_j \mid j=1,2,3,\dots,k) \quad 3$$

The feature vectors are grouped into (k) clusters using the Euclidean distance as shown in Eq 4.

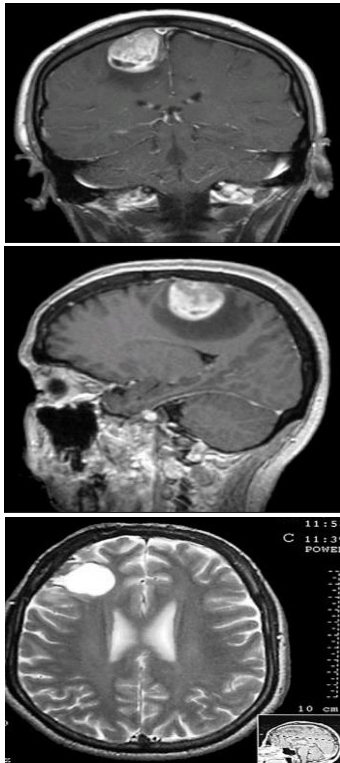
$$d = \left| \left| x_i - c_j \right| \right| \quad 4$$

K-Means clustering techniques are considered relatively high-quality clusters, and present very good results in low level of computation. Generally, the aims of k-Means segmentation method are to minimize the sum of squared distances between all images' pixels and the cluster center. The K-Means method produce good results with many data sets, but its good performance is limited mainly to compact groups. On the other hand, the disadvantages of K-Means method include the determination of K, producing different results based on different initial conditions and the centers away from optimum location<sup>14</sup>.

Many segmentation methods were used in pervious works to segment brain tumors<sup>15</sup>, and gave different results. In our study, we collect many segmentations method and applied to the same images to compare and identify whether any method that will give acceptable results.

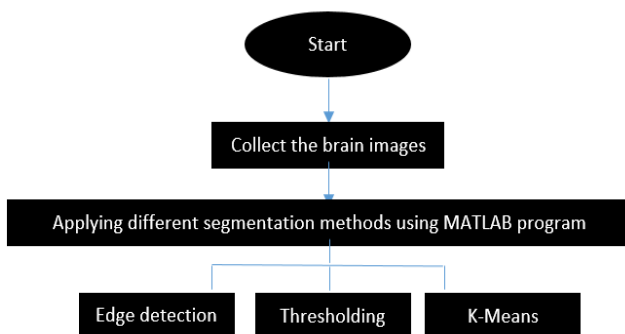
### Methods:

In this study many segmentation methods (edge detection, thresholding, and K-Means) are applied to segment MRI images and isolate the brain tumor using the MATLAB program (R2019a). The images used were obtained from the Internet websites for several people diagnosed with brain tumors as shown in Fig. 3.



**Figure 3.** The MRI brain images are used in this work.

The following diagram is representing the major steps used in this study of segmentation the brain tumor.



## Results and Discussion

### Results:

The results of applying the pervious algorithms are displayed in the following figures, where the first

### Algorithms:

#### 1. Edge's detection:

Read MRI images; Convert to RGB; Applying MATLAB code of (Sobel, Prewitt, and Canny) operators; Displayed original and edges detection segmented images;

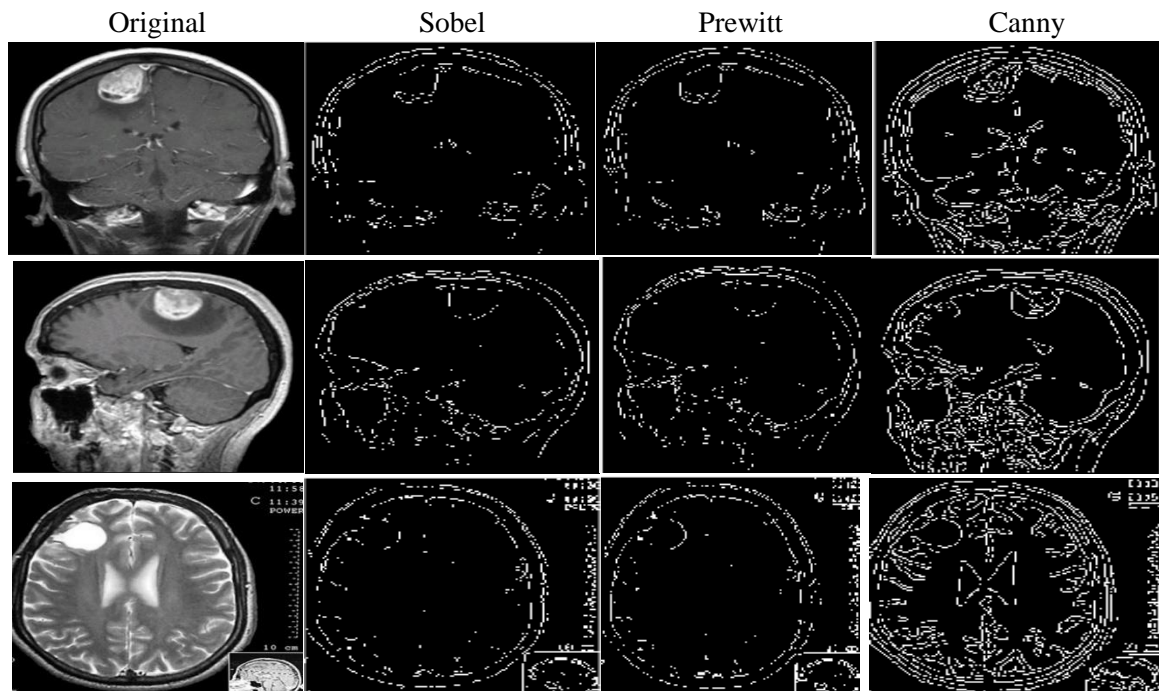
#### 2. Thresholding:

Read MRI images; Convert to RGB; Select the T values; Applying MATLAB code of thresholding method; Displayed original and thresholding segmented images;

#### 3. K-Means:

Read MRI images; convert them to an array; Input the clusters numbers (K); Choose the cluster's center; Determine the distance between each pixel and cluster's center; Applying MATLAB code of K-Means with different numbers of clusters; Displayed original and thresholding segmented images.

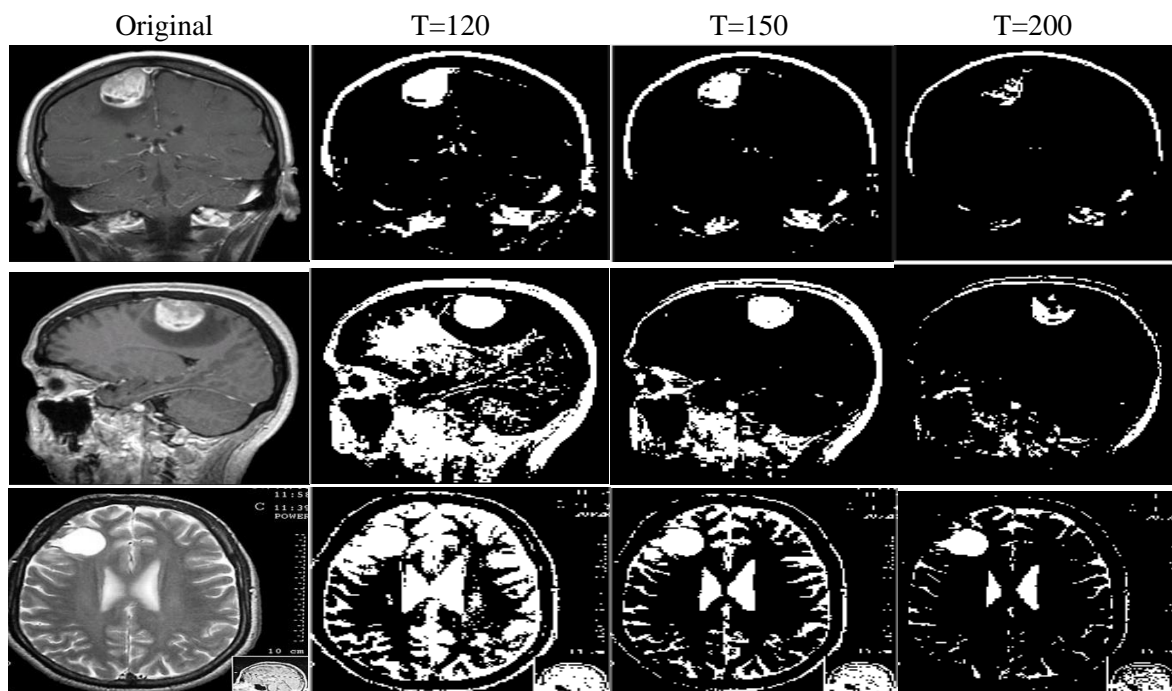
column represents the original images and others explained the results of each segmentation method.



**Figure 4. Shows original images, and segmented resultant images from edges detection.**

Fig. 4, displayed the results of applying edges detection, thresholding, and K-Means segmentation methods. In Fig.4, the first column contains the original MRI brain images. The second column

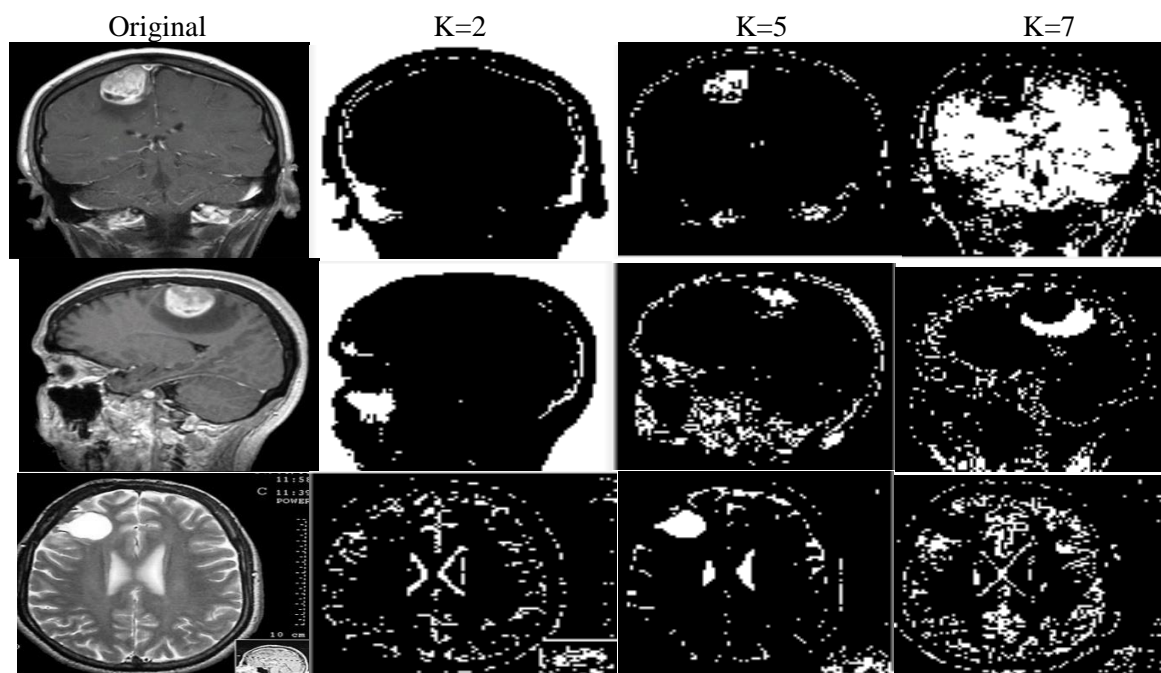
contains the segmented images produced by Sobel operator, and third column contains segmented images produced by Prewitt edge detection method, and the last column represents the resultant images from the applied Canny detector.



**Figure 5. Shows original images, and segmented resultant images from thresholding method with different threshold values (120, 150, and 200).**

Fig. 5, includes the original images (first column) and the segmented images produced by using thresholding segmentation method with different threshold values  $T=120$ ,  $T=150$ , and  $T=200$  respectively (second, third and last column,

respectively). When using  $T=120$ , the tumor for the first two images was segmented and isolated clearly. For last MRI image, the brain's tumor was isolated with some non-useful information when segmenting image using  $T=200$ .



**Figure 6. Shows original images, and segmented resultant images from K-Means method with different number of clusters (2, 5, and 7).**

The results of applying K-Mean segmentation method with different values of clusters ( $K=2,5$ , and  $7$ ) are presented in Fig. 6. From these results, can be concluded that, K-Mean segmentation method was not succeeding to segment and isolating brain's tumor. Only when using  $K=5$ , this method works and isolates the tumor region as shown in the last segmented image for the third column.

### Discussion

From results of different segmentation methods as shown in Figs. 4,5and 6 can be noted the edge detection methods are not successful to segment the

### Conclusion

The results of segmentation methods show that, the edges detection methods are failed to achieve our purpose, thresholding segmentation methods given good result when using  $T=120$ , and when using  $T=200$ , the acceptable result were produced. The

MRI images and isolate the brain's tumor clearly, these methods are segmenting only some edges of tumors regions as shown in Fig. 4, so cannot be dependent it for isolation the brains tumor. Also, the thresholding segmentation method succeeded in segmentation and isolation the brain's tumor in some cases which contain tissues of higher intensity and depending on the appropriate selection of thresholding values as shown in Fig. 5. Finally, the K-Means method succeeded in segment and isolate the tumor region of brain image having more intensity than other normal tissues, but this result depending on the selected cluster numbers, also the K-Means method produce changeable results.

results of applying K-Mean segmentation method were not succussed to segment and isolate brain's tumor. Only when using  $K=5$ , this method was succeed to isolate tumor of brain.

## Acknowledgment

The cooperation of the medical staff at the Department of Geographic Information Systems in the University of Baghdad.

## Authors' Declaration

- Conflicts of Interest: None.
- We hereby confirm that all the Figures and Tables in the manuscript are ours. Furthermore, any Figures and images, that are not ours, have been included with the necessary permission for re-publication, which is attached to the manuscript.
- Authors sign on ethical consideration's approval.
- Ethical Clearance: The project was approved by the local ethical committee at University of Baghdad.

## Authors' Contribution Statement

All authors contributed to the design and implementation of the research, to the analysis of the results and to the writing of this manuscript: A. A. H.; Data collection and analysis, writing the theoretical part and participating in the practical part.

S. H. M.; Show his assistance in obtaining and interpreting the results. B. S. I.; She participated in the interpretation of the results and write the practical part.

## References

1. Angulakshmi M, Lakshmi Priya GG. Automated Brain Tumour Segmentation Techniques—A Review. *Sch Info Technol Eng.* 2017; 27: 66–77. <https://doi.org/10.1002/ima.22211> .
2. Chang CW, Chien-Chang HO, yh-Hornng CH. ADHD. classification by a texture analysis of anatomical brain MRI data. *Front Syst Neurosci.* 2012; 6: 1-16. <https://doi.org/10.3389/fnsys.2012.00066>
3. Girish Ka, Syeda Arshiya Ar, Ayesha Sh. Magnetic Resonance Imaging (MRI) – A Review. *Int J Dent Clin.* 2011; 3(1): 65-70..
4. Stig E. Forshult. Magnetic Resonance Imaging MRI – An Overview. Karlstad University Studies. Faculty of Technology and Science Physics Sweden. 2007. 22.
5. Nayak SK, Panda CS. A Study on Brain Mri Image Segmentation Techniques. *Int J Res Stud Comput Sci Eng.* 2015; 2:4-13.
6. Saket BH, Ajay MI. A Survey on Various Edge Detector Techniques. *Proc Technol.* 2012; 4:220-226. <https://doi.org/10.1016/j.protcy.2012.05.033> .
7. Alyaa H, Hazim AH, Sabah MA, Aiyah No. Using Texture Analysis Image Processing Technique to Study the Effect of Microwave Plasma on the Living Tissue. *Baghdad Sci J.* 2018; 15(1):8 7-89. <https://doi.org/10.21123/bsj.2018.15.1.0087> .
8. William PA. Digital image processing. 4th edition. John WileyInc. 2012.
9. Himani SR, Himanshu SI. Comparative Study Between Canny and Sobel Edge Detection Technique. *Einstein Int J Org.* 2018; 3: 1-7. <https://www.researchgate.net/publication/343789107> .
10. Bydaa AH, Mohammed SH. Developing Arabic License Plate Recognition System Using Artificial Neural Network and Canny Edge Detection. *Baghdad Sci J.* 2020; 17(3): 909-915. <https://doi.org/10.21123/bsj.2020.17.3.0909> .
11. Zhang YJ. An Overview of Image and Video Segmentation in the last 40 years. *Proc 6th Int Symp Signal Proc Appl.* 2001; 144-151. <https://doi.org/10.4018/978-1-59140-753-9.CH001> .
12. Dilpreet KA, Yadwinder KA. Various Image Segmentation Techniques: A Review. *J Comput Sci Mob Computing.* 2014; 3(5): 809-814..
13. Sriparna SA, Sanghamitra BA. A new symmetry-based multiobjective clustering technique for the automatic evolution of clusters. *Pattern Recognit.* 2010; 43(3): 738-751. <https://doi.org/10.1007/s10115-009-0204-4>
14. Devarshi NA, Pinal SH. A Review on Image Segmentation Clustering Algorithms. *Int J Comput Sci Inf Technol.* 2014; 5(3): 3289-3293. <http://dx.doi.org/10.14257/ijcip.2016.9.5.18> .
15. Asra AS, Ekram KH, Sufyan MM. Improved Edge Detection Algorithm for Brain Tumor Segmentation. *Procedia Comput Sci.* 2015; 58: 430-437. <https://doi.org/10.1016/j.procs.2015.08.057> .

## تجزئة وعزل أورام الدماغ باستخدام طرق تجزئة الصور

أحلام علي حسين<sup>1</sup> ، سرمد حميل محل<sup>2</sup> ، بان صباح اسماعيل<sup>2</sup>

<sup>1</sup>قسم التحسس النائي ونظم المعلومات الجغرافية، كلية العلوم، جامعة بغداد، بغداد، العراق.  
<sup>2</sup>قسم الفلك والفضاء، كلية العلوم، جامعة بغداد، بغداد، العراق.

### الخلاصة

أورام الدماغ هي نمو غير طبيعي أو كتلة من الخلايا في أنسجة المخ أو ما حولها وتكون نوعان إما خبيثة (سرطانية) أو حميدة (غير سرطانية) ، يمكن لأورام الدماغ أن تصيب الأطفال وكذلك البالغين. وقد تؤثر أورام الدماغ على وظائف الدماغ البشري إذا نمت بشكل كبير بما يكفي للضغط على الأنسجة المحيطة. يعتبر ورم الدماغ خطيراً بطبيعته ويهدد الحياة. يعتمد تشخيص ورم الدماغ على الأطباء المتخصصين، ولكن في بعض الأحيان يعطي أطباء الدماغ تشخيصاً مختلفاً اعتماداً على التحديد الدقيق لحجم الورم وكتلته. لتجنب ذلك، في كثير من الحالات يتم استخدام الكمبيوتر كوسيلة مساعدة لتجزئة وعزل ورم الدماغ. تقنية التجزئة في معالجة الصور هو عملية تقسيم المنطقة إلى أجزاء مختلفة اعتماداً على معايير مختلفة مثل الكثافة والتجانس وغيرها. في هذه الدراسة، تم استخدام العديد من تقنيات التجزئة لتجزئة أورام الدماغ من صور التصوير بالرنين المغناطيسي وهي: طرق الكشف عن الحواف (سوبل، وبريوييت، وكاني)؛ طريقة العتبة باستخدام قيم عتبة مختلفة (T) ؛ وطريقة التجميع K-Means بأعداد مختلفة من العناقيد (K). من نتائج طرق التجزئة، استناداً على النتائج النهائية، كان من الواضح أن طرق الكشف عن الحواف فشلت في تجزئة وعزل منطقة الورم، اعطت طريقة تجزئة العتبة نتيجة جيدة عند استخدام  $T = 150$ ،  $200$  لبعض الحالات. في حين أن طريقة التجزئة K-Means كانت ناجحة في تجزئة وعزل ورم الدماغ لحالة واحدة عند استخدام عنقودين ( $K = 2$ ).

**الكلمات المفتاحية:** أورام الدماغ ، كشف الحواف ، طرق K ، تقنيات التجزئة ، العتبة.