

Toxopathological changes induced by high doses of sustanon in male rats treated with Alpha lipoic acid

Kh. H. Aljeboori and A. B. Majhool

College of Veterinary Medicine/ University of Baghdad

Abstract

This study was designed to evaluate the toxopathological effect of high doses of anabolic androgenic steroid (sustanon) in male rats and under the effect of alpha lipoic acid (ALA). Three groups of male rats (20 rat each group) were treated with I.M injection of sesame oil (control group) and 20 mg/kg.b.wt. Sustanon-sesame oil I.M (2nd group) and 3rd group, I.M treated with sustanon-sesame oil as a 2nd group and orally giving ALA 10mg/100gm b.wt. weekly for 60 days. The results showed extensive to moderate histopathological lesions including degenerative changes and inflammatory cellular reaction in the 2nd group and in the 3rd group respectively after 30th and 60th days. In conclusion the extensive to moderate histopathological degenerative and inflammatory cellular response in male rats treated with high doses of sustanon-sesame oil and sustanon-sesame oil alpha lipoic acid.

Key words: Toxopathological, sustanon, alpha lipoic acid, male rats
e-mail:khalilhassan1955@gmail.com.

دراسة سمية مرضية للتغيرات المستحدثة بجرع عالية من السستانون في ذكور الجرذان المعاملة

بحمض ليبويك ألفا

خليل حسن زناد واحمد بهلول مجهول

كلية الطب البيطري/ جامعة بغداد

الخلاصة

صممت هذه الدراسة لتقييم التغيرات السمية المرضية الناتجة من الجرعة العالية للستيرويد الاندروجيني (السستانون) في ذكور الجرذان والتي تحت تأثير حامض ليبويك ألفا. ثلاث مجاميع من ذكور الجرذان (كل مجموعة تتكون من 20 جرد ذكر) (المجموعة الأولى (مجموعة السيطرة) حققت عضليا بزيت السمسم، المجموعة الثانية حققت عضليا بـ(20 ملغ لكل كغم من وزن الجسم) من السستانون المخلوط مع زيت السمسم أما المجموعة الثالثة حققت عضليا كما في المجموعة الثانية إضافة إلى إعطائها حامض ليبويك ألفا فمويا وبتركيز (10 ملغ لكل كغم من وزن الجسم) أسبوعيا ولمدة 60 يوم. أظهرت النتائج تغيرات نسجية مرضية تراوحت بين الشديدة والمتوسطة امتازت بتكسبات في المجموعة الثانية وارتشاحات للخلايا الالتهابية في المجموعة الثالثة في اليوم 30 و60. لقد استنتج من هذه التجربة ان التغيرات النسجية المرضية كانت شديدة ومتوسطة في ذكور الجرذان في المجموعتان الثانية والثالثة.

الكلمات المفتاحية: دراسة سمية مرضية، السستانون، حامض ليبويك ألفا، ذكور الجرذان

Introduction

Testosterone assumes a critical part in male sexual separation, pubescence, sexual conduct and spermatogenesis (1). Testosterone is the male sex cholesterol inferred hormone (2) created and emitted by the interstitial leydig cells (3). It manages optional sexual qualities. Along with the incitement of follicle by follicle stimulating hormone (FSH), testosterone act to fortify sperm creation (4). The importance of sustanon treatment, this study aimed to: Identify the toxopathological effect of high doses of sustanon in male rats and to identify the effect of alpha lipoic acid in reducing testosterone toxopathological effect.

Materials and Methods

Sixty male rats were divided into 3 equal groups, first group treated 1/M with 1ml of sesam oil weekly for 60 days. The 2nd group treated with sustanon- sesam oil 1/M with dose of 20 mg/kg.b.wt weekly for 60 days; 3rd group treated with sustanone-sesam oil similar to 2nd group in addition to treated with alpha lipoic acid 10mg/100 gm kg.b.wt orally for 60 days. At 30th and 60th day, all male rats in these 3 groups were sacrificed equally and all pathological lesion were studied and examined (5).

Results

Control group (sesam oil) showed no significant pathological lesions in all groups at all periods. The second group: showed extensive different pathological lesions in different organs. **Liver:** Showed inflammatory cells infiltration mainly Neutrophils and mononuclear cells in the portal area at 30th days accompanied by extensive vacuolar generation and atrophy of some liver cells at 60th days of treatment with sustanon toxic doses (Fig.1).

Spleen: Showed hyperplasia of white pulp and reticuloendothelial cells lining red pulp at 30th days and depletion of lymphoid tissue in the white pulp at 60th day of sustanon treatment with toxic doses (Fig.2). **Kidney:** Vacuolar degeneration with interstitial mononuclear cells infiltration. Also, hyaline casts were seen in dilated renal tubules accompanied the degenerative changes at 30th and 60th day of sustanon treatment with high doses (Fig.3). **Lungs:** Extensive interstitial emphysema, and interstitial thickening of alveolar septae together with mononuclear cells infiltration. In the interstitial pulmonary tissue at 30th day and 60th day of sustanon treatment with toxic doses (Fig.4). **Testis:** Extensive edema in the interstitial testicular tissue with vacuolar degeneration of seminiferous tubular epithelia in addition to loss of spermatogenesis at 30th and 60th days of sustanon treatment with toxic dose (Fig.5).

The 3rd group (sustanon + lipoic acid group): Moderate degenerative pathological lesion together with moderate inflammatory cellular reaction as compared to extensive degenerative pathological lesions and extensive inflammatory cellular reactions seen in the different organs liver, spleen, kidney, lungs and testes at 30th and 60th day of treatment with sustanon toxic doses accompanied by treatment with alpha lipoic acid (Fig. 6, 7, 8, 9, 10).

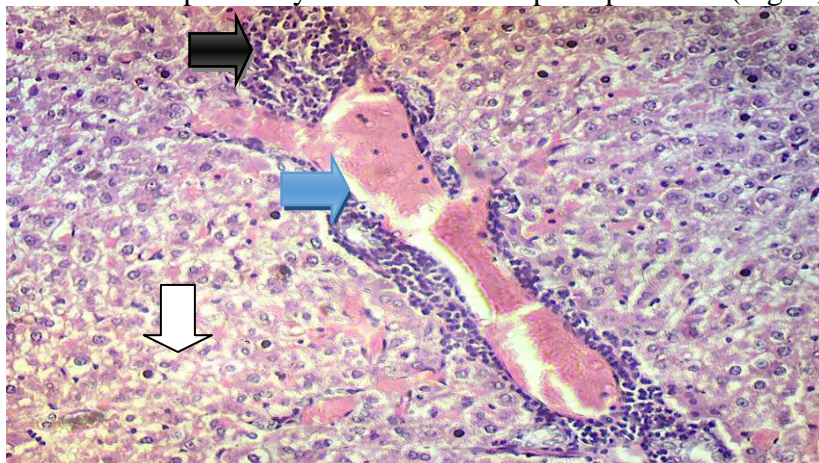


Fig. (1) liver of male rat treated with sustanon 20 mg/kg B.W. intramuscularly once a week (sixty day period), shows an extensive inflammatory reaction composed of mononuclear cells (macrophages and lymphocytes) and neutrophils (black arrow) around congested blood vessel in portal area (blue arrow); also there is extensive vacuolar degeneration (white arrow). X20 H&E stain.

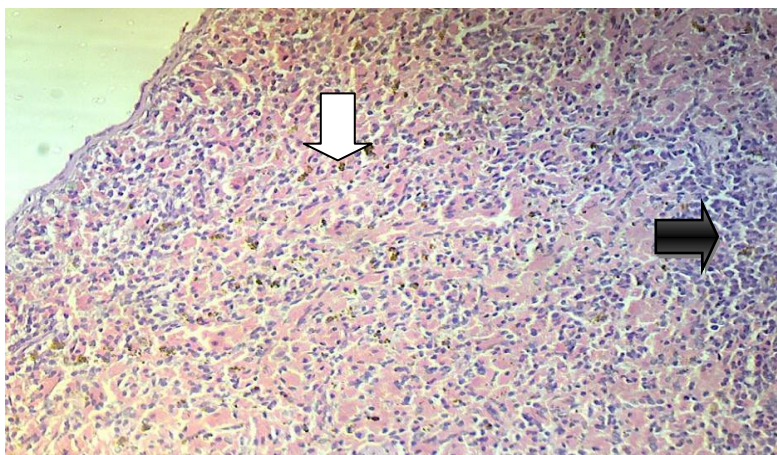


Fig. (2) spleen of male rat treated with sustanon 20 mg/kg B.W. intramuscularly once a week (sixty day period), shows a depletion of lymphoid tissue of white pulp (black arrow) together with haemosiderosis (white arrow). X20 H&E stain.

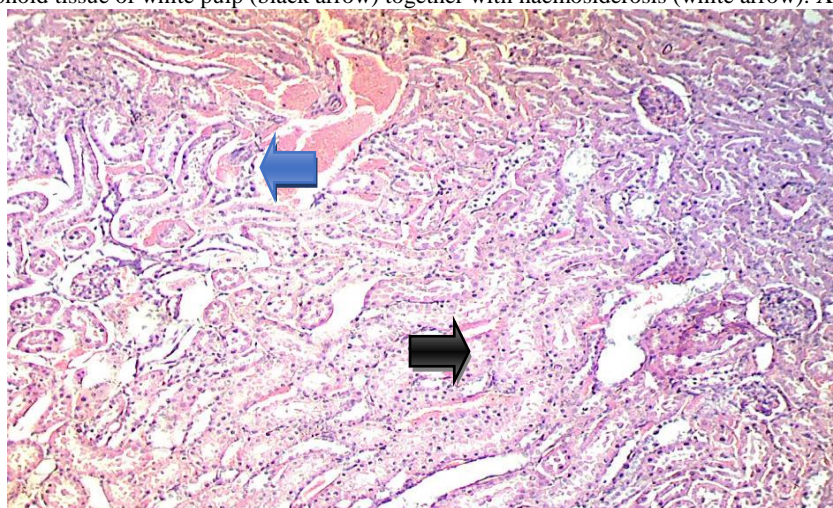


Fig. (3) kidney of male rat treated with sustanon 20 mg/kg B.W. intramuscularly once a week (sixty day period), shows vacuolar degeneration, and dilated renal tubules (black arrow) and dilated and congested blood vessels (blue arrow) with rupture of renal tubules. X10 H&E stain.

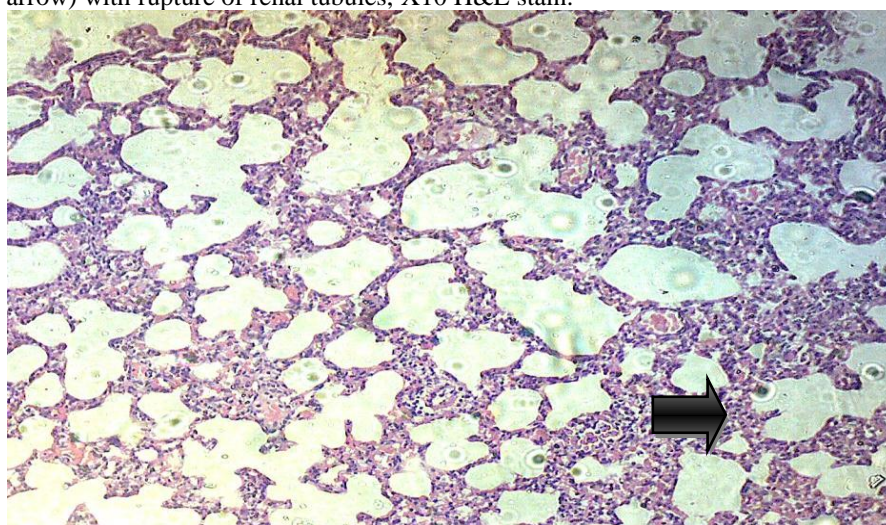


Fig. (4) lung of male rat treated with sustanon 20 mg/kg B.W. intramuscularly once a week (thirty day period), shows an extensive alveolar emphysema and interstitial thickening of the alveolar septa together with mononuclear cells infiltration in the interstitial tissue (black arrow); X10 H&E stain.

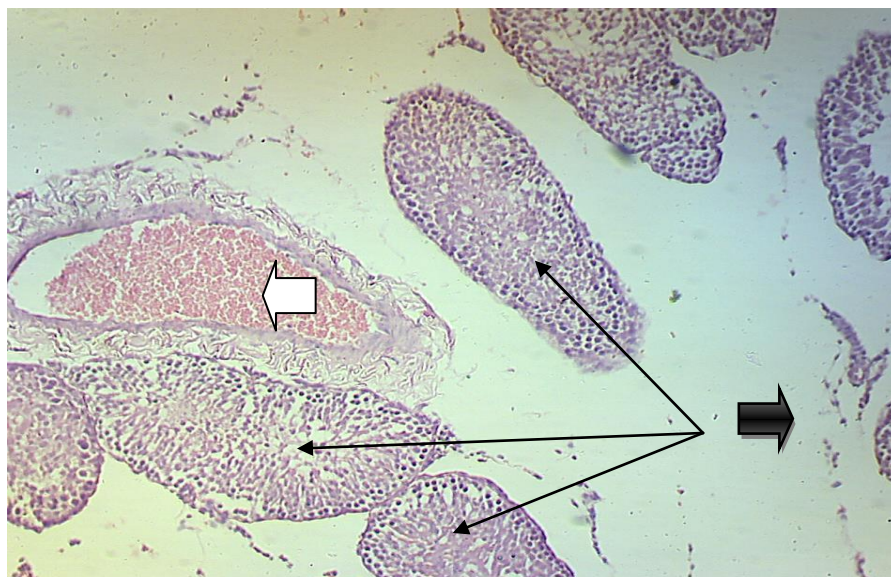


Fig. (5) Testis of male rat treated with sustanon 20 mg/kg B.W. intramuscularly weekly alone (sixty day period), shows a very extensive interstitial edema between seminiferous tubules (black arrow) with incomplete spermatogenesis (thin arrows) and congested blood vessel (white arrow), X10 H&E stain.

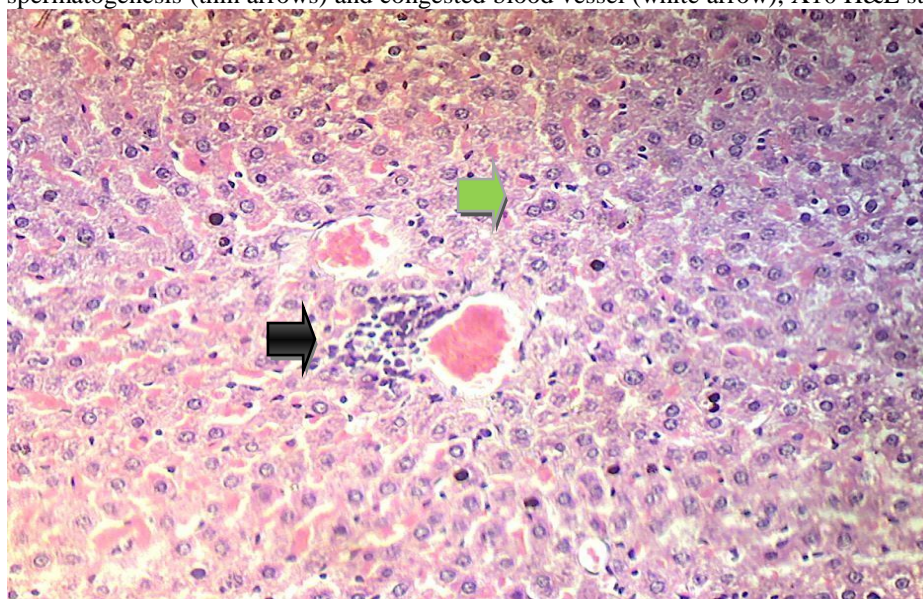


Fig. (6) liver of male rat treated with sustanon 20 mg/kg B.W. intramuscularly weekly, and alpha lipoic acid (ALA) suspension 0.5\100gm orally daily (thirty day period), shows a moderate inflammatory aggregation around the central vein composed of mononuclear cells (macrophages and lymphocytes) and neutrophils (black arrow) with proliferation of kupffer's cells (green arrow), X20 H&E stain.

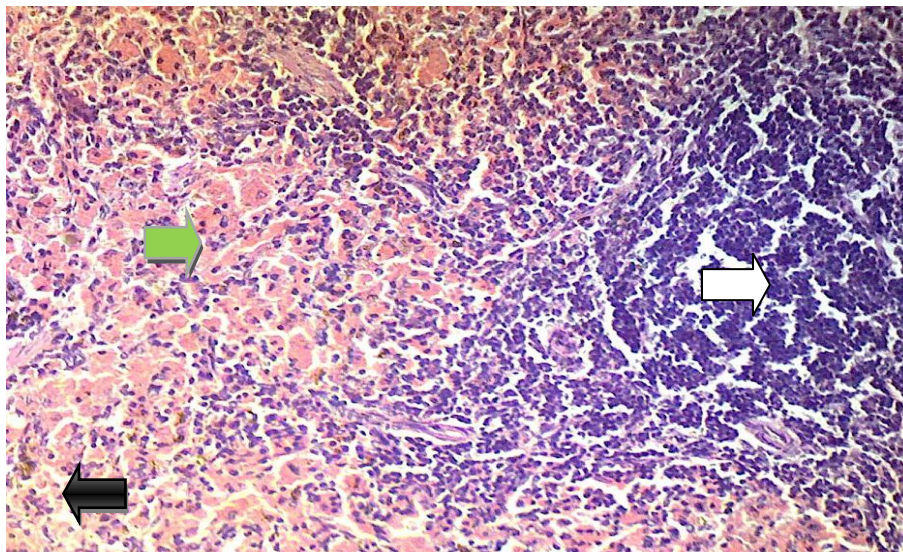


Fig. (7) Spleen of male rat treated with sustanon 20mg/kg B.W. intramuscularly weekly, and alpha lipoic acid (ALA) suspension 0.5ml/100gm orally daily (thirty day period), shows hyperplasia of lymphoid tissue of white pulp (white arrow), together with haemosiderosis (black arrow) and congestion of blood sinuses (green arrow), X20 H&E stain.

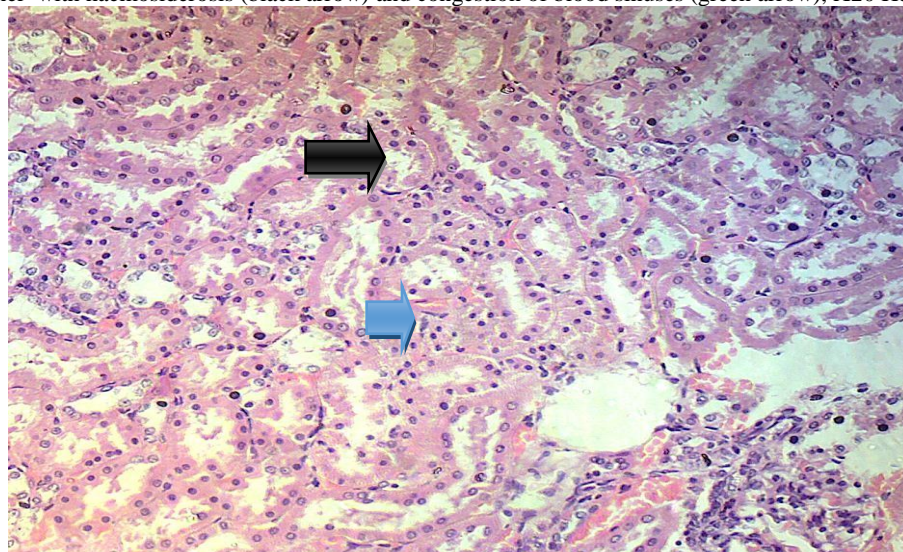


Fig. (8) kidney of male rat treated with sustanon 20mg/kg B.W. intramuscularly weekly, and alpha lipoic acid (ALA) suspension 0.5/100gm orally daily (thirty day period), shows a moderate cloudy swelling (black arrow), together with a moderate renal casts in the renal tubules (blue arrow). X20 H&E stain.

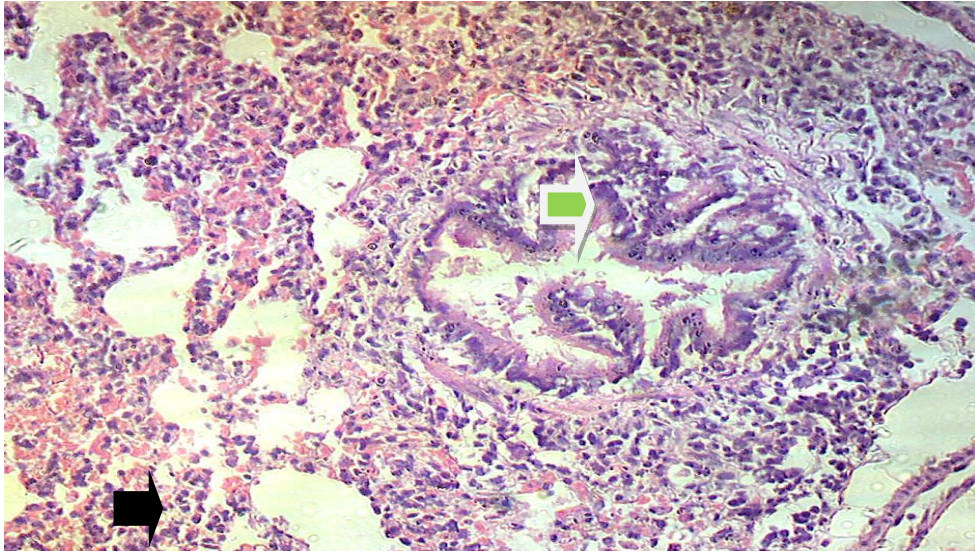


Fig. (9) lung of male rat treated with sustanon 20mg/kg B.W. intramuscularly weekly, and alpha lipoic acid (ALA) suspension 0.5 ml/100gm orally daily(sixty day period), shows a focal emphysema (black arrow), interstitial pneumonia, and peribronchial lymphoid tissue hyperplasia (green arrow). X20 H&E stain.

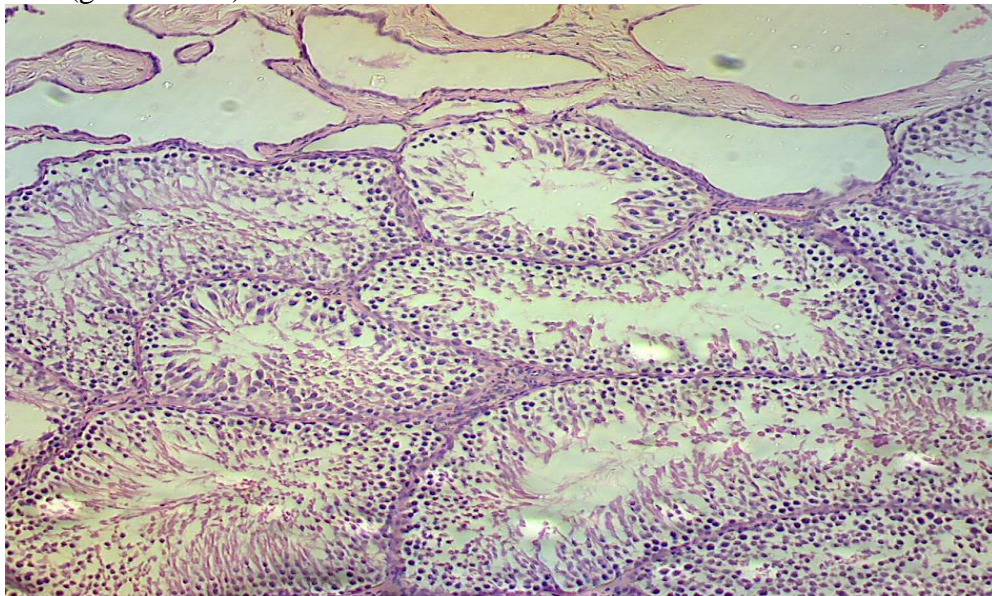


Fig. (10) testis of male rat treated with sustanon 20mg/kg B.W. intramuscularly weekly, and alpha lipoic acid (ALA) suspension 0.5 ml/100gm orally daily(sixty day period), shows complete spermatogenesis with sperms in the lumina of seminiferous tubules, X10 H&E stain.

Discussion

The results of this study revealed that the toxic doses of sustanon induced extensive degenerative pathological lesions accompanied with inflammatory cellular reaction in different body organs (liver, spleen kidney, lungs and testes) these toxic effects of sustanon lead to elevation of oxidative stress oxidative stress (6), subsequently the targeted molecules to become a free radical itself and initiates a cascade of events that can ultimately lead to cellular damage in different organs like liver, spleen, kidney, lungs and testes. Similar finding observed in these organs in this study. (7) showed similar pathological finding in liver under toxic doses of sustanon treatment. Also a similar effect

of toxic doses of sustanon were observed in testes (8) and in kidney (9) and in lungs and in spleen (10, 11) respectively, both authors reported that low doses of sustanon have not effect on body organs but toxic doses cause oxidative stress with releasing reactive oxygen species (Ros) which induced toxic injury to all body organs. Regarding the 3rd group which received sustanon toxic doses together with alpha lipoic acid as an antioxidants reduced the toxic effect of sustanone to moderate pathological lesions were seen in the different organs in this study, the modulating effect of ALA neutralizing the reactive oxygen species (ROS) effect (10, 12) body organs to sustanon treatment with toxic doses, similar finding reported by (13) that the ALA supplement improve the oxidative stress which was evident in this study.

References

1. Hines, M. (2009). Gonadal hormones and sexual differentiation of human brain and behavior. *Hormones Brain Behav.*, 4: 1869-1909.
2. Parr, M. K.; Dipl-sportwiss, U. F. & Schanzer, W. (2010). Sports-related issues and biochemistry of natural and synthetic anabolic substances. *Endocrinol. Metabol. Clinics North Amer.*, 39(1): 45-57.
3. Barret, K. M.; Barman, S. M.; Boitano, S. & Brooks, H. L. (2010). *Ganong's Review of medical physiology*, twenty third edition, McGraw- Hill company, New York.
4. Mader, S. S. (2010). *Biology*, tenth edition. McGraw-Hill book company, New York.
5. Luna, L. G. (1968). *Manual of histologic staining Methods of the armed forces institute of pathology*, 3rd. ed. McGraw-Hill book company, New York.
6. Aydliek, N.; Aksakal, M. & Karakilçik, A. Z. (2004). Effect of testosterone and vitamin E an antioxidant system in rabbits testis. *Andrologia*, 36(5): 277-281.
7. Gragera, R.; Sabrido, A.; Molano, F.; Jimenz, L.; Munz, E. & Mwgias, A. (1993). Ultrastructural changes induced by anaboli steroids in liver of trained rats. *Histo-Histopath*, 8:449-455.
8. Tahtamouni, L. H.; Mustafa, N. H.; Hassan, I. M.; Ahmad, I. M.; Yasin, S. R. & Abdalla, M. Y. (2010). Nandrolone decanoate administration to male rats induces oxidative stress, seminiferous tubules abnormalities and sperm DNA fragmentation *Jord. H. Biol. Sci.*, 3(4): 165-174.
9. Habscheid, W. & Abele, U. & Dahm, H. H. (1999). Server chestasis with kidney failure from anabolic steroids in body builder. *Dtsch Med Wochenschr.*, 124: 1020-1029.
10. Demarco, V. G.; Scumpia, P. O.; Bosanquet, J. P. & Skimming, J. W. (2004). Alpha lipoic acid inhibits endotoxin-stimulated expression of Nos and Nitric oxid independent of the heat shock response in RAW 264.7cells. *Free Radic. Res.* 38: 675-682.
11. Olsen, N. J.; Viselli, S. M.; Fan, J. & Kovacs, W. J. (1998). Androgen accelerates thymocytes apoptosis. *Endocrinol.*, 139: 748-752.
12. Packer, L.; Witt, E. H. & Tritschler, H. J. (1995). Alpha lipoic acid as a biological antioxidant. *Free Radic. Biol. Med.*, 19: 227-250.
13. Marangon, K.; Devaraj, S.; Tirosh, O.; Packer, L. & Jialal, I. (1999). Comparison of the effect of alpha lipolic acid and alpha tocopherol supplementation on measures of oxidative stress. *Free Rad. Biol. Med.*, 27: 1114-1121.