



# **An Analysis of Digital Panoramic Radiographs for the Shape Appearance and Position of Mental Foramen**

## **(A Comparative Study Between Dentate and Edentulous Patients)**

**Assit prof. Dr. Ahlam A.Fattah B.D.S MSC.**

**Dr. Aqeel Ibraheem Lazem B.D.S MSC.**

### **Abstract**

Digital panoramic radiographs were analyzed to study the shape, appearance, relative vertical and horizontal position of mental foramen in both dentate and edentulous patients

Digital panoramic radiographs were made to 144 patients, 76 dentate, (38 female and 38 male) and 68 edentulous, (30 female and 38 male). The age distribution of them was ranging between (24 – 73) years old. Mental foramen was unidentified on both sides (right and left) on 8 radiographs, so these 8 radiographs were excluded from the sample, which are consisting 5.5 % of the total sample. While mental foramen was unidentified on only one side (either right or left) of a radiograph, was included within the sample, which means that 136 radiographs (272 sides) were included in this study 72 dentate (144 sides) and 64 edentulous (128 sides) radiographs. Chi – square test was used to compare the shape and the appearance of mental foramen between the two groups (dentate and edentulous), while Student t – test was used to compare the relative vertical and horizontal position of mental foramen between them.

The comparison between dentate and edentulous groups showed no significant difference in the shape and appearance of mental foramen when Chi- square test was used. While the comparison using Student t- test showed a highly significant difference between the two groups in relative vertical position, and a significant difference in relative horizontal position of mental foramen.

No significant difference was found in the shape and appearance of mental foramen on the digital panoramic radiograph, for both dentate and edentulous patients, while the vertical and horizontal positions of mental foramen were not constant between them.

**Key words: digital panoramic radiography, mental foramen.**

### **Introduction**

Mental foramen is one of the most important anatomical landmarks in the mandible that the dentists should have accurate information about its shape, size, appearance and position. The

foramen is usually located mid way between the superior and inferior border of the body of mandible. when teeth are present, the most is often is located below the second premolar tooth, a little below the apex of the root, the position of the foramen is not

2007

constant and it may be between the first and the second premolar teeth, after the teeth are lost and the resorption of the alveolar bone has taken place, mental foramen may appear near the crest of the alveolar ridge. Knowledge of the position of the mental foramen is important both when administering regional anesthesia and performing periapical surgery in the mandible. Although it is often possible to identify the mental foramen by palpation and radio graphically, knowing the normal range of possible locations is essential. So, identification of the accurate anatomical location of the mental foramen is very important to dentists in endodontic treatment, periodontal surgery, surgical orthodontics, preprosthetic surgery and so forth.

Tooth position may not be a reliable indicator of mental foramen position because of variability in tooth size during eruption events<sup>1,2,3</sup>.

Digital radiography is considered to be a great enhancement to the diagnostic radiography due to its improved image properties, improved storage and transportability of the image and reduced equipments and time needed to produce a superior image<sup>4,5</sup>.

In the present study an analysis was made on digital panoramic radiographs for the shape, appearance and position of mental foramen between dentate and edentulous patients.

### AIMS OF THE STUDY:

1. To compare the shape of the mental foramen between dentate and edentulous on digital panoramic radiographs.
2. to compare the appearance of mental foramen in relation to the mandibular canal between dentate and edentulous on the digital panoramic radiographs

3. To compare the relative vertical position of mental foramen between edentulous and dentate on digital panoramic radiographs.

4. To compare the relative horizontal position of mental foramen between dentate and edentulous on digital panoramic radiographs.

## Materials and Methods

### X-ray machine

The panoramic x-ray machine that was used in the study is **Dimax 3 digital Planmeca X-ray machine** manufactured by Planmeca, Helsinki, Finland (Figure 1), which has the following specifications:

- Total filtration 2.5 mm Al.
- Exposure time; 2.5-18 seconds as indicated  $\pm 10\%$ .
- Magnification Constant 1.2

### Subjects Sample

The sample of this study is consisting of patients referred for panoramic radiographs from prosthodontic, surgery, and orthodontics departments at college of dentistry, university of Baghdad. The sample is consisting of (144) subjects divided into two groups according to the presence of teeth in the mandible; the first group consists of (76) subjects with full set of teeth in their mandibles (38 female and 38 male), while the second group is consisting of (68) subjects with fully edentulous mandible (30 female and 38 male). 8 radiographs were excluded from the sample because of unidentified mental foramen on both sides (right & left), which means that 136 radiographs (272 sides) were included in this study 72 dentate (144 sides) and 64 edentulous (128 sides).

2007

The age of the individuals included in the study is ranging between (24-73) years old.

### **Radiographic technique:**

-For each patient examined by the Dimax 3digital Planmeca x-ray machine, the set of exposure parameters is included in table (1).

-For edentulous patients, we used the chin support while the chin rest was used for dentate patients .Figure (2; A and B).

### **Examination technique:**

#### **a -Shape of mental foramen**

All the radiographs were examined on the monitor for the shape of the mental foramen on both sides (right and left), then tracing of mental foramen using a colored pencil, so the mental foramina were classified into oval , round , irregular, and unidentified <sup>6</sup> .

#### **b- Appearance of the mental foramen in relation to the mandibular canal**

The radiographs were examined on monitor and on glossy paper for the relation of the mental foramen to the mandibular canal on both sides and were classified into four types: continuous, separated, diffuse, and unidentified <sup>7</sup> .

#### **c- Position of mental foramen**

The measurements were done using the printed copy of the radiograph with the aid of radiographic image on the monitor to localize and trace the mental foramen, condyles, triangular representation of anterior nasal spine, and upper and lower border of the body of mandible on both sides .The tracing and measurements were made using a transparent ruler and a colored pencil.

## **1- Vertical position of mental foramen**

The vertical position of the mental foramen was estimated by determining the shortest line connecting the alveolar ridge and the lower border of the mandible, passing through the center of the mental foramen .Measurements were made from the alveolar ridge to the upper border of the mental foramen ("a" ), from the upper border of the mental foramen to the lower border of it (the vertical diameter of the foramen itself) ("b"), and from the lower border of the mental foramen to the lower border of the mandible ("c"). (Figure 3).

The ratio a/c gives the relative vertical position of the mental foramen <sup>7</sup>

## **2- Horizontal position of mental foramen**

### **- Points used in tracing:**

- Ar : the most superior point on the outline of the head of the condyle.

- Gn: Gnathion "lowest most anterior point at the midline of the mandible". Gnathion point was determined by intersection between midline and the inferior border of the mandible.

- Go: Gonion "the most inferior and posterior point at the angle of the mandible".

Gonion point was determined by intersection between a line perpendicular to the lower jaw diagonal (Ar-Gn) line and the external outline of the jaw angle.

The horizontal position of the mental foramen was determined by drawing a line extending from the crest of the alveolar ridge passing through the center of the mental foramen, this line is perpendicular on (Go-Gn) line and the intersecting point is termed (M) , the distance from (Gn) to M was designated as ("f"), while the distance from (Go) point to (M) was designated as ("g") , (Figure 4).

2007

The relative horizontal position of the mental foramen was measured by the ratio of (f/g)<sup>8</sup>.

## Results

### The shape of mental foramen:

The most common shape of mental foramen was the oval type for both groups.

In dentate group most common shape was the oval shape 47.9% followed by the round shape 38.1% followed by the irregular shape 11.8% the mental foramen was unidentified on one side in 2.2%.

In edentulous group the most common shape of mental foramen was also the oval shape 47.6% followed by the round shape 35.9%, then the irregular shape 13.2%, and the mental foramen was unidentified in 3.3%. A comparison of the frequency percentages of the shape between dentate and edentulous showed no statistical significant difference ( $p > 0.05$ ) for all types as shown in table (2).

### Appearance of mental foramen:

The most common appearance of mental foramen was the separate type in both groups.

In dentate group most common appearance of mental foramen as seen on digital panoramic radiographs was the separate type 60.4%, followed by the continuous type 32.6, then the diffuse type 4.9%, the mental foramen was unidentified in 2.1%. While in the edentulous group the most common appearance was also the separate type 60.1%, followed by the continuous type 26.6%, then the diffuse type 10.1%, while the mental foramen was unidentified in 3.2%

A comparison of the frequency percentages of the appearance between dentate and edentulous showed no

statistical significant difference ( $p > 0.05$ ) for all types as shown in table (3)

### Vertical position of mental foramen

The relative vertical position of the mental foramen was calculated as the ratio between the distance above the mental foramen to the distance below it (a/c)<sup>7</sup> figure 3.

A comparison of the relative vertical position of mental foramen (a/c) in the total dentate and edentulous groups showed a statistically highly significant difference ( $p < 0.001$ ). Table (4).

### Horizontal position of mental foramen

The relative horizontal position of mental foramen was estimated as the mean of (f/g)<sup>8</sup> figure 4.

A comparison of the relative horizontal position of mental foramen (f/g) between the total dentate and edentulous groups showed a statistically significant difference ( $p > 0.05$ ). Table (5).

## Discussion

### Shape of mental foramen:

The shape of mental foramen was classified into four types; oval, round, irregular and unidentified. The most common shape of mental foramen both groups was the oval shape (47.9% in dentate and 47.6% in edentulous), followed by the round shape (38.1% in dentate and 35.9% in edentulous), followed by the irregular shape (11.8% in dentate and 13.2% in edentulous), then the unidentified type on one side in (2.2% in dentate and 3.3% in edentulous). This result was in agreement with the findings of the previous studies, Gershenson, et al<sup>9</sup>, Graves, et al<sup>10</sup>, Jeffcoat<sup>11</sup>, Suaga, et al<sup>12</sup>, but it disagrees with the other reported findings Abdulhaleem<sup>13</sup>, and

2007

Mbajiorgu et al<sup>14</sup> that the most common shape of mental foramen is the round shape. The disagreement between our study and the last two studies could be due to the difference in the size of the sample selected.

### **Appearance of mental foramen:**

The most common appearance as found in the present study was the separated type (60.4% in dentate and 60.1% in edentulous) followed by the continuous type (32.6% in dentate and 26.6% in edentulous) then the diffuse type (4.9% in dentate and 10.1% in edentulous) and finally the unidentified type (2.1% in dentate and 3.2% in edentulous).

This finding was in agreement with those obtained by other studies Moore, et al<sup>15</sup> and Stafine<sup>16</sup>.

### **Position of mental foramen: Vertical position of mental foramen:**

A highly significant difference ( $p < 0.001$ ) was found when comparing the vertical position between the total (dentate and edentulous groups). This is because in edentulous group resorption of alveolar bone above mental foramen following the loss of teeth leads to reduction in the height of the body of mandible so that the mental foramen become nearer to the superior border of the ridge, that's why a highly significant difference in the mean values of (a/c) between the two groups was obtained. These findings were confine with previous researches Yosue, and Brooks<sup>7</sup>, and Gershenson, et al<sup>9</sup>. That a significant difference between the vertical position of mental foramen (a/c) in the two groups (dentate and edentulous).

The disagreement found with the other findings reported by Soikkonen, et al<sup>17</sup>, and Xie, et al<sup>18</sup>. Could be

related to the small sample they studied and difference in race.

### **Horizontal position of mental foramen:**

There was a significant difference ( $p < 0.05$ ) when comparing the mean values of (f/g) (the relative horizontal position of mental foramen) between the total dentate and edentulous groups.

The findings of the present study are confining with the results of previous studies Wang, et al<sup>3</sup>, Guler, et al<sup>5</sup>, and Suaga, et al<sup>12</sup>.

### **Conclusions**

- For both groups (dentate and edentulous), the most common shape of mental foramen on digital panoramic radiographs was the oval shape, followed by the round shape, then the irregular shape, and finally the unidentified type.
- For both groups (dentate and edentulous), the most common appearance of mental foramen on digital panoramic radiographs was the separate type followed by the continuous type, then the diffuse type, and finally the unidentified type.
- Highly significant difference was found when comparing the relative vertical position of mental foramen between the total dentate and edentulous patients groups of the study sample
- The relative vertical position of mental foramen on digital panoramic radiographs (a/c) for dentate group was (1.742), while for the edentulous group it was (1.014).
- A significant difference was found when comparing the relative horizontal position of mental foramen between the total dentate and edentulous patients groups of

2007

the study sample, the relative horizontal position of mental foramen on digital panoramic radiographs (f/g) for dentate group was (0.566), while for the edentulous group it was (0.530).

## References

- 1- Ngeow, WC. And Yazawati, Y. (2003):The location of the mental foramen in a selected Malay population. *J. Oral Sci.* 45(3):171-175.
- 2- Smajilagic, A. and Dilberovic, F. (2004): Clinical and anatomy study of the human mental foramen. *Bosn J Basic Med Sci.* 2004 Jul;4(3):15-23.
- 3- Wang, TM.; Shih, C.; Liu, JC. And Kuo, KJ. (1986):A clinical and anatomical study of the location of the mental foramen in adult Chinese mandibles. *Acta Anat (Basel).* 1986;126(1):29-33.
- 4- Brennan, J. (2002):An introduction to digital radiography in dentistry. *Journal of Orthodontics.* 29( 1): 66-69.
- 5- Guler, AU.; Sumer, M.; Sumer, P. and Bicer, I. (2005):The evaluation of vertical heights of maxillary and mandibular bones and the location of anatomic landmarks in panoramic radiographs of edentulous patients for implant dentistry. *J. Oral Rehabil.* 32(10):741-6.
- 6- Haring, J.I. and Jansen, L. (2000): Dental radiology principles and techniques, normal anatomy. C.W.B.Saunders Co.Ch.26 and 28,P.;429,430,461,463.
- 7- Yosue, T. and Brooks, Sh.L. (1989): The appearance of mental foramina on panoramic radiographs. I. Evaluation of patients. *J. Oral Surg. Oral Med. Oral Pathol.*,68: 360.
- 8- Dahan, J. (1970): Agantho-odontometric analysis of cases with extraction of first molars. *Europ.Orthod.Society.*367-379.
- 9- Gershenson, A.; Nathan, H. and Luchansky E. (1986):Mental foramen and mental nerve: changes with age. *J. Acta. Anat. (Basel).* 126(1):21-8.
- 10- Graves DT.; Al-Mashat, H. and Liu, R. (2004) :Evidence that diabetes mellitus aggravates periodontal diseases and modifies the response to an oral pathogen in animal models. *Compend Contin Educ Dent.* 25(7 Suppl 1):38-45.
- 11- Jeffcoat MK. (2005 ):The association between osteoporosis and oral bone loss. *J. Periodontol.*;76(11 Suppl):2125-32.
- 12- Suaga, K.; Adou, A. and Angoh, Y. (2004): Topographical and morphological study of the mandibular foramen in black Africans from the Ivory Coast. *J.Odontostomatol.Trop.*27(105):17-21.
- 13- Abdulhaleem, S.H.(2004): The shape, appearance, and position of the mental foramen on panoramic radiograph in a selected Baghdadi subjects. M.Sc. thesis, college of dentistry, University of Baghdad.
- 14- Mbajiorgu, EF.; Mawera, G.; Asala, SA. And Zivanovic, S. (1998):Position of the mental foramen in adult black Zimbabwean mandibles: a clinical anatomical study. *J. Cent. Afr J. Med.* 44(2):24-30.
- 15- Moore, PA.; Wyant , RJ. and Mongelluzzo, MB.(2001): Type 1 diabetes mellitus and oral health: assessment of coronal and root caries. *Community Dent Oral Epidemiol.* 29: 183-94.
- 16- Stafne, C. (1985): *Oral Radiographic Diagnosis .* 5th ed., Philadelphia, Saunders Co.
- 17- Soikkonen, K.; Wolf, J.; Ainmao, A. and Xie, Q. (1995) :Changes in the position of the mental foramen as a result of alveolar atrophy. *J. Oral Rehabil.* 22(11):831-833.
- 18- Xie, Q.; Wolf, J.; Ainmao, A. and Soikkonen K. (1996): Height of mandibular basal bone in dentate and edentulous subjects. *J. Acta Odontol Scand.* 54(6):379-383

Table (1): Exposure Parameters used with the Dimax 3 digital panoramic X-ray machine

patient	kVp	mA
Adult Female	64	6
Small adult male	64	6
Adult male	68	7
Large adult male	70	9

2007

Table (2) Chi-square for the percentage of the shape of mental foramen between dentate and edentulous patients

Shape	Oval %	Round %	Irregular %	Unidentified %
Dentate	47.9	38.1	11.8	2.2
Edentulous	47.6	35.9	13.2	3.3
Chi -square	0.209	0.165	0.023	0.010
P-value	0.647 NS	0.684 NS	0.879 NS	0.921 NS

Table (3) Chi-square for the percentage of the appearance of mental foramen between dentate and edentulous patients

Appearance	Continuous %	Separated %	Diffuse %	Unidentified %
Dentate	32.6	60.4	4.9	2.1
Edentulous	26.6	60.1	10.1	3.2
Chi -square	3.205	0.258	0.697	0.010
P-value	0.051 NS	0.612 NS	0.404 NS	0.921 NS

Table(4) Comparison of the vertical position between the total dentate and edentulous patients

Mean±SD	
	a/c
Dentate	1.742± 0.435
Edentulous	1.014± 0.45
t-value	10.260
p-value	0.000 HS

Table(5) Comparison of the relative horizontal position between the total dentate and edentulous patients

Mean ± SD	
	f/g
Dentate	0.566± 0.123
Edentulous	0.530± 0.082
t-value	1.940
p-value	0.041 S



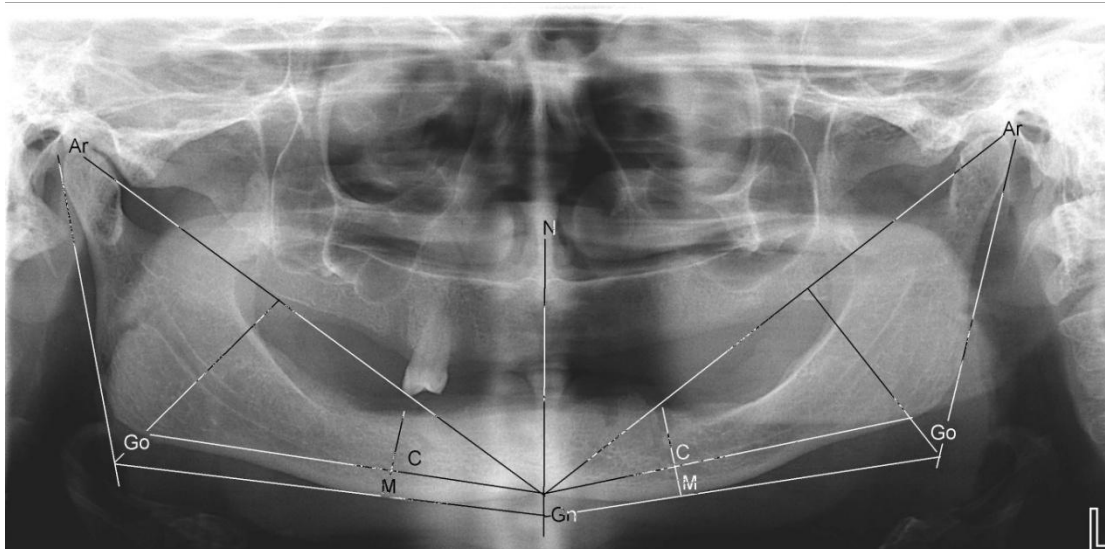
Figure (1): Dimax 3 digital Planmeca X-ray machine (panoramic part)



Figure (2): A) Chin support in place for use in case of edentulous subject



B) Chin rest with the bite piece in place for use in case of dentate subject



Figure(4): Method of tracing used to estimate the relative horizontal position of mental forame