

## mRNA in situ hybridization analysis of VEGF in chronic lymphocytic leukemia

Abdulkareem M. Jaafar\*

Ban A. Abdul Majeed\*

Haythem A. MJ Al-Rubaie \*

MBCbB, MSc, PhD (Hematopathology)

MBCbB, MSc, (Histopathology), Ph.D. (Molecular pathology)

MBCbB, FICMS-Pathology (Hematology)

### Summary:

**Background:** Several factors render chronic lymphocytic leukemia (CLL) an interesting subject for study by researchers. These include marked progress in understanding the molecular biology of normal and neoplastic lymphocytes and recent advances in molecular genetics techniques. Among molecular markers, vascular endothelial growth factor (VEGF), have been widely studied.

**Objective:** The aim of the study is to evaluate the role of VEGF in the pathogenesis of CLL and its role in disease progression.

**Patients, materials and methods:** A retrospective cross-sectional study was done on 60 patients with chronic lymphocytic leukemia (45 males & 15 females) compared with 20 controls (anemic patients), all recruited at the Medical City Hospital/ Teaching Laboratories/ Baghdad from January 2004 to December 2007. The bone marrow biopsy of each was re-examined histologically. In situ hybridization was performed utilizing biotin labeled VEGF cDNA probes.

**Results:** The frequency of VEGF positivity was 95% (57 of 60 cases). A statistically significant inverse correlation was found between increasing VEGF scores and lower packed cell volume level and lower platelet count. A statistically significant association was found between advanced modified Rai stage and patients with high score. In addition, there was a statistically significant positive correlation between increasing scores of VEGF and advancing clinical stage.

**Conclusions:** The score of VEGF is high among patients with advanced clinical stage of the disease.

**Key words:** Chronic lymphocytic leukemia; VEGF; in-situ hybridization.

*Fac Med Baghdad*  
2011; Vol. 53, No. 2  
Received Jan. 2011  
Accepted Feb. 2011

### Introduction:

The proliferation of vascular endothelial cells is a requirement for organ development and differentiation during embryogenesis and for tissue repair and reproductive functions in the adult 1. Angiogenesis is also implicated in the pathogenesis of a variety of disorders including tumors (2, 3). Vascular endothelial growth factor is a potent mitogen for micro and macrovascular endothelial cells derived from arteries, veins and lymphatics, but it is devoid of consistent and appreciable mitogenic activity for other cell types. Consequently, it is regarded as an endothelial cell specific mitogen. In situ hybridization studies have demonstrated that the VEGF mRNA is markedly upregulated in the majority of human tumors examined (1, 3).

### Patients, materials and methods:

**Selection of the patients:** This is a retrospective cross-sectional study; whereby archival paraffin-embedded tissue blocks along with the clinical and hematological records of sixty patients with CLL were recruited at the Department of Hematology of the Medical City Teaching Laboratories in the period from.

January 2004 to December 2007. The patients were newly diagnosed and did not receive prior treatment. The bone marrow biopsies were performed at diagnosis. Paraffin-embedded tissue blocks of twenty control individuals (age and sex matched) along with their hematological reports were also collected. All the control bone marrows were negative for infiltrative lesions and were obtained from patients with anemia due to iron or vitamin B<sub>12</sub> deficiencies.

CLL patients were diagnosed and selected according to the criteria of the International Workshop on CLL (IWCLL) <sup>4</sup> which included: 1- Persistent absolute lymphocytosis of more than 10,000 mature-appearing lymphocytes/ $\mu$ L in the peripheral blood, 2- bone marrow aspirate smear with lymphocytes  $\geq$  30% of all nucleated cells and 3- B-cell monoclonality of peripheral blood. Criteria 1 with either 2 or 3 were needed for diagnosis. In this study, diagnosis was based on criteria 1 and 2.

All patients had peripheral blood prolymphocytes of less than 10%.

Clinical staging was done according to the modified Rai staging system 5.

### In-situ hybridization:

Sections, 5  $\mu$ m in thickness were made on positively charged slides (Esco) from all the study sample and

\* Dept. of Pathology/ College of Medicine/ University of Baghdad

control groups and subjected for in-situ hybridization procedure to detect mRNAs of VEGF.

Biotinylated cDNA liquid probe for VEGF together with the in-situ hybridization/ detection kit were purchased from Maxim biotech, USA.

The kit contains a housekeeping gene probe as a positive control. A target positive control was also used, which included sections from invasive ductal carcinoma of the breast already positive for VEGF. The procedure of in-situ hybridization was conducted according to the manufacturing company. It involved deproteinization of fixed tissue sections mounted on slides by proteinase-k enzyme, hybridization of a denatured biotinylated probe to the target sequence and denaturation of the target mRNAs in tissue sections. The hybridized probe was then detected by streptavidin- alkaline phosphatase (streptavidin-AP) conjugate. Upon addition of the substrate solution which is 5-brom-4 chloro-3 indolyl phosphate/nitro blue tetrazolium (BCIP/NBT), an intense blue signal appeared at the specific site of the hybridized probe.

**Evaluation of the in situ hybridization signal:** Hybridization signals (diffuse, granular or focal), were detected either in the nucleus or in the cytoplasm of CLL lymphoid cells of BM biopsies with good preservation of the morphological details. In most patients, mononuclear cells (fibroblasts, macrophages, and polymorphs) also revealed positive signal of VEGF. These cells were found as few, isolated, or clustered elements, throughout the stroma and were clearly distinguished from CLL cells both on morphologic basis and because they usually displayed a different signaling intensity (in plus or minus) from CLL cells. Care was taken to recognize these cells and omit them from the evaluation. Endothelial cells, which could be identified in most cases, were positive. Normal lymphoid cells present in BM biopsies of control group did not show any signal for VEGF (the median BM lymphocyte percentage was 11.5% with a range between 5 and 20%). Therefore, CLL was considered positive when at least 1% of lymphoid cells gave positive hybridization signal.

Scoring of in situ hybridization signal was evaluated under light microscopy (X100, X400 and X1000), whereas the counting of positive cells was performed at oil immersion (X1000). Counting of positive cells was conducted in 10 different fields taking their mean for each sample.

ISH was given percentage scores, based on the number of stained cells. Percentage scores were assigned as: score 1 (low) = 1-25%, score 2 (intermediate) = 26-50%, and score 3 (high) = 51-100%<sup>6</sup>.

Statistical analysis was performed with the *SPSS16* statistical software program (SPSS Inc. Chicago, IL, USA). Associations between categorical variables were assessed via crosstabulation and chi-square. Spearman correlation was used to correlate variables when at least one variable was ordered. Exact tests

were used to calculate the *p* value. In all statistical analyses, a *p* value < 0.05 was considered significant.

### Results:

The overall frequency of VEGF positivity in CLL was 95% (57 of 60 cases; 43 males & 14 females), with no statistically significant difference between males and females (table 1).

No significant difference was found between VEGF-positive and VEGF-negative patients when they are subdivided according to modified Rai staging system (table 2).

The distribution of the different percentages of VEGF-scores among the CLL patients is shown in table 3 and figure 1. No statistically significant difference was found between VEGF-positive males and females regarding score.

A significant direct inverse correlation was found between increasing VEGF scores and lower PCV levels ( $P < 0.001$ ) and lower platelet count ( $P = 0.002$ ) as shown in figures 2 A & B.

A significantly larger number of patients, with high score for VEGF signal, was associated with advanced clinical stage than patients with low score ( $p < 0.001$ ) (Table 4). At the same time, there was a statistically significant direct positive correlation between increasing scores of VEGF-positive CLL cells and advancing clinical stage of the disease ( $p < 0.001$ ) (Figure 3).

**Table 1. Distribution of VEGF signal in CLL patients according to sex.**

		Sex		
		Male	Female	Total
VEGF signal	Positive	43	14	57
<i>P</i> = N.S.	Negative	2	1	3
	Total	45	15	60

**Table 2. Distribution of VEGF signal according to**

		Modified Rai stage			
		Low	Intermediate	High	Total
VEGF signal	Positive	1	17	39	57
<i>P</i> =	Negative	0	3	0	3
N.S.	Total	1	20	39	60

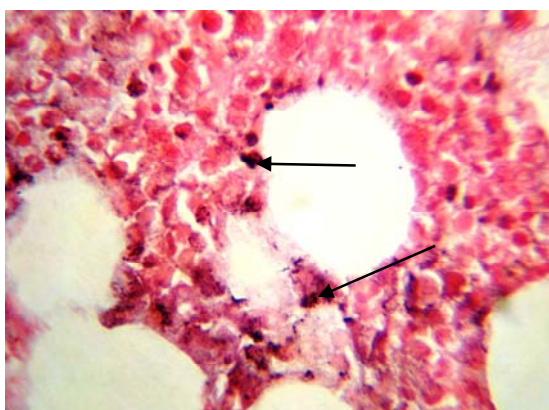
**clinical stage of the disease.**

**Table 3. Distribution of VEGF score according to sex.**

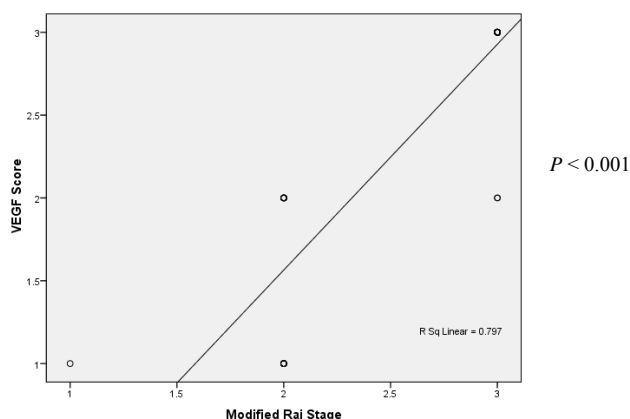
		Sex		
		Male	Female	Total
VEGF score	Low (1-25%)	8	2	10
	Intermediate (26-50%)	7	3	10
<i>P</i> = N.S.	High (51-100%)	28	9	37
	Total	43	14	57

**Table 4. Distribution of VEGF score according to the clinical stage of the disease.**

		Modified Rai stage			
		Low	Intermediate	High	Total
VEGF score	Low (1-25%)	1	9	0	10
	Intermediate (26-50%)	0	8	2	10
	High (51-100%)	0	0	37	37
$P < 0.001$	Total	1	17	39	57



**Figure 1. CLL: BM biopsy. Positive VEGF ISH signal. The lymphocytes show blue cytoplasmic staining (arrows); high score (× 1000).**



**Figure 3. Scatter-plot showing the correlation between VEGF score and clinical stage.**

**Discussion:**

A number of studies have demonstrated an important role for VEGF in CLL (7, 8).

The frequency of VEGF positivity in our CLL patients was high (95%) (table 1). This was similar to that reported by other workers who found high frequency of expression of VEGF using IHC methods (9, 10) or measured intracellular VEGF levels by immunoblot methods 11. These earlier observations indicated that dysregulated angiogenesis is a common phenomenon in CLL. They also showed that the proangiogenic factor VEGF is expressed by CLL cells (9, 12). No association was found between VEGF signal positivity and the sex of patients (table 1). Other workers reported similar results (7, 8).

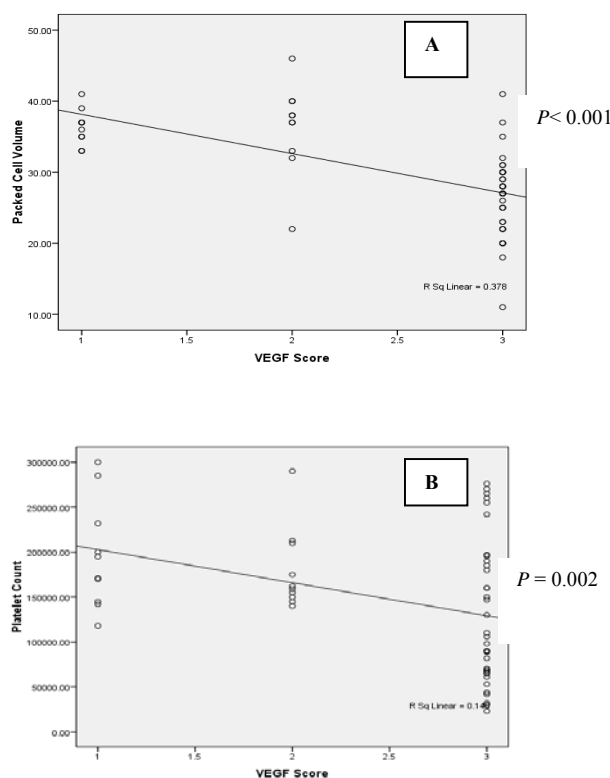
No significant difference was found between VEGF-positive and VEGF-negative patients when they are subdivided according to modified Rai staging system (table 2). Other workers reported similar results 10. No statistically significant difference was found between VEGF-positive males and females regarding score (table 3). Similar results were reported by other workers 11.

An inverse relationship was found between VEGF score and each of PCV level and platelet count (figures 2 A & B). Frater et al 11, referred to the role of hypoxia induced by low PCV level in the upregulation of VEGF. Also low PCV level and low platelet count are indicators of high-risk clinical stage of the disease (13, 14). This finding indicates that increasing VEGF positivity is a stage dependent prognostic indicator.

This study indicated that VEGF score, as assessed by ISH, is significantly correlated with the clinical stage of the disease (table 4 & figure 3).

Molica et al 9 had demonstrated that the expression of VEGF evaluated immunohistochemically, was correlated with the clinical stage and progression-free survival.

These findings suggest that dysregulation of angiogenesis is common in CLL, and as such may represent an early event in leukemogenesis. Since the



**Figure 2. Scatter plot showing correlation between VEGF scores and PCV level (A) and platelet count (B).**

clinical course of CLL may last many years, the acquisition of other genetic mutations may augment the earlier dysregulation of angiogenesis, accounting for the increased VEGF positivity seen in higher stage individuals. It also indicates that CLL demonstrates upregulated VEGF and this may switch the avascular phase of the disease to the vascular phase and thus may contribute to disease progression and a poor prognosis. Patients with a shorter duration of disease may have more modest changes in angiogenic status 10.

## References

1. Ferrara N. Vascular endothelial growth factor. *Eu J Cancer* 1996; 32 A: 2413-2422.
2. Fidler I. Regulation of neoplastic angiogenesis. *J Natl Cancer Inst Monogr* 2000; 28:10-14.
3. Hicklin D and Ellis L. Role of the vascular endothelial growth factor pathway in tumor growth and angiogenesis. *J Clin Oncol* 2005; 23: 1011-1027.
4. International Workshop on Chronic Lymphocytic Leukemia: Recommendations for diagnosis, staging, and response criteria. *Ann Intern Med* 1989; 110: 236.
5. Rai K, Sawitsky A, Cronkite E, Chanana A, Levy R, Pasternack B. Clinical staging of chronic lymphocytic leukemia. *Blood* 1975; 46: 219-234.
6. Blancato J, Singh B, Liu A, Liao D, Dickson R. Correlation of amplification and overexpression of the c-myc oncogene in high-grade breast cancer: FISH, in situ hybridization and immunohistochemical analysis. *Br J Canc* 2004; 90: 1612-1619.
7. Aguayo A, O'Brien S, Keating M, et al. Clinical relevance of intracellular vascular endothelial growth factor levels in B-cell chronic lymphocytic leukemia. *Blood* 2000 a; 96:768-770.
8. Molica S, Cutrona G, Vitelli G, et al. Markers of increased angiogenesis and their correlation with biological parameters identifying high-risk patients in early B-cell chronic lymphocytic leukemia. *Leuk Res* 2007; 31: 1575-1578.
9. Molica S, Vacca A, Ribatti D, et al. Prognostic value of enhanced bone marrow angiogenesis in early B-cell chronic lymphocytic leukemia. *Blood* 2002; 100: 3344-3351.
10. Frater J, Kay N, Goolsby C, Crawford S, Dewald G, Peterson L. Dysregulated angiogenesis in B-cell chronic lymphocytic leukemia: Morphologic, immunohistochemical, and flow cytometric evidence. *Diagnostic Pathology* 2008; 3:16.
11. Faderl S, Keating M, Do K-A, et al. Expression profile of 11 proteins and their prognostic significance in patients with chronic lymphocytic leukemia (CLL). *Leukemia* 2002; 16: 1045-1052.
12. Kini A, Kay N, Peterson L. Increased bone marrow angiogenesis in B-cell chronic lymphocytic leukemia. *Leukemia* 2000; 14: 1414-1418.
13. Ghia P, Ferreri AM, Galigaris-Cappio F. Chronic lymphocytic leukemia. *Crit Rev Oncol/Hematol* 2007; 234-246.
14. Inamdar K. and Bueso-Ramos C. Pathology of chronic lymphocytic leukemia: an update. *Annals of diagnostic pathology* 2007; 11: 363-389.