

## Morphological and Histopathological Liver Abnormalities Caused by Carbamazepine Induced Injury in Female Albino Mice

Nawar R. Jaber<sup>1</sup>, Nahla A. Al-Bakri<sup>2</sup>

<sup>1</sup> Biotechnology Research Center/ Environmental Biotechnologies department/Al-Nahrain University/Baghdad-Iraq

<sup>2</sup>Dept. of Biology / College of Education for Pure Science (Ibn- Al-Haitham) / University of Baghdad/Baghdad-Iraq

\*Correspondence: [Nawar.r.j@nahrainuniv.edu.iq](mailto:Nawar.r.j@nahrainuniv.edu.iq)

Received: 21/10/2023

Accepted: 11/03/2023

Online: 15/05/2024

2024. This is an open access article under the CC by licenses

<http://creativecommons.org/licenses/by/4.0>



### ABSTRACT

**Background:** The adverse effects of drugs can damage various organs, especially the liver, leading to a hepatic injury known as hepatotoxicity. Drug-induced liver injury (DILI) is challenging nowadays because of the large number of different drugs used, one of the offending medications that cause DILI is carbamazepine (CBZ), since the liver has an array of functions including detoxification, it will deal with several damages caused by exposure to the drugs. Objective: investigate the effect of (CBZ) 20mg/kg/day on female mice liver after 14 and 30 days of treatment on morphological and histopathological levels. **Materials and Methods:** 20mg/kg/day of CBZ was administered orally for (14) days to (10) female mice, another (10) mice were taking the same concentration for 30 days, and control groups were administered tap water. **Results:** The findings showed that CBZ can cause liver enlargement, changes in liver appearance, distortion in Glisson's capsule, cytologic alterations, hepatocytes hypertrophy, ballooning degeneration, pyknosis, karyolysis, karyomegaly, sinusoids dilation, increase in the number and sizes of Kupffer cells, fibrosis, glycogen depletion, and cirrhosis. **Conclusions** These findings have shown that carbamazepine (CBZ) can cause hepatotoxicity that can manifest into morphological and histopathological changes.

Keywords: liver, dili, cbz, hepatocytes, mice.

DOI: <https://doi.org/10.24126/jobrc.2024.18.1.778>

### 1-INTRODUCTION

The adverse effects of drugs can damage various organs, especially the liver, leading to a hepatic injury known as hepatotoxicity, the exposure to the drug reaction can be quite serious (1). Drug-induced liver injury (DILI) is considered the 4th important cause of liver disease (2) and is challenging nowadays because of the large number of different drugs used (3). DILI is the main cause of acute liver failure (4) that has been also described alongside severe hepatic injury (acute and chronic) and cirrhotic abnormalities after the use of manufactured or natural compounds, herbal products (5) anticancer drugs, anesthetics, anti-tuberculosis agents, antibiotics, cardiac medications and antiretroviral (6). Adults seem to be at greater risk than children to encounter DILI (7) due to the increase in drugs amount used, advanced age (50 years old and higher) are at higher risk of developing DILI (8). In order to help the pharmaceutical industry, the FDA issued in the year 2009 guidelines to be of use when conducting drugs development for medications that cause liver injury (9), since hepatotoxicity is one of the causes of clinical trials discontinuation and drug withdrawal from the market, in 2022 the FDA's national center for toxicological research launched a project called liver toxicity knowledge base (LTKB) to study DILI, the objective of that step is to develop resources to improve our understanding for hepatotoxicity and to be of use for investigators and scientific researchers (10). One of the offending medications that cause DILI is carbamazepine (CBZ), but severe hepatotoxicity caused by it is infrequent (3), CBZ is prescribed widely in the neuropsychiatry field (11), and has both anticonvulsant and antinociceptive properties (12), used for the treatment of acute mania (13), bipolar disorder (14) and plays an important role in epilepsy treatment (15), in many countries, it is one of the most prescribed drugs for the treatment of focal epilepsy (16) since the liver has an array of functions including detoxification (17) it will deal with several damages caused by exposure to the drugs (1). Chronic DILI research in the last decade is still not fully understood and lacking (18), some cases with persistent DILI may need life-long therapy to control the condition (19), if not managed properly, severe cases such as ALF may require liver transplantation (20).

## 2- MATERIAL AND METHODS

Animals. Female albino mice *Mus musculus* (the national center for drug control and research. Baghdad) between the age of (8-12) weeks were kept in a facility with controlled temperature and access to food and water at the biology department in the college of education for pure science (Ibn Al-Haitham).

- The first experiment:

carbamazepine (CBZ) was administered orally for (14) days to (10) mice (1<sup>st</sup> group) at 20 mg/kg/day, tap water was administered to the control group of (10) mice (2<sup>nd</sup> group).

- The second experiment:

The antiepileptic drug (CBZ) was given for (30) days to (10) mice (3<sup>rd</sup> group) at 20 mg/kg/day, and the (4<sup>th</sup> group), the control, was also administered tap water. After 14 days, groups of the first experiment were sacrificed, as for the second experiment, the groups were sacrificed after 30 days. Dissection was performed on all groups and the organs (livers) of the mice were collected and fixed in 10% formalin for 2 days. The histological sections were made using the paraffin method, liver sections were routinely stained with hematoxylin and eosin (21), periodic acid-Schiff (PAS) for the assessment of glycogen deposits (22), and Masson's trichrome for the assessment of fibrosis and cirrhosis (23).

## 3-RESULTS

The control group morphological study showed that the liver was red-brown, smooth, and consisted of four lobes, a right lobe, left lobe, medial lobe and a caudate lobe, located under the diaphragm, above the stomach, the gallbladder is found attached, between the right and quadrate liver lobes (figure 1). After 14 days of treatment with CBZ 20mg/kg/day, noticeable changes were found in liver size and appearance, the liver was enlarged and covered all the organs located under it, pits were found on the liver surface, and yellow spots (figure 2). After 30 days of treatment with CBZ 20 mg/kg/day, the liver increased more in size with yellow discoloration and white spots, pits were scattered on the surface (figure 3A&B).

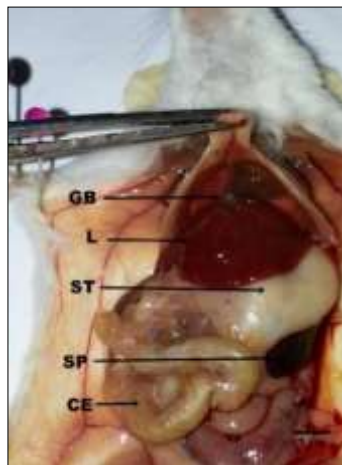


Figure (1) The normal liver in female mice control groups and other organs, the liver is visible when the mouse is first opened. gallbladder(GB), liver(L), stomach(ST), spleen(SP), cecum(CE).

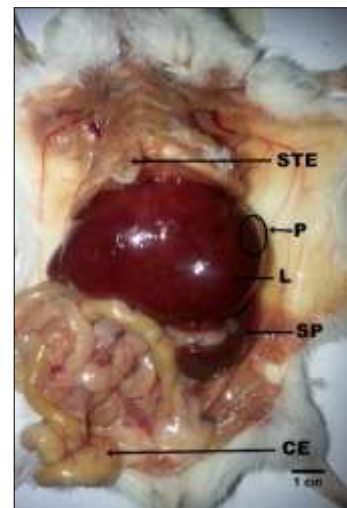


Figure (2) Liver of female mice after 14 days of treatment with CBZ 20 mg/kg/day, the liver showed enlargement and changes in its normal morphology, scattered pits on the surface and change in color. Sternum (STE), pits(P).

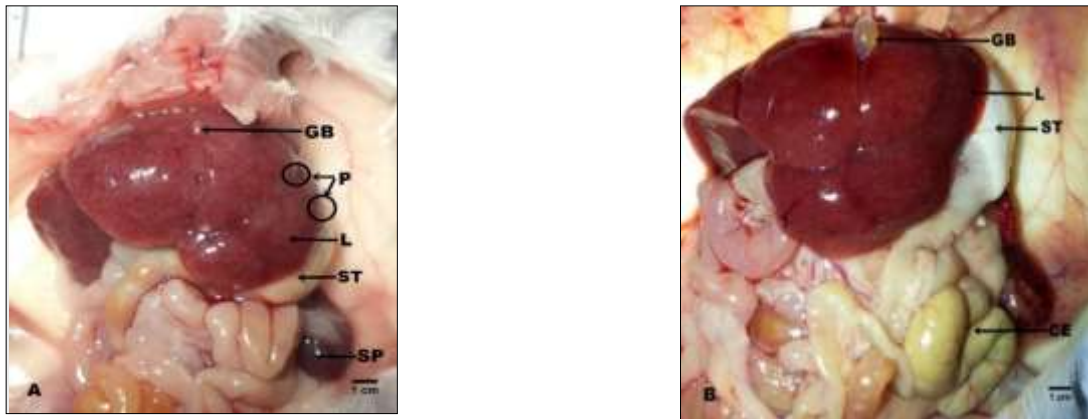


Figure (3A&B) Liver of female mice after 30 days of treatment with CBZ 20 mg/kg/day, notice the increased enlargement in the liver with discoloration and scattered pits on the surface. Gallbladder(GB), pits(P), liver(L), sternum(ST), spleen(SP), cecum(CE).

The histological study of the control groups under the light microscope using hematoxylin and Eosin stain showed that the liver was covered by a fibrous layer, known as Glisson's capsule in a convex manner (figure 4). As for the parenchyma, the hepatocytes were arranged radially in the hepatic cords that contains one row of hepatocytes in a classical hexagonal lobule, the lobule contain a central vein in the middle and portal areas at the peripheral of the lobule (figure5).

Hepatocytes were polyhedral in shape with eosinophilic cytoplasm, the cells contained a rounded nucleus, some cells were binucleated, vascular sinusoids lined with endothelial cells were found between the hepatocytes, the sinusoids and the hepatocytes were separated by perisinusoidal space (or space of Disse) (figure 6). As for the collagen fibers, they appeared in the liver tissue of the control group arranged symmetrically around the central vein, and their presence was noted around the portal vein and between the sinusoids as well when using Masson's trichrome stain (figure7). Regarding the glycogen granules, they appeared in the control group hepatocyte's cytoplasm in the form of granules of dark color scattered inside the hepatocyte when using the Periodic Acid Schiff (PAS) stain (figure 8).

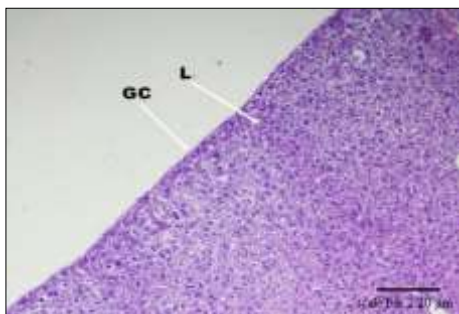


Figure (4) Glisson's capsule (GC) in control group liver tissue, H&E, 10x, scale bar 2.20 μm.

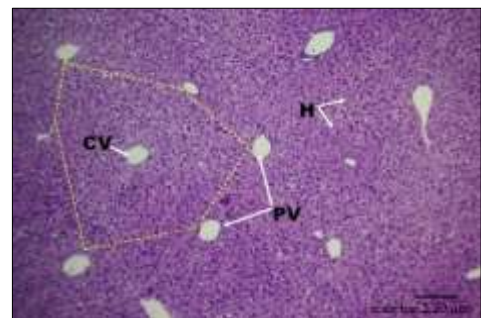


Figure (5) Hexagonal hepatic lobule (yellow dotted line) central vein (CV), hepatocytes(H) and portal vein (PV) in female mice liver tissue of the control groups, H&E, 10x.

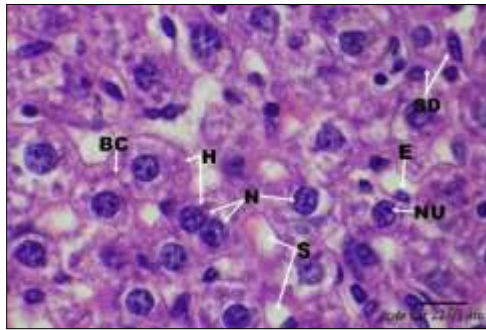


Figure (6) Hepatocytes(H), nucleus(N), nucleolus(NU), bile canaliculus(BC), sinusoids(S), endothelial cells(E), space of Disse(SD) in in female mice liver tissue of the control groups, H&E, 100x.

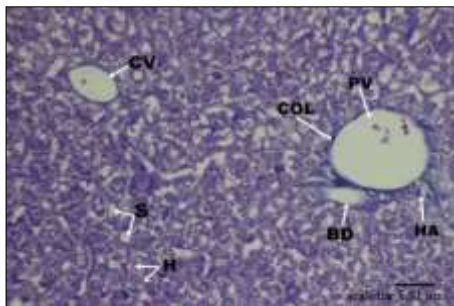


Figure (7) Cross section in female mice liver tissue of the control groups demonstrating collagen fibers (COL), hepatocytes(H), portal venule(PV), bile ductule(BC), hepatic arteriole(HA), central vein(CV), sinusoids(S), Masson's trichrome, 40x.

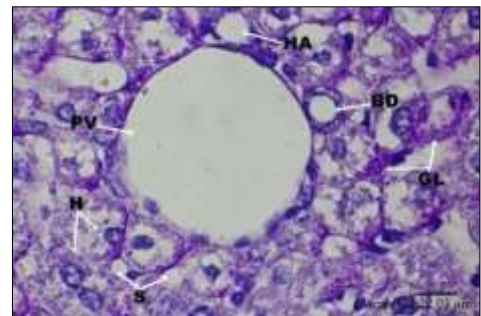


Figure (8) Cross section in female mice liver tissue of the control groups demonstrating glycogen granules(GL), Periodic acid Schiff (PAS), 100x.

The group of female white mice that was treated with CBZ at the concentration of 20 mg/kg/day for 14 days showed the following histological changes: The treatment with the drug led to liver damage compared to what it was with the control group, and the damage represented a distortion in Glisson's capsule which appeared disjointed and irregular, as well as the appearance of a sub-capsular space (figure.9).It was also observed that the radial organization of the hepatocytes architecture was scattered with cytologic alterations that were reflected in the appearance of light and dark areas in the tissue(figure 10A&B).Cellular changes represented by the hypertrophy of hepatocytes, as their size and the size of their nuclei and cytoplasm increased significantly were also observed (figure 11).Some hepatocytes showed ballooning degeneration, as the cell swelled and the cytoplasm appeared with a clear and pale appearance (figure 12), collected inside it and in a large quantity with a central dark nucleus that suffered from pyknosis in some hepatocytes (figure 13), and karyolysis in others (figure 14).Treatment with CBZ for 14 days led to dilation in the sinusoids, as well as an increase in the number and sizes of Kupffer cells inside them, the hepatic cords were scattered in the liver parenchyma, as they appeared irregularly and disjointed (figure 15).When using Masson's trichrome stain, fibrosis was represented by the increased accumulation of collagen fibers around the portal area, sinusoids, and central veins(figure 16).Periodic acid Schiff (PAS)stain demonstrated that glycogen was slightly depleted from hepatocytes, which was represented by the accumulation of glycogen granules on one side of the cells, and the depleted areas in hepatocytes appeared light in color(figure 17).

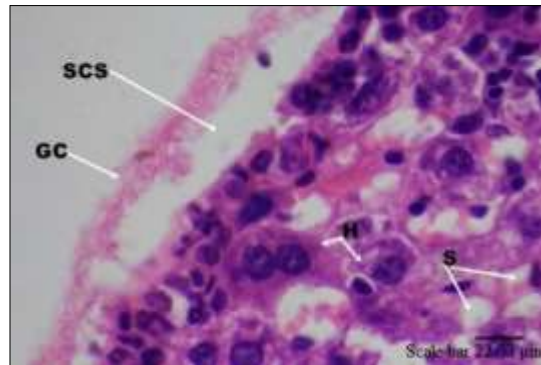


Figure (9) Cross section in the liver of female mice treated with CBZ 20mg/kg/ day for 14 days showing a damage in Glisson's capsule(GC) represented by a distortion, disjointed and irregular capsule, as well as the appearance of a sub-capsular space (SCS), H&E. 100x.

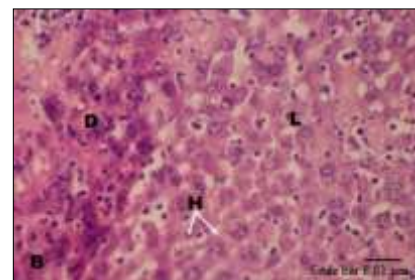
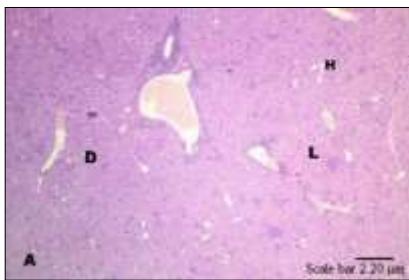


Figure (10A&B) Cross section in the liver of female mice treated with CBZ 20mg/kg/ day for 14 days, the radial organization of the hepatocytes (H) is scattered, cytotogic alterations represented by the appearance of light (L) and dark (D) areas in the parenchyma, H&E, A: 10x, B: 40x.

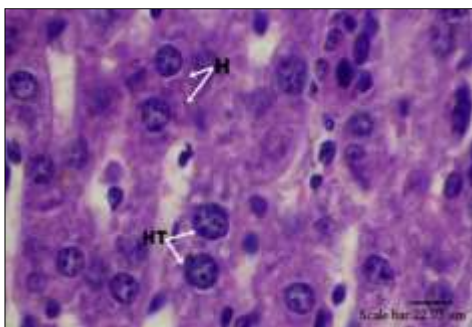


Figure (11) Cross section in the liver of the female mice treated with CBZ 20mg/kg/ day for 14 days showing hepatocyte (H) hypertrophy (HT), H&E, 100x.

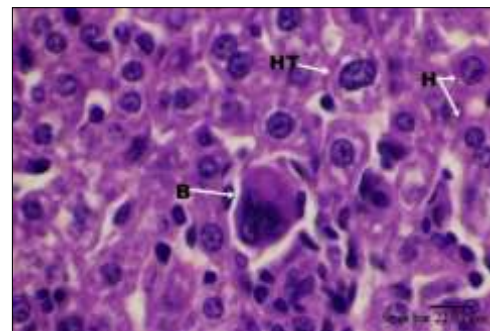


Figure (12) Cross section in the liver of the female mice treated with CBZ 20mg/kg/ day for 14 days, notice the ballooning degeneration (B), H&E, 100x.

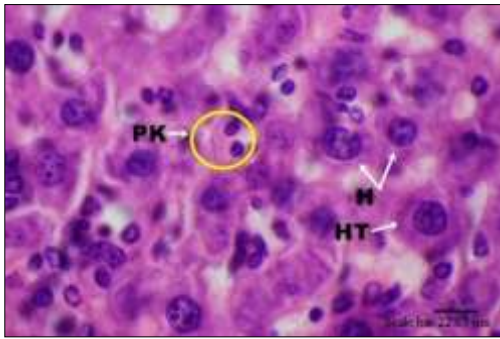


Figure (13) Cross section in the liver of the female mice treated with CBZ 20mg/kg/ day for 14 days showing pyknosis (PK) in the hepatocytes(H) nucleus, and hypertrophy (HT), H&E, 100x.

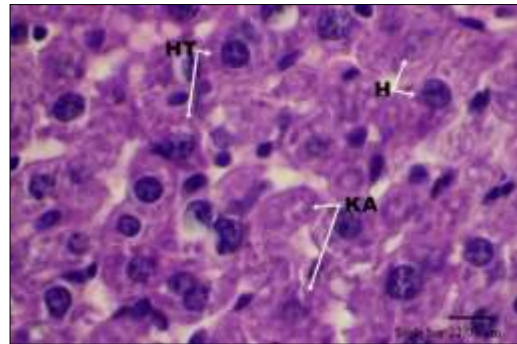


Figure (14) Cross section in the liver of the female mice treated with CBZ 20mg/kg/ day for 14 days showing karyolysis (KA), H&E, 100x.

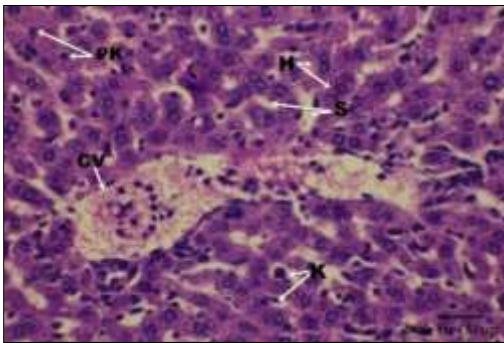


Figure (15): Cross section in the liver of the female mice treated with CBZ 20mg/kg/ day for 14 days, the treatment led to sinusoid (S) dilation and scattering of the hepatic cords around the central vein (CV), Kupffer cells hypertrophy (K), pyknosis(PK) in some hepatocytes(H), H&E, 40x.

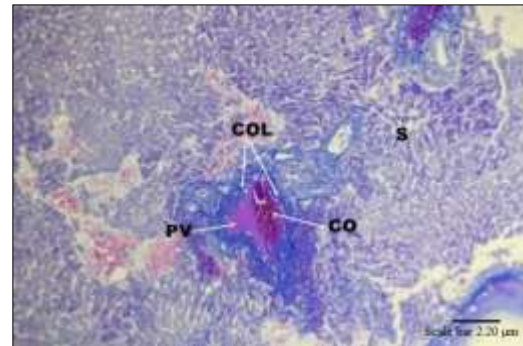


Figure (16) Cross section in the liver of the female mice treated with CBZ 20mg/kg/ day for 14 days, fibrosis due to CBZ treatment, collagen (COL) accumulation around the portal venule(PV), congestion (CO), Masson's trichrome stain, 10x.

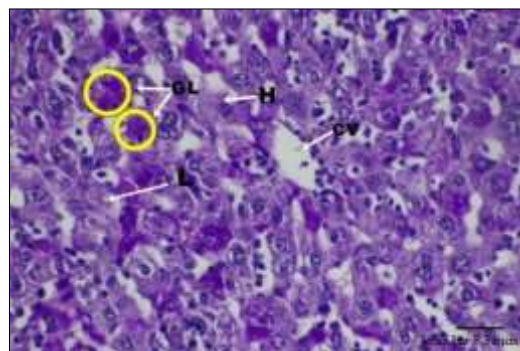


Figure (17) Cross section in the liver of the female mice treated with CBZ 20mg/kg/ day for 14 days showing glycogen (GL) depletion, notice that the depleted areas appeared light (L) in color, Periodic acid Schiff (PAS), 40x.

The group treated with CBZ for 30 days at 20 mg/kg/day dose cross-sections showed massive damage to liver tissue compared to what it was with the control group, the damage was greater than that which appeared in the 1st experiment, especially in Glisson's Capsule, the damage was represented by the disintegration of the capsule with the disappearance of its natural convexity around the liver and the appearance of concavity in it (figure.18A&B). There were also cytologic Alterations represented by a scattering of the radial organization of hepatocytes (figure.19). Hepatocyte hypertrophy was confirmed in this group by the enlargement of the cytoplasm throughout the tissue, as there was an increase in the size and contents of the cells (figure.20). Hydropic degeneration was also seen in some hepatocytes (figure.21), which appeared swollen as a result of fluid accumulation inside them with a pyknotic nucleus (figure.22), some nuclei suffered from Karyolysis and disappeared completely (figure.23). It should be noted that some nuclei showed karyomegaly, as the nucleus occupied most of the cell and the nuclear material appeared in a lumpy form (figure.24). Sinusoid dilation, increase in Kupffer cells and hepatic cords scattering was noticed in this group (figure.25&26). Advanced fibrosis was seen throughout the liver tissue, and by using Masson's trichrome stain (figure.27), nodules of different sizes with loose fibrous tissue around the edges of the nodules were represented by perisinusoidal fibrosis (PSF) with periportal fibrosis (PPF), as well as a fibrous septum (FS) separating the hepatic cords indicated the presence of cirrhosis were noticed in this group (figure.28). By using periodic acid Schiff (PAS) stain, significant depletion of glycogen from hepatocytes was also notable (figure.29).

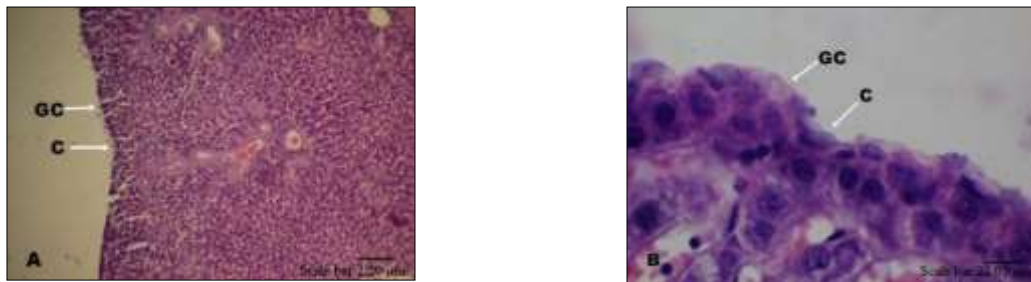


Figure (18A&B) Cross section in the liver of female mice treated with CBZ 20mg/kg/ day for 30 days showing a massive damage in Glisson's capsule (GC) disintegration of the capsule with the disappearance of its natural convexity around the liver and the appearance of concavity (C) in it, H&E, A: 10x, B: 100x.

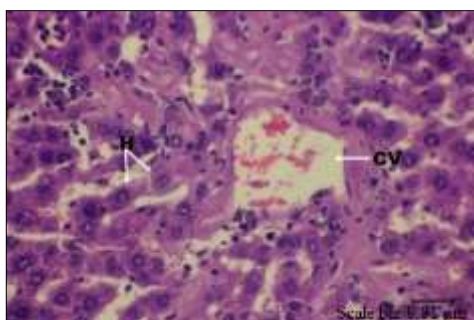


Figure (19) Cross section in the liver of female mice treated with CBZ 20mg/kg/ day for 30 days showing cytologic Alterations represented by a scattering of the radial organization of hepatocytes (H) around the central vein (CV), H&E, 40x.

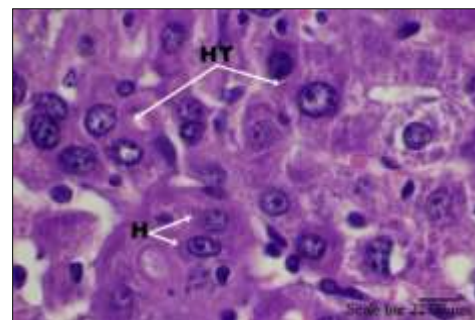


Figure (20): Cross section in the liver of female mice treated with CBZ 20mg/kg/ day for 30 days showing hypertrophy (HT), H&E, 100x.

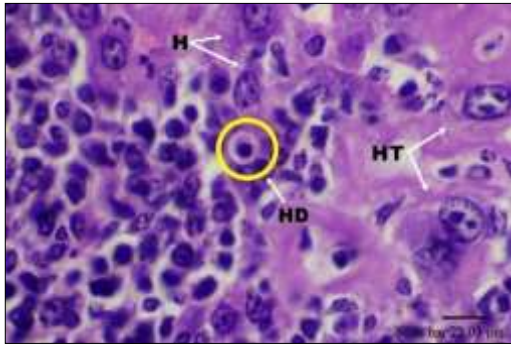


Figure (21) Cross section in the liver of female mice treated with CBZ 20mg/kg/ day for 30 days, notice the hydropic degeneration(HD) in the hepatocytes(H), H&E, 100x.

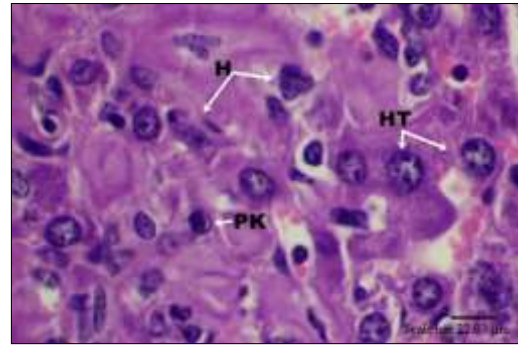


Figure (22) Cross section in the liver of female mice treated with CBZ 20mg/kg/ day for 30 days, pyknosis(P) is noticeable in some hepatocytes, H&E, 100x.

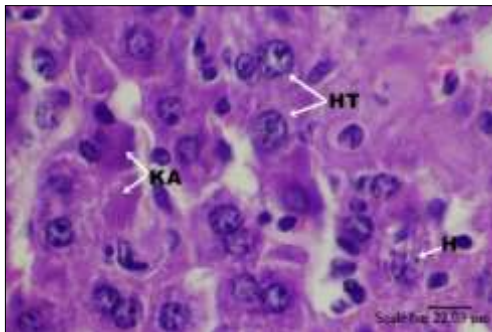


Figure (23) Cross section in the liver of female mice treated with CBZ 20mg/kg/ day for 30 days, karyolysis (KA) is noticeable in some hepatocytes, H&E, 100x.

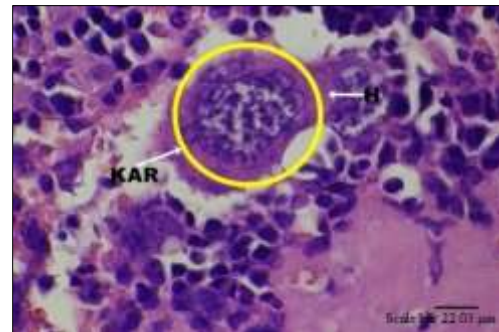


Figure (24) Cross section in the liver of female mice treated with CBZ 20mg/kg/ day for 30 days, Karyomegaly is seen in some hepatocytes, H&E, 100x.

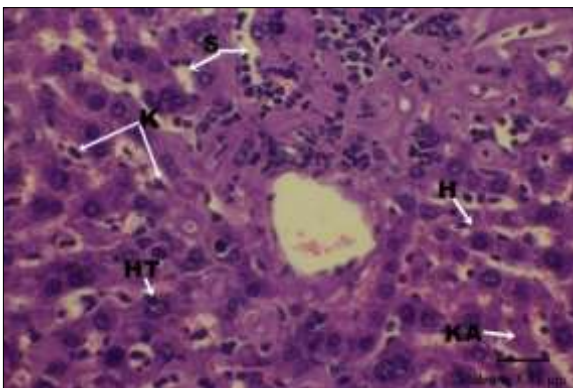


Figure (25) Cross section in the liver of female mice treated with CBZ 20mg/kg/ day for 30 days showing sinusoidal (S) dilation, hypertrophy (HT), karyolysis (KA) in some hepatocytes(H) and increase Kupffer cells(K), H&E, 40x.

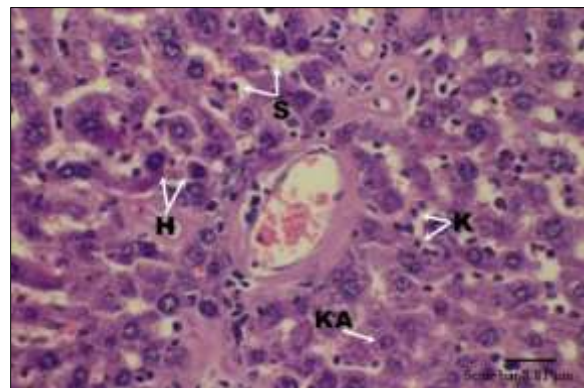


Figure (26) Cross section in the liver of female mice treated with CBZ 20mg/kg/ day for 30 days showing scattering in the hepatic cords, H&E, 40x.



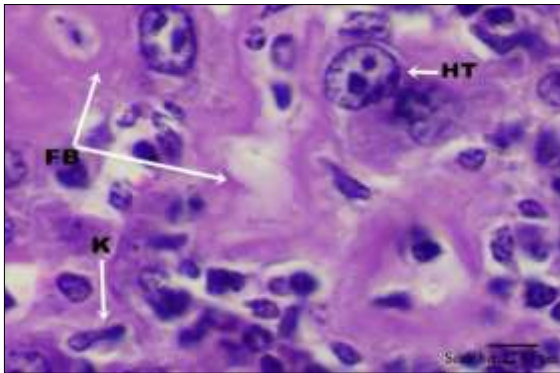


Figure (27): Cross section in the liver of female mice treated with CBZ 20mg/kg/ day for 30 days showing an advanced fibrosis (FB) throughout the liver tissue, H&E, 100x.

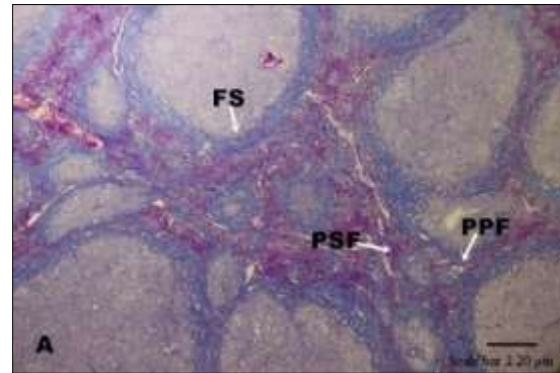


Figure (28): Cross section in the liver of female mice treated with CBZ 20mg/kg/ day for 30 days showing cirrhosis, fibrous septum(FS), perisinusoidal fibrosis (PSF), periportal fibrosis(PPF), Masson's trichrome stain, 10x.

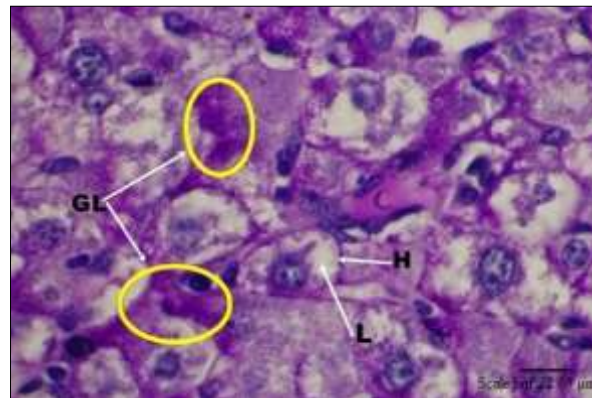


Figure (29): Cross section in the liver of female mice treated with CBZ 20mg/kg/ day for 30 days showing significant depletion of glycogen(GL) from the hepatocytes(H), notice that the depleted areas appeared light (L) in color, periodic acid Schiff (PAS), 100x.

#### 4-DISSION

The oral administration of CBZ 20 mg/kg/day for 14 and 30 days showed noticeable changes on some histological features of the liver in female white mice. After 14 and 30 days of treatment, the morphology of the liver was affected, several pits were seen on its surface and they were more prominent in the 30 days group, it appeared that inflammation is the main cause, change in the liver's color from normal brown-red to yellowish color and white spots were also seen, the liver was hard and increased in size, this may be a sign of liver fibrosis (24) and the toxicity of the drug. In the present study, the histopathological findings showed that there are different and obvious effects in liver tissue of the treated groups for 14 and 30 days, the results indicated that administration of CBZ distorts Glisson's capsule, the disappearance of the natural convex of the capsule with the appearance of a sub capsular space which was caused by hepatic contour retraction, this can result from several

causes including cirrhosis, infection, benign and malignant tumors (25). Cytologic alterations were also present in the treated groups for 14 and 30 days, these alterations manifested in the appearance of dark and light areas, which could be related to the microsomal enzyme induction or the peroxisomes proliferation (26), and smooth endoplasmic reticulum proliferation which is also seen in cases related to Phenobarbital treatment for epilepsy (27).Hydropic degeneration and ballooning degeneration are known to occur after CBZ treatment (28) hepatocytes appeared swollen and round in shape due to fluid accumulation with a central dark nucleus and pale cytoplasm, this degeneration and the cytoplasmic changes are the results of cloudy swelling that is known to be a form of cell death, it happens after an increase in Na<sup>+</sup> and K<sup>+</sup> ions inside the cells (29).Organelles swelling such as SER is noticed in the hepatocytes, it is generally accepted that the chronic use of antiepileptic drugs can cause cell death of all kinds such as neurons when drugs like PHT and VPA were used (30). Drug-induced liver injury(DILI) and cell death with necrosis or apoptosis depend mostly on the drug in use that can lead to oxidative stress on the organelles such as SER and mitochondria which can lead to cell death in both kinds (31). While cell death that results from Idiosyncratic DILI is caused by the contribution of both innate and adaptive immunity and mostly apoptosis, death receptors are thought to be participating in it too (31).These harmful cytological effects can induce immunological responses in both innate and adaptive immunity, and that damage to the hepatocyte can lead it to produce induction signals to other cells correlated with innate immunity such as Kupffer cells and natural killer cells (32).The findings of the present study revealed that the nucleus was affected by the toxicity of the drug in both treated groups, and a degenerative condition of a hepatocyte nucleus called pyknosis is seen (33), this condition occurred in studies related to LEV use on mice embryo's kidney that causes cell injury leading to necrosis, in addition to congenital malformation (34). Pyknosis was not the only pathological change, karyolysis, dissolution of the hepatocyte nucleus was found, it is proven that the toxicity of the drugs such as Paracetamol can lead to liver injury, it is known that karyolysis happens after the destructive fragmentation and the breaking down of chromatin in the necrotic cells (35).There was an increase in nucleus size, especially in the 30 days group, this condition is referred to as karyomegaly and is found in cases of hepatic hypertrophy due to enzymic induction, karyomegaly is a reflection of nucleus polyploidy that happens when there is a duplication in the nuclear material in the absence of failure in cytokinesis, hepatocyte ploidy increases with age, uses of toxic materials, surgery, oxidative damage, excessive metabolic load, and DNA damage (36).This condition is also seen in other organs such as the heart, brain, and skeletal muscles, hepatocytes that are affected with polyploidy become old and unable to proliferate, the more this condition occurs the more evident how great the damage is (37).The progression of CBZ toxicity caused dilation in the sinusoids in both treated groups, this change was more prominent in the 30 days group, this condition is linked to the inflammation that causes a decrease in venous blood flow (38) or an obstruction in the central vein that lead to congestion and an increase in venous pressure that leads to dilation in the sinusoids (39).The structural changes in the sinusoids coexisted with an increase in Kupffer cells, there was an increase in size and filopodia's number, it is known that the immune response triggers these cells which is related to the drug toxicity that damages the endothelium and parenchyma causing congestion and cytokines releases due to inflammation (40) and advanced fibrosis (41).Venous blood impairment can lead to congestion in liver parenchyma and blood vessels (39) due to the toxicity of the drug. A study of the toxic effect of Acetaminophen on a rat's liver showed that Kupffer cells release chemokines that promote infiltration of other inflammatory cells into the liver (42), the cytokines that are released from these cells lead to a cytotoxic effect which helps in the progression of the hepatic injury, after chronic use, the hepatic stellate cells cause fibrosis by releasing transforming growth factor-  $\beta$ 1(TGF- $\beta$ 1) (43). Hepatic injury is thought to be caused by the bioactivation of the drugs and active chemical metabolites that can react with macromolecules in the cells such as proteins, lipids, and nucleic acids causing protein dysfunction, oxidative stress, DNA damage, and lipid peroxidation (44).The accumulation of collagen fibers led to the formation of fibrosis, fibrosis spread in liver tissue and was more prominent in the 30 days group, when using Masson's trichrome stain in this study to identify fibrosis, the stain showed a derangement of the tissue architecture represented by perisinusoidal fibrosis, fibrous septum, and periportal fibrosis, bile ductule reaction caused periportal fibrosis, the ductule produces basement membrane that contains collagen IV and laminin (45).The activated mesenchymal cells, fibroblasts, and Ito cells

are found around the ductule secreting several factors, that suggest that the ductule reaction may have a role in the progression of fibrosis and cirrhosis (46). The effect of high levels of hepatic enzymes plays a role in fibrosis, and an increase in aspartate aminotransferase (AST) and alanine aminotransferase (ALT) was caused by enzymic induction when anti-viral treatment was used (47).

Chronic inflammation causes a variety of pathologic conditions, hepatic fibrosis is an example, the prolonged inflammation causes abnormal accumulation of collagen that form around the sinusoids in addition to re-arrangement of the extracellular matrix molecules that led to derangement in the liver tissue and functions (48). The matrix can work as a modulator for fibrosis (49). In a study of the defense role of Kupffer cells, while using cadmium in rat's liver, the fibrosis led to the release of immune cells such as Kupffer cell, and the factors released from this cell caused the activation of hepatic stellate cell that transforms into myofibroblast (50). Development of regenerative nodules was seen in the 30 days group when Periodic acid–Schiff stain was used, this stage is considered most complex and dangerous after fibrosis that resulted from necrosis, constant hepatocyte destruction that arises from the liver parenchyma breakage is the next step, fibrosis will accumulate around the necrotic hepatocytes and the proliferated bile ducts, causing the development of nodules leading to cirrhosis that is the final stage (51). When using periodic acid–Schiff stain, glycogen depletion from the hepatocytes was identified in both groups. Glycogen granules were seen outside the hypertrophied cells with the appearance of pale areas that indicate the depletion, especially in the 30 days group. Antipsychotic drug treatment can give rise to hyperglycemia that in turn cause an increase in glycogen consumption, it is also believed that the reactive metabolites have a role in the depletion process (52). Detoxification can cause glycogen depletion (53) that happens after using materials that cause hepatotoxicity, linked completely with the formation of reactive metabolites that lead to glycogenolysis which protects against the toxic side effects of the drug (54).

**5- CONCLUSIONS:** These findings have shown that carbamazepine (CBZ) can cause hepatotoxicity that can manifest into morphological and histopathological changes.

## REFERENCES

1. Paniagua AC, Amariles P. Hepatotoxicity by drugs. *Pharmacokinetics and Adverse Effects of Drugs - Mechanisms and Risks Factors.* (2018); doi:10.5772/intechopen.72005
2. Schuster D, Laggner C, Langer T. Why drugs fail - a study on side effects in New Chemical Entities. *Current Pharmaceutical Design.* (2005);11(27):3545–59. doi:10.2174/138161205774414510.
3. Bourhia M, Ullah R, S. Alqahtani A, Ibenmoussa S. Evidence of drug-induced hepatotoxicity in the Maghrebian population. *Drug and Chemical Toxicology.* (2020);45(3):985–9. doi:10.1080/01480545.2020.1797088.
4. Chang CY, Schiano TD. Review article: Drug hepatotoxicity. *Alimentary Pharmacology & Therapeutics.* (2007);25(10):1135–51. doi:10.1111/j.1365-2036.2007.03307. x.
5. Stickel F, Egerer G, Seitz HK. Hepatotoxicity of botanicals. *Public Health Nutrition.* (2000);3(2):113–24. doi:10.1017/s136898000000161.
6. Fisher K, Vuppalanchi R, Saxena R. Drug-induced liver injury. *Archives of Pathology & Laboratory Medicine.* (2015);139(7):876–87. doi:10.5858/arpa.2014-0214-ra.
7. Koch L. Propylthiouracil use associated with severe hepatotoxicity in children. *Nature Reviews Endocrinology.* (2010);6(8):416–416. doi:10.1038/nrendo.2010.96.
8. Katarey D, Verma S. Drug-induced liver injury. *Clinical Medicine.* (2016);16(Suppl 6). doi:10.7861/clinmedicine.16-6-s104.
9. Center for Drug Evaluation and Research. Drug-induced liver injury: Premarketing clinical evaluation (Internet). FDA; (cited 2023 Nov 24). Available from: <https://www.fda.gov/regulatory-information/search-fda-guidance-documents/drug-induced-liver-injury-premarketing-clinical-evaluation>.
10. Research NC for T. Liver toxicity knowledge base (LTKB) (Internet). FDA; (cited 2023 Nov 23). Available from: <https://www.fda.gov/science-research/bioinformatics-tools/liver-toxicity-knowledge-base-ltkb>.
11. Ganesh S, Shukla L, Kandasamy A, Benegal V. A case of carbamazepine-induced severe cholestatic hepatitis: Case report and review of literature. *Indian Journal of Psychological Medicine.* (2017);39(5):688–90. doi:10.4103/ijpsym.ijpsym\_19\_17.

12. Kaplan HI, Sadock BJ, V CA, Tohen V. Biological therapies. In: Comprehensive textbook of psychiatry. 7th ed. Lippincott Williams & Wilkins. (2000).
13. Soares MBM, Moreno RA, Moreno RA, Moreno DH. Tratamento médico-clínico. In: Almeida KM, editor. Transtorno Bipolar do Humor. SãoPaulo: Lemos Editorial. (2002).
14. Moreno RA, Moreno DH, Soares MB, Ratzke R. Anticonvulsivantes e antipsicóticos no tratamento do Transtorno Bipolar. *Revista Brasileira de Psiquiatria*. (2004);26(suppl 3):37–43. doi:10.1590/s1516-44462004000700009.
15. Jędrzejczak J, Majkowska-Zwolińska B, Ryglewicz D, Nagańska E, Mazurkiewicz-Beldzińska M. Recommendations of the Polish Society of Epileptology for the treatment of epileptic seizure in adult patients in Poland: An update. *Journal of Epileptology*. (2019);27:9–16. doi:10.21307/jepil-2019-002.
16. Beydoun A, DuPont S, Zhou D, Matta M, Nagire V, Lagae L. Current role of Carbamazepine and oxcarbazepine in the management of epilepsy. *Seizure*. (2020);83:251–63. doi:10.1016/j.seizure.2020.10.018.
17. Almazroo OA, Miah MK, Venkataramanan R. Drug metabolism in the liver. *Clinics in Liver Disease*. (2017);21(1):1–20. doi:10.1016/j.cld.2016.08.001
18. Wang Q, Huang A, Wang J-B, Zou Z. Chronic drug-induced liver injury: Updates and future challenges. *Frontiers in Pharmacology*. (2021);12. doi:10.3389/fphar.2021.627133.
19. Kleiner DE. Histopathological challenges in suspected drug induced liver injury. *Liver International*. (2017);38(2):198–209. doi:10.1111/liv.13584.
20. Hayashi PH, Rockey DC, Fontana RJ, Tillmann HL, Kaplowitz N, Barnhart HX, et al. Death and liver transplantation within 2 years of onset of drug- induced liver injury. *Hepatology*. (2017);66(4):1275–85. doi:10.1002/hep.29283.
21. Suvarna S, Layton C, Bancroft J. Bancroft’s theory and practice of histological techniques. Churchill Livingstone/Elsevier; (2016).
22. McManus JF. Histological and histochemical uses of periodic acid. *Stain Technology*. (1948);23(3):99–108. doi:10.3109/10520294809106232.
23. Garvey W. Modified elastic tissue-Masson Trichrome stain. *Stain Technology*. (1984);59(4):213–6. doi:10.3109/10520298409113858.
24. Scudamore CL. A practical guide to the histology of the mouse. Chichester: Wiley Blackwell; (2014).
25. Tan GX, Miranda R, Sutherland T. Causes of hepatic capsular retraction: A pictorial essay. *Insights into Imaging*. (2016);7(6):831–40. doi:10.1007/s13244-016-0520-7.
26. Lee JW, Kim S, Kwack SW, Kim CW, Moon TY, Lee SH, et al. Hepatic capsular and subcapsular pathologic conditions: Demonstration with CT and Mr Imaging. *RadioGraphics*. (2008);28(5):1307–23. doi:10.1148/rg.285075089.
27. Thoolen B, Maronpot RR, Harada T, Nyska A, Rousseaux C, Nolte T, et al. Proliferative and nonproliferative lesions of the rat and mouse hepatobiliary system. *Toxicologic Pathology*. (2010);38(7\_suppl):5–81. doi:10.1177/0192623310386499.
28. Jezequel AM, Librari ML, Mosca P, Novelli G, Lorenzini I, Orlandi F. Changes induced in human liver by long term anticonvulsant therapy functional and ultrastructural data. *Liver*. (1984);4(5):307–17. doi:10.1111/j.1600-0676.1984.tb00943.x.
29. Elshama SS, Osman HEH, El-Kenawy AE-M. Histopathological study of developmental toxicity of Carbamazepine in the mice. (2014);7(10):616–22.
30. Lock EA, Ishmael J, Pratt I. Hydropic change in rat liver induced by hexachloro- 1 : 3–butadiene. *Journal of Applied Toxicology*. (1982);2(6):315–20. doi:10.1002/jat.2550020610.
31. Forcelli PA, Kim J, Kondratyev A, Gale K. Pattern of antiepileptic drug-induced cell death in limbic regions of the neonatal rat brain. *Epilepsia*. (2011);52(12). doi:10.1111/j.1528-1167.2011.03297.x.
32. Iorga A, Dara L, Kaplowitz N. Drug-induced liver injury: Cascade of events leading to cell death, apoptosis or necrosis. *International Journal of Molecular Sciences*. (2017);18(5):1018. doi:10.3390/ijms18051018.
33. Malhi H, Gores GJ, Lemasters JJ. Apoptosis and necrosis in the liver: A tale of two deaths? *Hepatology*. (2006);43(Supplement 1):31–44. doi:10.1002/hep.21062.
34. Kumar V, Abbas AK, Aster JC, Robbins SL. Robbins basic pathology. Philadelphia, Pa: Elsevier Saunders; (2013).
35. Al-Ibrahimi. LHM, Al-Bakri. NA. Teratogenic Effect of Keppra (Levetiracetam) Drug on the Kidney in Albino Rat (*Rattus rattus*). *IHJPAS (Internet)*. (2017) Mar. 13 (cited 2023 Nov. 24);28(2):8-21. Available from: <https://jih.uobaghdad.edu.iq/index.php/j/article/view/143>.

36. Zamzami N, Kroemer G. Condensed matter in cell death. *Nature*. (1999);401(6749):127–8. doi:10.1038/43591.
37. Wang M-J, Chen F, Lau JT, Hu Y-P. Hepatocyte polyploidization and its association with Pathophysiological Processes. *Cell Death & Disease*. (2017);8(5):2805. doi:10.1038/cddis.2017.167.
38. Marzano C, Cazals Hatem D, Rautou P, Valla D. The significance of nonobstructive sinusoidal dilatation of the liver: Impaired portal perfusion or inflammatory reaction syndrome. *Hepatology*. (2015);62(3):956–63. doi:10.1002/hep.27747.
39. Brancatelli G, Furlan A, Calandra A, Dioguardi Burgio M. Hepatic sinusoidal dilatation. *Abdominal Radiology*. (2018);43(8):2011–22. doi:10.1007/s00261-018-1465-8.
40. Fu S, Korkmaz E, Braet F, Ngo Q, Ramzan I. Influence of kavain on hepatic ultrastructure. *World Journal of Gastroenterology*. (2008);14(4):541–6. doi:10.3748/wjg.14.541.
41. Sharma V, Singh M. therapeutic efficacy of isolated stigma-5,22 dien-3-o-b-d-glucopyranoside and ethanolic root extract of operculina turpethum against n- nitrosodimethylamine induced hepatopathy in the liver of mice: ultrastructural and histological evidences. *Int J Pharm Pharm Sci*. (2014);6(9):226–30.
42. Laskin DL, Pilaro AM. Potential role of activated macrophages in acetaminophen hepatotoxicity. *Toxicology and Applied Pharmacology*. (1986);86(2):204–15. doi:10.1016/0041-008x(86)90051-7.
43. Salguero Palacios R, Roderfeld M, Hemmann S, Rath T, Atanasova S, Tschuschner A, et al. Activation of hepatic stellate cells is associated with cytokine expression in thioacetamide-induced hepatic fibrosis in mice. *Laboratory Investigation*. (2008);88(11):1192–203. doi:10.1038/labinvest.2008.91.
44. Bartsch H, Hietanen E, Malaveille C. Carcinogenic nitrosamines: Free radical aspects of their action. *Free Radical Biology and Medicine*. (1989);7(6):637–44. doi:10.1016/0891-5849(89)90144-5.
45. Miyabayashi C, Kojima T, Inoue K, Sasaki H, Muragaki Y, Ooshima A. Ultrastructural localization of type IV collagen, laminin and prolyl hydroxylase in biliary epithelial cells of rat liver following ligation of the common bile duct. *Gastroenterologia Japonica*. (1987);22(3):354–69. doi:10.1007/bf02774262.
46. Mendenhall CL. Liver cirrhosis. edited by J. L. Boyer and L. Bianchi, 465 pp. Lancaster, England: MTP Press, 1987. *Hepatology*. (1988);8(4):979–80. doi:10.1002/hep.1840080452.
47. Azu OO, Jegede AI, Ugochukwu O, Onanuga IO, Kharwa S, Naidu EC. Hepatic histomorphological and biochemical changes following highly active antiretroviral therapy in an experimental animal model: Does Hypoxia Hemerocallidea exacerbate hepatic injury? *Toxicology Reports*. (2016);3:114–22. doi:10.1016/j.toxrep.(2015).12.013.
48. Opoku AR, Ndlovu IM, Terblanche SE, Hutchings AH. In vivo hepatoprotective effects of rhoicissus tridentata subsp. cuneifolia, a traditional Zulu medicinal plant, against CCL4-induced acute liver injury in rats. *South African Journal of Botany*. (2007);73(3):372–7. doi:10.1016/j.sajb.2007.02.193.
49. Schuppan D, Ruehl M, Somasundaram R, Hahn EG. Matrix as a modulator of Hepatic fibrogenesis. *Seminars in Liver Disease*. (2001);21(03):351–72. doi:10.1055/s-2001-17556.
50. Sauer J-M, Waalkes MP, Hooser SB, Kuester RK, McQueen CA, Sipes IG. Suppression of Kupffer cell function prevents cadmium induced hepatocellular necrosis in the male Sprague-Dawley rat. *Toxicology*. (1997);121(2):155–64. doi:10.1016/s0300-483x(97)00062-0.
51. Mohan H. Textbook of pathology. 6th ed. New Delhi: Jaypee Brothers Medical Publishers; (2010).
52. Maharaj V, Fitz M, Ding X. Drug-induced liver injury in the setting of glycogenic hepatopathy. *Journal of General Internal Medicine*. (2017);32(6):714–7. doi:10.1007/s11606-017-3996-z.
53. Mitchell J, Jollow D, Potter W, Gillette J and Brodie B. Acetaminophen-induced hepatic necrosis. iv. protective role of glutathione. *Journal of Pharmacology and Experimental Therapeutics*, (1973); 187(1):211–217.
54. Dimlich RV, Townsend SF, Reilly FD. Mast cell degranulation, hepatic glycogen depletion, and hyperglycemia in compound 48/80 or Pilocarpine-treated rats. *Hepatology*. (2007);2(3):372–8. doi:10.1002/hep.1840020314.

## التشوهات الشكلية والنسجية المرضية في الكبد الناجمة عن الإصابة المستحثة بعقار كاربامازيبين في اناث الفأر الابيض

نوار رشدي جابر<sup>1</sup> \* نهلة البكري<sup>2</sup>

مركز بحوث التقنيات الاحيائية، قسم التقنيات الاحيائية البيئية، جامعة النهرين، بغداد ، العراق  
قسم علوم الحياة، كلية التربية للعلوم الصرفة، ابن الهيثم، جامعة بغداد ، بغداد ، العراق

### الخلاصة

**خلفية عن الموضوع:** ان الآثار الضارة للعقاقير يمكن أن تلحق الأذى بأعضاء مختلفة، وخاصة الكبد، مما يؤدي إلى إصابة الكبد المعروفة باسم السمية الكبدية. تمثل إصابة الكبد الناجمة عن الأدوية تحديًا في الوقت الحاضر بسبب العدد الكبير من الأدوية المختلفة المستخدمة، أحد الأدوية المخالفة التي تسبب هذه الإصابة هو كاربامازيبين (CBZ)، نظرًا لأن للكبد مجموعة من الوظائف بما في ذلك إزالة السموم، فسوف يتعامل مع العديد من الأضرار الناجمة عن التعرض للعقاقير. **الهدف من الدراسة:** دراسة تأثير عقار كاربامازيبين 20ملغم/كغم/يوم على كبد اناث الفئران بعد 14 و 30 يوماً من المعاملة على المستويين الشكليائي والنسجي المرضي. **المواد وطرائق العمل:** تم تجريب 20 ملغم/كغم/يوم من عقار كاربامازيبين عن طريق الفم لمدة (14) يوماً إلى (10) فئران، وتم تجريب (10) فئران أخرى بنفس التركيز لمدة 30 يوماً، وتم إعطاء مجموعات السيطرة ماء الحنفية. **النتائج:** أظهرت النتائج أن عقار كاربامازيبين يمكن أن يسبب تضخم الكبد، تغيرات في مظهره، تشوه في محفظة جليسون، تغيرات خلوية، تضخم خلايا الكبد، تنكس انتفاخي، تغلظ النواة، انحلال النواة، تضخم الخلايا، اتساع الجيبانبات ، زيادة في عدد وأحجام خلايا كوففر. الاحتقان والتليف ونضوب الجليكوجين وتليف الكبد. **الاستنتاج:** أظهرت هذه النتائج أن لعقار الكاربامازيبين القابلية على أن يسبب تسمم الكبد الذي يمكن أن تظهر ملامحه في التغيرات الشكلية والنسجية المرضية.

**الكلمات المفتاحية:** الكبد، ال-DILI، CBZ، خلايا الكبد، الفئران.