
**MANAGEMENT OF COMPLEX ANAL FISTULAS; UP-TO
DATE AND NEW TECHNIQUES****Ibrahim Falih Noori**

MBChB, CABS, FICS, DS, Lecturer, Department of Surgery, College of Medicine, Basra University, IRAQ.

Fistula in ano is a track lined by granulation tissue which connects perianal skin superficially to anal canal, ano rectum or rectum deeply. It usually occurs in a pre-existing anorectal abscess which either bursts spontaneously or inappropriately drained. Other rare causes include inflammatory bowel disease, tuberculosis, carcinoma and trauma¹. Perianal fistulous disease has significant implications for patient's quality of life as sequelae range from minor pain and social hygienic embarrassment to frank sepsis. The management of the anal fistula remains one of the most challenging and controversial topic in anorectal surgery². Surgery remains the mainstay of therapy with ultimate aim of draining the abscess, eradicating the fistulous tract and avoiding recurrence with preserving anal sphincter function³. Treatment depends on where the fistula lays, which parts of the anal sphincter it crosses, etiology, duration of the fistula as well as previously performed procedures^{3,4}. Most anal fistulae are simple and can be treated using a fistulotomy which has good results, low recurrence rate and an acceptable rate of morbidity⁵. Treatment of a complex anal fistula, however, which is defined as these fistulae which open into the anal canal at or above the internal ring and whose treatment poses an increased risk for a change in continence still represent a challenge. Complex are anatomically higher, involve significant portions of the

sphincter musculature, may have multiple tracts, involve other organs

(e.g. vagina) and may be associated with radiation or inflammatory bowel disease⁶. Recurrent fistulas are usually considered as high anal fistula as well. Fistulae that traverse a significant portion of both sphincters are called trans-sphincteric and are part of group of complex fistulae^{4,6}.

Lay-open fistulotomy along these tracts are effective at fistula closure for the same pathophysiologic reason as simple fistulae, but based on the amount of the sphincter involved, may results in significant change in continence^{4,7,8}. Thus is no longer considered an acceptable approach. This article will cover some new promising procedures in treatment of high and complex anal fistulae.

Seton placement: Figures 1&2

This is a foreign piece of material inserted through the fistula tract which functions to maintain the fistula tract in an open state, preventing a closed space infection, and allowing for drainage and sepsis resolution⁸. A Seton (from Latin, seta, "bristle") involves inserting a silk or linen ligature across the fistula and left in place with a tie. The seton is tightened over time, gradually cutting through the sphincter muscle and healing as it goes. Once the fistula tract is in a low position it may be laid open to speed up the process of healing or the seton can remain in a place until the fistula is completely cured⁹. This process takes longer duration to heal, it is usually done for complex or trans-

sphincteric fistulae or it may be used prior to definitive procedures like fistulectomy or advancement flap. Seton can be kept for 3 months and it can be regularly replaced by new silk or linen by rail road technique without anesthesia. Two types of setons are present⁹.


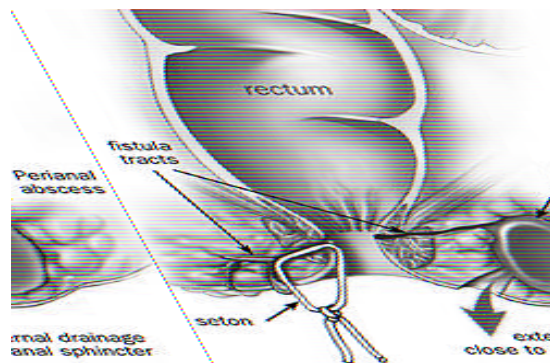
1. Loose setons are used mainly to drain for long period in recurrent /postoperative fistulas and due to specific causes like Crohns . There is no tension in seton.

2. Cutting setons are used when enclosed muscles is needed to cut (cheese wiring through ice effect). It is placed tight.

Seton technique is safe and usually simple method for control of the basic pathophysiologic insult that creates the fistula. Appropriate complex fistula management almost always indicates initial seton placement. Appropriate anorectal hygiene in the form of Sitz bath or showering is used until the infection clears. This creates a stable situation in which a fistula can be maintained indefinitely. Once sepsis and

inflammation have subsided, the presence of the seton in an uninfected tract allows for accurate delineation of the fistula anatomy, either by careful clinical exam, ultrasound or radiological study^{10,11}.

The idea beyond the use of cutting seton is that slow division of muscle allows for fibrosis and scarring and that overall integrity of the sphincter complex is maintained¹¹. This procedure, however, has several disadvantages. It required frequent office visits for tightening some times weekly or every two weeks. It is usually uncomfortable or painful for the patient and usually results in the need for narcotic or non-steroidal analgesia. In addition, despite the scarring through a maintained sphincter complex, continence can be negatively affected, so these procedures must be approached with caution. The reported success rates have been reported as similar to fistulotomy, changes in continence have been reported in greater than 50% of patients¹².



Figures 1&2: Fistula in ano, seton placement

Endorectal advancement flaps

Advancement flap procedures may be considered for complex fistula or if there is a high risk of incontinence. Advancement flap is a piece of tissue that is removed from the rectum or from the skin around the anus. In this procedures, the internal opening of the fistula is identified and a flap of mucosal tissue is cut around the opening¹³. The flap is lifted to expose the fistula, which is then cleaned and the internal opening is sewn

shut. After cutting the end of the flap on which the internal opening was, the flap is pulled down over the sewn internal opening and sutured in place. The external opening is cleaned and sutured, thus depriving the fistula of its source of sepsis, and allowing the de-functionalized tract to heal by secondary intention¹⁴.

This procedure is technically more difficult and is often plagued by difficult exposure, especially on posteriorly located fistulae. Fistulae with higher internal

openings are quite difficult to reach as well¹⁵. Additionally, this procedure involves the creation of a large defect in previously undamaged rectum, and run the risk of devascularization and loss of much larger portion of rectal wall. Failure or ischemia of these flaps may results in creation of a much larger defect than existed previously. Success rates for this approach vary widely through literature, and range from 0 to 63%^{16,17}.

Controversy is still continuing regarding the optimal flap approach. Mucosa-only flaps may minimize the risk to unaffected rectum, but a randomized trial comparing partial thickness advancement to mucosa alone demonstrated improve efficacy in fistula closure with thicker flaps¹⁸.

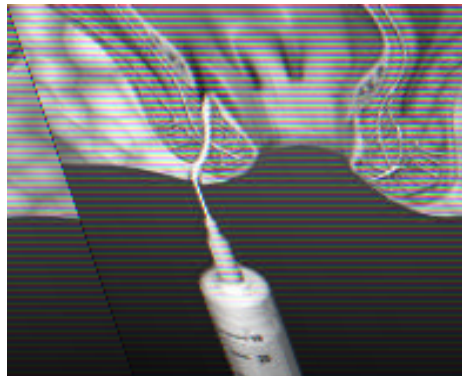
Fibrin glue injection: Figure 3

Fibrin glue is composed of a combination of fibrinogen, thrombin and calcium in a mixture. It is currently the only non-surgical option for treating anal fistulae¹⁹. This method explored in recent years with variable success. It involves injecting the fistula with biodegradable glue which should, in theory, close the fistula from inside out, and let it heal naturally. Fibrin glue injection was the first recent development in sphincter-sparing approaches to complex fistulae²⁰. The major advantages of fibrin glue are the extremely benign nature of approach. It requires no dissection or risk to the

sphincter complex regardless of the anatomy or complexity of the fistulous tract and has potential applications in inflammatory bowel as well^{20,21}.

Fibrin glue may seem an attractive option as it is safe, simple and painless procedure. However, long term results for this treatment method are poor. For example, one small study had initial success rate of 77%, but after 18 months only 14% of patients were still successfully healed and a more recent study reported a recurrence rate of 10%-78%²¹.

In the past decade, this technique was increasingly popular, but today many doubts about fibrin glue procedure still remain because of its poor long term results²². Currently, fibrin glue injection did not advocate as primary therapy given its lack of demonstrated success. It is most often used as an adjunct measure when combined with other methods such as advancement flap²³. Newer approaches have modified the use of fibrin glue with the addition of adipose derived stem cells, and this approach shows promise: in one study 71% of the patients with the enhanced approach healed their fistula, compared to 16% with fibrin glue alone. It is worthwhile to mention that failure of this treatment does not preclude other subsequent treatment²⁴.



Anal fistula plug: Figures 4&5

Anal fistulous plug involves plugging the fistula with a device made from small intestinal submucosa²⁵. The fistula plug is positioned from inside of the anus with suture. The small intestinal sub mucosa is a natural biomaterial harvested from porcine small intestine and fabricated into a biomedical product of various shape and thickness. The anal fistula plug has a biological configuration suitable for fistula disease²⁶.

The anal fistula plug is a simple repair that does not involve an extensive dissection. The plug is pulled through the fistula tract and secured in place at the internal opening (the wider portion of the plug is at the internal opening) and trimmed to the skin at the external opening with the external opening left open to drain. The idea is to bridge the defect of the fistula with a biocompatible material that would act as a scaffold for the patient own fibroblasts to come in and promote wound healing in fistula tract²⁷.

The technique of anal fistulous plug is as follows: The fistula tract is explored, probed and irrigated gently with hydrogen peroxide. The apex of the plug is tied then to the probe from the internal opening, and the plug is pulled through to the external opening. It is cut to fit and is secured in the internal opening by using a figure of eight suture incorporating it with the mucosa of the anorectum to close the internal opening.

The success rate with this method is as high as 80%^{25,27}. As opposed to the staged operations, which may require multiple hospitalizations, the fistulous plug procedure requires hospitalization for only

about 24 hour or less. This treatment option does not carry any risk of incontinence and can be regarded as a sphincter sparing procedure^{28,29}.

Systemic review published by Pankaj Garg et. al.³⁰ shows that, the success rate of fistula plug is 65-75%. An early prospective series of 46 patients reported by Champagne et. al.³¹ after a median follow –up of 12 months, 17% of fistulae recurred. Johnson et. al. reported an 87% closure rate for fistula plug group versus a 40% closure rate for the glue group. This was further supported by a study from Case Western^{32,33} documenting an 83% success rate; however with more studies the overall success rate has been found to be lower with some studies reporting a 20% success rate. Jacob and Keighleys⁶ recent meta-analysis found success rates ranging from 35%-85%. A consensus conference was held in 2007 in an attempt to standardized the indications for use of anal fistula plug and technique for its placement. The conference made a number of recommendations, first, it stressed that the use of the fistula plug could only be used in trans-sphincteric anal fistulae without acute inflammation or infection. The group felt that dislodgement of the anal fistula plug was a problem related to the technique of plug placement. It was also stressed on the importance of the external fistula opening being patent to allow for drainage.

It is worthwhile to note that the anal fistula plug procedure would probably be suitable for low trans-sphincteric fistula. The only variable that correlated with treatment outcome was the amount of sphincter involved.




Figure 4: Anal fistula plug

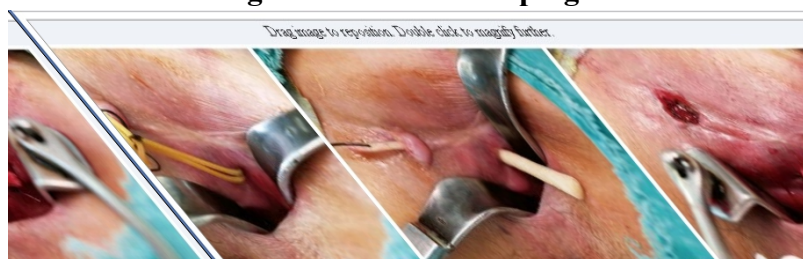


Figure 5: Steps of anal fistula plug placement

LIFT procedure: Figure 6

Is a novel modified approach through intersphincteric plane for the treatment of fistula in ano known as a LIFT (ligation of intersphincteric fistula tract) procedure. LIFT procedure is based on secure closure of the internal opening and removal of infected cryptoglandular tissue through the intersphincteric approach. LIFT procedure was first described by Rojanasakul³⁴ in 2007. His group initially reported a 94% success rate with no impact on continence. The procedure is a sphincter sparing technique and relatively simple operation. The first step in this procedure is to identify the intersphincteric space. Once the skin is incised in this area, a combination of blunt and sharp dissection is done to identify the fistula tract – a task made easier if a draining seton has been left in place for at least 6 weeks. Once the tract is identified, it is ligated on both sides and divided and the rest of intersphincteric tract is excised. The dissection is kept close to the external sphincter to avoid cutting through the internal sphincter and breaching the anal mucosa. Secure ligation of the intersphincteric tract abutting the internal opening is the key to the success. After removal of the correct fistulous tract has been confirmed, infected granulation tissues in the rest of the tract and cavity are thoroughly removed with curettage.

The open defect at the external anal sphincter is sutured through the intersphincteric wound. This technique prevents the entry of fecal material into the fistula tract and eliminates the formation of a septic nidus in the intersphincteric space to allow healing of anal fistula. Finally the incision wound is closed loosely.

The advantages of the LIFT procedure include preservation of anal sphincter, minimal tissue injury, and short healing time, easy to perform procedure, low cost and even if it does not work, other approaches can still be utilized. The long-term success rate of this technique remains to be determined. The first reports of preliminary healing results from the procedure were promising in five case series. Shanwani et al³⁵ reported primary healing rate of 82.2%. Blieler et al³⁶ reported a successful fistula closure was achieved in 57% of the 35 patients.

The LIFT procedure for a high transsphincteric or suprasphincteric fistulae is technically difficult. Apart from the difficulty in the LIFT procedure for a high transsphincteric or a suprasphincteric approach seems to require more advanced technical skills than the removal of the intersphincteric tract and infected granulation tissue in a conventional technique does³⁷.

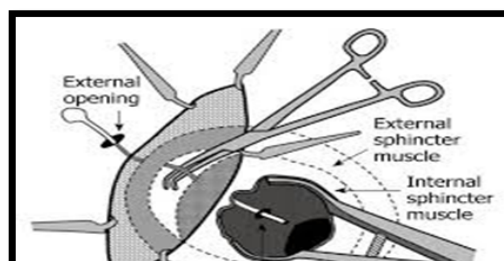


Figure 6: Fistula in ano, LIFT procedure.

BioLIFT Procedure

A modification of LIFT procedure has been described recently, after the fistula tract is identified and divided; a biological mesh is placed in the intersphincteric space to reinforce the closure of the fistula tract³⁷. This bioprosthesis acts as a physical barrier in the intersphincteric tract and closure of the fistula opening in the internal sphincter. The procedure includes a significant dissection of large portion of the intersphincteric space up to the level of the levator ani muscle. The BioLIFT technique when compared with LIFT procedure has two potential disadvantages. First, it requires a more extensive dissection in the intersphincteric plane because the biological graft must overlap the closure of the fistula tract by at least 1 to 2 cm in all directions. The second disadvantages are the high cost of the bioprosthesis mesh. Neal Ellis³⁸ reported a success rate of 94% in 31 patients treated with BioLIFT technique.

Expanded Adipose-Derived Stem Cells (ASCs)

Mesenchymal adult stem cell extracted from certain tissues, such as adipose tissue, can differentiate into various types of cells. Stem cells from the fat are being investigated as possible treatment for perianal fistulae especially those associated with Crohns disease. Administration of expanded adipose derived stem cells (20-60 millions cells) in combination with fibrin glue is an effective and safe treatment for complex perianal fistulae⁴⁰. The choice of adipose

tissue as a source of stem cells because of their two biological properties: their ability to suppress inflammation and their differentiation potential. In addition to that, enough fat can be obtained with liposuction, and the fat cells can be harvested with minimal adverse effect on the patient. The treatment procedures are as follows: 1) the fistula tract is identified with special emphasis on the identification of the internal opening; 2) curettage of the tract especially the intersphincteric tract; 3) closure of internal opening; 4) injection of a cell suspension through a long fine needle into the tract walls; 5) sealing the tract with fibrin glue⁴⁰.

Garcia-Olmo et al⁴¹ who chose adipose tissue, showed in the phase 1 clinical trial that adipos-derived stem cells are safe for treatment of fistulae in Crohns disease, and they published a phase 2 multicenter, randomized controlled trial to further investigate the effectiveness and safety of ASCs in the treatment of complex anal fistulae compared with fibrin glue group. They reported that fistula healing was observed in 71% of 24 patients who received ASCs in addition of fibrin glue compared with 16% of 25 patients who received fibrin glue alone. The proportion of patients with healing was similar between the Crohns and the non Crohns subgroups.

The advantage of ASCs is that the treatment does not injure the anal sphincter. The main limitations of the ASCs therapy are the cost of treatment and technical difficulties of secure closure of the internal opening and complete

injection of the cell is difficult procedure and finally there are no reports yet on the long term effect of using of ASCs.

FiLAC-(Fistula-tract Laser Closure)

Is a novel technique developed using a newly invented radial emitting laser probe to destroy the fistula epithelium and to simultaneously obliterate the remaining fistula tract. The aim is to gently remove the fistula tract without having to split it, thus, the sphincter muscles are preserved and incontinence can be avoided to a very high extent. Excision of the fistula from the healthy tissue is not required. In order

to eliminate the fistula tract as gently as possible, defined energy is being emitted radially into the fistula tract by using a novel fiber connected to diode fiber. The epithelialized tissue is being destroyed in a controlled way and the fistula tract collapses. This also support and accelerates the healing process. A recent study⁴² involving 11 patients treated by FiLAC technique showed very promising results. Nine out of 11 fistulae showed primary healing (81.8%). Minor and temporary form of incontinence was observed in one patient and no complications occurred.

References

1. Bastawrous A, Cintron J. Anorectal abscess and fistula. In: Current surgical therapy, Cameron, J (Eds), Elsevier Mosby, Philadelphia 2004
2. Rizzo JA, Naig AL, Johnson EK. Anorectal abscess and fistula in ano: evidence based management. *Surg Clin North Am* 2010;90:45
3. Holzheimer RG, Siebeck M. Treatment procedures for banal fistulous cryptoglandular abscess. How to get the best results? *Eur J Med Res* 2006; 11:501-5.
4. Whiteford MH, Kikenny J, Hymen N et al. Parameters for the treatment of perianal abscess and fistula in ano (revised) *Dis Colon Rectum* 2005; 48:1337
5. Garcia-Aguilar J, Belmonte C, Wong WD et al. Anal fistula surgery. Factors associated with recurrence and incontinence. *Dis Colon Rectum* 1996; 9:723-726.
6. Jacob TJ, Perakath B, Keighly MR. Surgical intervention for anorectal fistula. *Cochrane Data base. Syst Rev* 2010;CD006319
7. Sainio P. Fistula in ano in a defined population. Incidence and epidemiological aspects. *Ann Chir Gynaecol.* 1984;73:219-224.
8. Malik AI, Nelson RI. Surgical management of anal fistulae: a systemic review. *Colorectal Dis* 2008; 10:420-430.
9. Shouler PJ, Grimley RP, Keighly MRB, Alexander William. Fistula in ano is usually easy to manage surgically. *Int J Colorectal Dis* 1986;1: 113-5.
10. Christensen A, Nilas L, Christiansen J. Treatment of transsphincteric anal fistula by seton technique. *Dis Colon Rectum* 1986; 29:454.
11. Dziki A, Bartos M. Seton treatment of anal fistula: experience with anew modification. *Eur J Surg* 1998; 164:543
12. Gurer A, Ozlem N, Gokakiin. AK et al. A novel material in seton treatment of fistula in ano. *Am J Surg* 2007; 193:794?
13. Ortiz H, Mazo J. Endoanal flap advancement repair and fistulectomy for high transsphincteric and suprasphincteric fistulae. *Br J Surg.* 2000;87:1680-1683.
14. Byrne C, Solmon M. The use of seton in fistula in ano. *Semin Colon Rectal Surg* 2009; 20:10
15. Vamkoperen PJ, Wind J, Bemelman WA et al. Long-term functional outcome and risk factors for recurrence after surgical treatment for low and high perianal fistulas of cryptoglandular origin. *Dis Colon Rectum* 2008; 51:1475-1478.
16. Zimmerman D, Briel JW, Schouton WR. Endo anal advancement flap repair for complex anorectal fistula. *Am J Surg.* 2001; 181:576-577.
17. Ozuner G, Hull TL, Cartmill J, Fazio V. Longterm analysis of the use of transanal advancement flaps for complicated anorectal fistulas. *Dis Colon Rectum* 1996; 39:10-13.
18. Miller GV, Finan PJ. Flap advancement and care fistulectomy for complex anal fistula. *Br J Surg* 1998;58: 168-173.
19. Sentovich M. Fibrin glue for all anal fistulas: long-term results. *Dis Colon Rectum.* 2003;46: 498-502.
20. Gisbertz SS, Sosef MN, Festen S, Gerhards MF. Treatment of fistula in ano with a fibrin glue. *Dig Surg.* 2005; 22:91-94.
21. Buchanan GN, Bartram CI, Philips RK, Gould SW, Halligan S, Rockall TA, Sibbon P, Cohen RG. Efficacy of fibrin sealant in the management of complex anal fistula: a prospective trial. *Dis Colon Rectum* 2003; 46:1167-2274.
22. Ellis CN, Clark S. Fibrin glue as an adjunct to flap repair of anal fistulas: a randomized controlled study. *Dis Colon Rectum.* 2006;49: 1736-1740.
23. Sentovich SM. Fibrin glue for anal fistulas: long-term results. *Dis Colon Rectum.* 2003;46: 498-502.
24. Gisbertz SS, Sosef MN, Festen S, Gerhards MF. Treatment of fistula in ano with fibrin glue. *Dig Surg.* 2005; 22:91-94.
25. Johnson EK, Gaw JU, Armstrong DN. Efficacy of anal fistula plug vs. fibrin glue in closure of anorectal fistulas. *Dis Colon Rectum.* 2006;49:371-376.
26. Lawes DA, Efron JE, Abbas M, Heppell J, Young-Fadok TM. Early experience with the bioabsorbable anal fistula plug. *World J Surg.* 2008;32:1157-1159.
27. Corman ML, Abcarian H, Baily HR, Birnbaum EH, Champagne BJ, Cintron JR, et al. The surgisis (R) AFP™ anal fistula plug: report of consensus conference. *Colorectal Dis.* 2008;10:17-20.
28. Christoforidis D, Etzioni DA, Goldberg SM, Madoff RD, Mellgren A. Treatment of complex anal fistula with the collagen fistula plug. *Dis Colon Rectum.* 2008;51:1482-1487.
29. Lenisa L, Espin-Basany E, Rusconi A, Mascheroni L, Escoll- Rufino J, Lozoya-Trujillo R, et al. Anal fistula plug is a valid alternative option for the management of complex anal fistula in the longterm. *Int J Colorctal Dis.* 2010;25:1487-1493.
30. Garg P. To determine the efficacy of anal fistula plug in the treatment of high fistula in ano: an initial experience. *Colorectal Dis.* 2009;11:588-591.
31. Champagne BJ, O Connor LM, Furgeson M, Orangio GR, Schertzer ME, Armsrong DN. Efficacy of anal fistula plug in closure of cryptoglandular fistulas: long-term follow-up. *Dis Colon Rectum* 2006;49:1817-1821.
32. Thekkinkgne BJ, Cattil DK, Botterill I, Ambrose NS, Lundby L, Sagor PM, Buntzen S, et al. Efficacy of the anal fistula plug in complex anorectal fistulae. *Colorectal Dis.* 2009;11:584-587.
33. Ky AJ, Sylla P, Steinhagen R, Steinhagen E, Khaïtov S, Ly EK. Collagen fistula plug for the treatment of anal fistulas. *Dis Colon Rectum.* 2008;51:838-843.
34. Rojanasakul A, Pattanaarun J, Sahakitrungruang C, Tantiphachiva K. Total anal sphincter saving technique for fistula in ano; the ligation of intersphincteric fistula tract. *J Med Assoc Thai.* 2007;90:581-586.
35. Shanwani A, Nor AM, Amir N. Ligation of the interfistula tract (LIFT): A sphincter saving technique for fistula in ano. *Dis Colon Rectum.* 1989;32:1039-1041.
36. Bleier JI, Moloo H, Goldberg SM. Ligation of the interfistula tract: an effective new technique for complex fistulas. *Dis Colon Rectum.* 2010;53:43-46.
37. Matos D, Lunniss PJ, Philips RK. Total sphincter conservation in high fistula in ano: results of a new approach. *Br J Surg.* 1993;80:802-804.
38. Neal Ellis C. Outcomes with the use of bioprosthetic grafts to reinforce the ligation of the intersphincteric fistula tract (BioLIFT procedure) for management of complex anal fistulas. *Dis Colon Rectum.* 2010;53:1361-1364.
39. Himpson RC, Cohen CR, Sibbon P, Philips RK. An experimentally successful new sphincter conserving treatment for anal fistula. *Dis Colon Rectum.* 2009;52:602-608.
40. Mizuno H, Zuk PA, Zhu M, Lorenz HP, Benhamin P, Hedrick MH. Myogenic differentiation by humamn processed liposiprate cells. *Plast Reconstr Surg.* 2002;109:199-209.
41. Garcia-Omló D, Herrers D, Pascual I, Pascual JA, Del-Valle E, Zorrilla J, et al. expanded adipose-derived stem cells for treatment of complex perianal fistula: a phase 2 clinical trial. *Dis Colon Rectum.* 2009;52:79-86.
42. Giamundo P, Geraci M, Tibaldi L, Valente M. Closure of fistula-in-ano with laser—FiLAC™: an effective novel for complex disease. *Colorectal Dis.* 2014; 16(2):110-115.