



Etiological and pathological investigation of astrovirus infection in broilers in Sulaymaniyah province

O.M. Khan¹, N.R. Abdul-Rahman², S.M. Hassan² and A.K. Saeed²

¹Department of Poultry Disease, Veterinary Laboratory Center, Sulaimani Veterinary Directorate, ²Department of Anatomy and Histopathology, College of Veterinary Medicine, Sulaimani University, Sulaymaniyah, Iraq

Article information

Article history:

Received December 28, 2022

Accepted March 29, 2023

Available online June 19, 2023

Keywords:

Stunting

Urate crystal

Villous atrophy

Correspondence:

S.M. Hassan

snur.amin@univsul.edu.iq

Abstract

Astrovirus infection is an enteric viral disease, which leads to economic losses in the poultry industry worldwide. This study aimed to detect Chicken Astrovirus (CAstV) infection in broiler chicks in Sulaymaniyah province. Tissue samples were collected from 100 chicks from Sulaymaniyah broiler farms between July 2021 and February 2022 and were separated into 3 groups according to their age; 1-week-old chicks, group B; (n=33), was 2 weeks old chicks, and group C; (n=34) for 3 weeks old chicks. The tissue samples (intestine, liver, and kidney) were analyzed by PCR and suspected samples were passed for the histological techniques and preparation of H&E stain. Samples in groups B and C had characteristic gross and histologic lesions, specifically, the histopathologic sections revealed atrophied hepatocytes, the presence of urate crystals in the kidneys and ureters, also villous atrophy with cryptitis and crypt abscess in the duodenum. RT-PCR for detection and amplification of the 362 bps-ORF-1b (partial) region of the virus genome revealed, that 5 of the 100 samples were positive for CAstV; group B (2 samples) and group C (3 samples), while group A was negative for CAstV. Isolated CAstV strain IQ/CAstv/suly/2022 with (ON093075) was closely related to four Iranian ones.

DOI: [10.33899/ijvs.2023.137563.2699](https://doi.org/10.33899/ijvs.2023.137563.2699), ©Authors, 2023, College of Veterinary Medicine, University of Mosul.

This is an open access article under the CC BY 4.0 license (<http://creativecommons.org/licenses/by/4.0/>).

Introduction

Avian astroviruses comprise a diverse group of viruses affecting many avian species and causing enteritis, hepatitis, and nephritis. Astroviruses are becoming crucial to public health. Despite a continuous increase in publications on astroviruses since the 1970s, when the human astrovirus (HAstV) was originally discovered, they continue to be among the least investigated of the enteric RNA viruses (1,2). Astroviruses are positive-sense single RNA viruses that are round, have a diameter of 28-30 nm, and are non-enveloped. The word astrovirus, which refers to the star-like morphology seen by electron microscopy, derives from the Greek word Astron (3). Astroviruses have been implicated in more cases of sickness in birds than in mammals. Ducklings with deadly hepatitis were first identified in 1965

(4). A different astrovirus called avian nephritis virus (ANV) was initially discovered in 1976 and was linked to kidney lesions and growth retardation in young chicks. Following sequencing of the entire viral genome, it was later reclassified from an enterovirus to an astrovirus (5). The turkey astrovirus type 1 (TAstV-1) and type 2 (TAstV-2) as well as the chicken astrovirus (CAstV) and the duck astrovirus (DAstV) type 1 (DAstV-1) and type 2 (DAstV-2) were among the six astroviruses found in avian species. The ANV has also been found in turkeys, but since that astrovirus may spread between several species, the standard for classifying them was changed to one based on the amino acid composition of the viral capsid protein (6), ducklings (7), pigeons (8), guinea fowl (9), very similar viruses to TAstV-2 have also been discovered in guinea fowl (10). The ANV, which was previously believed to be a picornavirus but was

eventually identified as the first CAstV in 2000, is one of two unique types of Astroviruses that have been discovered in chickens (5). Chicken Astrovirus (CAstV), is the second form of Astrovirus and was found in broiler chicks with runting issues (11). Several studies have found that CAstV is highly associated with young birds leading to runting and stunting syndrome (RSS), renal infection with visceral gout, and white chicks hatchery illness that has been documented in several countries throughout the world (12-15). CAstV infects chicks at the ages of 1-3 weeks old, the main clinical signs reported were diarrhea, reduced food consumption, and restlessness (16). The majority of CAstV infections detected worldwide were gastrointestinal infections in chickens. Investigations have linked CAstV to poor hatching rates, frailty, and white plumage, which was known as an unusual condition called white chicks' syndrome (17). A previous study hypothesized that CAstV created an abnormal gut environment that allowed later dysbacteriosis, an imbalance of naturally colonizing bacteria that typically occurred between days 2-4 weeks post-hatch (18). This interfered with chick performance by decreasing nutrient digestibility and destroying intestinal barrier protection (19). Clinical signs of CAstV infection are characterized by diarrhea, loss of appetite, enteritis, growth retardation, and irregular flock performance (20). Also, CAstV infection causes renal infection and visceral gout that result in 40% mortality in young broilers (12,21). Furthermore, CAstV results in a condition that leads to a reduction in hatchability between 4-68%, an increase in embryonic deaths, chicks with pale feathering, weakness, loss of body weight, reduced activity, and death during the first days of life (17). In general, viral diseases considered the most infective agent that result in massive economic loss in broiler farms particularly in young chicks (22), this has a negative influence on commercial poultry farms by slowing growth rates and chick growth in a non-uniform pattern resulting in variations of the body weights at slaughter (23,24). Several viral and bacterial disease had been investigating in Iraq, that results in great economical issue in poultry industry; Inclusion Body Hepatitis in broiler flocks in Nineveh governorate, Avian pathogenic *E. coli* in Baghdad province and avian influenza virus-H5 (25-27). Up to date there is not any published date reported astrovirus infection in broiler flocks in Iraq. Astroviruses are difficult to characterize as they are infrequently isolated or adaptable to cell culture systems (11). The main techniques for detecting astroviruses are negative staining transmission electron microscopy and molecular analyses using RT-PCR (28).

Our goal was to prove the presence of CAstV infection in broiler chicks by using conventional RT-PCR and histopathology abnormalities in the intestine, liver, and kidney of the infected chicks that confirm Astrovirus infection. Complete genome sequencing and phylogenetic analysis were done to compare this strain with other reference strains. To our knowledge, this for the first time

confirms the prevalence of the CAstV infection in Iraq. This study opens the gate for other researchers to further study of virus.

Materials and methods

Study location and samples collection

The current study was carried out between July 2021 and February 2022. One hundred suspected chick samples of three different age groups. Chicks were taken from various commercial broiler farms and hatcheries in Sulaymaniyah province at various times, where they were given standardized poultry feed and free access to fresh water. Specific nutrient requirements for optimum performance were taken into account when formulating the feed for chicks. The sample was divided into 3 groups according to their age. The groups were classified into group A; (n=33) for 1-week-old chicks, group B; (n=33), were 2 weeks old chicks, and group C; (n=34) for 3 weeks old chicks. A sensitive balance was used for measuring the actual weight of the chicks. The chicks were euthanized by cervical dislocation before being subjected to subsequent gross and macroscopic examinations. Tissue samples from the liver, intestine, and kidneys were collected from each chick and put into 2 separate containers, the first container containing 10% neutral buffered formalin (NBF) for histopathological examination placed at room temperature, the second container for molecular examination stored at -20°C. The containers were labeled with the sample number from 1-100.

Sample processing

The received organs including intestine, liver, and kidney tissue samples 0.5-1 gm were collected and merged in a five-volume of RNA/water solution in a sterile tube, then were kept at -20°C. Each tissue sample was homogenized (IKA; DI 18 DISPERSOR, speed 8000, 2400 RPM, Brazil) in phosphate-buffered saline (PBS) 10% wt/vol. The homogenates samples were clarified by centrifugation at 4°C for 2 min at 15000 rpm. For the RNA isolation, the supernatant 200µl was collected. Viral RNA was extracted using the commercial mini kit (Addprep total RNA extraction kit, Korea) according to the manufacturer's instructions.

RT-PCR

Conventional RT-PCR was used for the detection and amplification of 362 bps of ORF-1b region of the virus genome using an Addscript RT-PCR kit, and CAstV-forward 5'-GAYCARCGAATGCGRAGRTTG-3' and CAstV-reverse 5'-TCAGTGGGAAGTGG GKARTCTAC-3' primers (29,30). The RNA was reverse transcribed and amplified in a 20µl reaction using 8µl of 2.5X reaction buffer, 1 µl (10 µM) of each primer, 1 µl 20X addscript-enzyme mix, then RNA about 1-3µl volume was completed by adding diethyl pyrocarbonate-treated H₂O. At first, the PCR reaction was

set at 50°C for 30 min to reverse transcriptase RNA to cDNA, then it was followed by an initial denaturing step starting at 95°C for 10 min, followed by 35 cycles of denaturation at 95°C for 30 sec, annealing at 59°C for 30 sec, extension at 72°C for 1 min, final extension step was at 72°C for 5 min to amplify the sequence and the reaction was held at 4°C.

Gel electrophoresis

The amplicons were run on 1% agarose gels to detect the amplified bands. Electrophoresis was used to separate the PCR products in a 1% agarose gel (Sigma, UK). Agarose gel was made by combining 50 ml of TAE buffer with 0.5 g of agarose. After adding safe dye (EURx, Banino, Poland), the gel was cast onto the tray, combs were added and the gel was allowed to solidify for 20 min. Five µl PCR products were loaded into the wells. The middle well of the gel was filled with 4 µl of a 100 bp DNA ladder (Add Bio in the Republic of Korea). After 30 minutes of electrophoresis 150 volts on the gel, DNA was observed under UV light, and the image was analyzed and captured by using a gel documentation system (Uvitec, Cambridge, UK) (31).

Sequences analysis

Partial nucleotide sequences of ORF-1b gene of Chick Astrovirus strains worldwide were obtained from the GenBank. Multiple alignments of these sequences were performed by MEGA 7 with the ClustalW method (32). MEGA 7 was used to perform phylogenetic analysis with Neighbor-Joining (NJ). The bootstrap values were determined from 1000 replicates of the original data.

Histopathological examinations

Tissue samples were taken from the intestine (duodenum), liver, and kidney tissues. The specimens were fixed for at least 24 hours in 10% neutral buffered formalin before being dehydrated in a graded series of ethanol solutions. The tissues were dehydrated, then cleaned in xylene, and fixed in paraffin. In the Histopathology Lab of Anwar Shexa Medical City, Sulaymaniyah governorate, 4 µm sections were mounted on glass slides and stained with hematoxylin and eosin (H&E), the slides were inspected using an eyepiece grid under a microscope at 20-400 magnification by a pathologist who was blind to the study, the lesions were evaluated manually with a conventional light microscope (Leica, Germany) via computer-assisted image analysis software to examine slices (Am Scope™, Japan).

Results

Clinical signs

Clinical examination of chicks showed that all 100 chick samples were suffering from retarding growth or stunting with poor feathering, also there were variations in body

weight between infected and healthy chicks, especially in Group B and Group C.

Molecular analysis

The target genes specific to CAstV produced amplicons at appropriate amplicon size 362 bp ORF1b gene. The gel image of PCR products of the partial virus genome (Figure 1). The RT-PCR detection results of the three groups were presented in table 1, all samples in group A were negative for CAstV, and only five of the 100 clinical samples were positive for CAstV in groups B, and C as shown, in group B, two samples were positive out of 33 clinical samples (6%) vs. group C in which 3 chicks out of the 34 clinical samples (9%) were positive for CAstV.

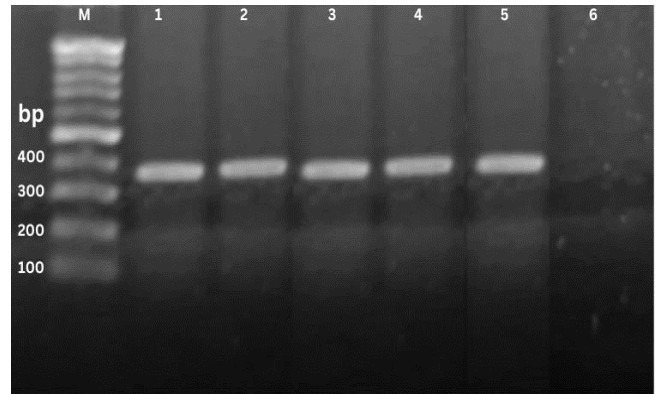


Figure 1: Agarose gel showing appropriate amplicon size of the partial ORF-1b gene (362 bp) using primer set CAstV-F and CAstV-R. Lane M: DNA marker 100 bp, lanes 1–2: (362-bp) group B, Lanes 3-5: (362-bp) group C. Lane 6 negative sample.

Table 1: Molecular analysis of CAstV-positive samples for each group of broiler chicks

Groups	Total Number	Positive Samples	Negative Samples	% positive samples
Groups A (1 week)	33	0	33	0
Group B (2 weeks)	33	2	31	6
Groups C (3 weeks)	34	3	31	9

Sequence analyses

The virus's ORF-1b region was amplified by PCR and sequenced from both directions (forward and reverse) in 25 ml (Macrogen sequencing service, Korea). Mega X software was used to align both sequences, after which they were submitted to GenBank with the accession number ON093075, under the name isolate/IQ/CAstv/suly/2022. The partial ORF-1b gene nucleotide sequences,

approximately 362 nucleotides in length of the selected strains exhibited that field-isolated viruses (IQ/CAstv/suly/2022) related to other Iranian strains. Phylogenetic comparison of the Astrovirus genomes demonstrates that individual isolates cluster based primarily on the host they corresponded to that of the Iranian CAstV strains MN871899, MN871914, MN871900, and MN871904 were closely related to the current strain's ORF1b gene sequence IQ/CAstv/suly/2022, with the highest identities 92.5-94% (Figure 2).

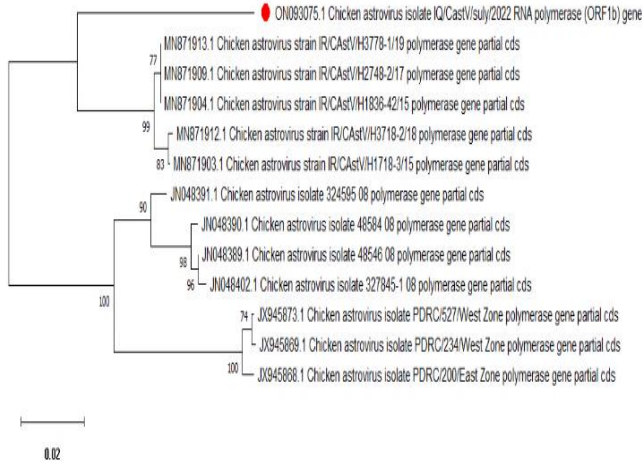


Figure 2: Phylogenetic tree relationship of CAstVs based on partial ORF-1b gene nucleotide sequences. The tree was constructed with MEGA X software using the neighbor-joining method and 1000 bootstrap replicates. The viruses that have been assigned to the genogroups have been highlighted with red cubic.

Sequence alignment

Multiple sequences of the partial ORF-1b gene of the field virus were aligned with other reference strains' amino acid residues, showing that some positions were different from all references and were replaced by new amino acids, such as the amino acid residues at position (Glutamine-Q³⁴) instead of (Arginine-R³⁴), (Tyrosine-Y⁵⁵) instead of (Aspartic acid-D⁵⁵), and the one at position (Leucine-L⁷⁶) instead of (Valine-V⁷⁶), while other positions were different from only a few references such as the amino acid residues at position (Alanine-A²⁸) instead of (Proline-P²⁸), (Aspartic acid-D⁴⁹) instead of (Glutamic acid-E⁴⁹), the amino acid residues at position (Isoleucine-I⁶⁵) instead of (Valine-V⁶⁵) as seen in (Figure 3).

Clinical and gross examination

Clinical examination of chicks showed that all 100 chick samples were suffering from retarding growth or stunting, their weight was 50-69 g, especially in group B and C vs. normal or non-infected chicks were about 164-168 g weight

at the same age. Also, the infected chicks showed pale-white poorly or abnormal feathering. At necropsy various abnormalities were detected in the visceral organs of chicks in group B and C; the most significant lesions were seen in the intestine, particularly the duodenum which showed a pale distend that was filled with liquid and gas. In some cases of chicks in group B, there was an unabsorbed yolk sac filled with green-yellowish color. The kidneys and ureter were pale and filled with urate crystal; also, there was visceral gout in some cases, particularly in group B. Additionally, the main abnormalities in the liver infected by this virus revealed pale, small necrotic foci with deposited white-chalky urate crystal on the liver capsule and surface, also within the peritoneum, particularly in group C (Figure 4).




Figure 3: Multiple sequences alignment of the amino acid sequence of partial ORF-1b region of the field isolate (isolate/IQ/CAstv/suly/2022) with other reference strains.

Histopathologic examination

Histopathological analysis showed that there were noticeable changes and the most obvious lesions of this disease were seen in the liver, intestine (duodenum), and kidney; the liver revealed cellular swelling in 40% of cases, atrophy or shrinkage of hepatocytes in 10% of cases, the remainder cases revealed necrotic changes; eosinophilic cytoplasm with small dark basophilic nuclei, in chicks for the group B vs. to those in group C in which liver sections showed congestion of the central and portal veins, dilation of a sinusoidal capillary with huge numbers of RBC and mononuclear inflammatory cells particularly; lymphocytes, plasma cells, and macrophages that were diffusely distributed through our liver parenchyma. A microscopic section of the kidney revealed chronic interstitial nephritis specifically with lymphocytes and macrophages, also interstitial hemorrhage in both groups (Figure 5).

Severe tubular degeneration was seen in most cases, localized pus exudate in interstitial tissue, in 50% of infected chickens the kidney showed deposition of colorless to

basophilic radiating, sharp, irregular, crystalline deposits that were restricted to, or surrounded by chronic inflammatory cells particularly giant cells in both groups (Figure 6).

The most common histopathologic features in the intestine were severe infiltration of mononuclear inflammatory cells particularly; lymphocytes, plasma cells, and macrophages that were diffusely distributed through all layers of the intestine (transmural inflammation), sloughing of lining epithelium with villi atrophy in both groups B and C, in few cases, there was a clubbing of villi due to infiltration of RBCs and chronic inflammatory cells, cryptitis and crypt abscess as in groups of B and C (Figure 7).

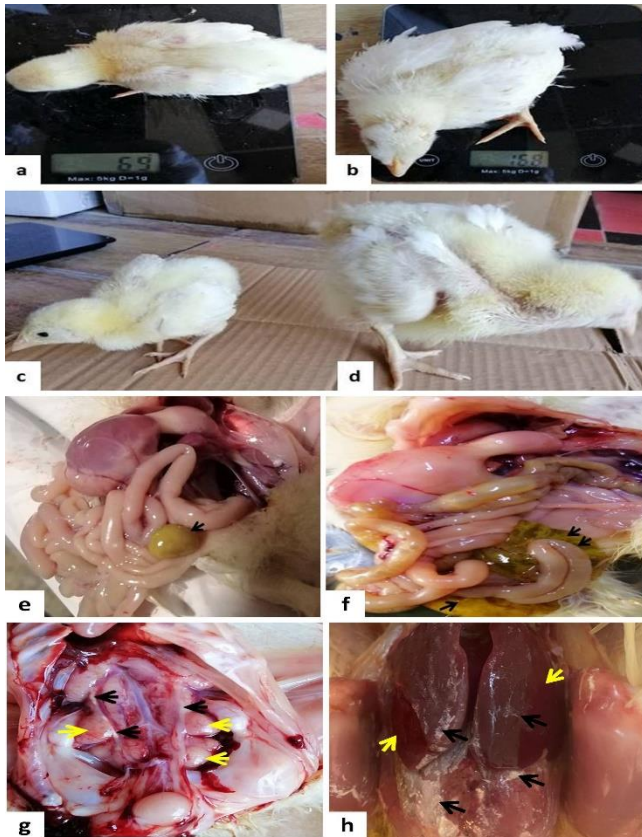


Figure 4: Variation of body weight between non-infected and infected chicks with CAstV infection; a and c: Dwarf chicks in infected chicks of groups B and C. b, and d: Normal growth rate in non-infected chicks. Gross abnormality of chick visceral organ infected with CAstV; e and f: Pale-yellowish, distended duodenum filled with liquid and unabsorbed yolk sac filled with green-yellowish colore yolk as indicated by black arrows in groups B and C. g: Enlarged, pale kidney (black arrows) and ureter that contain deposited urate (yellow arrows) in groups B and C. h: The liver revealed pale, small necrotic foci (yellow arrows) and deposited chalky urate crystal on the liver capsule and surface, also within peritoneum (black arrows) in group C.

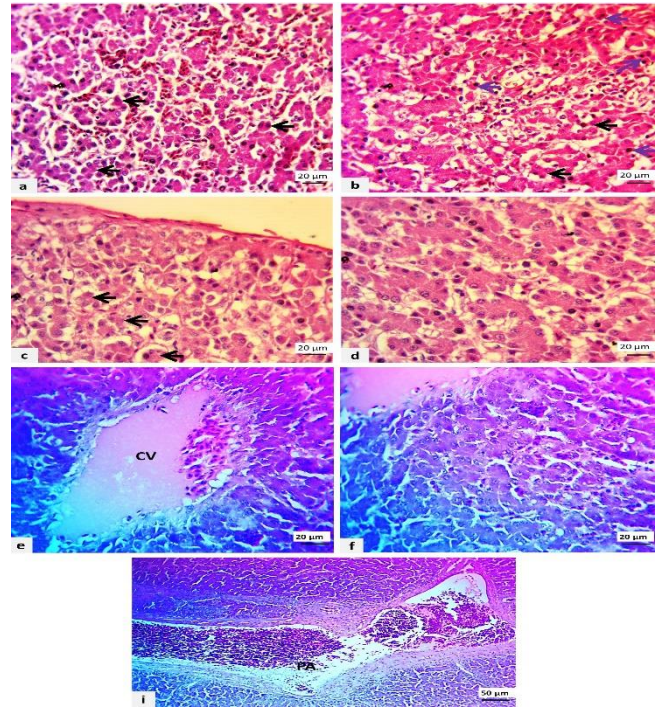


Figure 5: Microscopic section of the liver in infected chicken with Astrovirus shown; a-c: Atrophy of hepatocytes (black arrows), necrotic hepatocyte with pyknotic feature (purple arrows), and dilation of the sinusoidal capillary with RBC, d: Swollen hepatocytes with a dilated sinusoidal capillary in group B, e and f: Severe congestion of central vein (CV) with hemorrhage in centri lobular and dilation of a sinusoidal capillary with RBC and chronic inflammatory cells infiltration, swelling of unorganized hepatocytes i: Marked congestion of portal vein (PA) with periportal fibrosis in group C, (H&E stain).

Discussion

Chicken astrovirus (CAstV) is a significant issue for the poultry industry that results in high economic losses (33) because it causes adverse effects on the intestine and kidneys and hatching problems (34). Gross retardation and enteric disease are caused by many viruses' diseases like; Chicken Astrovirus (CAstV), Infectious Bronchitis Virus IBV (35), Avian Nephritis Virus (ANV), Avian Rota Virus (AvRV), Chicken Parvovirus (ChPV), Avian Reo Virus (ARV), and Fowl Adeno Virus (FAdV) (36-39), but CAstVs are the most common viruses that result in runting stunting syndrome (RSS) in broiler chicks (40). In recent years, clinical cases of CAstV infections have been documented in many countries throughout the world, resulting in massive economic losses on broiler farms. In addition, many studies have dealt with CAstV virus isolation and identification (41,42), up to date there were no studies on CAstV infection from broiler farms in Sulaymaniyah province, Iraq.

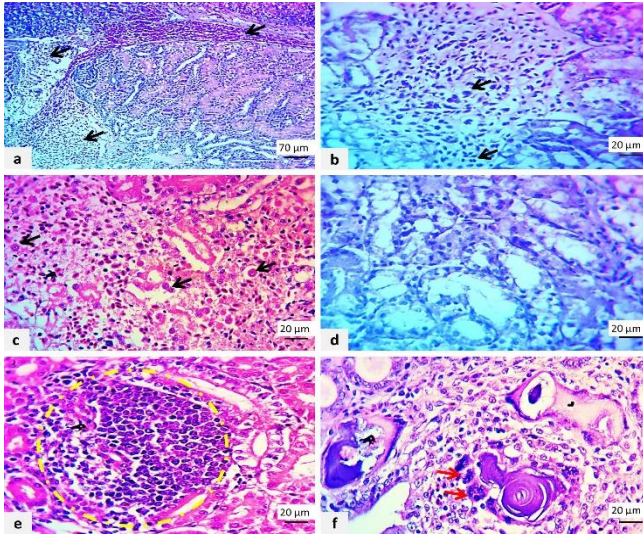


Figure 6: Microscopic section of kidney in chicken infected with Astrovirus shown; a-c: Marked inflammatory reaction in interstitial tissue with hemorrhage (black arrows) in both groups, d: Marked tubular degeneration, e: Focal suppurative inflammatory exudate in the interstitial tissue, e: Presence of urate crystal that surrounded by chronic inflammatory cells and giant cells as indicated by red arrows in both groups, (H&E stain).

In our study, the chicks were examined for CAstV infection in 3 different Groups. The CAstV strain ON093075 was isolated in group B and group C from broiler chicks that suffered from growth retardation. The group A chicks were negative for CAstV infection, which indicates that CAstV infection in group B and C chicks could be transmitted horizontally through the digestive tract, in agreement with a previous study which concluded that the presence of CAstV infection in old age chicks confirm horizontal transmission (28). Phylogenetic analysis showed the highest identity of new isolate ON093075 with four Iranian strains MN871899, MN871914, MN871900, and MN871904 belonging to cluster II based on whole genome and capsid protein and relying on partial ORF-1b sequence gene (23). This finding is an indicator that the Iranian strain is at least one of the main sources of chicken astrovirus infection in Iraq.

The ORF-1b protein is responsible for the variation in antigenicity and pathogenicity of CAstV and it is the most variable astrovirus gene, for example, some strains are associated with white hatchery disease whereas other strains result in visceral gout in addition some strains lead to RSS and growth retardation (15,17), this report similar with our result in which amino acid alignment showing many variations in amino acid residue. According to phylogenetic analysis, the CAstV strain has a close relation with four Iranian strains, which confirms the possibility of horizontal transmission of CAstV in our region because of the geographical border with Iran.

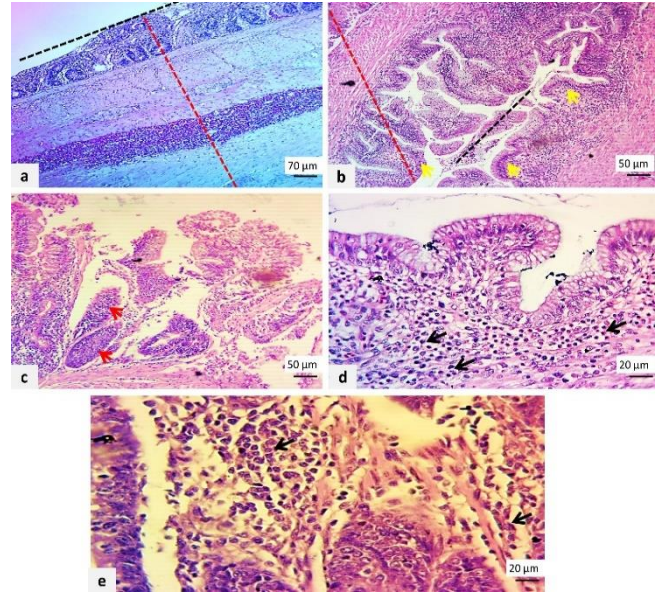


Figure 7: Microscopic section of the intestine in chicken infected with Astrovirus shown; a and b: Marked-transmural inflammatory reaction throughout intestinal layers (red dash lines) with severe sloughing of lining epithelium and atrophy of villi in section a (black dash lines), clubbing of villi due to infiltration of chronic inflammatory cells (yellow arrows) in both groups, c: Sloughing of lining epithelium with cryptitis and crypt abscess (red arrows) in both groups, d, and e: infiltration of chronic inflammatory cells as indicated by black arrows with few RBC in mucosa and submucosa in both groups, (H&E stain).

In the current study RSS, growth retardation, pale color feather, and watery diarrhea were the main clinical manifestation of all suspected cases, molecular diagnosis of these suspected samples confirm the CAstV infection. The presence of this condition was reported formerly (15,43). Also, it is responsible for histopathologic changes in several visceral organs especially the liver, kidneys, and small intestine. In our study, the liver showed pale with focal necrotic foci on its surface, the kidneys were pale and filled with urate crystal; also, there was visceral gout in some cases, and the intestine particularly the duodenum was pale, distended filled with liquid, and gas, our finding is supporting previous reports mentioned that the CAstV could infect other organs outside of the enteric system including the kidneys and liver (33). The microscopic observation of affected visceral organs showed several abnormalities; liver showing cellular swelling, atrophy of hepatocytes, congestion of the central vein, and portal vein with severe fibrosis surrounding the portal area, our data is in agreement with the previous finding reported by published studies, stated that CAstV infection results in hepatic necrosis, peribiliary inflammation, periductal, and periportal fibrosis (15,33,44).

The kidney sections in our result revealed chronic interstitial nephritis, degeneration, and interstitial hemorrhage with depositions of urate crystalline deposits that are surrounded by chronic inflammatory cells which following the results of the formerly studies confirmed interstitial nephritis with urate crystals in tubules of the kidney (12,44). In addition, the kidney showed severe tubular (collecting tubules) degeneration in most cases which supports the published study on fatal visceral gout in domestic goslings results in renal tubular necrosis as a pathological lesion (21,45). The most significant histopathologic lesions seen in the intestine there were severe inflammatory cell infiltration, sloughing of lining epithelium with villi atrophy, and cryptitis with crypt abscess which is the most microscopical lesion related to CAstV infection and confirmed by other published studies (34,43).

According to these results, chicken astrovirus causes severe damage to the most visceral organs, especially the intestine which leads to reduced feed intake and low feed conversion efficiency, which leads to growth depression (46). In our result the infected chicks in group B and group C suffered from weight loss, their weight was 50-69g which leads to considerable economic losses.

Conclusions

To our knowledge, this is the first study in Sulaymaniyah province Iraq reporting molecular characterization of a CAstV in broiler chicks, and histopathological examination of infected chick's visceral organs to confirm the abnormality induced by this virus. Therefore, this study isolated CAstV strain as one cause of growth retardation from broiler chick in Sulaymaniyah province. Phylogenetical analysis of the isolated strain based on the partial ORF-1b gene and capsid protein sequence showed that the newly isolated strain has a close relationship with 4 Iranian strains. In addition, due to the absence of CAstV infection in chick samples taken from the hatchery, we concluded that the CAstV infection in this region was transmitted horizontally.

Acknowledgments

We would like to thank the Research Center in the College of Veterinary Medicine, University of Sulaimani, Sulaymaniyah, Iraq, for the maintenance and support during the study.

Conflict of interests

All authors declare no conflict of interest.

References

1. Yokoyama CC, Loh J, Zhao G, Stappenbeck TS, Wang D, Huang HV, Virgin HW, Thackray LB . Adaptive immunity restricts replication of

- novel murine astroviruses. *J Virol.* 2012;86(22):12262-12270. DOI: [10.1128/JVI.02018-12](https://doi.org/10.1128/JVI.02018-12)
2. Marvin SA, Huerta CT, Sharp B, Freiden P, Cline TD, Schultz-Cherry S. Type I interferon response limits astrovirus replication and protects against increased barrier permeability in vitro and in vivo. *J Virol.* 2016;90(4):1988-1996. DOI: [10.1128/JVI.02367-15](https://doi.org/10.1128/JVI.02367-15)
3. Madeley C. Comparison of the features of astroviruses and caliciviruses seen in samples of feces by electron microscopy. *J Infect Dis.* 1979;139(5):519-523. DOI: [10.1093/infdis/139.5.519](https://doi.org/10.1093/infdis/139.5.519)
4. Barnes H, Guy J, Vaillancourt J. Poultry enteritis complex. *Rev Sci Tech.* 2000;19(2):565-588. DOI: [10.20506/rst.19.2.1234](https://doi.org/10.20506/rst.19.2.1234)
5. Imada T, Yamaguchi S, Mase M, Tsukamoto K, Kubo M, Morooka A. Avian nephritis virus (ANV) as a new member of the family Astroviridae and construction of infectious ANV cDNA. *J Virol.* 2000;74(18):8487-8493. DOI: [10.1128/jvi.74.18.8487-8493.2000](https://doi.org/10.1128/jvi.74.18.8487-8493.2000)
6. Domanska-Blicharz K, Seroka A, Minta Z. One-year molecular survey of astrovirus infection in turkeys in Poland. *Arch Virol.* 2011;156:1065-1072. DOI: [10.1007/s00705-011-0958-3](https://doi.org/10.1007/s00705-011-0958-3)
7. Bidin M, Lojkić I, Biđin Z, Tišljar M. Detection and characterization of avian nephritis virus in ducklings. *Avian Pathol.* 2011;40(2):173-177. DOI: [10.1080/03079457.2011.551873](https://doi.org/10.1080/03079457.2011.551873)
8. Zhao W, Zhu A, Yu Y, Yuan C, Zhu C, Yang Z, Cui L, Hua X. Complete sequence and genetic characterization of pigeon avian nephritis virus, a member of the family Astroviridae. *Arch Virol.* 2011;156(9):1559-1565. DOI: [10.1007/s00705-011-1034-8](https://doi.org/10.1007/s00705-011-1034-8)
9. Canelli E, Cordioli P, Barbieri I, Catella A, Pennelli D, Ceruti R, Moreno A, Lavazza A. Astroviruses as causative agents of poultry enteritis: Genetic characterization and longitudinal studies on field conditions. *Avian Dis.* 2012;56(1):173-182. DOI: [10.1637/9831-061311-Reg.1](https://doi.org/10.1637/9831-061311-Reg.1)
10. Cattoli G, De Battisti C, Toffan A, Salviato A. Co-circulation of distinct genetic lineages of astroviruses in turkeys and guinea fowl. *Arch Virol.* 2007;152(3):595-602. DOI: [10.1007/s00705-006-0862-4](https://doi.org/10.1007/s00705-006-0862-4)
11. Baxendale W, Mebatsion T. The isolation and characterisation of astroviruses from chickens. *Avian Pathol.* 2004;33(3):364-370. DOI: [10.1080/0307945042000220426](https://doi.org/10.1080/0307945042000220426)
12. Bulbule N, Mandakhalikar K, Kapgate S, Deshmukh V, Schat K, Chawak M. Role of chicken astrovirus as a causative agent of gout in commercial broilers in India. *Avian Pathol.* 2013;42(5):464-473. DOI: [10.1080/03079457.2013.828194](https://doi.org/10.1080/03079457.2013.828194)
13. Cloft SE, Kinstler SR, Reno KE, Sellers HS, Franca M, Ecco R, Lee MD, Maurer JJ, Wong EA. Runting stunting syndrome in broiler chickens is associated with altered intestinal stem cell morphology and gene expression. *Avian Dis.* 2022;66(1):85-94. DOI: [10.1637/21-00109](https://doi.org/10.1637/21-00109)
14. Kang KI, Icard AH, Linnemann E, Sellers HS, Mundt E. Determination of the full length sequence of a chicken astrovirus suggests a different replication mechanism. *Virus genes.* 2012;44(1):45-50. DOI: [10.1007/s11262-011-0663-z](https://doi.org/10.1007/s11262-011-0663-z)
15. Long KE, Ouckama RM, Weisz A, Brash ML, Ojkić D. White chick syndrome associated with chicken astrovirus in Ontario, Canada. *Avian Dis.* 2018;62(2):247-258. DOI: [10.1637/11802-012018-Case.1](https://doi.org/10.1637/11802-012018-Case.1)
16. Moser LA, Schultz-Cherry S. Pathogenesis of astrovirus infection. *Viral Immunol.* 2005;18(1):4-10. DOI: [10.1089/vim.2005.18.4](https://doi.org/10.1089/vim.2005.18.4)
17. Smyth V, Trudgett J, Wylie M, Jewhurst H, Conway B, Welsh M, Kaukonen E, Perko-Mäkelä P. Chicken astrovirus detected in hatchability problems associated with 'white chicks'. *Vet Rec.* 2013;173(16):403-404. DOI: [10.1136/vr.f6393](https://doi.org/10.1136/vr.f6393)
18. Xi Y, Huang Y, Li Y, Yan J, Shi Z. Fermented feed supplement relieves caecal microbiota dysbiosis and kidney injury caused by high-protein diet in the development of gosling gout. *Anim.* 2020;10(11):2139. DOI: [10.3390/ani10112139](https://doi.org/10.3390/ani10112139)
19. Teirlynck E, Gussem M, Dewulf J, Haesebrouck F, Ducatelle R, Van Immerseel F. Morphometric evaluation of dysbacteriosis in broilers. *Avian Pathol.* 2011;40:139-144. DOI: [10.1080/03079457.2010.543414](https://doi.org/10.1080/03079457.2010.543414)
20. Devaney R, Trudgett J, Trudgett A, Meharg C, Smyth V. A metagenomic comparison of endemic viruses from broiler chickens with runting-stunting syndrome and from normal birds. *Avian Pathol.* 2016;45(6):616-629. DOI: [10.1080/03079457.2016.1193123](https://doi.org/10.1080/03079457.2016.1193123)

21. Chen H, Zhang B, Yan M, Diao Y, Tang Y. First report of a novel goose astrovirus outbreak in Cherry valley ducklings in China. *Transbound Emerg Dis.* 2020;67(2):1019-1024. DOI: [10.1111/tbed.13418](https://doi.org/10.1111/tbed.13418)
22. Isa RH, Abdo JM, AL-Barzinji YM. Genotyping of avian infectious bronchitis virus in broiler farms in Duhok province, north of Iraq. *Iraqi J Vet Sci.* 2022;36(2):171-175. DOI: [10.33899/ijvs.2021.129635.1670](https://doi.org/10.33899/ijvs.2021.129635.1670)
23. Mafigholami N, Ghalyanchilangeroudi A, Hosseini H, Haghbin Nazarpak H, Morshed R. Detection and molecular characterization of chicken Astrovirus from broiler flocks in Iran: The first report. *Iran J Virol.* 2021;15(1):1-6. [available at]
24. Li L, Sun M, Zhang Y, Liao M. A review of the emerging poultry visceral gout disease linked to avian Astrovirus infection. *Int J Mol Sci.* 2022;23(18):10429. DOI: [10.3390/ijms231810429](https://doi.org/10.3390/ijms231810429)
25. Hasan MH, Abdulla SM, Ulaivi AH. Isolation and molecular detection of some virulence associated genes in avian pathogenic *E. coli*. *Iraqi J Vet Sci.* 2022; 36(4): 889-894. DOI: [10.33899/ijvs.2022.132476.2095](https://doi.org/10.33899/ijvs.2022.132476.2095)
26. Isihak FA, Ismail HK, Wahid AA .Diagnosis and histopathological study of avian influenza virus-H5 (AIV-H5) in broiler farms. *Iraqi J Vet Sci.* 2020;34(1):101-107. DOI: [10.33899/ijvs.2019.125646.1120](https://doi.org/10.33899/ijvs.2019.125646.1120)
27. Jarjees MT, Jwher DT, Alshater A. Studying an outbreak of inclusion body hepatitis in broilers in Nineveh governorate, Iraq. *Iraqi J Vet Sci.* 2022;36(3):769-774. DOI: [10.33899/ijvs.2022.131932.2024](https://doi.org/10.33899/ijvs.2022.131932.2024)
28. Adebisiyi AI, Tregaskis PL, Oluwayelu DO. Investigation of enteric viruses associated with runting and stunting in day-old chicks and older broilers in southwest Nigeria. *Front Vet Sci.* 2019;6:239. DOI: [10.3389/fvets.2019.00239](https://doi.org/10.3389/fvets.2019.00239)
29. Kaithal B, Jindal N, Kumar P, Mor S. Detection and molecular characterization of enteric viruses in enteritis-affected commercial broiler chickens in India. *Acta Virol.* 2016;60(4):361-371. DOI: [10.4149/av_2016_04_361](https://doi.org/10.4149/av_2016_04_361)
30. Michael DJ, Spackman E, Pantin-Jackwood M. A multiplex RT-PCR test for the differential identification of turkey astrovirus type 1, turkey astrovirus type 2, chicken astrovirus, avian nephritis virus, and avian rotavirus. *Avian dis.* 2007;51(3):681-684. DOI: [10.1637/0005-2086\(2007\)51\[681:AMRTFT\]2.0.CO;2](https://doi.org/10.1637/0005-2086(2007)51[681:AMRTFT]2.0.CO;2)
31. Wang T, Wang L, Zhang J. A simplified universal genomic DNA extraction protocol suitable for PCR. *Genet Mol Res.* 2011;10(1):519-525. DOI: [10.4238/vol10-1gmr1055](https://doi.org/10.4238/vol10-1gmr1055)
32. Kumar S, Stecher G, Li M, Knyaz. MEGA X: molecular evolutionary genetics analysis across computing platforms. *Mol Biol Evol.* 2018;35(6):1547-1549. DOI: [10.1093/molbev/msy096](https://doi.org/10.1093/molbev/msy096)
33. Smyth VJ. A review of the strain diversity and pathogenesis of chicken astrovirus. *Viruses.* 2017;9(2):29. DOI: [10.3390/v9020029](https://doi.org/10.3390/v9020029)
34. Kang KI, Linnemann E, Icard AH, Durairaj V. Chicken astrovirus as an aetiological agent of runting-stunting syndrome in broiler chickens. *J Gen Virol.* 2018;99(4):512-524. DOI: [10.1099/jgv.0.001025](https://doi.org/10.1099/jgv.0.001025)
35. Al-Jameel W, Al-Mahmood SS. Similarities and differences of COVID-19 and avian infectious bronchitis from molecular pathologist and poultry specialist view point. *Iraqi J Vet Sci.* 2020;34(2):223-231. DOI: [10.33899/ijvs.2020.126984.1426](https://doi.org/10.33899/ijvs.2020.126984.1426)
36. Günes A, Marek A, Graf B, Berger E, Hess M. Real-time PCR assay for universal detection and quantitation of all five species of fowl adenoviruses (FAdV-A to FAdV-E). *J Virol Methods.* 2012;183(2):147-153. DOI: [10.1016/j.jviromet.2012.04.005](https://doi.org/10.1016/j.jviromet.2012.04.005)
37. Guy JS. Virus infections of the gastrointestinal tract of poultry. *Poultry Sci.* 1998;77(8):1166-1175. DOI: [10.1093/ps/77.8.1166](https://doi.org/10.1093/ps/77.8.1166)
38. Otto PH, Ahmed MU, Hotzel H. Detection of avian rotaviruses of groups A, D, F and G in diseased chickens and turkeys from Europe and Bangladesh. *Vet Microbiol.* 2012;156(1-2):8-15. DOI: [10.1016/j.vetmic.2011.10.001](https://doi.org/10.1016/j.vetmic.2011.10.001)
39. Pantin-Jackwood MJ, Spackman E, Michael DJ. Pathogenesis of type 2 turkey astroviruses with variant capsid genes in 2-day-old specific pathogen free poults. *Avian Pathol.* 2008;37(2):193-201. DOI: [10.1080/03079450801932200](https://doi.org/10.1080/03079450801932200)
40. Roussan D, Shaheen I, Khawaldeh G, Totani W, Al-Rifai R. Simultaneous detection of astrovirus, rotavirus, reovirus and adenovirus type I in broiler chicken flocks. *Polish J Vet Sci.* 2012;15(2):337-344. DOI: [10.2478/v10181-012-0052-0](https://doi.org/10.2478/v10181-012-0052-0)
41. Xue J, Han T, Zhao Y, Yang H, Zhang G. Complete genome sequence and phylogenetic analysis of novel avastroviruses circulating in China from 2016 to 2018. *Virus Res.* 2020;278:197858. DOI: [10.1016/j.virusres.2020.197858](https://doi.org/10.1016/j.virusres.2020.197858)
42. Zhao W, Wu Z, Yao Y, Qin A, Qian K. The isolation and molecular characterization of an astrovirus from Yellow chickens, China. *Front Vet Sci.* 2020;7:581862. DOI: [10.3389/fvets.2020.581862](https://doi.org/10.3389/fvets.2020.581862)
43. Yin L, Zhou Q, Mai K, Huang J. Isolation and characterization of a novel chicken astrovirus in China. *Poultry Sci.* 2021;100(9):101363. DOI: [10.1016/j.psj.2021.101363](https://doi.org/10.1016/j.psj.2021.101363)
44. Panigrahi S, Jindal N, Kumar P. Molecular characterization of chicken astroviruses in gout-affected commercial broiler chickens in Haryana, India. *Virusdisease.* 2019;30:551-561. DOI: [10.1007/s13337-019-00554-1](https://doi.org/10.1007/s13337-019-00554-1)
45. Zhang Q, Cao Y, Wang J, Fu G. Isolation and characterization of an astrovirus causing fatal visceral gout in domestic goslings. *Emerg Microbes Infect.* 2018;7(1):1-11. DOI: [10.1038/s41426-018-0074-5](https://doi.org/10.1038/s41426-018-0074-5)
46. Jindal N, Patnayak D, Ziegler A, Lago A. Experimental reproduction of poult enteritis syndrome: Clinical findings growth response and microbiology. *Poultry Sci.* 2009;88(5):949-958. DOI: [10.3382/ps.2008-00490](https://doi.org/10.3382/ps.2008-00490)

البحث في احتمالية المسبب المرضي لإصابة أفراخ فروج اللحم بالفيروس النجمي في محافظة السليمانية

أوميد محمد حمه خان¹، نوزاد رشيد عبد الرحمن²، سنور محمد أمين حسن² و أزداد كريم سعيد²

¹فرع أمراض الدواجن، المختبر المركزي، مديرية البيطرة في السليمانية، ²فرع التشريح والأنسجة والأمراض، كلية الطب البيطري، جامعة السليمانية، السليمانية، العراق

الخلاصة

عدوى الفيروس النجمي هو مرض فيروسي معوي يؤدي إلى خسائر اقتصادية في صناعة الدواجن في جميع أنحاء العالم. هدفت هذه الدراسة إلى الكشف عن الإصابة بالفيروس النجمي في أفراخ فروج اللحم في محافظة السليمانية. جمعت عينات الأنسجة من 100 أفراخ من حقول التسمين في السليمانية ما بين تموز 2021 وشباط 2022 وتم تقسيمها إلى 3 مجموعات حسب أعمارهم. المجموعة أ بعمر أسبوع (عددها = 33 فرخ) المجموعة ب بعمر أسبوعين (عددها = 33 فرخ) والمجموعة ج بعمر ثلاثة أسابيع (عددها = 34) عينات. تم تحليل عينات الأنسجة (الأمعاء والكبد والكلية) بواسطة تفاعل البلمرة المتسلسل وتم تمرير العينات المشتبه بها لتقنيات الأنسجة وتحضيرها لصيغة الهيماتوكسيلين والايوسين. العينات في المجموعتين ب و ج كانت فيها أفات عيانية ونسجية مميزة. وبالأخص أظهرت مقاطع الأنسجة المرضية عن ضمور خلايا الكبد ووجود بلورات اليوريت في الكلية والحالب وكذلك ضمور الزغابات مع وجود التهاب وخراج جريب العفج. تم استخدام تقنية النسخ العكسي لتفاعل البلمرة المتسلسل لتضخيم جزء من جينوم الفيروس المسبب لأمراض الكلى، وجد بان 5 عينات من مجموع 100 عينة كانت موجبة للفيروس النجمي في الدجاج، عينتين منها تعود للمجموعة ب وثلاث عينات تعود للمجموعة ج، بينما كانت المجموعة أ سالبة بالنسبة للفيروس النجمي في الدجاج، كذلك أظهرت العترة المعزولة للفيروس النجمي في الدجاج والمسجلة بالرقم IQ/CastV/suIy/ON093075 بانها مرتبطة ارتباطاً وثيقاً بأربعة سلالات إيرانية.