
THREE DIMENSIONAL ANATOMICAL STUDY OF CARPAL TUNNEL (CADAVERIC STUDY)

Zuhair F. Fathallah^{*}, Majeed Al-Hamdani[@] & Thimir A. Hamdan[#]

^{*}M. Sc., Plastic Surgeon, Saddam Teaching Hospital [@]M. M.Sc. Ph.D, Department of Anatomy, University of Basrah College of Medicine [#] FRCS, Professor Orthopaedic Surgery, Department of Surgery, University of Basrah College of Medicine, Basrah; IRAQ

Summary

The right wrist of twenty cadavers were examined to measure the three dimensions of the carpal tunnel by using a Vernia (INOX), the cross sectional area and volume were then calculated for males and females separately. All were above 40 years. Males were found to have larger carpal tunnel than females of the same age group, both in cross sectional area and volume. It was found also that the volume of the tunnel change according to the age. The pattern by which the volume changes is different in males and females. In active age group i.e. fourth to sixth decade, the tunnel volume in females' collapse but it expand in males, this may explain the high incidence of carpal tunnel syndrome in females in this age group and the low number of affected males. The age / volume relation may shed some light on the etiology of the "Idiopathic" carpal tunnel syndrome.

Introduction

Carpal tunnel syndrome (CTS) is the most frequently encountered peripheral neuropathy, specially in middle age women, it was first described in 1853 by Sir James Paget¹, since that time considerable researches were done to describe different clinical aspect of the syndrome as well as to identify the different etiological and causative factors. Local and systemic causes as well as various occupational hazards were to be blamed^{2,3}.

In about half of the patients, a cause

can be identified e.g. hypothyroidism, obesity, trauma to the hand, local tumor or ganglion, etc, but In the rest of the cases no abnormality or causative agents could be pointed^{5,6}, these cases were classified as idiopathic carpal tunnel syndrome^{3,7}.

In the last quarter of the 20th century a trend begin to identify any anatomical abnormalities in size and volume of the carpal tunnel, this was facilitated by the new non-invasive techniques e.g. MRI, CT scan and Ultrasound. Many of these idiopathic cases were found to have anatomical abnormalities in the carpal bones i.e. stenosis of the carpal tunnel with the narrowing of the space available for the gliding of the nerve and tendons with their coverings as they pass

Correspondence to:

Dr. Zuhair Fathalla,
Department of Surgery, Saddam Teaching
Hospital, Basrah; IRAQ.

through the tunnel from forearm to the hand.

The narrowing or stenosis of the tunnel may be minimum and the symptoms of median nerve compression arise only later in life when degenerative changes in the walls of the tunnel compete with the median nerve for space and its function became impaired by compression of its arterial supply as ischaemic changes of its distal part may give rise to the feeling of numbness^{6,8}. Symptoms may also become clinically apparent when other causes of compression is present e.g. pregnancy with retention of fluid⁶.

The objective of this study is to determine the CSA of the proximal and distal ends and volume of the empty tunnel in males and females in vivo i.e. cadavers so as to determine the changes in CSA and volume as affected by age and sex and if these changes are of any significance, also if this volume changes is the sole cause of the syndrome, and the list of causes are only contributory factors.

Material and Methods

All the materials were obtained from the Department of Anatomy, College of Medicine and Department of Forensic Medicine, Basrah.

Examination of carpal tunnel (canal) of the right hand were done in 20 cadavers both fresh and formalin preserved, they were 10 females and 10 males. Their ages range from 44 - 81 year. All the cadavers were presumed to have normal carpal tunnel as long as their families do not give any history of wrist diseases, and there was no scar of any previous operation.

The length, height and width of the proximal and distal ends of the carpal tunnel were measured after dividing the flexor retinaculum; using the vernia (INOX) to perform these measurements.

The length of the flexor retinaculum (transverse carpal ligament) was considered as equal to the length of the bonny tunnel.

The width of the tunnel, which is the transverse (long) diameter of the tunnel, was measured at proximal and distal ends. The inside distance between scaphoid and pisiform was recorded as the proximal width and the inside distance between triquetrum and hook of hamate as the width of the distal end.

The height (Depth) of the proximal and distal ends was obtained by measuring the depth between flexor retinaculum and the bottom of the carpal arch.

The cross section profile of both tunnel ends are not circular but rather elliptical then two diameters have to be measured i.e. width and height. In circular shape these two diameters are equal, but in elliptical shape an apparent intermediate axis have to be calculated⁹. The diameter of cross section profile were obtained by converting these elliptical profile measurements to those of circles using the equation:

$$D = 2 \sqrt{L/2 \times S/2}$$

$$D = \sqrt{LS}$$

Were D is the new diameter of cross-section profile and L and S are the long and short axis measurements.

In this way circles of known diameter¹⁰ could represent all cross section profile both circular and elliptical.

Then it is possible from D to measure the CSA as:

$$CSA = (D/2)^2 \times \pi$$

With the availability of the mean length for males and females, the volume for both sexes can be obtained as follows:

$$\text{Volume} = \text{mean CSA} \times \text{length}$$

Were mean CSA = Proximal CSA / 2 + Distal CSA / 2.

This volume represent the empty space through which the contents with their coverings are gliding, and it is the potential space for the expansion of the

contents by e.g. synovitis or edema without exerting pressure on the median nerve.

Statistical analysis

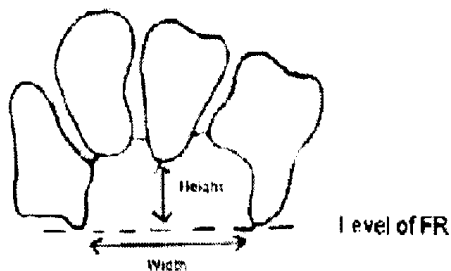
Data were analyzed statistically using student "t" test of significance and "P" value. The tests of significance were done between males & females values. Females' samples were divided into below 40 years & above 40 years to match males' samples whom were all above 40 years. All the results were plotted into curves and tables.

Results

Age; in 10 males, the range of age was 44 - 78 years, while in 10 females the age range from 20 -81 years.

The mean tunnel length was 28.4 ± 3.3 mm in males (Table I), and 26.2 ± 1.5 mm in females below 40 years (Table II), there is a difference in length of 2.2 mm between the sexes which is not significant ($P > 0.05$).

The width of the tunnel was measured at proximal (inlet) and distal (outlet) ends (tables 1, 2 & 3). At the proximal end the mean width was 17.5 ± 2 mm in males and 16.9 ± 2.4 mm in females the difference is not significant ($P > 0.5$). At the distal end, the measurement in males is 15.3 ± 2.2 mm and in females it is 14.7 ± 2.1 mm, again there is no significant difference between the two means ($P > 0.5$). In comparing the width



of proximal and distal area in both sexes, it was found that in males there is a difference of 2.2 mm which is significant ($P < 0.05$). In females again

the difference is 2.2 mm which is also significant ($P < 0.01$).

The mean height in (Table I & II), proximal ends of the males is 10.7 ± 3.3 mm while in females it is 9.9 ± 2.9 mm the difference is not significant ($P > 0.5$). In the distal end the mean height in males is 13.1 ± 2.1 mm while in females it is 12.5 ± 2.3 mm the difference is not significant as well ($P > 0.5$). The difference in height between the proximal and distal ends in males is not significant ($P > 0.05$), but still that means distal end is higher than the proximal by 2.4 mm. In females, the distal end is significantly higher than the proximal end by 2.6-mm ($P < 0.05$).

From the measurement of width and height, it is clearly shown that the profile of the proximal end are elliptical in shape while distal end profile is more or less circular in shape.

The mean C.S.A. of the proximal end in males is 151.2 ± 62.3 mm², while in females it is 135.6 ± 60 mm² (table 1 & 2), this demonstrate that the mean tunnel inlet CSA is smaller in females than males but the difference is not significant ($P > 0.5$). In distal end, the CSA again is smaller in females and equal to 145.8 ± 49.3 mm² as shown in Table II, compared to male value of 160.4 ± 46.8 mm² as shown in (Table 1), which show that males have larger CSA of the outlet but it is also not significant ($P > 0.5$). In correlating these findings in both males and females the distal end is larger by 9.2 and 10.2 mm² respectively than proximal end, that makes the tunnel cone in shape with its base looking distally, the differences between the two ends are not significant ($P > 0.5$) both in males and females.

The volume of the carpal tunnel (Table I and II) was calculated from the mean of the CSA of both proximal and distal ends multiplied by the length of the tunnel of the same specimen measured directly from the cadavers. The mean volume of the tunnel in males is 4.6 ± 2

Specimen No.	Age	Length mm	Prox. width mm	Prox. Height mm	Prox. CSA mm ²	Distal width mm	Distal height mm	Distal CSA mm ²	Volume mm ³	Volume cm ³
1	44	29	18	11	155.5	14	13	142.9	4326.8	4.3
2	45	26	16	11	138.2	17	15	200.3	4400.5	4.4
3	46	28	18	12	169.6	16	13	163.4	4662	4.7
4	48	29	18	12	169.6	16	14	175.9	5009.8	5
5	54	34	20	16	251.3	18	16	226.2	8117.5	8.1
6	55	33	21	15	247.4	18	16	226.2	7814.4	7.8
7	69	23	15	6	70.7	12	10	94.2	1896.4	1.9
8	71	27	15	7	82.5	12	11	103.7	2513.7	2.5
9	74	26	17	10	133.5	15	11	129.6	3420.3	3.4
10	78	29	17	7	93.5	15	12	141.4	3406.1	3.4

Table I. Measurements of carpal tunnel in Males

Specimen No.	Age	Length mm	Prox. width mm	Prox. height mm	Prox. CSA mm ²	Distal width mm	Distal height mm	Distal CSA mm ²	Volume mm ³	Volume cm ³
1	47	27	18	10	141.4	18	16	226.2	4962.6	5
2	49	27	17	9	120.2	15	12	141.4	3531.6	3.5
3	58	25	16	8	100.5	13	10	102.1	2532.5	2.5
4	60	24	15	7	82.5	12	11	102.7	2234.4	2.2
5	68	27	16	12	150.8	13	11	112.3	3551.9	3.6
6	69	29	16	8	100.5	12	10	94.2	2823.2	2.8
7	76	26	21	13	214.4	17	15	200.3	5391.1	5.4
8	77	27	21	16	263.9	17	16	213.6	6446.3	6.4
9	80	25	14	8	88	14	12	131.9	2748.8	2.7
10	81	25	15	8	94.2	14	12	131.9	2826.3	2.8

Table II. Measurements of carpal tunnel in Females.

cm³ (Table I), while in females the volume is 3.7 ± 1.4 cm³ (Table II). There is a difference of 0.9 cm³ between sexes, which is not significant (P>0.5) that still leaves the males with larger carpal tunnel volume.

The age and sex relations to tunnel volume are shown in fig.1 and 2. The pattern in females is large volume at the age of 40 year, then the tunnel capacity decrease steadily till the age of about 70 year, the volume then starts to increase again. The age between 40-60 years is the age of maximum incidence of carpal tunnel syndrome. In males, the picture is different; the volume is steady till the 4th decade then it starts to increase till late

50s followed by a decrease in size below the values of the 40s. Figure 3, show both females and males data blotted together, it show that during the active period of life males are less susceptible to carpal tunnel compression than females, this goes well with the clinical observation of higher incidence in females i.e. 80% of affected females are over 40 years¹¹, that can be explained partially by small tunnel volume and partially by increase bulk of the contents during diseases or illnesses as rheumatoid arthritis, myxoedema or pregnancy, results in median nerve compression and ischaemia.

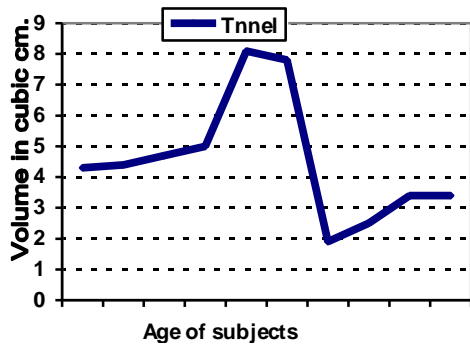


Fig 1. Volume of carpal tunnel in relation to age in male.

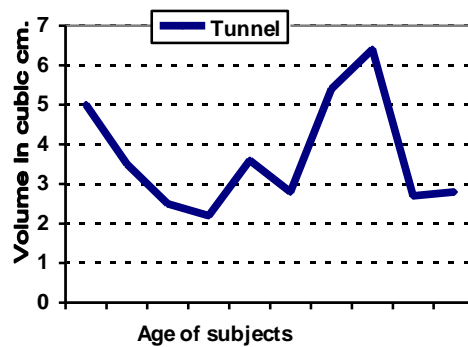


Fig 2. Volume of carpal tunnel in relation to age in female

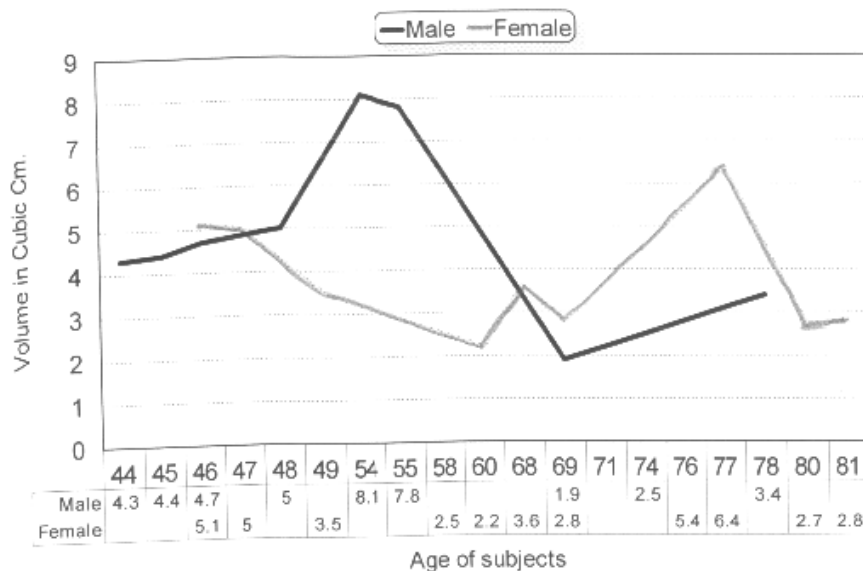


Fig.3 : Volumes of carpal tunnel in males and females in relation to age.

Discussion

In reviewing the literatures of the last three decades, it appears that the Vernia has been used for the first time in such study to measure the three dimensions of the carpal tunnel.

The length of the carpal tunnel was measure directly from the cadavers (Table I and II). Although there are differences in the means between sexes but they are not significant, which can be attributed to the differences in the hand size between men and women in general. Pierre¹², using the MRI found that the mean length of the tunnel in women (in general) was 36.3 ± 3.4 which is 10.1 mm more than the female figures for the carpal tunnel length in this series, but if Pierre figures are corrected by the correction index for the tunnel (which is 0.8161) advocated by Cobb et al and Richman et al^{13,14}, then the differences between this work and Pierre results will be slight (3mm). Kunou et al¹⁵ also found that there is no significant difference between male and female in length of the carpal tunnel, which is a similar result as this work.

The width of the proximal and distal ends showed little differences between sexes (table 1 & 2), male have wider canal in proximal and distal end, which is 0.6 and 0.7 mm respectively, but it is not significant. There is a large significant difference between inlet and outlet in both males and females i.e. proximal end of the carpal tunnel is wider than the distal end, which is in agreement with the finding of Takechi and his group¹⁶, they found that the proximal end is wider than the distal end but they did not mention any age or sex differences they also found that the width in the inlet is 35 mm which is nearly double the overall figure of this series (17.75 mm mean of combined reading of males and

females), the reason behind this large difference is that Takechi and co-workers used the carpal eminence's as a measuring point while in this series the measurements were done by the vernia directly from the inside of the carpal tunnel, there is as well an element of magnification in radiological films¹⁷, used by Takechi and his workers. All these account for the differences in the two figures. Not all workers accept no sex differences in the tunnel width, Kunou and co-worker¹⁵ found that the width is different between male and female being narrow in females as our finding in this work. Females' carpal tunnel is narrower at both ends but not significant.

The height of the tunnel at the proximal end and at the distal end. In this work the height of the tunnel was measured carefully because it is of importance in calculating the CSA exactly and to have an idea about the shape of the proximal and distal ends cross section. Slight differences were found in the height between sexes with the males' tunnel slightly but not significantly higher than females at both ends (0.8 and 0.6 mm). The differences between height of the proximal and distal ends were found to be significant with the distal end is higher than the proximal.

As a result of having an elliptical shape inlet, the carpal contents as they pass through this elliptical proximal end will spread transversely making them less liable to compress on each other during wrist movement in flexion and extension as the proximal end is at the most mobile part of the wrist (carpo-radial joint). In distal end which is circular the contents are crowded in a circular manner which make them more liable for compression if the distal end is as freely mobile as the proximal end, but the line of movements of flexion and extension is not passing

through the carpo-metacarpal joint i.e. distal carpal tunnel end¹⁸.

The CSA of the proximal and the distal ends of the carpal tunnel show some differences regarding the sex and age (Table I and II). At the proximal end the difference between males and females is not significant also at the distal end, the males have larger overall CSA but it is not significant, that still leaves the males with larger overall CSA of the carpal tunnel.

Regarding the differences in CSA between proximal and distal ends, in males the proximal end is smaller than distal end but it is not significant, the shape of the tunnel from these measurements is conical with its base looking distally. In females the proximal end is smaller than the distal end also it's not significant, tunnel shape is conical as well with its base looking distally. Dekel et al⁶ also found that females have smaller CSA than males in both proximal and distal ends, their measurements were done by the CT scan, their figures were larger as compared with this work which is partially due to the magnification in the CT scan. Another work was done by Bleecker¹⁹ who examined CSA in 7 normal males again by the CT scan, he found that their CSA were $2.53 \pm 0.15 \text{ cm}^2$ which is larger than this work value in males but there is also an element of magnification in the CT scan film^{17,20} Pierre et al¹² found that the inlet is larger than the outlet, all their cases were normal females examined by MRI their finding is opposite to this work finding. Skie et al²¹ measure the CSA at the hook of hammat level (distal end) and found similar CSA figures as this work during neutral position of the wrist (CSA = 1.52 cm^2) they also found that the CSA is more during extension and less during flexion. Ham et al²² similarly measured the CSA at hook of hammat and found that the CSA with the fingers in flexion and extension positions are $191 \pm 26 \text{ mm}^2$ and $169 \pm 15 \text{ mm}^2$

respectively which mean that the neutral position is some where in between i.e. 180 mm^2 which is larger than this work figures (MRI magnification). In both groups the findings of large CSA in extension of the wrist and flexion of fingers fits with the clinical observation of relief of symptom during wrist extension²³

The volume of the carpal tunnel was calculated as the mean of the volumes (table 1 & 2) a difference of 0.9 cm^3 between males and females but its not a significant one. Richmann et al¹³ Measured the tunnel capacity directly by silicon mold and by MRI and found that the mold volume is $4.73 \pm 1.01 \text{ ml}$ while by MRI it is $5.84 \pm 1.24 \text{ ml}$ which is 4.77 ml when corrected¹⁴, the corrected figures are near to this work figures.

The relations between age, sex and volume of the carpal tunnel are studied (figures 1 and 2). In females, there is a change in tunnel capacity according to the age, large tunnel volume was noticed at the two extremes of age and small volume during the fourth to sixth decades which is the period recognized clinically as the period of high risk for carpal tunnel syndrome⁸. In males the shape of the curve is different, there is a steady curve at fourth decade then increase in volume capacity of the tunnel till late sixties followed by drop in size, this explain the low incidence of the syndrome in males during the active period of life. During this period females have small tunnel volume while males have large tunnel volume that explain the overall incidence of median nerve compression M: F = 1: 4 Ferry et al¹² suggest some hormonal factors in females which may contribute to the high number of female cases, small tunnel will not cause the compression of the nerve alone this is true in non idiopathic cases as there should be a pathology precipitating the compression. In idiopathic cases, it is the decrease of the tunnel volume, which may lead to

the symptoms. Manarguez³ found that 84% of the cases of compression were bilateral which suggest inherited abnormalities. Pierre et al¹² agreed that the anatomy of the tunnel do change by age but they found that women over 45 have larger tunnel than younger women this is not our finding. Dekel et al⁶ rejected the idea of any relation between age and size of the tunnel. It was also rejected by Winn et al²⁵ who stated that small carpal canal area does not appear to be a risk factor in carpal tunnel syndrome but from this work it is clear that the size and structure of the tunnel are changed according to age and sex which partially explained the high incidence of compression of the median nerve in females during the active period of life.

Conclusions

- (1) The proximal end of the carpal

tunnel is smaller than the distal end and its contents are more bulky, so the chance of getting compression of the nerve at proximal end is higher than the distal end and hence the importance of good decompression in proximal end.

(2) There is a difference in the measurements of carpal tunnel between males and females.

(3) CSA & volume of the carpal tunnel differs according to age and sex.

(4) Idiopathic causes of median nerve compression are merely a manifestation of volume changes in different age groups.

(5) The non-idiopathic type is due to increase in the volume of the contents within the tunnel by the presence of pathology, which overcome the available expansion space.

References

1. Sinner RJ, Bochman JW, Amadio PC. The many faces of carpal tunnel syndrome, *Mayo Clinic Proc.* 1989; 64: 829-836.
2. Hays CW. Compression neuropathies in the upper limb. In: Grabb & Smith, *Plastic Surgery* 5th edition 1997, Lippincott - Raven Publishers, Philadelphia New York. PP 917.
3. Manarguez Puche JF, Luna Rodriguez C, Alcantara PA, Micol Torres C, Martinez N, Ferrá Minarro I. Carpal tunnel syndrome in primary care. Impact of work place risk. *Aten Primaria.* 1996 Feb.29; 17(3): 187-192.
4. Bottinelli O, Campani R, Bozzini A, La-Fianza A, Calliada F. Echographic assessment of the hand: Normal anatomy and pathological pattern. *Radio Med Torino* 1993; 85 (5 suppl 1): 227-236.
5. Gelmer HJ. Primary carpal tunnel stenosis as a cause of entrapment of the median nerve. *Acta Neurochir Wien* 1981; 55(3-4): 317-320.
6. Dekel S, Papaioannou I, Rushworth G, Coates R. Idiopathic carpal tunnel syndrome caused by carpal stenosis. *Br Med J* 1980 31; 280 (6227): 1297 – 1299.
7. Nakamichi K, Tachibana S. The use of ultrasonography in detection of synovitis in carpal tunnel syndrome. *J Hand Surg Br* 1993; 18 (2): 176-179.
8. Razemon JP. The carpal tunnel syndrome. *J Chir Paris* 1982; 119 (4): 283-294.
9. Humphries DW. Mensuration methods in optical microscopy. In: *Advances in optical and electron microscopy*. Bares R and Cosslett VE. eds. Vol.3, 1969, Academic press London and New York. Pp3398. (Cited from Ref. 19)
10. Al-Hamdani M. An ultra-structure and stereological study of lymphocyte blast transformation in vivo & in vitro. Ph.D. Thesis, Sheffield University 1977, p. 163.
11. Peimer CA. Surgery of the Hand. In: Schwartz, Shires & Spencer. *Principle of Surgery*. 7th edition, McGraw-Hill Book Company, 1999 PP 2023.
12. Pierre Jerome C, Bekkelund SI, Nordstrome R “Quantitative MRI analysis of anatomic dimensions of the carpal tunnel in women”

- Surg Radiol Anat 1997; 19 (1): 31-34.
13. Richman JA, Gilberman RH, Rydevik RL, Gylys-Morin VM, Hajek PC, Sartoris DJ. Carpal tunnel volume determination by magnetic resonance imaging. *J Hand Surg Am* 1987; 12 (5pt.1): 712-717.
14. Cobb TK, Dalley BK, Posteraro RH, Lewis RC. Establishment of carpal content / canal ratio by means of magnetic resonance imaging. *J Hand Surg Am* 1992; 17 (5): 843-849.
15. Kunon M. An anatomical study of the carpal tunnel for endoscopic carpal tunnel releases. *Nippon. Sakergeka. Gakkai. Zasshi.* 1994; 68 (10): 878-884.
16. Takechi H, & Kono M. The osseous structure of the carpal groove. *Anat Clin* 1983; 5(3): 153 – 157.
17. Johns HE, Cunningham JR. *The physics of Radiology.* 3rd edition 1978, Charles C Thomas Publisher, Illinois, USA.
18. Kaver JMG, Landsmeer JMF. Functional anatomy of the wrist. In: Tubiana R “The hand” Volume 1, WBS Saunders Co., London 1981. PP 142.
19. Bleecker M, Bohlman M, Moreland R, Tipton A. Carpal tunnel syndrome: role of carpal canal size. *Neurology* 1985; 35 (11): 1599-1604.
20. Moyle JTB. Serial Radiology. In: Hill DR. *Principles of Diagnostic X-ray Apparatus.* Philips Technical Library 1979, The MacMillan Press Ltd. London
21. Skie M, Zeiss J, Ebraheim NA, Jakson WT. Carpal tunnel changes & median nerve compression during wrist flexion and extension seen by magnetic resonance imaging. *J Hand Surg Am* 1990; 15 (6): 934-939.
22. Ham SJ, Kolkman WF, Heeres J, Den-Boer JA. Changes in carpal tunnel due to action of the flexor tendons: Visualization with magnetic resonance imaging. *J Hand Surg Am* 1995; 21 A (6): 997-1003.
23. Weiss AP, Akelman E. Carpal tunnel syndrome: a review. *R. I. Med.* 1992 Jun; 75 (6): 303 – 306.
24. Ferris BD, Stanton J, Zamora J. Kinematic of the wrist, evidence for types of movement. *J. Bone. Joint. Surg. Br.* 2000; 2-B: 242 – 245.
25. Winn FJ. Jr. Habes DJ. Carpal tunnel area as a risk factor for carpal tunnel syndrome. *Muscle & Nerve* 1990 Mar; 13 (3): 254-258.