



The protective effect of bosentan on methotrexate-induced oral mucositis in rats

R.Kh. Attarbashee¹ , J.Kh. Mammdoh¹  and S.Gh. Al-Kazzaz² 

¹Department of Dental Basic Sciences, ²Department of Oral and Maxillofacial Surgery, College of Dentistry, University of Mosul, Mosul, Iraq

Article information

Article history:

Received October 23, 2022

Accepted March 29, 2023

Available online June 10, 2023

Keywords:

Bosentan
Methotrexate
ICAM

Correspondence:

J.Kh. Mammdoh

jawnaakhalid@uomosul.edu.iq

Abstract

This study aimed to evaluate the effectiveness of bosentan as a protective agent on the rat's cheek mucosa for Methotrexate-induced oral mucositis. Twenty-four Wister-albino rats, about 12-16 weeks and weighing 300-400 g, were used. The animals were divided into three groups. In the first control group, the second group was treated with methotrexate (80 mg/kg), and the third group was treated with methotrexate and bosentan 60 mg/kg. The microscopical parameters were estimated, the pro-inflammatory marker (TNF- α) and intercellular adhesive molecule-1(ICAM-1) measurement in the buccal mucosa. The animals were sacrificed on day 15, and the buccal mucosa was dissected for histological and immunohistochemical analysis. Bosentan decreased the severity of the Methotrexate-induced oral mucositis by a significant decrease in the histological score and a significant decrease in TNF- α and ICAM-1 immune histochemical expression at day fifteen. Bosentan at a concentration of 60 mg/kg/day produced protection against Methotrexate-induced oral mucositis by its anti-inflammatory action and reduction in the histological score and, therefore, can be used as a protective agent against Methotrexate-induced oral mucositis.

DOI: [10.33899/ijvs.2023.135827.2536](https://doi.org/10.33899/ijvs.2023.135827.2536), ©Authors, 2023, College of Veterinary Medicine, University of Mosul.

This is an open access article under the CC BY 4.0 license (<http://creativecommons.org/licenses/by/4.0/>).

Introduction

Oral mucositis is an inherent complication of cancer therapy for many patients and plays a significant role in the physical and psychosocial aspects of patients undergoing cancer therapy. It is a larger problem than is currently recognized and represents a therapeutic challenge frequently encountered in cancer patients because of a significant number of patients affected by this side effect. The drugs used in chemotherapy, like Methotrexate, destroy rapidly dividing cells in the body, like the gastrointestinal epithelium and buccal epithelium (1,2). Methotrexate, the rival of folic acid, is one of the remedies for tumor treatment (3,4). Oral mucositis affects the quality of life and nutritional state of the patient, who may require hospitalization, thus increasing health care costs (5). Mucositis reportedly consists of steps beginning with the formation of reactive oxygen species

(ROS), progressing with the release of pro-inflammatory cytokines, such as tumor necrosis factor (TNF- α) and interleukin-1 beta (IL-1 β), resulting in mucosal damage, infection, and cell death (6). Oral mucositis causes either discontinuation or reduced chemotherapy dose (7,8). Therefore, numerous studies have been conducted about protection against mucositis, but there are no specific medications in clinical practice for the treatment of mucositis. Bosentan is a mixed endothelin receptor antagonist recognized as the first orally bioavailable endothelin receptor antagonist approved by the Food and Drug Administration for treating patients with pulmonary arterial hypertension (9,10). Pre-clinical studies have suggested the potential of using bosentan to treat a wide range of inflammatory diseases, including arthritis (11), cancer (12), uveitis (13), and depression (14). Thus, bosentan has been a crucial tool in investigating endothelin-1 roles in

disease and the perspective of targeting endothelin-1 to treat diseases.

To date, the anti-inflammatory activities of bosentan against methotrexate-induced oral mucositis have not been investigated. Therefore, this investigation was designed to evaluate the preventive effect of bosentan against methotrexate-induced oral mucositis.

Materials and methods

Ethical approve

The study protocol was approved by the institutional animal ethics committee from Al-Mosul university in the college of dentistry (UoM.Dent/A.L.14/22).

Experimental rats

Prior to the experiment, adult albino male rats that are weighing 300-400g were domiciled in four per cages for 7 days. The animals were raised in a laboratory affiliated with the College of Dentistry and were subjected to standard conditions of temperature, humidity, and light, in addition to being them with water and the necessary food throughout the research period.

Drugs

Remedy Methotrexate was provided by Ebewe company at 2.5 mg/ml, and bosentan from Cipla company volume of dose admiration was 2ml/kg

Experimental pattern

This study was conducted on 24 adult male rats. The rats were divided into three groups (n= 8/group). I received distal water and served as a control, while the other group II was exposed to the methotrexate induction at 80 mg/kg intraperitoneally. Group III was administered bosentan 60mg/kg orally, seven days before and after the induction by 80 mg/kg of Methotrexate.

Preparation of drugs

On the day of the experiment, the Methotrexate and bosentan were freshly prepared before administration. Estimated drugs were prepared as suspensions in distilled water. The dose of bosentan 60 mg/kg was determined based on a previous study (15). Methotrexate (80 mg/kg) was used as chemotherapeutic-induced oral mucositis (16).

Drug-induced oral mucositis model

All the experimental rats were kept in the animal house for 7 days without any treatment to adapt to the environmental conditions. Oral mucositis was induced by the Intraperitoneal administration of the chemotherapeutic agent methotrexate at 80 mg/kg (16). The third group was given bosentan seven days before methotrexate treatment and was continued for 7 days after induction (totaling 15 days of treatment) with a dose of 60 mg/kg (17). After the

experiment ended, the animals were anesthetized with ketamine 50 mg/kg and xylazine 5 mg/kg in the different syringes, and their buccal mucosa was removed for histological and immunohistochemical studies.

Histological evaluations

Formalin 10% was used to fix the mucosa samples, then the sample was dehydrated, embedded in paraffin, deparaffinized with xylene, cut into 4 µm sections, and stained by hematoxylin and eosin (H&E). Slides were examined and scored to evaluate the histopathological changes. During the evaluation, the slides were coded to prevent observer bias (18-21). All tissue sections were examined in a blinded fashion by an experienced histopathologist. The classification was made following previous studies (22) as follows: 1 = epithelial and connective tissue without vasodilatation, absence or low cellular infiltration, absence of edema, ulceration, and abscess; 2 = scattered vasodilatation, areas of reepithelization, diffuse cell infiltration with multiple mononuclear leukocytes, and absence of bleeding, edema, ulcers, and abscesses; 3 = moderate vasodilatation, hydropic epithelial degeneration (vacuolization), moderate cell infiltration dominated by polymorph nuclear leukocytes, the presence of hemorrhagic areas, edema and rarely small ulcers but the absence of abscesses; 4 = marked vasodilation, cell infiltration with multiple polymorph nuclear leukocytes, presence of hemorrhagic sites, presence of edema and ulceration, and absence of abscess; 5 = severe vasodilatation and inflammatory infiltration, characterized by neutrophils, abscesses, and diffuse ulcers.

Immunohistochemistry of TNF- α and ICAM-1

This technique is based on the detection of the product of gene expression (protein) in the cells of normal, mucositis and treated groups using specific polyclonal and monoclonal antibodies. The bound primary antibody is then detected by secondary antibody (usually mouse anti rat), which contains specific label (peroxidase labeled polymer conjugated to goat anti rat immunoglobulin). The substrate is 3,3-diaminobenzidine in chromogen Solution. Positive reaction will result in a brown colored precipitate at the antigen site in tested tissue (23). Immunohistochemistry (IHC) directly demonstrated the affected tissue's cells (24). The development of specific antibodies for immunohistochemical reactions, simultaneously with the evaluation of the production of several biochemical markers in intestinal samples that were paraffin-embedded to measure the pro-inflammatory cytokine TNF- α and adhesive molecule ICAM-1. Quantification of IHC was performed in accordance to the following semiquantitative scores (25), which were based on the percentage of positively stained cells as follows :0, no staining; 1, \leq 25%; 2, 26-50%; 3, 51-75 %; and 4, 76-10%.

Statistical analysis

Two software programs: SPSS (statistical package for social science) version 23 and Microsoft Office Excel 2013, were used to summarize, analyze and present the data. Quantitative (numeric) variables were expressed as mean and standard error. A paired t-test was utilized to determine the differences in the mean of dependent variables between the two groups. One-way ANOVA was used to study the difference in mean of quantitative variables among more than two groups, followed by a post hoc least significant difference (LSD) test to evaluate the mean difference between any two groups. The level of significance was considered at $p \leq 0.05$ (26).

Results

This current study exhibits the histological changes in oral mucosal tissue in methotrexate treated group, primarily with focal infiltration of inflammatory cells in submucosa, necrosis, and atrophy of skeletal muscles with hyaline degeneration and edema between it, as displayed in figures 1 and 2.

In addition, the bosentan-treated group showed a significant reduction in the microscopical score as judged by intact mucosa and submucosa with slight edema between muscle fibers as displayed in table 1 and figures 3-5. Table 1 and figures 6-9 showed there was a highly significant difference of TNF- α and ICAM-1 level in the methotrexate treated group in comparison with bosentan and methotrexate treated group. However, there were no statistical differences between the control group and Methotrexate in bosentan treated group.

Table 1: Histopathological and immunohistochemical score

	mean \pm Standard Error (n=8/group)		
	Control group	Methotrexate group	Bosentan group
Histopathology	1 \pm 0.0 ^a	4 \pm 0.0 ^b	1.33 \pm 0.33 ^a
TNF- α	1 \pm 0.0 ^a	3 \pm 0.0 ^b	1.67 \pm 0.33 ^a
ICAM-1	1 \pm 0.0 ^a	3 \pm 0.0 ^b	1.67 \pm 0.33 ^a

Comparison is expressed by letters; dissimilar letters denote significant differences.

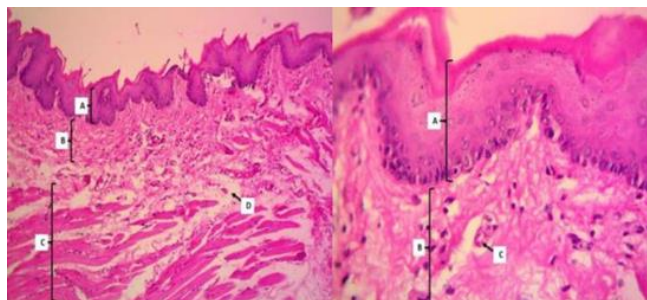


Figure 1: photomicrograph of rat buccal mucosa of control group shows normal architecture representing by mucosa (A), submucosa (B) and muscles (C) with slight edema between it (D). H&E stain, 100X, and by mucosa (A), submucosa (B) and blood vessels (C) 400X.

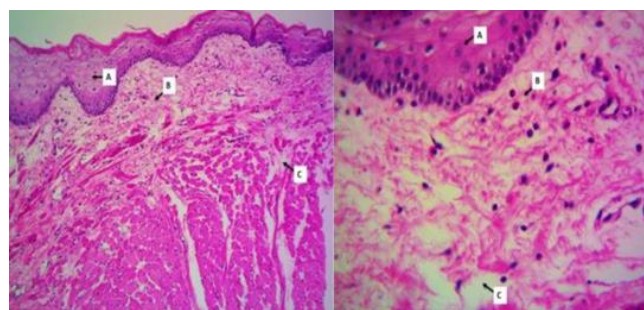


Figure 3: photomicrograph of rat oral mucosa of Bosentan group shows intact mucosa (A) and submucosa (B) with slight edema between muscles fibers (C). H&E stain, 100X, 400X.

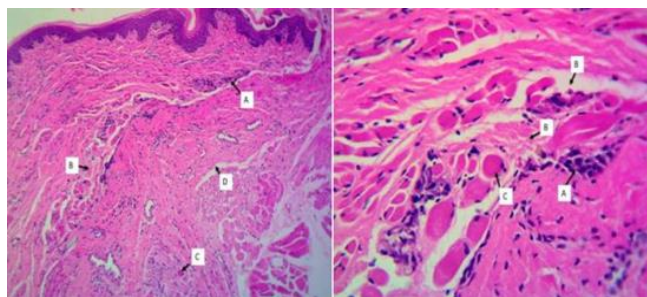


Figure 2: photomicrograph of rat oral mucosa of Methotrexate group shows present of focal infiltration of inflammatory cells in submucosa (A), necrosis and atrophy of skeletal muscles (B) with hyaline degeneration (C) and edema between it (D). H&E stain, 100X, 400X.

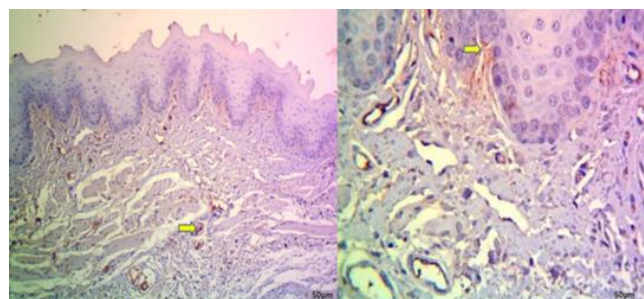


Figure 4: Immunohistochemical expression of TNF- α in the oral mucosa of the control group reveals slight blood vessels and cytoplasmic pattern in the stromal cells (brown color in the submucosa) (score 1); hematoxylin; 100X, 400X.

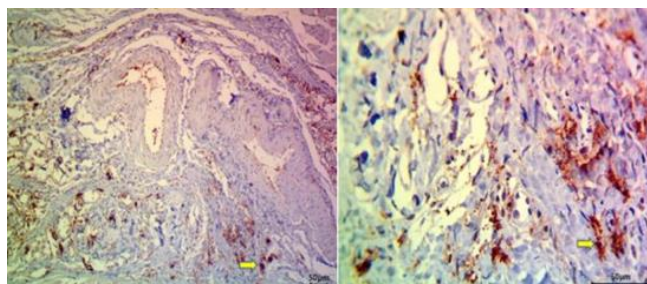


Figure 5: Immunohistochemical expression of TNF- α in the oral mucosa of the methotrexate group reveals strong blood vessels and cytoplasmic pattern in the stromal cells (brown color in the submucosa) (score 3); hematoxylin; 100X, 400X.

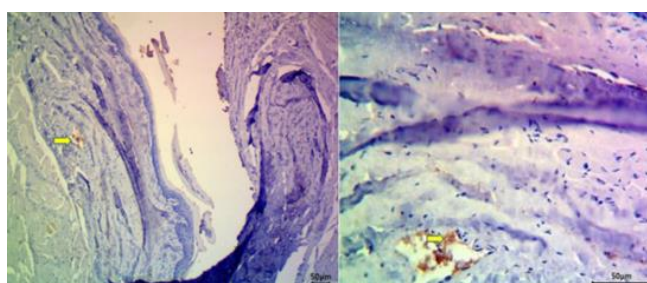


Figure 6: Immunohistochemical expression of TNF- α in the oral mucosa of the bosentan group reveals very slight blood vessels and cytoplasmic pattern in the stromal cells (brown color in the submucosa) (score 1); hematoxylin; 100X, 400X.

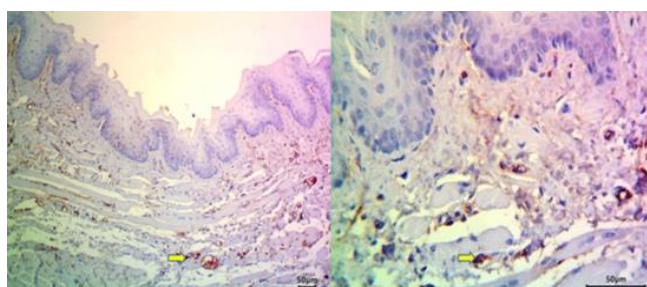


Figure 7: Immunohistochemical expression of ICAM-I in the oral mucosa of the control group reveals slight blood vessels and cytoplasmic pattern in the stromal cells (brown color in the submucosa) (score 1); hematoxylin; 100X, 400X.

Discussion

Methotrexate, a folic acid antagonist, is widely preferred as a cytotoxic chemotherapeutic agent, but its efficacy is limited due to its side effects (16). Despite the availability of many therapeutic agents that claim to prevent or reduce the severity of oral mucositis, no intervention that is entirely successful at preventing oral mucositis exists. In the present

study, the combined treatment of Methotrexate and bosentan ameliorated the buccal mucositis induced by Methotrexate alone.

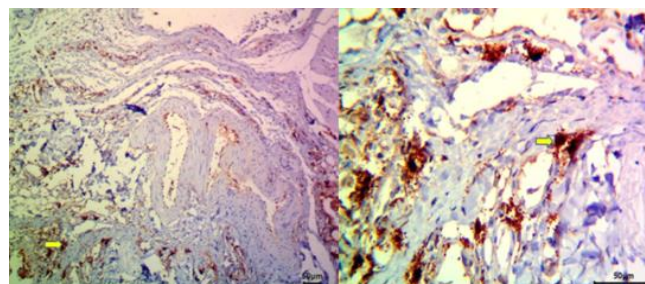


Figure 8: Immunohistochemical expression of ICAM-I in the oral mucosa of the methotrexate group reveals strong blood vessels and cytoplasmic pattern in the stromal cells (brown color in the submucosa) (score 3); hematoxylin; 100X, 400X.

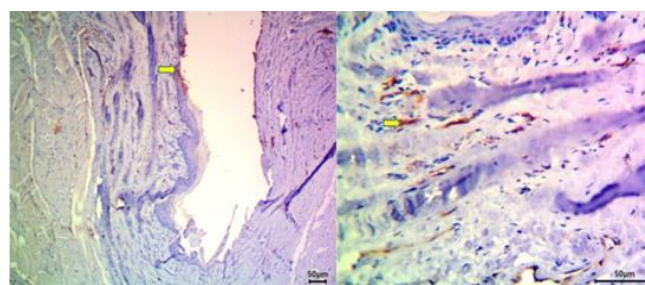


Figure 9: Immunohistochemical expression of ICAM-I in the oral mucosa of the bosentan with methotrexate group reveals very slight blood vessels and cytoplasmic pattern in the stromal cells (brown color in the mucosa and submucosa) (score 1); hematoxylin; 100X, 400X.

In the initial inflammatory/vascular phase of mucositis, the epithelial, endothelial, and connective tissue cells in the buccal mucosa release free radicals, modified proteins, and pro-inflammatory cytokines, including interleukin-1 β , prostaglandins, and Tumor Necrosis Factor (TNF). These inflammatory mediators cause further damage either directly or indirectly by increasing vascular permeability and angiogenesis, thereby enhancing cytotoxic drug uptake into the oral mucosa (1). Tumor necrosis factor- α is a crucial pro-inflammatory cytokine liberated from the lymphocytes and macrophages in the initial step of inflammation (27).

In this study, we also found that immunohistochemical expression of TNF- α in the cheek tissues was significantly increased in the rats' given Methotrexate, compared with healthy and bosentan groups. Chang *et al.* noted that the levels of pro-inflammatory cytokines, such as IL-1 β and TNF- α , were elevated in the oral tissue with mucositis developed due to chemotherapy (28). Another study shows that the levels of IL-1 β and TNF- α were increased, and

inflammatory ulcers were developed in the intestinal tissue with Methotrexate (29). Endothelial adhesion molecules, including intercellular adhesive molecule-1 (ICAM-1) and leukocyte extravasation during inflammation, are mainly regulated by the pro-inflammatory nuclear factor kappa-b (NF-Kb) pathway, which controls the transcription of adhesion molecules and mediators of inflammatory processes (30,31). Inter Cellular adhesive molecule (ICAM-1) engages the leukocytes association with endothelial cells, simplifying their penetration to the inflammatory site (32).

Chemotherapy-induced mucositis is characterized by damage to mucous membranes (33). Cell adhesion molecules interact with extracellular matrix components to regulate cell behavior, including apoptosis, proliferation, migration, and differentiation. Differential expression of Cell adhesion molecules has been demonstrated at the injury and healing phases of mucositis (34). Recently, the subepithelial extracellular matrix changes have been recognized as a hallmark of mucositis development. The cellular receptors that bind to the extracellular matrix are called cell adhesion molecules. Cell adhesion molecules are well known for their role in the regulation of cell kinetics through extracellular matrix regulation. Furthermore, they play a central role in inflammation, which is a key process in the pathogenesis of mucositis (34).

In this study, TNF- α expressions were significantly increased in the tissues in which ICAM-1 was significantly increased. Mafra *et al.* (35) reported the induction of the immunohistochemical expression of TNF- α and ICAM-1 in the 5 fluorouracil (5-FU) Induced Oral Mucositis. Histopathology also exhibited the histological changes in Methotrexate treated group, primarily with focal infiltration of inflammatory cells in submucosa, necrosis, and atrophy of skeletal muscles with hyaline degeneration and edema between it. In contrast, vacuolar degeneration of some epithelial cells, flattening or shortening of the rete ridge, and an increase in the number of congested blood vessels in the connective tissue are among the histopathologic findings of oral mucositis reported by Sultan (16) in an attempt to examine the protective effect of green tea extract.

Bosentan is a low molecular weight, potent, competitive, dual endothelin A and endothelin B receptor antagonist that is selective for the endothelin system (36). Bosentan antagonizes the detrimental effects of endothelin in various experimental models and exhibits vasodilating, antiproliferative, anti-inflammatory, and anti-fibrotic effects. Bosentan also improves endothelial function. Those effects may be responsible for bosentan's long-term efficacy in treating pulmonary arterial hypertension, which slows disease progression and increases survival (37). In our experiment, bosentan, which significantly prevented the increase of ICAM-1, also significantly prevented the increase of TNF- α expressions. Thus, bosentan probably inhibits inflammation by blocking various inflammatory network agents. It has been shown that treating animals with

bosentan resulted in a substantial decrease in several pro-inflammatory mediators, including TNF- α , endothelin-1 (38), and ICAM-1 (39). This observation provides insight into the mechanism of bosentan as an inhibitor of the inflammatory reaction. In a murine model of inflammatory bowel disease, the anti-inflammatory effect of bosentan was investigated, and it was determined that bosentan reduced inflammation in this animal model (40). Another study showed that prophylactic oral administration of bosentan reduced clinical inflammation in trinitrobenzene sulphonate-induced colitis in rats (41).

Conclusion

Bosentan has a protective effect through the anti-inflammatory action and reduction in histological score.

Acknowledgements

I am very grateful to the University of Mosul College of Dentistry for their provided facilities, which helped to improve the quality of this work.

Conflict of interest

Authors declared the absence of any conflict of interest.

References

1. Cawley MM, Benson LM. Current trends in managing oral mucositis. Clin J Oncol Nurs. 2005;9:584-592. DOI: [10.1188/05.CJON.584-592](https://doi.org/10.1188/05.CJON.584-592)
2. Munaretto JC, Ponzoni D, Haddad AS, Puricelli E. Preliminary histological analysis of methotrexate induced oral mucositis; an experimental study in mice. Passo Fundo. 2011;16:144-148. [\[available at\]](#)
3. Fadel MA, Abdullah MA, Al-Mahmood SS, Thanoon IA. Protective effect of propolis on liver and kidney injury caused by methotrexate in chicks. Iraqi J Vet Sci. 2022;36(4):1061-1067. DOI: [10.33899/ijvs.2022.133021.2162](https://doi.org/10.33899/ijvs.2022.133021.2162)
4. Alabdaly Y, Saeed M, Al-hashemi H. Effect of methotrexate and aspirin interaction and its relationship to oxidative stress in rats. Iraqi J Vet Sci. 2021;35(1):151-156. DOI: [10.33899/ijvs.2020.126490.1335](https://doi.org/10.33899/ijvs.2020.126490.1335)
5. Georgiou M, Patapatiou G, Domoxoudis S, Pistevou-Gompaki K, Papanikolaou A. Oral mucositis: Understanding the pathology and management. Hippokratia. 2012;16:215-216. [\[available at\]](#)
6. Alfreijat M. Tongue hyperpigmentation associated with chemotherapy. J Community Hosp Intern Med Perspect. 2013;3(3-4):21047. DOI: [10.3402/jchimp.v3i3-4.21047](https://doi.org/10.3402/jchimp.v3i3-4.21047)
7. Blanco-Colio LM, Tuñón J, Martín-Ventura JL, Egido J. Anti-inflammatory and immunomodulatory effects of statins. Kidney Int. 2003;63(1):12-23. DOI: [10.1046/j.1523-1755.2003.00744.x](https://doi.org/10.1046/j.1523-1755.2003.00744.x)
8. Duarte T, Da Cruz IB, Barbisan F, Capelletto D, Moresco RN, Duarte MM. The effects of rosuvastatin on lipid-lowering, inflammatory, antioxidant and fibrinolytic blood biomarkers are influenced by Val16Ala superoxide dismutase manganese-dependent gene polymorphism. Pharmacogenomics J. 2016;16(6):501-506. DOI: [10.1038/tbj.2015.91](https://doi.org/10.1038/tbj.2015.91)
9. Maheshwari RA, Balaraman R, Sailor, GU, Sen DB. Protective effect of simvastatin and rosuvastatin on trinitrobenzene sulfonic acid-induced colitis in rats. Indian J Pharmacol. 2015;47:17-21. DOI: [10.4103/0253-7613.150311](https://doi.org/10.4103/0253-7613.150311)

10. Abdel-Daim MM, Abdeen A. Protective effects of rosuvastatin and vitamin E against fipronil-mediated oxidative damage and apoptosis in rat liver and kidney. *Food Chem Toxicol.* 2018;114:69-77. DOI: [10.1016/j.fct.2018.01](https://doi.org/10.1016/j.fct.2018.01)
11. Abdeena A, Aboubakr M, Elgazzar D, Abdo M, Abdelkader A, Ibrahim S, Elkomy A. Rosuvastatin attenuates piroxicam-mediated gastric ulceration and hepato-renal toxicity in rats. *Biomed Pharmacoth.* 2019;110:895-905. DOI: [10.1016/j.biopha.2018.11.004](https://doi.org/10.1016/j.biopha.2018.11.004)
12. Yahyazadeh A. Effect of curcumin on rat sublingual gland exposed to cyclophosphamide. *Cukurova Med J.* 2021;46(3):897-903. DOI: [10.5455/medscience.2021.03.099](https://doi.org/10.5455/medscience.2021.03.099)
13. Keles S, Halici Z, Atmaca H, Yayla M, Yildirim K. The Ocular Endothelin System: A Novel target for the treatment of endotoxin-induced uveitis with bosentan. *Investig Ophthalmol Vis Sci.* 2014;55:3517-3524. DOI: [10.1167/iovs.14-14193](https://doi.org/10.1167/iovs.14-14193)
14. Watanabe S, Suemaru K, Nakanishi M, Nakajima N, Tanaka M, Tanaka A, Araki H. Assessment of the hamster cheek pouch as a model for radiation-induced oral mucositis, and evaluation of the protective effects of keratinocyte growth factor using this model. *Int J Radiat Biol.* 2014;90(10):884-91. DOI: [10.3109/09553002.2014.922716](https://doi.org/10.3109/09553002.2014.922716)
15. Hogaboam CM, Muller MJ, Collins SM, Hunt RH. An orally active non-selective endothelin receptor antagonist, bosentan, markedly reduces injury in a rat model of colitis. *Eur J Pharmacol.* 1996;15;309(3):261-9. DOI: [10.1016/0014-2999\(96\)00276-2](https://doi.org/10.1016/0014-2999(96)00276-2)
16. Sultan AA, Ali AH, Kamal KA. Immunohistochemical study of the effect of green tea extract on methotrexate- induced oral mucositis in albino rats. *J Cytol Histol.* 2014;5(3):1-7. DOI: [10.4172/2157-7099.1000227](https://doi.org/10.4172/2157-7099.1000227)
17. Campos MI, Campos CN, Corrêa JA, Aarestrup FM, Aarestrup BV. Induced oral mucositis in Wistar rats treated with different drugs: Preventive potential in cytokine production. *Mol Clin Oncol.* 2021;14(6). DOI: [10.3892/mco.2021.2289](https://doi.org/10.3892/mco.2021.2289)
18. Ahmed AA, Mammdoh JK. Expression of Ki67 in submandibular salivary glands of rabbits after BTX injection: Histological and immunohistochemical study. *Iraqi J Vet Sci.* 2022;36(3):611-620. DOI: [10.33899/ijvs.2021.131101.1919](https://doi.org/10.33899/ijvs.2021.131101.1919)
19. Al-Allaf LI, Attarbashee RA, Mammdoh JK. The effect of cyclophosphamide on hippocampal structure of adult male rats (Role of Rosuvastatin). *Mil Med Sci Lett.* 2022;91(3):256-264. DOI: [10.31482/mmsl.2022.022](https://doi.org/10.31482/mmsl.2022.022)
20. Al-Allaf LI, Mammdoh JK, Ahmed AA. The histologic effects of high doses of botulinum toxin a on the rabbit's salivary gland. *Iraqi J Vet Sci.* 2022;36(4):1111-1117. DOI: [10.33899/ijvs.2022.133149.2184](https://doi.org/10.33899/ijvs.2022.133149.2184)
21. Mammdoh JK, Al-Mashhadanee FA, Al-Moula AD, Aljader GH. Effect of topical serratiopeptidase on facial wound healing in rabbit. *J Glob Pharma Technol.* 2020;12(6):284-290. [\[available at\]](#)
22. Watanabe S, Suemaru K, Nakanishi M, Nakajima N, Tanaka M, Tanaka A, Araki H. Assessment of the hamster cheek pouch as a model for radiation-induced oral mucositis, and evaluation of the protective effects of keratinocyte growth factor using this model. *Int J Radiat Biol* 2014;90:884-91. DOI: [10.3109/09553002.2014.922716](https://doi.org/10.3109/09553002.2014.922716)
23. Kabiraj A, Gupta J, Khaitan, T. Principle and techniques of immunohistochemistry-a review. *Int J Biol Med Res.* 2015;6(3):5204-5210. [\[available at\]](#)
24. Bertevello PL, Logullo ÂF, Nonogaki S, Campos FM, Chiferi V. Immunohistochemical assessment of mucosal cytokine profile in acetic acid experimental colitis. *Clin.* 2005;60(4):277-86. DOI: [10.1590/S1807-59322005000400004](https://doi.org/10.1590/S1807-59322005000400004)
25. Hernández-Rodríguez J, Segarra M, Vilardell C. Tissue production of pro-inflammatory cytokines (IL-1beta, TNF alpha, and IL-6) correlates with the intensity of the systemic inflammatory response and with corticosteroid requirements in giant-cell arteritis. *Rheumatol.* 2004;43(3):294-301. DOI: [10.1093/rheumatology/keh058](https://doi.org/10.1093/rheumatology/keh058)
26. Daniel WW. *Biostatistics: A foundation for analysis in the health sciences.* 9th ed. New York: Saunders; 2009. 278 p.
27. Attarbashee RK, Abu-Raghiif A. Comparative treatment of induced ulcerative colitis in male rat model by using cinnarizine and sulfasalazine. *Iraqi J Vet Sci.* 2020;34(2):465-472. DOI: [10.33899/ijvs.2019.126170.1254](https://doi.org/10.33899/ijvs.2019.126170.1254)
28. Chang CT, Hsiang CY, Ho TY, Wu CZ, Hong HH, Huang YF. Comprehensive assessment of host responses to 5-fluorouracil-induced oral mucositis through transcriptomic analysis. *PloS One.* 2015;10(8):e0135102. DOI: [10.1371/journal.pone.0135102](https://doi.org/10.1371/journal.pone.0135102)
29. de Araújo AA, Borba PB, de Souza FH, Nogueira AC, Saldanha TS, Araújo TE, da Silva AI, de Araújo Júnior RF. In a methotrexate-induced model of intestinal mucositis, olmesartan reduced inflammation and induced enteropathy characterized by severe diarrhea, weight loss, and reduced sucrose activity. *Biol Pharm Bull.* 2015;38(5):746-752. DOI: [10.1248/bpb.b14-00847](https://doi.org/10.1248/bpb.b14-00847)
30. Lai TH, Chung CH, Chen BH, Hung CF, Inbaraj BS, Ma MC. Gold nanoparticles compromise TNF-alpha-induced endothelial cell adhesion molecule expression through NF-kappaB and protein degradation pathways and reduce neointima formation in a rat carotid balloon injury model. *J Biomed Nanotechnol.* 2016;12:2185-2201. DOI: [10.1166/jbn.2016.2315](https://doi.org/10.1166/jbn.2016.2315)
31. Zhao W, Feng H, Guo S, Han Y, Chen X, Danshenol A. Inhibits TNF-alpha-induced expression of intercellular adhesion molecule-1 (ICAM-1) mediated by NOX4 in endothelial cells. *Sci Rep.* 2017;7:12953. DOI: [10.1038/s41598-017-13072-1](https://doi.org/10.1038/s41598-017-13072-1)
32. Attarbashee RK, Abu-Raghiif A. The therapeutic effects of ambrisentan on experimentally induced colitis in a male rat's models. *Ann Trop Med Public Health.* 2021;23(4):S495. DOI: [10.36295/ASRO.2020.23411](https://doi.org/10.36295/ASRO.2020.23411)
33. Mamdoh J, Mustafa EA, Jawad AA. Evaluation of anti-inflammatory and antimicrobial effects of Iraqi propolis mouth wash in mucositis patients induced by chemotherapy. *Int J Enhanc Res Sci Technol Eng.* 2015;4(9):80-88. [\[available at\]](#)
34. Al-Dasooqi N, Bowen J, Bennett C, Finnie J, Keefe D, Gibson R. Cell adhesion molecules are altered during irinotecan-induced mucositis: A qualitative histopathological study. *Support Care Cancer.* 2017;25:391-398. DOI: [10.1007/s00520-016-3413-x](https://doi.org/10.1007/s00520-016-3413-x)
35. Mafra CD, Vasconcelos RC, Xavier de Medeiros CA, Leitão RF. Gliclazide prevents 5-FU-induced oral mucositis by reducing oxidative stress, inflammation, and p-selectin adhesion molecules. *Front Physiol.* 2019;10:327. DOI: [10.3389/fphys.2019.00327](https://doi.org/10.3389/fphys.2019.00327)
36. Clozel M, Salloukh H. Role of endothelin in fibrosis and anti-fibrotic potential of bosentan. *Ann Med.* 2005;37(1):2-12. DOI: [10.1080/07853890410018925](https://doi.org/10.1080/07853890410018925)
37. Kılık G, Muz MH, Deveci F, Turgut T, İlhan F, Özeran İ. Effect of bosentan on the production of proinflammatory cytokines in a rat model of emphysema. *Exp Mol Med.* 2007;39(5):614-620. DOI: [10.1038/emm.2007.67](https://doi.org/10.1038/emm.2007.67)
38. Muller DN, Mervaala EM, Schmidt F, Park JK. Effect of bosentan on NF-κB, inflammation, and tissue factor in angiotensin II-induced end-organ damage. *Hypertens.* 2000;36:282-290. DOI: [10.1161/01.HYP.36.2.282](https://doi.org/10.1161/01.HYP.36.2.282)
39. Anthoni C, Mennigen RB, Rijcken EJ, Laukötter MG, Spiegel HU, Senninger N, Schürmann G, Krieglstein CF. Bosentan, an endothelin receptor antagonist, reduces leucocyte adhesion and inflammation in a murine model of inflammatory bowel disease. *Int J Colorectal Dis.* 2006;2:409-18. DOI: [10.1007/s00384-005-0015-3](https://doi.org/10.1007/s00384-005-0015-3)
40. Güllüoğlu BM, Kurtel H, Güllüoğlu MG, Yegen C, Aktan AÖ, Dizdaroglu F, Yalin R, Yegen BC. Role of endothelins in trinitrobenzene sulfonic acid-induced colitis in rats. *Digestion.* 1999;60:484-92. DOI: [10.1159/00007695](https://doi.org/10.1159/00007695)
41. Clozel M. Effects of bosentan on cellular processes involved in pulmonary arterial hypertension: Do they explain the long-term benefit?. *Ann Med.* 2003;35:605-13. DOI: [10.1080/07853890410018925](https://doi.org/10.1080/07853890410018925)

الحيوانات إلى ثلاث مجاميع: المجموعة الأولى هي السيطرة، المجموعة الثانية عولجت بالميثوتريكسيت ٨٠ ملغم / كغم، المجموعة الثالثة عولمت بالميثوتريكسيت والبوسينتان ٦٠ ملغم / كغم. تم تحديد التغيرات النسيجية المجهرية وقياس عامل النخر الورمي وجزء المادة اللاصقة بين الخلايا -١ في الغشاء المخاطي للشدق. تم التضحية بالحيوانات في اليوم الخامس عشر وتم تشريح الغشاء المخاطي للشدق للتحليل النسيجي والكيميائي المناعي. قلل البوسينتان من شدة التهاب الغشاء المخاطي للغم الناجم عن الميثوتريكسيت عن طريق انخفاض معنوي في درجة التغيرات النسيجية، وانخفاض كبير في التعبير الكيميائي المناعي لعامل النخر الورمي وجزء المادة اللاصقة بين الخلايا -١ في اليوم الخامس عشر. أظهر البوسينتان بتركيز ٦٠ مجم / كجم / يوم حماية ضد التهاب الغشاء المخاطي للغم الناجم عن الميثوتريكسيت من خلال تأثيره المضاد للالتهابات وتقليل درجة التغيرات النسيجية وبالتالي يمكن استخدامه كعامل وقائي ضد التهاب الغشاء المخاطي للغم الناجم عن الميثوتريكسيت.

التأثير الوقائي للبوسينتان في التهاب الغشاء المخاطي الفموي المحدث بواسطة الميثوتريكسيت في الجرذان

رنا خيرى عطارباشي^١، جوناء خالد ممدوح^١ و سحر غاتم القزاز^٢

^١ فرع علوم طب الأسنان الأساسية، فرع جراحة الفم والوجه والفكين، كلية طب الأسنان، جامعة الموصل، الموصل، العراق

الخلاصة

هدفت هذه الدراسة إلى تقييم فعالية البوسينتان كعامل وقائي للغشاء المخاطي لغم الجرذان ضد التهاب الغشاء المخاطي للغم الناجم عن الميثوتريكسيت. تم استخدام أربعة وعشرين جرذاً من نوع ويست-البينو، تتراوح أعمارهم بين ١٢-١٦ أسبوعاً وبوزن ٣٠٠-٤٠٠ غم. قسمت