



## Detection of *Sarcocystis* spp in imported frozen and slaughtered chickens by different techniques in Mosul city

N.H. Mohammed , L.Y. Khalil  and E.G. Suleiman 

Department of Microbiology, College of Veterinary Medicine, University of Mosul, Mosul, Iraq

### Article information

#### Article history:

Received 10 June, 2024

Accepted 27 August, 2024

Published online 30 September, 2024

#### Keywords:

*Sarcocystis wenzeli*

Chickens

PCR

#### Correspondence:

E.G. Suleiman

[emanghanim73@gmail.com](mailto:emanghanim73@gmail.com)

### Abstract

*Sarcocystosis* is an important disease, especially in many types of birds. It is caused by the *Sarcocystis* parasite, a protozoan that needs two hosts to complete its life cycle. The current study showed diagnosis of *Sarcocystis* spp. in slaughtered poultry and imported frozen chickens. The infection rate of the *Sarcocystis* spp parasite of slaughtered chickens was 24.6-40%, respectively. At the same time, the infection of *Sarcocystis* spp of imported frozen chickens were 51.1 and 66.7% by macroscopic and microscopic examination, respectively. The infection rate of macroscopic cysts among the organs of slaughtered and imported frozen chickens in the pectoral muscles showed the highest percentage 50, 60.9%, while the lowest percentage was in the arm 0-8.7% respectively. The pepsin digestibility test recorded the highest percentage in the microscopic examination, reaching 40 and 66.7% in slaughtered and imported frozen Chickens, respectively. The histopathological examination showed the presence of tachyzoites within the interstitial tissue muscle, with coagulative necrosis, edema with inflammatory cells, congestion, and thickening of blood vessels. In our study, we confirmed the diagnosis of *Sarcocystis* in locally slaughtered and imported frozen chickens by molecular analysis using genus specific primers with a molecular weight of 700 bp. We found two new local isolates related to the species *Sarcocystis wenzeli*. Based on morphology and molecular methods, the current research is the first to diagnose *Sarcocystis wenzeli* infection in slaughtered local chickens and imported frozen chickens in Mosul.

DOI: [10.33899/ijvs.2024.150772.3719](https://doi.org/10.33899/ijvs.2024.150772.3719), ©Authors, 2024, College of Veterinary Medicine, University of Mosul.

This is an open access article under the CC BY 4.0 license (<http://creativecommons.org/licenses/by/4.0/>).

### Introduction

*Sarcocystis* is a parasitic protozoan that forms cysts intracellular and needs two hosts to complete its life cycle; predators represent the final host of the *Sarcocystis* parasite, while prey animals act as intermediate hosts (1). order of Anseriformes are intermediate hosts for *Sarcocystis* species of avian species within this order, *S. wobeseri* *S. rileyi*, *S. albifronsi*, and *S. anasi*, macrocysts form of the *S. rileyi*, its shape is like a grain of rice, and the other three species from microcysts that are not visible by the naked eye (2-4). The asexual proliferation of *Sarcocystis* produces meronts in pulmonary capillaries in infected birds, and the *Sarcocystis* is characterized by a wall striated and merozoites (5-7).

*Sarcocystosis* is vital disease, especially in many types of birds. One of these types is chickens, as mentioned in the case report by Villar *et al.* (8). When they diagnosed *Sarcocystis* in Psittaciformes birds, they found different clinical signs: an acute pulmonary, neurological, and muscular disease. Has astrocytes observed within the myocardium, necropsy, and histological findings associated with fatal *Sarcocystosis*. Many *Sarcocystis* spp. may be infected in poultry (9-11). *S. horvathi* and *S. wenzeli*, which affect chickens, are emerging neurologic diseases with lethal outcomes (11). The rice grain shape of *Sarcocystis* spp. contained many bradyzoites released by homogenization in water; the *Sarcocystis* were surrounded by a single cyst wall in some cases, but not all (12). The possible infection of man

in Malaysia by the contamination of water food with sporocysts of *S. nesbitti*, which are excreted by snakes (definitive hosts of this parasite) (13). the economic losses caused by the parasite *Sarcocystis* spp. in animal meat; it is also a zoonosis disease infecting humans through contamination of beef with *Sarcocystis* of the parasite (14). So, monitoring the health conditions and food of animals acting as intermediate hosts and keeping these animals from being definitive hosts may effectively reduce animal infection in birds and cattle (15,16).

Due to the fewer studies on the presence and diagnosis of *Sarcocystis* in poultry in the city of Mosul, therefore the research aimed to detect the macroscopic and microscopic cysts of *Sarcocystis* spp. in the tissue section and record the histopathological changes conjugated with *Sarcocystis* and Molecular identification of species *Sarcocystis* in chickens in Mosul city.

## Materials and methods

### Ethical approve

The research ethics were previously permitted by an authorized ID of UM. Vet.016/2024.

### Collection of samples

This research was conducted for the period from January 2024 to May 2024; one hundred and ten samples of muscle were collected from 45 slaughtered chickens that were randomly examined from different abattoirs in Mosul city, Iraq (15,16), and imported frozen chickens sold in local markets in the city of Mosul. The *Sarcocystis* was diagnosed based on the following diagnostic methods they are:

### Macroscopic examination

All chickens had their skin removed, and all tissue was visually examined cysts of *Sarcocystis* spp. (17,18).

### Trichinostomy (Slide squash method)

This involves taking one gram of muscle tissue for each sample, cutting it into 2-3 mm thick, placing them between two slides, and examining them under a microscope at (40x) to detect microscopic *Sarcocystis* cysts (19,20).

### Squeezing (Muscle grinds method)

20-25 g from each sample was prepared using a garlic press (21).

### Pepsin digestion method

Muscular tissue 50 gm was homogenized and incubated with 100 ml of pepsin 0.5%, HCL 1.5% at 24°C overnight, and filtered centrifuge. The sediment was stained by Giemsa stain after fixing the smear in methanol and examined by a light microscope for detection of the bradyzoites (22,23).

## Histopathological diagnosis

The Positive samples were fixed in 10% neutral buffered formalin for 24 hours before dehydrating to obtain accurate preservation. They were then dehydrated, cleared, embedded in paraffin and sliced into 5 micrometers. Finally, the slides were stained with hematoxylin and eosin and prepared to be examined under a microscope (24).

## DNA extraction

The DNA was extracted from the small parts of muscles that contain the microscope and macroscopic cysts of *Sarcocystis* according to the manufacturer's Geneaid kit. The DNA pellet was hydrated by adding 100 ml of Rehydration solution and then saved at -20°C until a technical PCR production was done.

## Polymerase chain Reaction

The polymer analysis of the sbp was based on the amplification of the 185 Ribosomal gene for the *Sarcocystis* genus, and we use primers: Sar-fi: forward 5'-GCACTTGATGAA TTCTTGGCA-3'. Sar-Ri: Reverse 5'-GCACTTGATGAA TTCTTGGCA-3' (25).

## The PCR reaction

The reaction mixture for the PCR technique was prepared from 20 ml, containing 1 ml of each primer, 4 ml of DNA template 10 master mix bio labs, and 4 ml of PCR grade water. After that, the PCR cycles were conducted using a thermocycler within the reaction program (25). The reaction product of PCR was then run on a 2% agarose, adding the Ladder DNA (Biolaps) in one of the agarose gels. After that, the sample was migrated using electrophoresis for 60 v for 60-70 min and in the vaginal while sustained with the red safe and photographed under UV light (Gel documentation).

## DNA sequencing

Nitrogenous base sequences of *Sarcocystis* were done using the Genetic Analyzer 3130 (Hitachi, Japan) and compared with NCBI according to the BLAST program. Based on the Mega 11 program, a study of the phylogenetic tree of the *Sarcocystis* parasite species was diagnosed.

## Statistical analysis

The significant difference was calculated when the probability value was less than 0.05 using the chi-square test in SPSS software (SPSS Inc., Chicago, USA).

## Results

This research revealed that the macroscopic and microscopic cysts of *Sarcocystis* were recognized, and the prevalence of *Sarcocystis* spp. in slaughtered chicken was 24.6-40% respectively. In comparison, the prevalence of macroscopic and microscopic examination of *Sarcocystis* spp. in the imported frozen chicken was 51.1, 66.7%. The

highest prevalence of macroscopic and microscope cysts of *Sarcocystis* spp. were found in imported frozen chicken (Table 1). The macroscopic examination of *Sarcocystis* appeared milky white and had oval or cylindrical cysts similar to those of rice grains. Their length ranged from 5 -8 mm embedded in the muscle's fibers examined by the naked eye (Figure 1). The occurrence of macroscopic cysts among the organs examined of slaughtered chickens and imported frozen pectoral muscles showed the highest rate 50, 60.9%. At the same time, low visible lesions were seen in the arm (Table 2).

Under light microscopic examination, the Bradyzoites were recognized as banana-shaped, as examined using the digestion by pepsin test, squeezing, and muscle squash (Figures 2-4). The pepsin digestion test gave the highest average rate, 40, 66.7%, followed by squeezing 35.4, 62.2%, and muscle squash, 29.2, 53.3% (Table 3). The results of the histopathological examination showed the presence of tachyzoites inside the interstitial tissue of the muscle with the presence of coagulative necrosis of these fibers and the edema among the fiber of the muscle with inflammatory cells and congestion with thickening of blood vessels (Figures 4-7).

The result of the PCR technique showed that it confirmed the diagnosis of infection with *Sarcocystis* species with a molecular weight of 700 bp, as shown in (Figure 8). The results of genetic sequencing showed the diagnosis of the macroscopic and microscopic cysts of *Sarcocystis wenzeli* for the first time in samples of the slaughtered local and imported frozen chickens. Two new isolates of this species were recorded in the world gene bank; they were the *Sarcocystis wenzeli* NLESa1 gene for 18SrRNA partial sequence LC 792624.1 and *Sarcocystis wenzeli* NLESa2 gene for 18SrRNA, partial sequence. The phylogenetic tree showed that our diagnostic isolates from local chickens and imported frozen chickens in the city of Mosul were close to isolates diagnosed in China, as isolates LC792624.1 *Sarcocystis wenzli* NLESa1 close to MT 756998.1 *Sarcocystis wenzli* China and while the isolates LC79265.1 *Sarcocystis wenzeli* NLESa2 close to the MT75990.1

*Sarcocystis* China and MT756993.1 *Sarcocystis wenzeli* China (Figure 9).

Table 1: Prevalence of *Sarcocystis* spp. infection

Type	No.	Macroscopic cysts	Microscopic cysts
Slaughter	65	16(24.6%)	26(40%)a
Imported	45	23(51.1%)	30(66.7%)a

Similar letters mean no significant value.

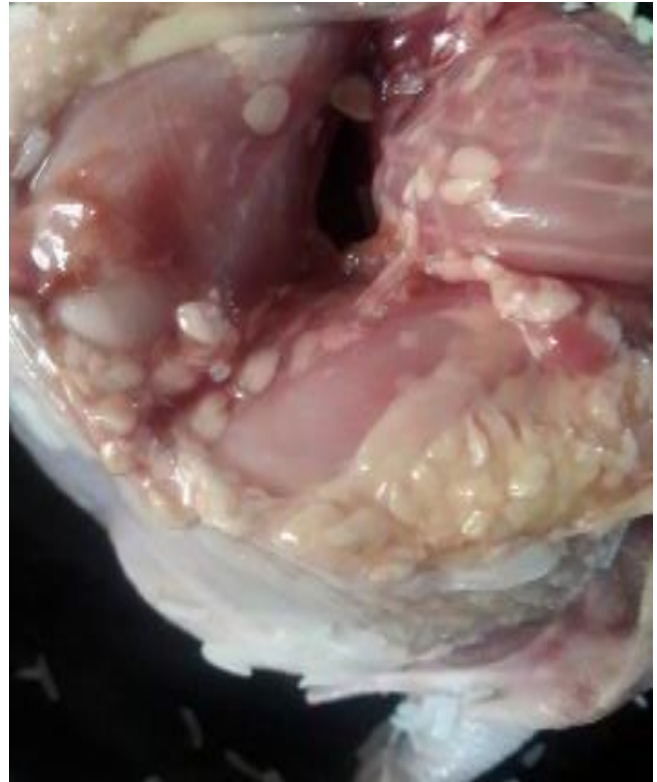

Figure 1: Macroscopic examination of *Sarcocystis* detected from imported frozen chickens.

Table 2: Macroscopic examination of *Sarcocystis*

Type	No. positive	Pectoral (%)	Neck (%)	Dorsal (%)	Ventral abdominal (%)	Arm (%)
Slaughter	16	8 (50%)	6 (37.5%)	3 (18.8%)	2 (12.5%)	Not done
Imported	23	14(60.9%)	10 (43.5%)	6 (26.1)	3 (13 %)	2 (8.7%)

Table 3: Comparison between examination methods used for diagnosis of *Sarcocystis*

Type	No. examined	Pepsin	Squeezing	Trichinoscopy
Slaughter	65	26 (40%)	23 (35.4%)	19 (29.2%)
Imported	45	30 (66.7%)	28 (62.2%)	24 (53.3%)




Figure 2: Microscopic examination of cysts in the muscle fibers of chickens by Trichinoscopy 40x.

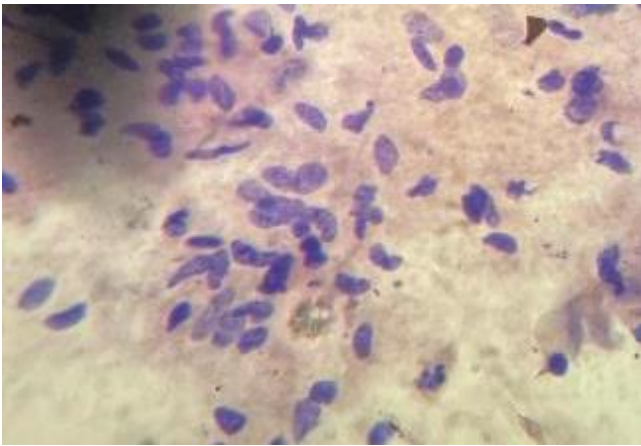


Figure 3. *Sarcocystis* bradyzoites from digested muscle samples by pepsin digestion method stained with Giemsa stain 100x.

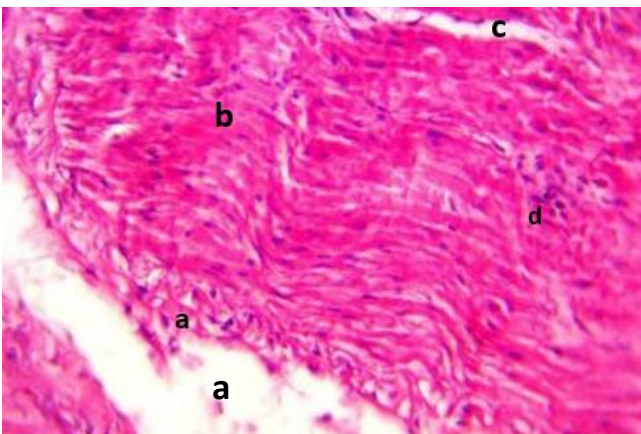

Figure 4: *Sarcocystis* spp. a: Tachyzoites showed inside the muscle fibers. b: with the presence of coagulative necrosis of these fibers. c: the edema among the fiber of the muscle. d: inflammatory cell. H and E, 40X.

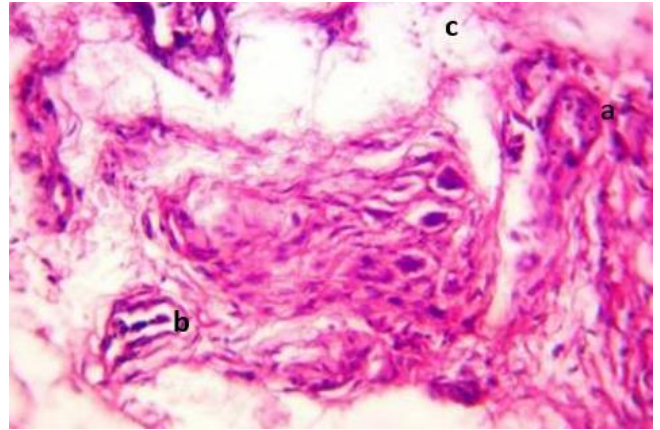


Figure 5: a: the Tachyzoites in the interstitial tissue of the muscle. b: The Congestion of blood vessels. c: edema. H and E, 10X.

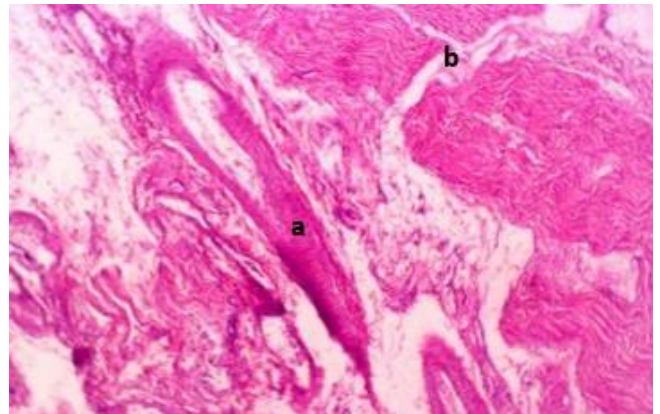


Figure 6: a: congestion and thickening of blood vessel wall with edema. b: coagulative necrosis. H and E, 10x.

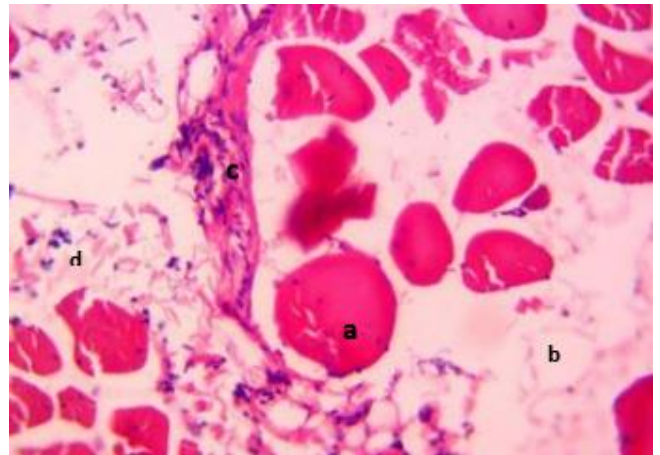


Figure 7: a: coagulative necrosis. b: edema. c: Tachyzoites in the interstitial tissue of muscle. d: inflammatory cell. H&E, 10X.

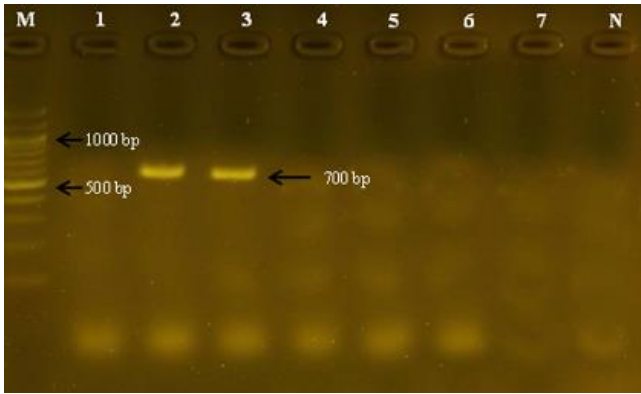


Figure 8: Shows the product of a 700 bp PCR reaction for the *Sarcocystis* spp. in chicken meat, which was transferred with 2% agarose gel.

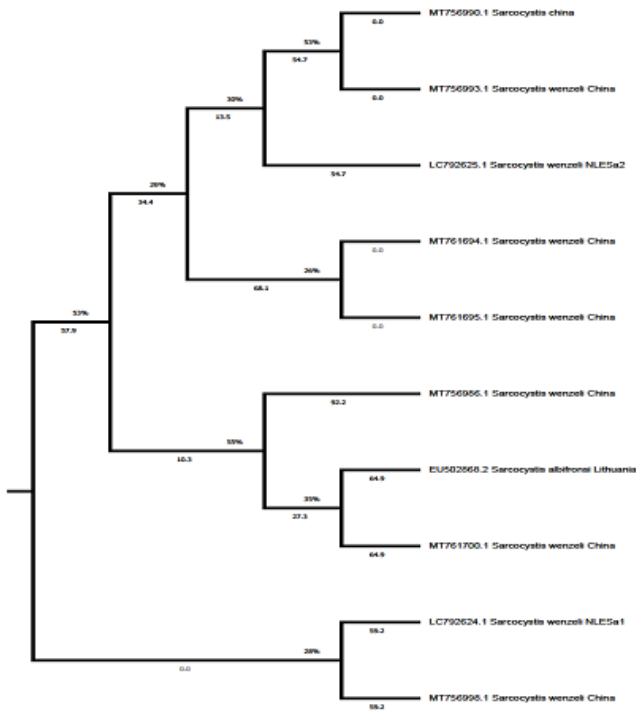


Figure 9: Showing the phylogenetic tree of the *Sarcocystis wenzeli* diagnosed in local slaughtered chickens and frozen imported chickens in Mosul.

## Discussion

The poultry industry faces many challenges, including exposure to many pathogens such as bacterial, viral and parasitic diseases (26-29), in addition to problems in feeding and management methods (30-33). The *Sarcocystis* parasite, one of the important parasitic protozoa, spread in all countries and has a major impact on public health, as it has been isolated from various animals from all over the world,

causing economic losses in meat packaging and production through its impact on the quality and appearance of meat, which affects meat consumption (34,35). This research is the first study in which *Sarcocystis* was diagnosed in slaughtered local and imported frozen chickens in Mosul -Iraq. In this study, macro and micro cysts of the *Sarcocystis* were identified in slaughtered chickens and imported frozen chickens, and this indicates the importance of this parasite in poultry, which is one of the important intermediate hosts for this parasite, this result was in agreement with Mac *et al.* (36) who noted of macro and micro cysts of birds slaughtered in the north central Nigeria, this study also agreed with Faraj *et al.* (37) who demonstrated the presence of macro cysts in the thoracic muscles and neck area in wild birds, Costanzo (38) found 3% macroscopic cysts in ducks at older ages, and no cysts were recorded in ducks at younger ages. The current results indicated that the infection rate of microscopic and macroscopic cysts in slaughtered local chickens was 24.6%, 40% less than in imported frozen chickens, where infection rates reached 51.1% and 66.7%. This percentage in the current study is lower than recorded by Vahidi *et al.* (39) that the infection rate in ducks and chickens reached 100%, 94.78% in Iran, while Latif (40) recorded an infection rate 25% of microscopic cysts in birds. In contrast, macroscopic cysts were not recorded; this covariance in prevalence was due to the difference in geographical region, climatic factors, and methods of raising and managing poultry. The number of samples, in addition to the presence of dogs and cats in the areas surrounding the poultry farm, and the extent of soil contamination with *Sporocysts* (41,42). The results also showed a difference in the infection rate depending on the site of infected muscles, as the highest percentage was recorded in the pectoral muscles, while the lowest percentage was in the abdominal and arm muscles. This is consistent with Faraj *et al.* (37), while it is not consistent with Latif (40), which did not record macroscopic cysts of the parasite in birds. In the results of this study, different methods were used to detect microscopic cysts, and the pepsin method recorded the highest percentage, and this was consistent with the results of many researchers (43,44) who indicated that this technique is the most sensitive in detecting this parasite. The existence of *Sarcocystis* can lead to incomplete or entire rejection of slaughtered animals in slaughterhouses, which can critically affect meat quality and sales promotion (45). In the present research, edema, coagulative necrosis of muscle fibers, and almost focal inflammatory cell infiltration of mononuclear cells, similar studies found mild inflammatory cell infiltrations around the cysts and the cyst compartments containing thousands of Bradyzoites (46,47). Also, the study demonstrated that the influence of Tachyzoites on the interstitial connective tissue caused the split of muscle fibers, which was agreed upon (48). This result is conceded to by Swar and Shnawa (49), who mentioned in their outcome that the disorganization of muscle tissue infected with *Sarcocystis* appeared and was

filled with Bradyzoites and necrosis. In contrast, the study (24) indicated no inflammation was observed in the tissue surrounding the Bradyzoites, which did not agree with our result. This is because protozoa are located in the cysts within the muscle fibers, which apply for protection from host immunity, a hypothesis that has been approved for different parasites (50). Our study showed that *Sarcocystis wenzeli* caused thickening and congestion of blood vessel walls, which comply with those of (51). A molecular analysis is widely used to confirm and diagnose *Sarcocystis* species (41,52). Our research used the 18srRNA gene to detect *Sarcocystis* spp. in locally slaughtered and imported frozen chickens using genus-specific primers as in previous studies (25). We found two isolates: the *Sarcocystis wenzeli* NLEsA1 gene for 18srRNA, partial sequence (LC792624.1) and the *Sarcocystis wenzeli* NLEsA2 gene for 18sr RNA, partial sequence. The current research is the first to diagnose the macroscopic and microscopic cysts of *Sarcocystis wenzeli* in local and imported frozen chicken in Mosul city, depending on the morphology and molecular methods. This result was in agreement with (53), who referred that only *Sarcocystis wenzeli* was identified in poultry of China based on the cyst ultrastructure and five loci (18sr RNA, ITS1, 28sr DNA coxi, and rpo B) of the parasite were sequenced, analyzed and deposited in Gen-Bank, also Al-Saadi (20) showed that the molecular assay was used to identify the *Sarcocystis* by using certain regions of 18srRNA which are used widely to diagnose the *Sarcocystis* spp. in different species of animals and easily used the molecular methods for diagnosing the *Sarcocystis* compare with the microscopic examination which it takes a long time and needs more expertise for microscopic screening. The phylogenetic tree of our study indicated that the isolates identified in local and imported frozen chicken in Mosul city related to the species *Sarcocystis wenzeli* these isolates were close to isolates of *Sarcocystis* and *Sarcocystis wenzeli* in China, Pan *et al.* (54) showed that *Sarcocystis wenzeli* is closely related to the *Sarcocystis* spp. which uses geese or ducks as intermediate host and dogs as final host. The results of genetic diversity showed that the new diagnostic isolates of the *Sarcocystis wenzeli* parasite recorded in local chickens slaughtered and frozen imported in the city of Mosul differ from isolates in many countries of the world, and this may be due to the influences of the environment that prepare the organisms to adapt to them.

## Conclusion

This study showed the diagnosis of *sarcocystis* spp. a parasite in slaughtered poultry and imported frozen chickens and diagnose two new local isolates related to the species *sarcocystis wenzeli* based on morphology and molecular methods

## Acknowledgment

This research was conducted at the University of Mosul, College of Veterinary Medicine.

## Conflict of interest

Researchers confirm that there is no conflict.

## References

1. Dubey JP, Calero BR, Roseenthal BM, Speer CA, Fayer R. Sarcocystosis of animals and humans. 2<sup>nd</sup> ed. Boca Raton: CRC Press; 2016. DOI: [10.1201/b19184](https://doi.org/10.1201/b19184)
2. Dubey JP, Cawthorn RJ, Speer CA, Wobeser GA. Redescription of the Sarcocysts of *Sarcocystis rileyi* (Apicomplexa: Sarcocystidae). J Eukaryot Microbiol. 2003;50:476-482. DOI: [10.1111/j.1550-7408.2003.tb00274.x](https://doi.org/10.1111/j.1550-7408.2003.tb00274.x)
3. Kutkiene L, Parkas P, Sruoga A, Butkauskas D. The mallard duck (*Anas platyrhynchos*) as intermediate host for *Sarcocystis wobeseri* sp. nov. from the barnacle goose (*Branta leucopsis*). Parasitol Res. 2010;107:879-888. DOI: [10.1007/s00436-010-1945-4](https://doi.org/10.1007/s00436-010-1945-4)
4. Kurkienė L, Parkas P, Sruoga A, Butkauskas D. Description of *Sarcocystis anasi* sp. nov. and *Sarcocystis albifronsi* sp. nov. in birds of the order Anseriformes. Parasitol Res. 2012;110:1043-1046. DOI: [10.1007/S00436-011-2588-9](https://doi.org/10.1007/S00436-011-2588-9)
5. Clubb SL, Frenkel JK. *Sarcocystis falcatula* of opossums: Transmission by cockroaches with fatal pulmonary disease in psittacine birds. J Parasitol. 1992;78:116-124. DOI: [10.2307/3283697](https://doi.org/10.2307/3283697)
6. Smith JH, Neill PG, Dillard EA, Box ED. Pathology of experimental *Sarcocystis falcatula* infections of canaries (*Serinus canarius*) and pigeons (*Columba livia*). J Parasitol. 1990;76:59-68. DOI: [10.2307/3282628](https://doi.org/10.2307/3282628)
7. Qui NH. Baker's yeast (*Saccharomyces cerevisiae*) and its application on poultry's production and health: A review. Iraqi J Vet Sci. 2023;37(1):213-221. DOI: [10.33899/ijvs.2022.132912.2146](https://doi.org/10.33899/ijvs.2022.132912.2146)
8. Villar D, Kramer M, Howard L, Hammond E, Gray C, Latimer K. Clinical presentation and pathology of Sarcocystosis in Psittaciform birds: 11 cases. Avian Dis. 2008;52:187-194. DOI: [10.1637/8104-090207-case](https://doi.org/10.1637/8104-090207-case)
9. Odening K. The present state of species – systematics in Sarcocystis Lankester, 1882 (Protista, Sporozoa, Coccidia). Syst Parasitol. 1998;41:209-233. DOI: [10.1023/A:1006090232343](https://doi.org/10.1023/A:1006090232343)
10. Ecco R, Luppi MM, Malta MC, Araujo MR, Guedes RM, Shivaprasad HL. An outbreak of Sarcocystosis in Psittacines and a pigeon in a zoological collection in Brazil. Avian Dis. 2008;52:706-710. DOI: [10.1637/8303-040408-case.1](https://doi.org/10.1637/8303-040408-case.1)
11. Olias P, Gruber AD, Heydorn AO, Kohls A, Mehlhorn H, Hafez HM, Lierz M. A novel Sarcocystis – associated encephalitis and myositis in racing pigeons (*Columba livia* f. dom.). Avian Pathol. 2009;38(2):121-128. DOI: [10.1080/03079450902737847](https://doi.org/10.1080/03079450902737847)
12. Zuo S, Sorensen SR, Kania PW, Buchmann K. *Sarcocystis rileyi* (Apicomplexa) in *Anas platyrhynchos* in Europe with a potential for spread. Int J Parasitol Parasit Wildl. 2021;15:270-275. DOI: [10.1016/j.ijppaw.2021.06.007](https://doi.org/10.1016/j.ijppaw.2021.06.007)
13. Latif B, Muslim A. Human and animal Sarcocystosis in Malaysia: A review. Asian Pac J Trop Biomed. 2016;6(11):982-988. DOI: [10.1016/j.apjtb.2016.09.003](https://doi.org/10.1016/j.apjtb.2016.09.003)
14. Mavi SA, Teimouri A, Mohebbali M, Yazdi MS, Shojae S, Rezaian M, Salimi M, Keshavarz H. Sarcocystis infection in beef and retail stores: A molecular microscopic study. Heliyon. 2020;(6)e04171. DOI: [10.1016/j.heliyon.2020.e04171](https://doi.org/10.1016/j.heliyon.2020.e04171)
15. Ahmed AM, Albakri HS. Phenotypic and genotypic identification of Eimeria species in backyard chicken in Nineveh governorate, Iraq. Iraqi J Vet Sci. 2021;35(2):41-46. DOI: [10.33899/ijvs.2021.130487.1834](https://doi.org/10.33899/ijvs.2021.130487.1834)

16. Saied MQ, Hameed HM. Biocetical role of nano and organic selenium on certain reproductive value of laying hen during force molting. *Iraqi J Vet Sci.* 2023;37(2):325-331. DOI: [10.33899/ijvs.2022.134401.2364](https://doi.org/10.33899/ijvs.2022.134401.2364)
17. Ngugu E, Butkauskas D, Prakas P. Investigations on *Sarcocystis* species and the leg muscles of the bird family Corvidae in Lithuania. *Protozool.* 2022;121:703-711. DOI: [10.1007/s00436-021-07409-z](https://doi.org/10.1007/s00436-021-07409-z)
18. Dakhil HG. Infection rate of *Sarcocystis* spp of the intermediate host in Iraq from 1999-2020. *NTU J Agric Vet Sci.* 2022;2(2):43-48. DOI: [10.56286/ntujavs.v2.2.228](https://doi.org/10.56286/ntujavs.v2.2.228)
19. El-Dakhly KM, Arafa WM, Hussein NM. Morphological and molecular identification of *Sarcocystis* sp. from the little grebe *Tachybaptus ruficollis* (Aves: Podicipediformes) for the first time in Egypt. *J Basic Appl Sci.* 2022;11(21). DOI: [10.1186/s43088-022-00205-3](https://doi.org/10.1186/s43088-022-00205-3)
20. Al-Saadi SA, Mehdi K, Ali H. Molecular identification of *Sarcocystis* species infection in sheep in Karbala governorate, Iraq. *Med Legal Update.* 2020;20(1):890-895. [\[available at\]](#)
21. Janregni Z, Salas-fajardo M, Purcon V, Lucas J. Prevalence and distribution pattern of *Sarcocystis* spp and slaughtered cattle from the Peruvian tropical Andes, Peru. *Vet Parasitol Reg Stud Rep.* 2024;48:100990. DOI: [10.1016/J.vprsr.2024.100990](https://doi.org/10.1016/J.vprsr.2024.100990)
22. Soulsby EL. Helminths, arthropods, protozoa of domesticated animals. 7<sup>th</sup> ed. London: Baillier; 1986. 430-431 pp.
23. Mohamed TA, Hussein SN, Shukur MS, Mohammad RA, Ali AA, Khalil LN. Survey on *Sarcocystis* infection in imported male cattle carcasses slaughtered at Duhok abattoir, Kurdistan region of Iraq. *Microb Biosyst.* 2020;5(1):119827. DOI: [10.21608/MB.2020.119827](https://doi.org/10.21608/MB.2020.119827)
24. Gareh A, Soliman M, Saleh A, Elgohary F, Elsherbiny H, Mohamed R, Elmahallawy E. Epidemiological and histological investigation of *Sarcocystis* spp in slaughtered dromedary camels (*Camelus dromedarius*) in Egypt. *Vet Sci.* 2020;7:162. DOI: [10.3390/vetsci7040162](https://doi.org/10.3390/vetsci7040162)
25. Dalimi AH, Mutamedi G, Paykari H. Detection of *Sarcocystis* spp of slaughtered sheep and Gazvinzarian slaughter house by molecular assay. *Int Syst Agric Sci Technol.* 2008;11:65-72. [\[available at\]](#)
26. Rahawi AM, Al-Tae SK, Ali FF, Altaey OY, Abdullah DA. Protective role of biosynthetic silver nanoparticles in broilers with aflatoxicosis through histopathological study of spleen. *Iraqi J Vet Sci.* 2024; 38(3):565-572. DOI: [10.33899/ijvs.2024.146024.3414](https://doi.org/10.33899/ijvs.2024.146024.3414)
27. Maty HN. Impact of sorbitol and l-carnitine on stimulating thyroid hormone, triiodothyronine, and adenosine triphosphate levels in broilers. *Iraqi J Vet Sci.* 2023;37(3):589-590. DOI: [10.33899/ijvs.2022.135305.2464](https://doi.org/10.33899/ijvs.2022.135305.2464)
28. Alrahal HH, Al-Tae SK, Sultan GA. I See Inside semi quantitatively analysis of nutritional disturbances lesions in the liver and breast muscle of broiler during the starter period. *Iraqi J Vet Sci.* 2024;38(3):485-492. DOI: [10.33899/ijvs.2024.145162.3358](https://doi.org/10.33899/ijvs.2024.145162.3358)
29. Morsi AI, Rafequ AM, Gharieb SA, Elkhayat ME. Isolation and molecular identification of multidrug-resistant *Pseudomonas aeruginosa* isolated from broiler chickens in Fayoum, Egypt. *Iraqi J Vet Sci.* 2024 ;38(4):809-816. DOI: [10.33899/ijvs.2024.149618.3656](https://doi.org/10.33899/ijvs.2024.149618.3656)
30. Mustafa MM, Zangana SA, Isa RH, Hassan WH. effect of herbal extracts in drinking water of layer quails on performance, egg quality, intestinal histology, and some serum biochemical parameters. *Mesopotamia J Agric.* 2024;52(1):135-150. DOI: [10.33899/mja.2024.143930.1283](https://doi.org/10.33899/mja.2024.143930.1283)
31. Ahmed AT, Batkowska J. Evaluating of Iraq and Polish feed additives in poultry feeding. *Mesopotamia J Agric.* 2023; 51(2):79-88. DOI: [10.33899/ma.grj.2023.140570.1241](https://doi.org/10.33899/ma.grj.2023.140570.1241)
32. Ibrahim FK, ALomari AM, Sabri MA. Production performance and genetic similarities in Ukrainian and local brown quail. *Mesopotamia J Agric.* 2023;51(4):59-71. DOI: [10.33899/mja.2023.144335.1290](https://doi.org/10.33899/mja.2023.144335.1290)
33. Ameen MH, Wahhab MA, Muhammad SS, Salih SA. Impact of mixed dietary vitamin e-selenium powder on reproductive hormones concentration of males and females in Japanese quail bird (*Coturnix coturnix japonica*). *Mesopotamia J Agric.* 2023;51(3):99-108. DOI: [10.33899/magrj.2023.149903.1233](https://doi.org/10.33899/magrj.2023.149903.1233)
34. Abdulah RL, Mousa YJ. Effects of hydrogen peroxide-induced oxidative stress on the plasma concentration and pharmacokinetics of ketorolac in chicks. *Iraqi J Vet Sci.* 2023;37(1):83-88. DOI: [10.33899/ijvs.2022.133592.2260](https://doi.org/10.33899/ijvs.2022.133592.2260)
35. Fadel MA, Mustafa KA. The anti-inflammatory effect of allopurinol and diclofenac in chicks model. *Iraqi J Vet Sci.* 2023;37(3):547-553. DOI: [10.33899/ijvs.2023.138108.2769](https://doi.org/10.33899/ijvs.2023.138108.2769)
36. Mac PA, Ibrahim TM, Buba DM, Airiohuodion PE, Ambu S. Prevalence of *Sarcocystis* species in meat of cattle, pigs and birds slaughtered in north central Nigeria. *J Vet Sci Med Diag.* 2018;7(5):2-6. [\[available at\]](#)
37. Faraj AA, Kawan MH. Detection of Sarcocystosis in some wild birds. *Iraqi J Vet Med.* 2012;3(2):65-70. [\[available at\]](#)
38. Costauzo G. *Sarcocystis* in American black ducks wintering in New Jersey. *J Wildl Dis.* 1990;26(3):387-389. DOI: [10.7589/0090-3558-26.3.387](https://doi.org/10.7589/0090-3558-26.3.387)
39. Vahedi NN, Salehi A, Razavi M, Masoumi M. Poultry carcasses investigation of parasitic *Sarcocystis* infection in native in Mazandaran (north part of Iran). *Animal Husb Dairy Vet Sci.* 2019;3:1-3 DOI: [10.15761/AHDV5.1000165](https://doi.org/10.15761/AHDV5.1000165)
40. Latif B, Vellayan S, Omar E, Abdullah S. *Sarcocystis* among wild captive and zoo animal in Malaysia. *Korean J Parasitol.* 2010;48(3):213-217. DOI: [10.3347/kjp.2010.48.3.213](https://doi.org/10.3347/kjp.2010.48.3.213)
41. Hu J, Zhang M, Tao J. The description of *Sarcocystis platyrhynchos* n. sp. (Apicomplexa: sarcocystidae) from domestic ducks *Anas platyrhynchos* (Anseriformes Anatidae) in China. *Parasit Vectors.* 2023;16(50). DOI: [10.1186/s13071-023-05656-w](https://doi.org/10.1186/s13071-023-05656-w)
42. Ali SA, Al-Tae SK, Sabaawy HB. Effect of antibiotic substitution with *Saccharomyces cerevisiae* and probiotic on hematic parameters and growth performance of broilers. *Iraqi J Vet Sci.* 2023;37(3):667-673. DOI: [10.33899/ijvs.2023.137187.264](https://doi.org/10.33899/ijvs.2023.137187.264)
43. Prakas P, Stankevičiūtė J, Švažas S, Juozaitytė-Ngugu E, Butkauskas D, Vaitkevičiūtė-Balčė R. *Sarcocystis* spp, Macrocyts infection in wildfowl species eastern Baltic region: Trends in prevalence in 2011-2022. *Anim.* 2023;13:2875. DOI: [10.3390/ani13182875](https://doi.org/10.3390/ani13182875)
44. Chen X, He Y, Lin Y, Olias P. Infections with *Sarcocystis wenzeli* are prevalent in the chickens of Yuunan province, China but not in the flocks of domesticated pigeons or ducks. *Exp Parasitol.* 2012;131(1):31-34. DOI: [10.1016/j.exppara.2012.02.022](https://doi.org/10.1016/j.exppara.2012.02.022)
45. Kalantari N, Khaksar M, Ghaffari S, Hamidekish SM. Molecular analysis of *Sarcocystis* spp. isolated from sheep (*Ovis aries*) in Babol area, Mazandaran province, northern Iran. *Iranian J Parasitol.* 2016;11(1):73. [\[available at\]](#)
46. Hussein SN, Ibrahim AA, Shukur MS. Histopathology and molecular identification of *Sarcocystis* species forming macrocyts in slaughtered sheep and goats of Duhok, Iraq. *Vet Res Forum.* 2023;14(8):415-422. DOI: [10.30466/vrf.2023.559514.3575](https://doi.org/10.30466/vrf.2023.559514.3575)
47. Portella LP, Fernandes FD, Rodrigues FD, Minuzzi CE, Sangioni LA, Flores MM, Vogal FS. Macroscopic, histological, and molecular aspects of *Sarcocystis* spp. infection in tissues of cattle and sheep. *Brazil J Vet Parasitol.* 2021;30(3):e003621. DOI: [10.1590/s1984-29612021050](https://doi.org/10.1590/s1984-29612021050)
48. Farhangpazhouh F, Yakhchali M, Farshid AA, Rezaei H. Prevalence and pathologic changes due to *Sarcocystis* species in naturally infected sheep in Urmia city, Iran *J Zoonotic Dis.* 2020;4(3):54-60. DOI: [10.22034/jzd.2020.11208](https://doi.org/10.22034/jzd.2020.11208)
49. Swar SO, Shnawa BH. Prevalence and histopathology study of *Sarcocystis* species in naturally infected cattle in Soran city, Erbil Iraq. *Adv Res Stud J.* 2022;13(4):1-13. [\[available at\]](#)
50. Vangeel L. Bovine *Sarcocystis* species and their role in bovine eosinophilic myositis [Ph.D. dissertation]. Belgium, Ghend: Ghent University; 2012.
51. JyothiSree C, Venu R, Samatha V, Malakondaiah P, Rayulu VC. Prevalence and microscopic studies of *Sarcocystis* infection in naturally infected water buffaloes (*Bubalus bubalis*) of Andhra Pradesh. *J Parasit Dis.* 2017;41:476-82. DOI: [10.1007/s12639-016-0832-z](https://doi.org/10.1007/s12639-016-0832-z)
52. Huang ZM, Ye YL, Zhang HZ, Deng SS, Tao dd, Hu JJ. Morphological and molecular characterizations of *Sarcocystis miescheriana* and *Sarcocystis suihominis* in domestic pigs (*Sus scrofa*) in China. *Parasitol Res.* 2019;118:3491-6. DOI: [10.1007/s00436-019-06521-5](https://doi.org/10.1007/s00436-019-06521-5)

53. EL-Kady AM, Hussein NM, Hassan AA. First molecular characterization of *Sarcocystis* spp. in cattle and Qena governorate, Upper Egypt. J Parasitol Dis. 2018;42(1):114-121. DOI: [10.1007/s12639-017-0974-7](https://doi.org/10.1007/s12639-017-0974-7)
54. Pan D, Ma C, Huang Z, Ye Y, Zeng H, Deng S, Hu D, Toa D. Morphological and molecular Characterization of *Sarcocystis wenzeli* and chickens (*Gallus gallus*) in China. Parasit Vectors. 2020;13:512. DOI: [10.1186/s13071-020-04390-x](https://doi.org/10.1186/s13071-020-04390-x)

## الكشف عن طفيلي الحويصلات الصنوبرية في الدجاج المستورد المجمد والمحلي المذبوح بتقنيات مختلفة في مدينة الموصل

نادية حامد محمد، ليان ياسين خليل و إيمان غانم سليمان

فرع الأحياء المجهرية، كلية الطب البيطري، جامعة الموصل، الموصل، العراق

### الخلاصة

أظهرت نتائج الدراسة الحالية تشخيص طفيلي الحويصلات الصنوبرية العياني والمجهري في الدواجن المذبوحة والدجاج المجمد المستورد. إذ بلغت نسبة تشخيص الأكياس العيانية والمجهرية لطفيلي الحويصلات الصنوبرية في الدجاج المذبوح المصاب طبيعياً ٢٤,٦ و ٤٠%. في حين بلغت نسبة تشخيص الأكياس العيانية والمجهرية لطفيلي الحويصلات الصنوبرية في الدجاج المجمد المستورد ٥١,٨ و ٦٦,٧%. أظهرت نسبة الخمج بالأكياس العيانية في العضلات الصدرية أعلى نسبة ٥٠ و ٦٠,٩%، في حين كانت أقل نسبه في الذراع ٨,٧-٠%. في عضلات الدجاج المذبوح والمستورد المجمد على التوالي. كما وجد في الفحص المجهرى أن اختبار هضم البيسين سجل أعلى نسبه وبلغ ٤٠%، ٦٦,٧% في الدجاج المذبوح والمستورد المجمد. أظهرت نتائج الفحص النسجي المرضي وجود الحويصلات داخل النسيج الخلالي للعضلة مع وجود نخر تخثري ونمة مع خلايا التهابية واحتقان مع سماكة الأوعية الدموية. تم في دراستنا تأكيد تشخيص طفيلي الحويصلات الصنوبرية في الدجاج المجمد المحلي والمستورد عن طريق التحليل الجزيئي وباستخدام بادئات محددة للجنس بوزن جزيئي ٧٠٠ زوجاً قاعدياً ووجدنا عزلتين محليتين جديدتين تعود لطفيلي الحويصلات الصنوبرية. تعد هذه الدراسة الحالية هي الأولى لتشخيص انتشار طفيلي الحويصلات الصنوبرية في الدجاج المجمد المحلي والمستورد في مدينة الموصل بالاعتماد على الشكل والطرق الجزيئية.