

A CASE OF LEFT VENTRICULAR HYDATID CYST**Hamid Abdul Wahab*, Sarkis K Strak****

*FICMS (Med), FICMS (CA/D), Basrah Teaching Hospital. **(FRCP) Department of Medicine, College of Medicine, University of Basrah.

Introduction

Hydatid disease with cysts caused by the tape worm *Echinococcus granulosus*, is endemic in cattle-raising areas of the world including Middle East. The parasite usually settles and forms cyst in liver and lung with a frequency of 60% and 20-30% respectively¹.

Cardiac involvement is infrequent accounting for 0.2 to 2%². It is caused by the invasion to the myocardium via coronary arteries and may be either confined solely to the heart or associated with involvement of other organs³. The left ventricular wall is the most frequent site, but the interventricular septum, right ventricle, and left or right atrium may also be involved⁴. Major complications of cardiac hydatid disease result from rupture of the cyst either into the heart or pericardium and death may occur subsequent to an anaphylactic shock, cardiac tamponade, and systemic or pulmonary embolization. When echinococcosis is diagnosed, surgery is the treatment of choice for even asymptomatic cases due to the risk for cystic rupture⁵.

Case Report

A 40-year-old female from Amara province presented with vague recurrent retrosternal chest pain and occasional palpitation. She had no previous history of heart disease or rheumatic fever. Cardiovascular, abdominal, chest and CNS examination revealed no abnormal findings. Her

electrocardiogram showed T wave inversion in anterior chest lead for which she was prescribed antianginal drugs in Amara but with no response. Her chest x-ray, haematological and biochemical tests were normal.

Transthoracic two-dimensional echocardiography showed a big 3.70cm x 2.25 cystic mass occupying 1/3 of left ventricular cavity with a thick capsule occupying mostly the apical cavity. Tissue mode revealed no velocity of flow inside the cyst.

The patient underwent surgery through median sternotomy in Baghdad Cardiac surgical center. Standard cardiopulmonary bypass techniques were used with moderate hypothermic and cardioplegic arrest.

The patient was discharged on the 7th post operative day and treated with albendazole 400 mg. B.d.

At two months follow up, the patient was asymptomatic. Two dimensional transthoracic echocardiography showed no signs of cystic formation.,

Discussion

Cardiac hydatid disease is vary rare. Occurring in 0.2-2% of patient with hydatid disease. Cardiac hydatid cysts develop in many parts of the heart such as left ventricle (55-75%), right ventricle (13-18%) interventricular septum (5-13%), right atrium (2-4%) and left atrium (8%)^{6,7}. Several hypothesis have been proposed for the predilection for left ventricular location, including dominance of the

left coronary artery, better conditions of the left ventricular myocardial mass for parasitic development and different pressure regimens⁸. Although hydatid cysts are more frequently located in the left ventricle, right ventricular hydatid cysts have a higher propensity to rupture⁹.

Cardiac infestation can be asymptomatic or may present with clinical findings depending upon the size, location, and number of cysts, mild, recurrent, non specific chest pain is the most common complaint¹⁰.

The diagnosis of a cardiac cyst is probable in patient with history of echinococcosis in another organ. In the absence of any diagnostic sign, routine investigations by specific cardiac imaging procedures are necessary.

Electrocardiographic abnormalities are non specific such as T-wave inversion, ST-depression, premature ventricular beats, incomplete or complete bundle brunch block, and superaventricular tachycardia are present in more than 80% of patients¹¹.

The serologic diagnosis is not reliable, although it has a high specificity, but sensitivity is low in patients with intact cysts as the concentration of the antibody in the serum is very low until the cyst leaks¹⁰.

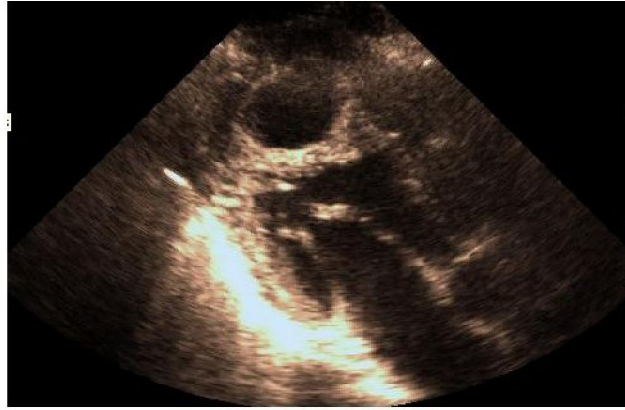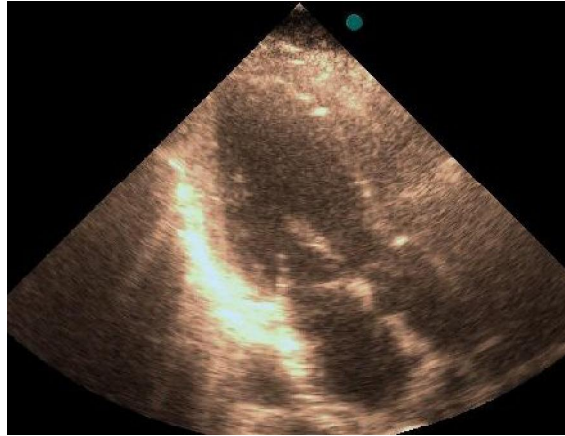
Two-dimensional echocardiograph is the best diagnostic procedure. On echocardiography, a unilocular cyst with well-defined margins and internal trabeculation corresponding to daughter cyst is diagnostic of a hydatid cyst. Movement of cyst contents

(hydatid sand) seen on changing the patients posture was considered to be characteristic of hydatid cysts¹². Transesophageal echocardiography provides details of the cyst¹³. Computed tomography and magnetic resonance imaging may provide valuable information. Recently 67 Ga scintigraphy has been used to detect the lesion of Echinococcosis multilocularis infection¹⁴.

Surgical excision is the definitive method of treatment for cardiac hydatid cysts, even for asymptomatic patients in order to prevent rupture. However, surgical intervention may result in serious complications¹⁵.

Medical treatment with Albendazole results in disappearance of extracardiac hydatid cyst in up to 48% and reduction in size in 24%. However, the specific efficacy of Albendazole against cardiac hydatid cysts has not been established. Antihelmintics have been recommended in inoperable cases or as adjuvant therapy¹⁶ when there is risk for dissemination.

Albendazole is a benzimidazole and most promising agent for the treatment of echinococcosis at present. The recommended standard therapeutic regimen is 4 or 5 cycles of 10 mg/kg/day for 30 days with rest period of 2 weeks between cycles. Most of the cysticidal activity of Albendazole seems to occur within 2-3 months of treatment and if the cyst does not regress after two months of treatment further treatment is unlikely to help^{17,18}.

Preoperative picture**Postoperative picture****References**

1. Bhatia G. Echinococcus. *Semin Respir Infect* 1997;12:171-87.
2. Maffei GR, Petrucci O, Carandina R et al. Cardiac echinococcosis. *Circulation* 2000;101:1352-4.
3. McManus DP, Zhang W, Li J, Bartley PB. Echinococcosis. *Lancet* 2003;362:1295-304.
4. Kardaras F, Kardara D, Tselikos D, Tsoukas A, Exadactylos N, Anagnostopoulou M, et al. Fifteen year surveillance of echinococcal heart disease from a referral hospital in Greece. *Eur Heart J* 1996;17:1265-70.
5. Salih OK, Celik SK, Topcuoglu MS, Kisacikoglu B, Tokcan A. Surgical treatment of hydatid cysts of the heart: a report of 3 cases and a review of the literature. *Can J Surg* 1998;41:321-7.
6. Sensoz Y, Ozkokeli M, Ates M, Akcar M. Right ventricle hydatid cyst requiring tricuspid valve excision. *Int J Cardiol* 2005;101:339-41.
7. Kunt AS, Aydin S, Demir D, Selli C, Andac MH. Left ventricle wall hydatid cyst. *Kalp Damar Cer Derg* 2006;14:325-7.
8. Thameur H, Abdelmoula S, Chenik S, Bey M, Ziadi M, Mestiri T, et al. Cardiopericardial hydatid cysts. *World J Surg* 2001;25:58-67.
9. De Paulis R, Seddio F, Colagrande L, Polisca P, Chiariello L. Cardiac echinococcosis causing coronary artery disease. *Ann Thorac Surg* 1999;67:1791-3.
10. Gulati G, Goyal NK, Kothari SS, Sharma S, Bisoi AK. Pericardial Hydatid Cyst. *Indian Heart J* 2002;54(4):437-8.
11. Bashour TT, Alali AR, Mason DT, Saalouke M. Echinococcosis of the heart: clinical and echocardiographic features in 19 patients. *Am Heart J* 1996;132:1028-30.
12. SB Siwach, VK Katyal and Jagdish. Cardiac echinococcosis--a rare echocardiographic diagnosis. *Heart* 1997;77:378-379.
13. Tufan Tükek, Şeref Demirel, Dursun Atılgan, Ertan Onursal, Ferruh Korkut. Kardiak kist hidatik tanı ve tedavisinde transözofageal ekokardiyografinin önemi: iki vaka nedeni ile literatürün gözden geçirilmesi. *Türk Kard Derg* 2000;28:131-3.
14. Inceboz T, Mavi A, Copa Kaya G et al. The ability of 67 Ga scintigraphy to detect the lesion of Echinococcosis multilocularis infection. *Ann Nucl Med* 2006 Jun;20(5):345-8.
15. Kaplan M, Demirtas M, Cimen S, Ozler A. Cardiac hydatid cysts with intracavitary expansion. *Ann Thorac Surg* 2001;71:1587-90.
16. Simeunovic D, Seferovic PM, Ristic AD, Petrovic P, Maisch B. Pericardial cysts: incidence, clinical presentations and treatment. In: Seferovic PM, Spodick DH, Maisch B, editors. *Pericardiology: contemporary answers to continuing challenges*. Belgrade: Science Publishers; 2000; p.203-12.
17. Murat Ozdemir, Erdem Diker, Sinam Aydogdu, Siber Goksel. Complete heart block caused by cardiac echinococcosis and successfully treated with albendazole. *Heart*. 1997 Jan; 77(1):84-5.
18. Oliviero U, Scordino F, Scherillo G et al. Myocardial ischemia caused by an hydatid cyst of the interventricular septum successfully treated with albendazole. *Ital heart J* 2000;1(6):431-4.