
**DIGITAL PHOTOGRAPHY IN THORACIC AND CARDIO-
VASCULAR SURGERY****Abdulsalam Y Taha* & Amanj Kamal#**

*Professor and Head of Department of Thoracic & Cardiovascular Surgery, College of Medicine, University of Sulaimania, IRAQ, E-mail:salamyt_1963@hotmail.com. #MB,ChB, Senior House Officer, Sulaimania Teaching Hospital, IRAQ.

Digital photography has become a practical alternative to film photography for documentation, communication and education in medical practice. We present our experience at the Department of Thoracic and Cardiovascular Surgery/Sulaimania Teaching Hospital in digital photography. As an excellent method of medical documentation, the digital camera is recommended to be available in the ward, operation theatre and bronchoscopy unit.

Photography has long been used for medical documentation. The 35- mm single lens reflex camera has been the traditional device for photo documentation in surgical practice. The widespread availability of computer hard and software, digital cameras and the internet has enhanced the advantages and ease of using digital photography¹.

Digital photography has become a practical alternative to film photography for documentation, communication and education in medical practice². The department of thoracic and cardiovascular surgery in Sulaimania Teaching Hospital was established in November 2003.

Since the establishment of our Department in November 2003, a large number of patients with varieties of elective and emergent conditions were admitted to and managed in the department of thoracic and cardiovascular surgery in Sulaimania Teaching Hospital. Whenever possible,

documentation was carried out using a Kodak digital zoom 6440 camera. Photography was used in the bronchoscopy unit, ward and the operation theatre.

Digital photography and flexible bronchoscopy: an increasing number of patients with different thoracic lesions were bronchoscoped using a flexible bronchoscope (Olympus BF Type 20). A Kodak digital zoom 6440 camera held by an assistant is brought into contact with the proximal end of the bronchoscope whenever an interesting abnormality is seen and a still photograph and sometimes a video record is obtained. The photos are stored in the computer and edited if necessary and used for documentation, research and teaching.

Digital photography in the ward: The digital camera was also used to document important physical signs pre and post-operatively.

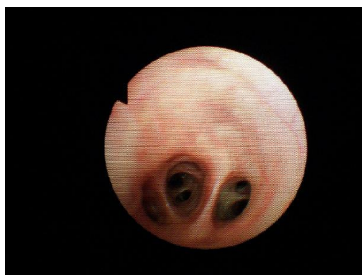
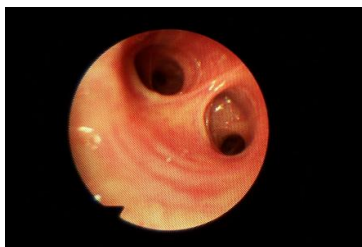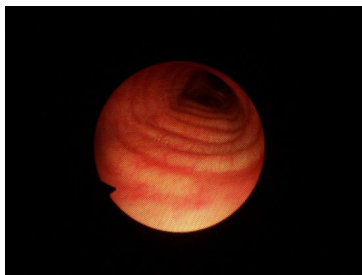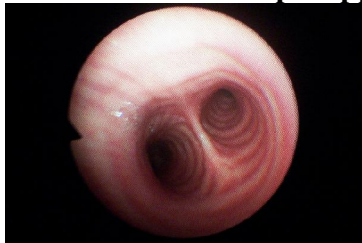Intra-operative digital photography: still photographs and sometimes a video record of certain operative procedures were similarly obtained.

A large pool of interesting digital photographs and video records were obtained since 2003. These photographs were an excellent teaching aid for both under and postgraduate students. They were used in many presentations in local and national medical conferences and were really exciting. Reports of rare cases were nicely demonstrated using

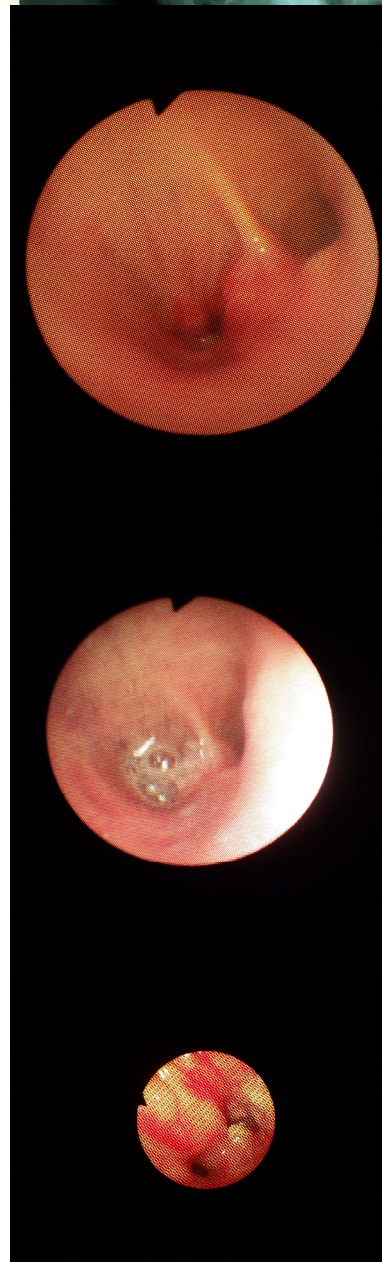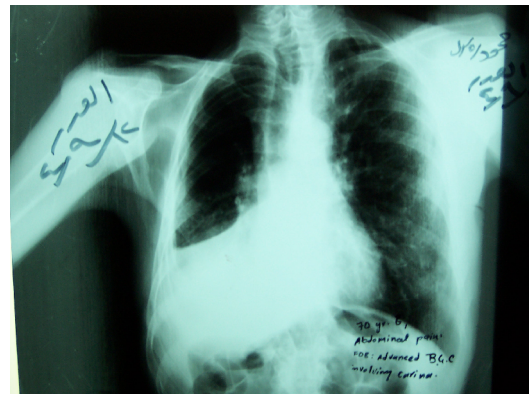
this technique. Several clinical articles were written in our department which included digital photographs of the relevant patients. Publication in medical journals was possible by online uploading. Communication with colleagues in the same specialty was possible by sharing these photos through the Internet.

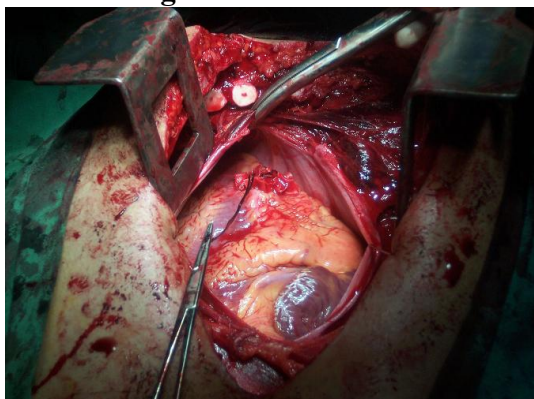
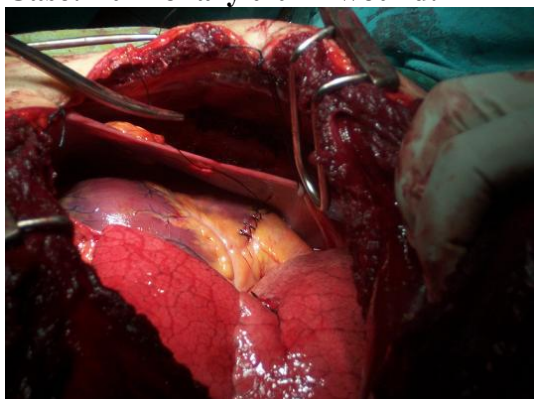
Selected photographs:

Normal bronchoscopic appearance:



Case: Right-sided bronchogenic carcinoma.



Case: Right ventricular wound.**Case: Pulmonary trunk wound.****Discussion**

The digital camera has the advantages of producing instant photos of high quality without a film. The image quality has reached that of conventionally taken photography, and for most applications, the digital origin of the photo is no longer discernable³.

Digital cameras can be used to document preoperative and postoperative condition, intra-operative findings and image studies. Images may be immediately viewed on the liquid crystal display (LCD) screen of the camera and reshot if necessary².

Photography image files may be stored in the camera in a floppy diskette, compact flash card and transferred to a computer. The images may be manipulated using photo-editing software programs and incorporated into digital presentations.

The digital photographs may be transmitted to others using e-mail and Internet web sites².

Using digital operative records along with digital photography, surgeons can document their procedures more accurately and efficiently than by the conventional method (hand-writing). A complete digital operative record is not only accurate but also time-saving⁴.

We here highlights the usefulness of digital photography in the practice of thoracic and cardiovascular surgery.

From the very beginning, we have realized the importance of photographic medical documentations for many reasons:

1. Varieties of elective and emergent surgical conditions were encountered. Many of them were interesting or rare; thus proper documentation was worthy.
2. Digital photographs were used as an excellent teaching aid for both under and postgraduate students. Many lectures were prepared from these photographs.
3. These photos were used in many presentations in local and national medical conferences and were really exciting.
4. Rare case reports were nicely demonstrated using this technique.
5. Medico-legal discussions were common about cases like a severely injured limb which requires a primary amputation for irreversible ischemia. It was very difficult sometimes to describe such an injury using the conventional method of words. However, a digital photograph obtained preoperatively and /or intra-operatively could save words and efforts and protect the surgeon during any medico-legal discussion.
6. Communication with colleagues in the same specialty was possible by sharing these photos through the Internet.

7. Several clinical articles were written in our department which included digital photographs of the relevant patients.
8. Publication in medical journals was possible by online uploading.
9. Shortly after establishing our department, a unit of bronchoesophagoscopy was opened. The flexible fiber optic bronchoscope which we have initially used was a conventional bronchoscope (Olympus BF Type 20: without a video). We have solved the problem of endoscopic documentation by using a digital camera (Kodak). Still photographs and sometimes a digital record of reasonably good quality were obtained.

In conclusion, Digital photography is an excellent method of medical documentation. It is an indispensable

technique for the busy surgeon indulged in clinical teaching, research and practice. In comparison with conventional photography, the digital version is cheaper, does not use films, and provides us with instant pictures of good resolution which can be saved in the computer or storage media, sent to colleagues and modified by software if necessary.

It is recommended that a digital camera be available in the ward or in the clinic for documentation of interesting physical signs and photography of imaging studies. It should also be present in the operation theatre for intra-operative still photography and video record of operative procedures.

It should also be available in the bronchoscopy unit if no video-bronchoscope is present for documentation of important bronchoscopic findings.

References

1. Kokoska,-M-S; Thomas,-J-P. 35-mm and digital photography for the facial plastic surgeon. *Facial- Plast- Surg.* 2000 Feb, 8 (1): 35-44, viii
2. Talmor,-M .Digital photography in orthopaedic surgery. *Plast- Reconstr- Surg.* 2001 Mar; 107 (3): 896-7
3. Bengel,-W. Digital photography in the dental practice- an overview (II). *Int-J- Comput- Dent.* 2000 May; 3 (2): 121-32
4. Houkin,-K; Kuroda,-S; Abe,-H. Operative record using intra-operative digital data in neurosurgery. *Acta- Neurochir-(Wien).* 2000; 142 (8): 913-9.