

ABSTRACT

Background: Calcaneus is a spongy cancellous bone with rich blood supply, its fracture heals more rapidly providing no occurrence of infection and soft tissue injury around, no gross malposition of fragments. The associated pain leads to a major impairment in life quality. The aim of treatment for calcaneal fractures is the decrease of pain and rebuilding of walking ability for patients with normal foot shape and the ability to wear normal foot wear. To reduce complications, a minimally invasive technique for the treatment of displaced intra-articular fractures of the calcaneus was preferred to use. The purpose of this study was to determine whether the closed reduction and percutaneous K. wire fixation of displaced intra-articular calcaneal fractures results in better functional outcome at a minimum one year follow up after the injury compared with those after non-operative management.

Methods: One hundred and eleven displaced closed intra-articular calcaneal fracture in 105 patients (six were bilateral) were seen at the orthopedic department of Al-Kindy teaching hospital and Shaikh Zaid hospital, only 45 cases included in this study and prospectively evaluated with an average follow-up time of minimum of one year (1–3years follow-up). For radiographic evaluation, plain radiographs

and CT scans were obtained. The Maryland Foot Score was used for clinical estimate. Sanders type II, III and IV fractures were diagnosed.

Results: The incidence of subtalar arthritis was correlated with the severity of fracture. Böhler's angle was restored in 70.1% (47 of 67) of the cases. The majority (77.7%) of patients were content with their treatment result. The rate of significant complications was 6.5%.

Discussion: Percutaneous K. wire fixation of displaced intra-articular calcaneal fractures presented minimally invasive technique which showed comparable results with a low rate of serious complications and is a viable alternative for the treatment of intra-articular, dislocated calcaneal fractures.

Conclusions: the functional results after K. wires fixation of displaced intra-articular calcaneal fractures were better than those after non-operative care.

Key words : Displaced calcaneal fracture, K. wires fixation, Bohler's angle.

Corresponding Author: Dr. Mohammed Sh. Al-Edanni

Place : Assistant Professor /Al-Kindy College of Medicine

E mail: orthomohammed1970@yahoo.com

Received at : 22/1/2019

Accepted at :4/3/2019

Introduction

A fracture of the calcaneus permitted healing in an unsuitable anatomical location leads to static and dynamic faults of the whole foot with resulting partial load bearing capacity and walking ability^[1, 2]. The related pain leads to a important impairment in the life quality. The objective of treatment for calcaneal fractures is the decrease of pain and return of walking ability for patients with normal foot shape and the ability to dress normal footwear. At present, there are numerous operative procedures for the treatment of calcaneal fractures.^[3-10]

Controversy remains with respect to whether displaced intra-articular calcaneal fractures should be treated operatively or conservatively^[11-15]. Historically, displaced intra-articular calcaneal fractures were treated conservatively, as predictable operative reduction and fixation were not possible^[12, 13, 16]. Operative reduction became more standard as fracture care improved^[17-20]. Reviews on this subject, however, have failed to demonstrate unquestionable superior results of a single approach to the treatment of displaced intra-articular calcaneal fractures^[15,19,21-23]. Historical cohort studies^[14,24-26] have suggested that open and closed treatment

provide nearly equal results. Kundel et al.^[25] pointed out that gait may be somewhat superior after surgical treatment. A radiographic review²⁶ demonstrated little association between treatment and outcome but showed a high prevalence of hardware in the subtalar joint after surgery.

Few prospective, randomized trials have been done in this field of orthopedic surgery. Parmar et al.^[27] in a study of fifty six patients who had been randomized by date of birth to either operative or conservative care, confirmed that there was no difference between the groups at one year of follow-up. In a study by O'Farrell et al.^[28] twelve patients were allocated, without randomization, to operative care and twelve were allocated to conservative care. After fifteen months of follow-up, the patients who had been treated operatively had returned to work faster and walked improved than those who had been managed conservatively.

In a meta-analysis published in 2000, Randle et al. specified that "there is a tendency for surgically treated patients to have better outcomes; however, the strength of evidence for recommending operative treatment is weak." They concluded that, before a strong approval could be made for operative treatment, a randomized trial with controls and validated outcomes was needed^[29].

The aim of the study

Evaluate the clinical and radiographic results of our minimally invasive surgical treatment (percutaneous K. wire fixation) of intra-articular fractures of the calcaneus at 1-3 years postoperatively follow up and compare with the results of conservatively treated cases.

Methods

Between January 2015 and January 2018 , 111 displaced closed intra-articular calcaneal fractures in 105 patients (six were bilateral) were seen at the orthopedic department of Al-Kindy teaching hospital and Shaih Zaid hospital , only 45 cases included in this study. The patients were divided into two groups. Group A (17 cases 37.8%) were treated by closed reduction and percutaneous K. Wires fixation under fluoroscope screen and cast splint and group B (28 cases 62.2%) were treated by MUA manipulation under anesthesia and below knee POP (Plaster of Paris) .A written informed consent was taken from each study participant . Preoperative CT scan for classification and preoperative planning.

Inclusion criteria including:

1. Sander's type II, III and IV fractures.
2. Closed fractures.
3. Recent fractures.
4. Non-pathologic origin.

Exclusion criteria including:

1. Sander's Type I fracture.
2. Neglected fractures.
3. Severe comminution.
4. Infected blisters.

Patients whom were excluded from the study is listed in table 1

All patients in both groups had been subjected to complete investigation for anesthetic purposes and in group A we fixed the fracture after reduction under screen by multiple K. wire and supported the foot by posterior back slab below knee (Fig. 1), while in group B we stabilize the fracture after reduction under fluoroscope screen by back slab initially below knee then change to full Plaster of Paris cast below knee after 10-14 days (Fig. 2) .

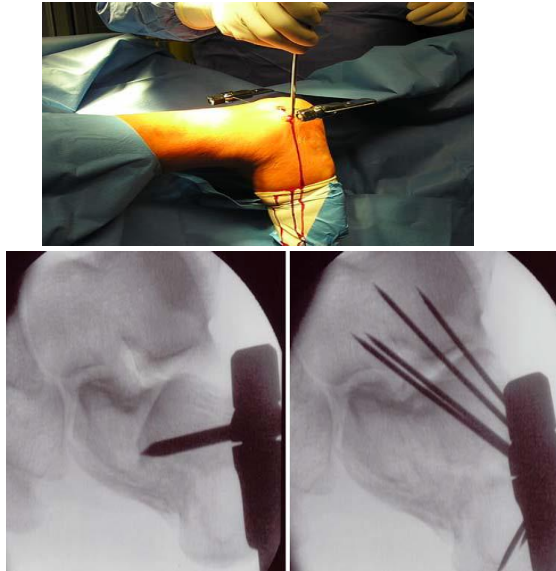
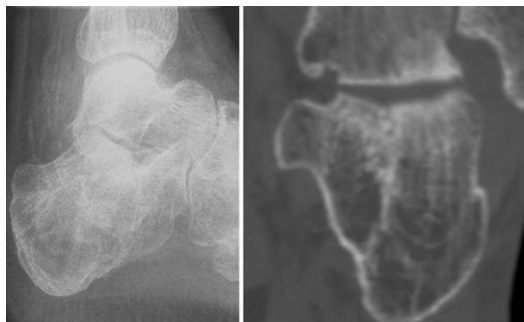


Fig. 1 The Steinmann pin is placed into the dorso-lateral calcaneus. Intraoperative lateral radiograph of a dislocated calcaneal fracture before and after reduction the fragments are fixed with percutaneous Kirschner wires

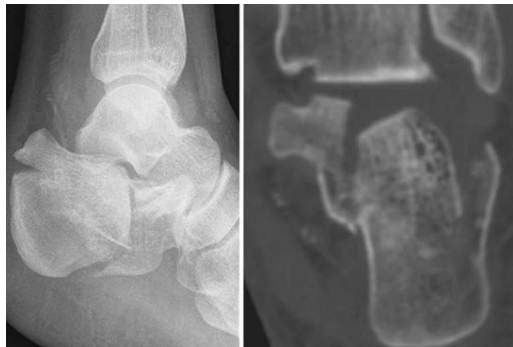

Fig. 2 : Pre and post reduction of displaced intraarticular calcaneal fracture



We follow up all patients initially 14days post reduction, 6weeks and 3 months by X-ray, and cast and K-wires had been removed. Full range of motion exercises of

ankle and subtalar joints, partial weight bearing and physiotherapy started 12weeks post-operatively. Functional assessment of our patients included:

1. Alignment (measurement of Bohler angle): in coronal plane . varus and valgus alignment of the heel , usually by radiology. Fig 3

2. Rate of union: by clinical examination. Lack of pain and tenderness and movement on stressing the fracture site, radiologically by absence of fracture line and smoothing of articular surface.

3. Function: determined by assessment of pain, movement possible at the subtalar and other tarsal joints including the ankle joints Maryland Foot Score [30] and is graded as

- Grade 1—pain with total restriction of all activities
- Grade 2— less pain with total restriction of daily activities
- Grade 3— restriction permitting daily activities with some difficulties
- Grade 4— minimal restriction not impeding daily activities
- Grade 5— no pain.

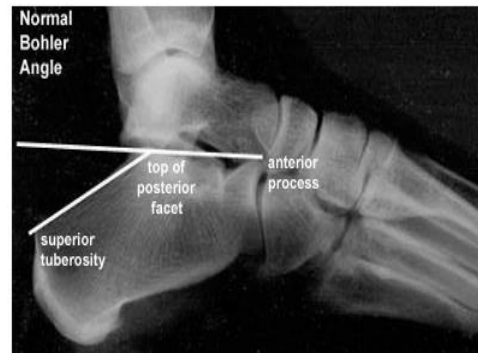


Fig. 3 : Bohler angle

Results

We treated 45 patients with closed displaced intra-articular calcaneal fracture at Al-kindy teaching hospital and we found that; The left side was more involved (28 cases 62.2%) , than right foot (17 cases 37.8%) .tab. 2

In fourteen patients (31.3%) got work injury and in 31 patients (68.9%) got fall

from height. Majority of the patients had moderate to heavy work 29 out of 45 cases (64.5%) tab 2

Most age group involved was (30-39) years old about (62.2%) as shown in tab 2 below

Female were less affected than males in such type of trauma. The two fragment of the fracture calcaneum is most common type of fracture 21 cases (46.7%). tab 3

In patients treated conservatively (17 out of 28 cases) started weight bearing at 12 weeks , six patients started weight bearing at 16 weeks , three patients at 18 weeks , and only two patients at 22 weeks . Bohler angle measurement in those treated conservatively was listed in table 4

In patients treated by percutaneous K. wire fixation , 14 patients started weight

bearing at 12 weeks , and three patients started weight bearing at 16 weeks . Bohler angle measurement pre and post percutaneous K. wire fixation was listed in table 4

The quality of the reduction fragments assessed according to Bohler angle measurement per operatively X-ray screen as in tab 5

In 40 weeks of follow up we faced different types of problems and complications, table 6 shows some of these complications

Last visit assessment for all patient was at 40 weeks and patient were assessed according to pain and limitation of movements and the results was listed in table 7

Table 1: Cases excluded in the study

Cases	No. of cases
Highly comminuted	22
Below 18 years old	3
Refuse treatment	13
Lost follow up	22
Fracture- dislocation	4
Above 60 years old	2

Table 2: Site of injured foot, Type of work and age group

Site	No.	Type of work	No.	Age	No.
Left	28 (62.2%)	Heavy work	17 (37.8%)	20-29 years	11 (24.5%)
		Moderate	12 (26.6%)	30-39 years	28 (62.2%)
Right	17 (37.8%)	Light	16 (35.6%)	40-49 years	6 (13.3%)
Total	45		45		45

Table 3 : Number of cases according with number of fragments

No. of fragment	No. of cases	Percentage
2 pieces	21	46.7%
3 pieces	9	20%
Crushed articular facet with depression	15	33.3%

Table 4: Bohler angle in both groups

Groups	No. of cases	At day of injury	After K. wire fixation
A	3	0°	30°
	4	12°	30°
	4	16°	24°
	6	8°	24°
Total no. 17			
B	2	8o	18o
	4	12o	22o
	5	16o	22o
	6	18o	18o
	5	20o	22o
	6	24o	22o
Total no. 28			

Table 5: Quality of Bohler angle reduction

Quality of reduction	Group A No.	Group A %	Group B No.	Group B %
Very good anatomical reduction	11	64.7	12	42.9
Step – off 1 mm	2	11.8	10	35.7
less degree of comminution with depression	6	23.5	6	21.4

Table 6: Shows the complications

Complications	conservatively	%	K. wire	%
Pain	8	28.6	5	29.4
Stiffness	4	14.3	2	11.8
Loss of reduction	4	14.3	0	0
Osteopenia	8	28.6	6	35.3
Infection	0	0	2	11.8
Residual varus and valgus	12	42.9	2	11.8

Table 7: Distribution of patients according to functional grade

Grade	Group A No. 17	Group A %	Group B No.28	Group B %
I	3	17.7	3	10.7
II	4	23.5	6	21.4
III	4	23.5	10	35.7
IV	4	23.5	5	17.9
V	2	11.8	4	14.3

Discussion

Calcaneus is a spongy cancellous bone with rich blood supply, its fracture heal more rapidly providing no occurrence of infection and soft tissue injury around, no gross malposition of fragments.

Calcaneus has an important role in standing and walking which starts with heel strike phase so great care and attention should be applied to its fracture and its articular facet.

Still there is a considerable divergence of opinions in dealing with articular facet fractures of calcaneus.

To correct distortions of the calcaneus, spare the soft tissue and decrease the complication rate, indirect and less aggressive reduction and fixation techniques to treat calcaneal fractures have been advanced [31-39]. Also techniques with percutaneous reduction and internal K-wire fixation [31, 35, 36, 38] percutaneous reduction techniques with external fixation are described in the literature [33, 34, 37, 39]. In our study we have closed reduction and internal fixation techniques by K. wire to create a minimally invasive technique.

Patients whom got intra-articular calcaneal fractures usually have pain and swelling as the primary symptoms. Another complaint is inability to put the foot on the ground and sometime ecchymosis of the forefoot. The severity of the trauma can lead to displacement of the pieces resulted from the injury as well as comminution of the articular surface.

In our study small percentage of female involvement in this type of injury doesn't mean it is uncommon in the female because it is mainly relates the trauma which from it result the fracture and probably it is due to the restricted participation of women in active and heavy work in our country.

About two thirds of patients are occur in active age group (30-39 years) 28 patients out of 45 (62.2%) with a mean age of 35 years .and this is similar to results of Sanders and Gregory 2010 .^[40]

Swelling of the foot and pain was the most common associated symptoms with intra-articular calcaneal fractures. We faced moderate pain in 20 patients (44.5%) in our patients.

During our study we got acceptable results in that patient treated conservatively regarding pain and stiffness but we got loss of reduction in seven patients after weight bearing. Thordrson et al ^[41] stated

that conservative treatment of intra-articular calcaneal fracture frequently lead to sever functional impairments with considerable disability with higher rate (5.5) times more need for later joint fusion. It has been noticed that patients whom got surgery were more satisfied about their foot than those whom were treated non-operatively (they were worried about their foot and more optimistic about future). Three patients in those treated non-operatively got varus heel and 6 of them get valgus, while only one patient got varus heel in those treated operatively. Micheal et al ^[42] reported that non operative treatment for displaced intra-articular calcaneal fractures may result in malunion affecting function of both ankle and subtalar joints , and reported that conservative treatment almost need later surgery like lateral wall exostectomy or calcaneal osteotomy or subtalar bone block arthrodesis .

We avoided open surgery in these comminuted fractures because of difficulty of surgery and reduction, instead we use percutaneous k wire fixation after reduction under screen , however Mathias Speck^[43] state in his study that anatomical reconstruction of intra-articular calcaneal fractures with an acceptable rate of subsequently need for subtalar fusion , in the late ; subtalar fusion is much easier and safer to perform.

On the other side we advise and select another group of this type of fracture for surgery to correct Bohler angle as apriority for the operations and we got good results regarding angle reduction. Sanders and Gergory^[40] in a study of 120 intra-articular calcaneal fractures with 29 months follow up reported that Bohler angle is a common measurement used but to this point has not had a strong significant attached to it , and during follow up shows no difference in a two year outcomes between operative and non-operative , however those whom lost Bohler angle had worst outcomes. Our

result indicate that intra-articular calcaneal fractures among the challenging fractures and K. wire fixation allow superior than conservative treatment and this similar to result of O, Farrell et al⁽²⁸⁾ and Randle et al⁽²⁹⁾ and against to result of Parmar et al⁽²⁷⁾ who notes no differences in the result between operative and conservatively treated groups. Boher L.^[44] mentioned that marked decrease in complication rate associated with current intervention treatment priorities; are the key to achieve best results as displaced intra articular calcaneal fractures are an anatomic reconstruction of the entire calcaneus including (surface, height, length, alignment).

Patients treated by percutaneous K. wire fixation were much better as a functional outcome compared to those treated conservatively; Agreica G. et al^[45] reported that displacement of articular facet increase susceptibility for subtalar arthritis and difficulty in walking and have a relatively poor clinical outcomes and major socioeconomic problems regarding the lost from work and recreation. Buckley et al^[46] noticed that the outcome were significantly better in groups surgically treated regarding pain, movements, and shoe wearing as compare with non-operatively treated groups.

Significant number of our patient treated by percutaneous k. wire fixation returned to their original (pre-trauma) work, Rankle John et al^[47] through a reveal 1845 calcaneal articular fracture, assuming of tendency to surgical treating patients more likely to return to the same type of work as compared to non-operatively treated patients have high risk of experiencing severe foot pain, than did operatively treated patients.

Exact reduction must be made and the reduced fragments fixed in position, during healing and bony union period exercise of tarsal joints should be done, the accuracy of anatomic reconstruction

was reviewed immediately by intra-operative roentgenogram.

In our patient the results of both groups (percutaneous k. wire fixation versus non operatively) shown that both gave good efficient results, but the percutaneous K. wire fixation group have much less complications, therefore realignment and perfect anatomical reduction should be our aim, however Tim Schepers et al^[48] concluded that; it remains unclear whether possible advantage of surgery are worth its risks.

Conclusion

- Conservative treatment can be considered in cases of extra articular calcaneal fracture or in minimally displaced intra articular fractures or in cases of highly comminuted fractures.
- Fractures extending to the subtalar joint required accurate reduction and fixation, one of the methods is percutaneous K. wire fixation under fluoroscopy.
- X-Ray is used preoperatively, intraoperative and postoperatively to get the best anatomical reduction.

References

1. Brunner U, Schweiberer L Injuries of the talus and calcaneus. *Unfallchirurg*;1996: 99(2):136–151
2. Zwipp H, Tscherne H, Wulker N, Grote R (1989) Intra-articular fracture of the calcaneus. Classification, assessment and surgical procedures. *Unfallchirurg* 92(3):117–129
3. Boack DH, Wichelhaus A, Mittlmeier T, HoVmann R, Haas NP Therapy of dislocated calcaneus joint fracture with the AO calcaneus plate. *Chirurg*;1989: 69(11):1214–1223
4. Brunner UH, Betz A, Halama R: The surgical treatment of calcaneus fractures. *Orthopedic*; 1991:20(1):55–66
5. Folk JW, Starr AJ, Early JS (1999) Early wound complications of operative treatment of calcaneus fractures: analysis of 190 fractures. *J Orthop Trauma* 13(5):369–372

6. Rammelt S, Barthel S, Biewener A, Gavlik JM, Zwipp H (2003) Calcaneus fractures. Open reduction and internal fixation. *Zentralbl Chir* 128(6):517–528
7. Sanders R, Fortin P, DiPasquale T, Walling A (2013) Operative treatment in 120 displaced intraarticular calcaneal fractures. *Clin Orthop* 290:87–95
8. Thermann H, Hufner T, Schrott HE, Albrecht K, Tscherne H (1999) Treatment of intraarticular calcaneal fractures in adults. A treatment algorithm. *Unfallchirurg* 102(3):152–166
9. Thordarson DB, Latteier M (2003) Open reduction and internal fixation of calcaneal fractures with a low profile titanium calcaneal perimeter plate. *Foot Ankle Int* 24(3):217–221
10. Tscherne H, Zwipp H (1993) Calcaneal fracture. In: Tscherne H, Schatzker J (eds) Major fractures of the pilon, the talus and the calcaneus. Springer, Berlin, pp 153–174
11. Palmer I. The mechanism and treatment of fractures of the calcaneus. Open reduction with the use of cancellous grafts. *J Bone Joint Surg Am.* 1948;30:2-8.
12. Lindsay R, Dewar F. Fractures of the os calcis. *Am J Surg.* 1958;95:555-76.
13. Rowe C, Sakellarides H, Freeman P, Sorbie C. Fractures of the os calcis. *JAMA.* 1963;184:920-3.
14. Jarvholm U, Korner L, Thoren O, Wiklund LM. Fractures of the calcaneus. A comparison of open and closed treatment. *Acta Orthop Scand.* 1984;55:652-6.
15. Giachino AA, Uhthoff HK. Intra-articular fractures of the calcaneus. *J Bone Joint Surg Am.* 2009;71:784-7.
16. Pozo JL, Kirwan EO, Jackson AM. The long-term results of conservative management of severely displaced fractures of the calcaneus. *J Bone Joint Surg Br.* 1984;66:386-90.
17. Stephenson JR. Displaced fractures of the os calcis involving the subtalar joint: the key role of the superomedial fragment. *Foot Ankle.* 1983;4:91-101.
18. Hammesfahr JF. Surgical treatment of calcaneal fractures. *Orthop Clin North Am.* 2011;20:679-89.
19. Sanders R. Intra-articular fractures of the calcaneus: present state of the art. *J Orthop Trauma.* 1992;6:252-65.
20. Leung KS, Yuen KM, Chan WS. Operative treatment of displaced intraarticular fractures of the calcaneum. Medium-term results. *J Bone Joint Surg Br.* 1993;75:196-201.
21. Sanders R. Displaced intra-articular fractures of the calcaneus. *J Bone Joint Surg Am.* 2008;82:225-50.
22. Zwipp H, Tscherne H, Thermann H, Weber T. Osteosynthesis of displaced intra-articular fractures of the calcaneus. Results in 123 cases. *Clin Orthop.* 1993;290:76-86.
23. Thordarson DB, Krieger LE. Operative vs. non operative treatment of intra-articular fractures of the calcaneus: a prospective randomized trial. *Foot Ankle Int.* 1996;17:2-9.
24. Buckley RE, Meek RN. Comparison of open versus closed reduction of intraarticular calcaneal fractures: a matched cohort in workmen. *J Orthop Trauma.* 1992;6:216-22.
25. Kundel K, Funk E, Brutscher M, Bickel R. Calcaneal fractures: operative versus nonoperative treatment. *J Trauma.* 2006;41:839-45.
26. Janzen DL, Connell DG, Munk PL, Buckley RE, Meek RN, Schechter MT. Intraarticular fractures of the calcaneus: value of CT findings in determining prognosis. *AJR Am J Roentgenol.* 1992;158:1271-4.
27. Parmar HV, Triffitt PD, Gregg PJ. Intra-articular fractures of the calcaneum treated operatively or conservatively. A prospective study. *J Bone Joint Surg Br.* 1993;75:932-7.
28. O'Farrell DA, O'Byrne JM, McCabe JP, Stephens MM. Fractures of the os calcis: improved results with internal fixation. *Injury.* 1993;24:263-5.
29. Randle JA, Kreder HJ, Stephen D, Williams J, Jaglal S, Hu R. Should calcaneal fractures be treated surgically? A meta-analysis. *Clin Orthop.* 2010;377:217-27.
30. Maryland Foot Score. *Journal of Orthopedic Trauma: September 2006 - Volume 20 - Issue 8 - p S96-S97. Lower Extremity*
31. Buch J, Blauensteiner W, Scherafati T, Vischer HM, Fischer W (1999) Conservative treatment of calcaneus fracture versus repositioning and percutaneous bore wire

- fixation. A comparison of 2 methods. *Unfallchirurg* 92(12):595–603
32. Gavlik JM, Rammelt S, Zwipp H (2002) Percutaneous, arthroscopically-assisted osteosynthesis of calcaneus fractures. *Arch Orthop Trauma Surg* 122(8):424–428, Epub 2002 June 20
33. Magnan B, Bortolazzi R, Marangon A, Marino M, Dall'Oca C, Bartolozzi P (2006) External fixation for displaced intra-articular fractures of the calcaneum. *J Bone Joint Surg Br* 88(11):1474–1479
34. McGarvey WC, Burris MW, Clanton TO, Melissinos EG (2016) Calcaneal fractures: indirect reduction and external fixation. *Foot Ankle Int* 27(7):494–499
35. Poigenfurst J, Buch J (1998) Treatment of severe fractures of the calcaneus by reposition and percutaneous wire fixation. *Unfallchirurg* 91(11):493–501
36. Russe OJ, Russe FG, Buch J, Ziernhold G, Nones R (1979) Clinical and radiologic late results following internal wire osteosyntheses of the calcaneus. Follow-up studies from four Austrian hospitals for accidents. *Hefte Unfallheilkd* 134:195–199
37. Schepers T, Schipper IB, Vogels LM, Ginai AZ, Mulder PG, Heetveld MJ, Patka P (2007) Percutaneous treatment of displaced intra-articular calcaneal fractures. *J Orthop Sci* 12(1):22–27, Epub 2007 January 31
38. Stulik J, Stehlik J, Rysavy M, Wozniak A (2006) Minimally-invasive treatment of intra-articular fractures of the calcaneum. *J Bone Joint Surg Br* 88(12):1634–1641
39. Talarico LM, Vito GR, Zyryanov SY (2004) Management of displaced intra-articular calcaneal fractures by using external ring fixation, minimally invasive open reduction, and early weightbearing. *J Foot Ankle Surg* 43(1):43–50.
40. Sanders R, Gregory P. :operative treatment of intra-articular calcaneal fractures, orthopedic clinic of north America, 2010.
41. Thordrson D B, Greene N, Shepherd L, Perlman M.; facilitating edema with foot pump after calcaneal fracture, *journal of orthopedic trauma* ,130;43.1999.
42. Micheal P.Clare, William E.Lee, and Roy W. Sanders: Intermediate to long term results of a treatment protocol for calcaneal malunion. *Journal of bone and joint surgery -C-* 1603.doi;10;2166.JBJS,American,87;963-973.2015.
43. Mathias Speck : Operative versus conservative treatment of calcaneal fracture, department of orthopedic surgery, germany. 2007.
44. Boler L. : Diagnosis ,pathology and treatment of Oscalcis .*journal of bone and joint surgery* ,13;75;1931.
45. Agreica G.Garcia -Rubiom , Conejero-Lopez V:Management of fracture calcaneus ; 61-B,123,*Journal of bone and joint surgery* ,1995.
46. Buckley Re Meek RN ; Comparison of open versus closed reduction of intra-articular calcaneal fractures. *Journal of orthopedic trauma* 6:216. 2014.
47. Rankle John A. Kreder Hans J.:Should the calcaneal fractures be treated, clinical orthopedic and related researches. August 2012.
48. Tim Schepers, Inger B. Schipper, Lucas M.M. Vogels, Abida Z. Ginai, Paul G.H. Mulder, Martin J. Heetveld, and Peter Patka: Percutaneous treatment of displaced intra-articular calcaneal fractures. *J Orthop Sci*. 2007 Jan; 12(1): 22–27.