

Pyometra Presented With Rectal Pain, a Case Report and Review of Literature

Yosra T. Jarjees* DOG, FIBMS (Obs.Gyn)

Summary:

Fac Med Baghdad
2011; Vol. 53, No. 3
Received Jan.2011
Accepted Sept. 2011

Pyometra is an uncommon gynecological condition resulted from occlusion of the cervix usually by a malignant condition. It has an incidence of 0.1%-0.5%. Untreated pyometra leads to rupture uterus and acute infective peritonitis presented as acute abdomen and needs urgent surgical intervention. Pyometra resulted from occlusion of the vagina is very rare. No cases have been described in the English literature to the best of our knowledge and in the PubMed. The purpose of reporting this case is to show that occlusion of the vagina could occur in postmenopausal women as a consequence of local infection and results in pyometra and also to show that pyometra can be presented in a different way apart from the classical presentation. The way to reach the diagnosis and how to manage the case has been also discussed thoroughly.

Key words: Pyometra, hysterectomy, uterine perforation

Introduction:

Pyometra a collection of purulent material in the uterus is an uncommon gynecologic condition occurs when the natural drainage of the uterine cavity is compromised usually by malignant lesions especially carcinoma of the cervix (1, 2). Benign conditions such as infection and congenital cervical anomalies are other causes (3, 4). It has an incidence of 0.1%–0.5% (5, 6). However, it may rise to 13.6% among elderly patients (7). This case differs from the other cases of pyometra in that the occlusion of the birth canal was in the vagina and not in the cervix, as well as the cause of obstruction was an inflammatory condition, also the presentation was not a gynecological complaint. No evidence of malignancy or other cervical disease was found in this case. These features deserve emphasis when compared with other published case reports.

The Case:

Mrs. B. A. S, 63-year-old married lady presented to Al-Batool Maternity Teaching Hospital in Mosul at 2008 with difficulty in passing motion (she felt that something obstruct her rectum) associated with pain in the rectum occurred during defecation. There was no change in stool consistency and no bleeding per rectum. This complaint was for several months duration. For this reason she had consulted many doctors and received lots of medications but without any relief. The patient was postmenopausal for the last 10 years, she had no postmenopausal bleeding nor vaginal discharge or pruritus or bad odor from the vulva and no fever. Prior to her complaint she had preceding purulent vaginal discharge which was treated by antibiotics; she recorded her illness after this event. She did not have diabetes mellitus and had never had sexually transmitted disease. Seven normal vaginal deliveries were reported without other operative history. Review of systems was normal; she had negative family history for similar complaint or bowel disease. On physical

examination, she looked depressed by her illness, vital signs were normal and she was afebrile. Palpation of her abdomen was soft without distension. General or local tenderness and muscular guarding was not recognized, and there were no palpable masses. Systemic examination was normal. Per vagina examination showed blind vagina and the adnexia could not be palpated. The cervix was not visualized. Per rectum examination was unremarkable. The results of laboratory studies on admission were normal. Ultrasound of the pelvic organs using abdominal probe showed no abnormalities, vaginal ultrasound could not be performed because of the short blind vagina. Magnetic resonance imaging was not requested because of the long waiting list. As the cervix was not visualized we could not exclude any pathology in the cervix which could cause her illness. For this reason a diagnosis could not be settled with confidences. Other opinions from my colleagues were taken and with adequate patient counseling exploratory laparotomy and a decision to perform total abdominal hysterectomy on the assumption of the presence of local cervical lesion. At laparotomy the uterus was atrophic (fig. 1) as expected by her age; the only abnormal finding is a filmy adhesion extending from the posterior wall of the uterus to the rectum. No abnormal findings were found in the gastrointestinal tract, liver or gall bladder. At hysterectomy; after clamping the paracervical ligaments and as we reached the vagina a purulent fluid of about 4cm³ was encountered which was sucked out with packing of the abdomen to prevent spread to the peritoneal cavity. Pus was drawn for culture and sensitivity. The cervical canal was found to be open, and the blind vaginal pouch was plicated. Drain was not left as the amount of pus was small and adequate packing was done carefully to isolate the uterus from the peritoneal cavity. Empiric parenteral antibiotics (Cefotaxim and metronidazole) were given for 2 days postoperatively. No bacteria were isolated from the pus. The patients had smooth postoperative period discharged home on the second postoperative day. Histopathology investigation of the surgical specimen revealed just atrophic

*Department of Obstetrics and Gynecology,
Ninewah College of Medicine, University of Mosul.

endometrium without evidence of malignancy. The patient then came for post-operative check-up and happily reported relief of her symptoms and depression.

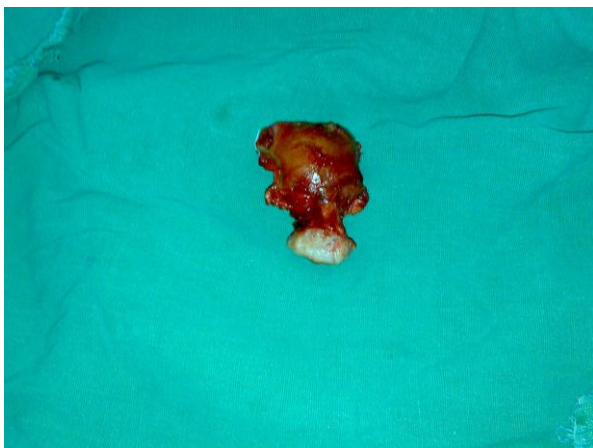


Figure (1)

Discussion:

Pyometra is more common in postmenopausal women than in menstruating women, and more than 50% of all patients of nonruptured pyometra are asymptomatic⁽⁸⁾. The incidence of pyometra becomes much higher with age and decline in activity; incontinence is also a significant risk factor⁽⁹⁾. Our patient as an elderly low activity woman was predisposed to have pyometra especially after the local vaginal infection reported to occur just before appearance of the symptoms. Postmenopausal bleeding, vaginal discharge, uterine enlargement, and cramping pain are said to be the classic symptoms of pyometra⁽²⁾. This patient had none of these symptoms. Benign or malignant conditions of the cervix cause accumulation of secretions and gradual enlargement of the uterus, leading to thinned uterine walls which may be sloughed with spontaneous uterine rupture and causing generalized peritonitis. A spontaneous perforation of pyometra leading to diffuse peritonitis only rarely occurs^(5,10). Once ruptured, the symptoms become severe and acute abdomen often develops; it is therefore important to make a differential diagnosis from other causes of acute surgical abdomens⁽¹¹⁾. Luckily, this lady had operated upon before this drastic complication has occurred. The strange thing in this patient is the presence of blind vagina; this feature has not been reported in the literature. The closure of the vagina in this lady may be due to local inflammatory condition resulted from purulent infection as the patient is postmenopausal with low estrogen and without replacement for long time. The possibility of tuberculosis should be considered in all patients presented with pyometra⁽¹²⁾. In this case the sterile pus could be due to tuberculosis, but the histopathological examination did not show the features of tuberculosis and also the patient was relieved from her symptoms after surgery, this diagnosis was thought to be remote.

References:

1. Li C, Chang W. Spontaneous perforated pyometra with an intrauterine device in menopause: a case report. *Jpn. J. Infect. Dis.*, 2008; 61: 477-478.
2. Chan LY, Lau TK, Wong SF, Yuen PM. Pyometra. What is its clinical significance? *The Journal of Reproductive Medicine*. 2001; 46(11):952-956.
3. Lee SL, Huang LW, Seow KM, Hwang JL. Spontaneous perforation of a pyometra in a postmenopausal woman with untreated cervical cancer and "forgotten" intrauterine device. *Taiwan J Obstet Gynecol* 2007; 46: 43941.
4. Chan LY, Yu VS, Ho LC, Lok YH, Hui SK. Spontaneous uterine perforation of pyometra: A report of three cases. *J Reprod Med* 2000; 45: 85760.
5. Geranpayeh L, Fadaei-Araghi F, Shakiba B. Case report spontaneous uterine perforation due to pyometra presenting as acute abdomen. *Infectious Diseases in Obstetrics and Gynecology Volume 2006, Article ID 60276, Pages 1-2*
6. Inui A, Nitta A, Yamamoto A, et al. Generalized peritonitis with pneumoperitoneum caused by the spontaneous perforation of pyometra without malignancy: report of a case. *Surgery Today*. 1999; 29(9):935-938.
7. Sawabe M, Takubo K, Esaki Y, et al. Spontaneous uterine perforation as a serious complication of pyometra in elderly females. *Aust. N. Z. J. Obstet. Gynecol*. 1995; 35: 87-91.
8. Hansen PT, Lindholt J. Spontaneously perforated pyometra. A differential diagnosis in acute abdomen. *Annales Chirurgiae et Gynaecologiae*. 1985; 74(6):294-295.
9. Iwase F, Shimizu H, Koike H, Yasutomi T. Spontaneously perforated pyometra presenting as diffuse peritonitis in older females at nursing homes. *Journal of the American Geriatrics Society*. 2001; 49(1):95-96.
10. Vyas S, Kumar A, Prakash M, et al. Case report spontaneous perforation of pyometra in a cervical cancer patient: a case report and literature review. *Cancer Imaging* (2009) 9, 1214
11. Zeferino Toquero M, Bañuelos Flores J. Secondary peritonitis due to rupture of pyometra in cervical cancer. *Ginecol Obstet Mex*. 2005 Nov; 73(11):618-21. (Abstract).
12. Gatongi D K, Kay V. Endometrial tuberculosis presenting with postmenopausal pyometra. *Journal of obstetrics and gynecology*, July 2005; 25(5):518-520.