

---

## **CATARACT EXTRACTION UNDER TOPICAL- SUBCONJUNCTIVAL LOCAL ANAESTHESIA COMBINED WITH NEUROLEPTANALGESIA**

**Salam N. Asfar<sup>\*</sup>, Mohammed Z. Al-Sherifi<sup>@</sup>**

<sup>\*</sup>M.Sc., Assistant Professor of Anaesthesiology, Department of Surgery, University of Basrah College of Medicine. <sup>@</sup>DO, Consultant Ophthalmic Surgeon, Saddam Teaching Hospital, Basrah; IRAQ.

### **Summary**

Local anaesthesia for ophthalmic surgical techniques is achieving prevalence now. Various local procedures were described in the literature including retrobulbar, peribulbar, subconjunctival and topical anaesthesia. This study endeavor to ascertain the efficacy of lidocaine topical-subconjunctival anesthesia technique combined with neuroleptic sedation-analgesia consisting of fentanyl and droperidol in cataract surgery, and to test patient's and surgeon's satisfaction with this method. Sixty five patients with mature cataract age range 55-70 years were scheduled for cataract extraction. Patients were 36 male and 29 female. Topical and subconjunctival local anaesthesia was supplemented by intravenous sedative and analgesic medication consisting of 50µg fentanyl and 2.5 mg droperidol. A special patient's pain scoring system used in this study with another intraoperative surgeon's satisfaction score to test the reliability of this method. All patients had successful cataract extraction with an average surgery time of 20-25 minutes. Patients had minimal or no movement during surgery. No patient required additional supplement of anaesthesia as there were no intolerable pain. No postoperative complications. Cataract surgery can be safely and effectively performed by surgeons converting to topical anesthesia using this method.

---

### **Introduction**

**L**ocal anaesthesia for ophthalmic surgical techniques is gaining more popularity now. Many surgeons are converting from general to local anaesthesia in cataract surgery<sup>1</sup>. In the United Kingdom, 75% of intraocular operations

are performed under local anaesthesia<sup>2</sup>.

Many local procedures were introduced in the literature including retrobulbar, peribulbar, subconjunctival and topical anaesthesia<sup>2</sup>. Some like retrobulbar and peribulbar are distressing to the patient and may increase the intraocular pressure forcing out the intraocular contents<sup>3</sup> or they may lead to Chemosis subconjunctival hemorrhage, eyelid

---

#### **Correspondence to:**

Dr. Salam N. Asfar  
Department of Surgery, College of Medicine  
University of Basrah, Basrah; IRAQ.

hemorrhage and retrobulbar hemorrhage<sup>4</sup>. Also they may have more serious complications including multiple cranial nerve palsies<sup>5</sup>.

Different sedatives or analgesics were tried as a supplement to local anaesthesia including; midazolam, diazepam, propofol, fentanyl and ketamine<sup>2,4,6,7</sup>.

The aim of this study is to determine effectiveness of lidocaine topical-subconjunctival anesthesia technique combined with neuroleptic sedation-analgesia consisting of fentanyl and droperidol in cataract cases, and to test patient's and surgeon's satisfaction with this method.

## Patients and Methods

Sixty five patients with mature cataract age range 55-70 years, were scheduled for cataract extraction under local anaesthesia supplemented by analgesic-sedative combination. They were ASA class II and III. Patients were 36 male and 29 female. Prior to start of the procedure, a full instruction was provided to the patients.

Local anaesthetic solution consisting of 2% lidocaine drops and injection was used. Six drops of lidocaine were put in the conjunctival sac followed by subconjunctival injection of 1-1.5 ml lidocaine injected 2-3 mm above the limbus using a fine BCG needle. Another 6 drops of lidocaine solution was then put in the conjunctival sac of the eye undergoing surgery and the other eye to prevent blinking reflex of the contralateral eye. Topical and subconjunctival local anaesthesia was supplemented by intravenous sedative and analgesic medication consisting of 50 µg fentanyl and 2.5 mg droperidol. Patients were monitored apart from the vital signs for discomfort to light and touch, and for foreign body sensation or pain. A questionnaire method (Tables I and II) used for both the patients and the surgeon and was completed in the

recovery room postoperatively, a subjective pain score for the patient was utilized. Surgeon reported the intraoperative conditions in both procedures of cataract extraction including extracapsular lens extraction and cryo-extraction whether there is vitreous loss and if the operating environment is optimum.

Score	Patient's condition
0	No pain or discomfort
1	Some discomfort
2	Mild tolerable pain
3	Moderate pain
4	Severe pain

Table I. Patient's pain scoring system used in this study.

Score	Operative conditions
0	Poor
1	Fair
2	Good
3	Excellent

Table II. Intraoperative surgeon's satisfaction score.

## Results

All patients had successful cataract extraction with an average surgery time of 20-25 minutes. Patients had minimal or no movement during surgery.

Figure one showed that 55 patients (84.6%) had no pain or discomfort reported intraoperatively and only 9.2% had some discomfort to touch and light sensation and 6.2% had mild tolerable pain from the speculum. Surgeon reported the intraoperative conditions as excellent in 57 patients (87.7%), good in 9.2% of the patient as there was some blinking and fair in only 3.1 % of the patients where there was blinking and eye movement as demonstrated in fig.2.

No case required conversion to other method of anaesthesia. There were no subconjunctival bleeding or other serious complications postoperatively.

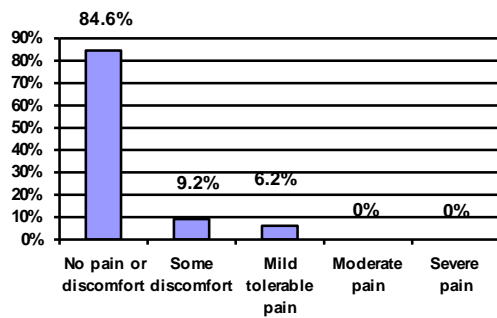


Figure 1. Subjective pain scoring

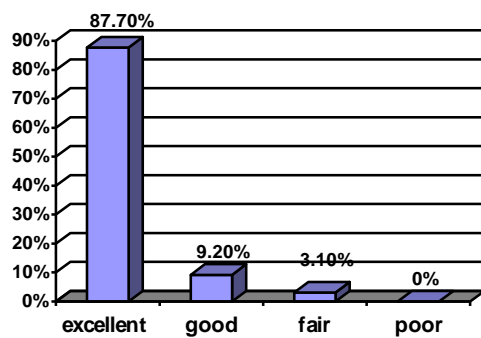


Figure 2. Intraoperative conditions reported by surgeon. Surgeon's satisfaction score.

## Discussion

Although it is often said "There is no safe anaesthetic agent, there is no safe anaesthetic technique, there is only safe anaesthetist", but this study offer the use of a safe anaesthetic agents and technique by a least trained ophthalmic anaesthesiologist.

Topical and subconjunctival anesthesia provided acceptable analgesia during surgery and showed that intraocular procedures can be performed without

akinesia. They also are safe as compared to the other ways that increases intraocular pressures<sup>8</sup>.

Many sedatives and analgesics have been tried as a supplement to local anesthesia<sup>9</sup>, but here we choose the combination of fentanyl-droperidol. Fentanyl is a narcotic analgesic which has no side effect in this dose, it can prevent physical and psychological discomfort, it provides good cooperation of the patient in spinal anaesthesia, and it arrest patients recall of intraoperative events<sup>10</sup>. Droperidol is a good sedative with all its advantages of intraoperative stability in regard to cardiovascular system", it also has postoperative antiemetic effect<sup>12</sup>, this is important as It is undesirable for patients undergoing cataract surgery to have postoperative nausea and vomiting with concomitant strain being put on eye<sup>13</sup>.

The combination of fentanyl-droperidol give the advantage of a wake and cooperative patient who obey commands quietly. We have noticed previously on giving diazepam in such cases they go into sleep and suddenly awake with abnormal reaction to the operative effects.

Although eyelid squeezing and ocular motility were present frequently, it was neither a problem to the surgeon nor to the patient.

No patient required additional supplement of anaesthesia. Surgeon was satisfied with this method, patients express the willing to have this type of anaesthesia for the other eye in the future.

## References

1. Uusitalo RJ, Maunuksele EL, Paloheimo M. Converting to topical anesthesia in cataract surgery. *J Cataract Refract Surg* 1999; 25:432-440.
2. Eke T, Thompson JR, The National Survey of Local Anaesthesia for Ocular Surgery. I. Survey methodology and current practice. *Eye* 1999; 13 :189-195.
3. Sanford DK, Minoso y, Belyea DA, Response of intraocular pressure to retrobulbar and peribulbar anesthesia. *Ophthalmic Surg Lasers* 1998; 29: 815-817.
4. Patel BC, Clinch TE Burns TA Prospective evaluation of topical versus retrobulbar anesthesia: a converting surgeon's experience. *J*

- Cataract Refract Surg 1998; 24: 853-860.
5. Jackson K, Vote D, Multiple cranial nerve palsies complicating retrobulbar eye block. *Anaesth Intensive Care* 1998; 26: 662-664.
  6. Andersan CJ, Circumferential perilimbal anesthesia for combined cataract glaucoma surgery. *Ophthalmic Surg Lasers* 1999; 30:205-207.
  7. Frey K, Sukhani R, Pawlowski J, Propofol versus propofol-ketamine sedation for retrobulbar nerve block: comparison of sedation quality, intraocular pressure changes, and recovery profiles. *Anesth Analg* 1999; 89:317-32.
  8. Lanini PG, Simona FS, Change in intraocular pressure after peribulbar and retrobulbar injection: practical sequelae. *Kiin Monatsbl Augenheilkd* 1998; 212: 283-285.
  9. Perez Castanedo J, Planell J, Barrachina V, Effectiveness of topical anesthesia enhanced by sedation and analgesia for cataract surgery. *Rev Esp Anesthesiol Reanim* 1988;45:312-316.
  10. Causins MJ, Bridenbaugh PO, *Neural Blockade*, Lippincott, 1980, 1<sup>st</sup> ed. Page 136.
  11. Asfar SN. Total intravenous anaesthesia in disaster situation. *Intern Rev Armed Forces Med Serv* LXIX 1986; 317-322.
  12. Cohen S, Antiemetic efficacy of droperidol and metoclopramide. *Anesthesiology* 1984; 60:67-69.
  13. Churchill-Davidson HC. *A Practice of Anaesthesia*, Lloyd-Luke, 5<sup>th</sup> ed. 1984.