

Pathological and bacteriological study of bumblefoot cases in Sulaimaniyah province

A.H. Hassan, S. A. Hussein and E. A. AbdulAhad
College of Veterinary Medicine\ University of Sulaimani

Abstract

Various aspects of the environmental status were explored in a farm of broiler breeders Ross 308 in Al Sulaimaniyah city, Iraq, suffering from bumblefoot lesion, to check out the management, dietary and hygienic conditions that could be responsible for initiation of this lesion. For pathological and bacteriological investigations, 15 hens and 7 roosters were randomly selected out of 5300 chickens suffering from the bumblefoot in the concerned farm. Exploring the environmental status of the farm showed that the chickens were bred under crowded condition in humid weather on a thick, muddy litter, were feeding commercial layer ration not subjected to quality control confirmation and were allowed to lay their eggs in laying nests with sharp-edged perches. The pathological examination showed abscess foci and ulcers of various diameters and depths on the affected feet and some of the ulcers were associated with a gangrenous appearance. In some of these chickens, the first toe was partially lost, most probably due to a previous gangrenous ulceration. Microscopically, ulcerative epithelial damage, hyperkeratosis and suppuration were seen associated with marked fibrovascular granulation tissue response in the dermis. A total of 28 facultatively anaerobic bacterial isolates were recovered from only 16 out of the 22 diseased chickens that were sampled in the current study. These bacterial isolates were belonging to three species; *Staphylococcus aureus*, *Escherichia coli* and *Proteus mirabilis*.

دراسة مرضية وبكتريولوجية لحالات القدم المتورم في منطقة السليمانية

علي حسين حسن، سهى علي حسين وعماد أدور عبد الأحد

كلية الطب البيطري/ جامعة السليمانية

الخلاصة

تم التقصي عن جوانب مختلفة من الظروف البيئية لحقل تربية دجاج امهات لحم "Ross 308" في مدينة السليمانية/ العراق، تعاني من آفة القدم المتورم bumblefoot وذلك لاجل التحري عن ادارة الحقل وعن ظروفه الغذائية والصحية التي قد تكون مسؤولة عن نشوء هذه الافة. ولجل اجراء الفحوصات المرضية النسجية والبكتيرية، اختيرت 15 دجاجة و7 ديكة بشكل عشوائي من مجموع 5300 فرخة كانت تعاني من آفة القدم المتورم في الحقل المعني. لقد تبين "من خلال التحري عن الظروف البيئية للحقل المعني" أن افراخ الدجاج قد تمت تربيتها تحت ظرف مزدحم في جو رطب على فرشاة سميكة متطينة، وأنها كانت تغذى عليقة تجارية غير خاضعة لفحوصات السيطرة النوعية وكانت تضع بيضها في اعشاش بيض ذات مساند حادة الحواف، وقد أظهر الفحص المرضي وجود بؤر خراج وتقرحات مختلفة القطر والعمق على الاقدام المصابة وكانت بعض هذه التقرحات ذات مظهر مواتي (غانغريني)، وفي بعض الدجاج كان الاصبع الاول مفقودا جزئيا بسبب تقرح مواتي سابق على الاغلب. مجهريا، لوحظ تحطم ظهاري تقرحي وفرط التقرن وتقحح مصحوبا باستجابة حبيبية وعائية ليفية واضحة في الادمة. تم الحصول على 28 عزلة بكتيرية لاهوائية اختيارية من 16 فقط من مجموع الـ 22 فرخة التي تم أخذ النماذج منها في الدراسة الحالية، وكانت هذه العزلات تعود الى أجناس المكورات العنقودية الذهبية *Staphylococcus aureus* والايشيرشيا القولونية *Escherichia coli* والـ *Proteus mirabilis*.

Introduction

Bumblefoot is a general term referring to any inflammatory or degenerative condition of the avian foot and it may range from a very mild redness or swelling to chronic, deep-seated abscesses and bony changes (1). It is also referred to as planter abscess, pododermatitis or foot dermatitis; is characterized by massive swelling and ulceration of the plantar and/or digital pads; causes lameness; impedes perching and walking; and may limit access to food and water (2, 3). If left untreated, bumblefoot will compromise the internal tissues of the foot, such as the tendons and bones, causing osteomyelitis, synovitis, laminitis, and eventually death (4). It occurs in domestic poultry (5-7) as well as captive avian species (8-11). Cases of bumblefoot may be classified clinically into seven grades. Grade I is characterized by focal epithelial sloughing on the plantar surface of the foot represented clinically by the appearance of small, shiny pink areas and peeling of the skin on the foot. Grade II is recognized as smooth, thinly surfaced, circumscribed areas of hyperplastic connective tissue on the plantar and/or digital pads with no distinct ulcers. Grade III is ulceration of the plantar and/or digital pads and may be associated with formation of a peripheral callus. In grade IV, a plug of necrotic tissue is present in the ulcer and is accompanied by pain and/or mild lameness. Grade V is characterized by swelling and edema involving the ulcer-surrounding tissues and possibly the digits or the entire foot associated with severe lameness. In Grade VI, the inflammation and necrosis extend deeply into the flexor tendons and is recognized clinically by swelling of the digits and ankylosis whilst in Grade VII the bones are involved (1). This inflammatory disease is claimed to be the result of management, dietary and traumatic factors within the bird's enclosure, including improper perching, poor hygiene, piercing of the bottom of the foot and leg fractures (8, 12). This research aimed to describe and determine the epidemiological background, pathological changes and the bacterial causes of bumblefoot cases occurred in a private poultry farm in Al Sulaimaniyah province, Iraq.

Materials and Methods

- **Broiler Breeders:** The bumblefoot cases involved in this study were obtained on November, 2010 from Awder farm ða private farm of broiler breeders in Tasluja quarter in Al Sulaimaniyah city, Iraq. The farm was containing 15000 female and 1630 male broiler breeders ðRoss 308ö of 56 weeks age, of which about 5300 chickens (from both sexes) were suffering from bumblefoot in one or both of their feet. Out of these 5300 chickens, 15 hens and 7 roosters were randomly selected and processed for pathological and bacteriological investigation.
- **Environmental Status of the Farm:** To explore the management, dietary and hygiene conditions of the farm; the different aspects of the environmental status was explored with special concern to the number of chickens, number, area and ventilation system of the breeding halls, and the litter, ration and automatic drinkers of chickens. In addition, the egg laying nests were also explored to check out their safety for chickens.
- **Pathological Examination:** The diseased chickens were carefully examined by the naked eye to describe the bumblefoot lesion and any other pathological changes related to it. Following gross examination, tissue samples of about 1 cubic centimeter were obtained and kept in 10% formalin for 24-48 hours. The formalin-fixed tissue samples have undergone a series of histopathological preparations according to Luna (13). Glass slide tissue sections (obtained from these tissue samples) were stained by hematoxylin and eosin stains and examined by different magnifying powers of light microscopy.

- **Bacterial Isolation and Identification:** In all of the randomly selected 15 bumblefoot cases, the bumblefoot lesion was sampled with a sterile loop which was then aseptically cultured on blood agar and brain heart infusion agar. All inoculated media were incubated at aerobic, microaerophilic and strictly anaerobic conditions at 37 °C and inspected for growth after 24 to 48 hours of incubation. Primary cultures were evaluated by visual examination of the colony morphology and were subcultured on mannitol salt agar, eosin methylene blue agar and nutrient agar slants. Identification of the purified bacterial cultures was performed using conventional bacteriological and biochemical procedures as described by Carter (14) and Carter *et al.* (15).

Results

- **Environmental Status of the Farm:** Exploring the environmental status showed that the farm includes three halls of 770 square meters each (11m x 70m). A total of 16630 broiler chickens were bred under crowded conditions in these three halls with an average of 7.2 chickens per each square meter. The chickens were feeding commercial layer ration in pelleted form, locally-produced and not subjected to quality control confirmation. The egg laying nests have sharp-edged perches. The litter was old, thick and muddy and the automatic drinkers in the farm were unfit permitting water to pour onto the litter. In addition, the ventilation system of the farm was poor creating a humid general weather.
- **Pathological Findings:** The gross pathological examination of bumblefoot lesions in the diseased chickens showed that the affected feet were generally swollen. The swelling was more prominent on the ventral surfaces of the feet, in which abscess foci of various diameters and depths were seen on the pads and toes of the foot. Some of these abscess foci were already broken with the appearance of a deep ulcer surrounded by thickened skin (Fig. 1) and some others were associated with a gangrenous dermatitis (Fig. 2). Dissecting of the closed abscess foci revealed the presence of solidified, cheesy-like material surrounded by thickened skin (Fig. 3). In some of the diseased chickens, the first toe was partially lost probably due to a previous gangrenous ulceration (Fig. 1 and 3). Microscopic examination of the routinely-stained skin sections obtained from the bumblefoot lesion of the diseased chickens revealed ulcerative epithelial damage, marked hyperkeratosis and extensive suppuration on the surface of the skin and within the epithelial layer (Fig. 4) associated with presence of granular basophilic structures, probable to be bacterial colonies (Fig. 5). Extensive fibrous connective tissue proliferation and angiogenesis (new blood vessels formation) was apparent in the dermis, an indication of marked fibrovascular granulation tissue response (Fig. 6).
- **Bacterial Isolation and identification:** A positive bacterial isolation was obtained from sixteen out of the twenty two chickens with bumblefoot lesion that were sampled on the primary culturing media. Out of these sixteen, four cultures revealed a single bacterial isolate (pure cultures) whereas the remaining twelve cultures revealed a mixture of 2 bacterial isolates; i.e., a total of 28 bacterial isolates were recovered from only 16 out of the 22 diseased chickens that were sampled in the present study. All of these 28 bacterial isolates were facultatively anaerobes. The biochemical tests revealed that these bacterial isolates belong to three different species. *Staphylococcus aureus* was the most frequent bacterial isolate encountered in this study. It was recovered from all the 16 chickens that revealed positive bacterial isolation. Out of these 16 *Staphylococcus aureus* isolates, four appeared as single isolates in pure cultures, ten isolates were mixed with *Escherichia coli* and two isolates were mixed with *Proteus mirabilis* (Table 1).

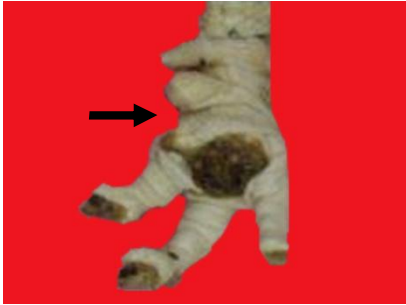

Fig. (1) Bumblefoot lesion in a rooster involved in this study. Deep ulcer surrounded by thickened skin is visible on the pad of the foot. The distal half of the first toe (arrow) is lost probably due to a previous gangrenous ulcer.

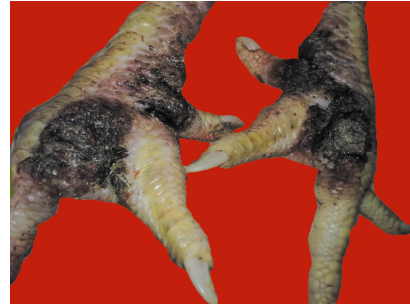

Fig. (2) Bumblefoot lesion in a hen involved in this study. Gangrenous ulcers are visible on the foot and at the bases of the toes in both feet.



Fig. (3) Bumblefoot lesion in a rooster involved in the present study. Cheesy-like material (arrow) is seen in a dissected abscess at the base of the first toe and an open ulcer is apparent on the pad of the foot at the bases of the 3rd and 4th toes. In addition, the distal half of the first toe (arrow head) is lost probably due to a previous gangrenous ulcer.

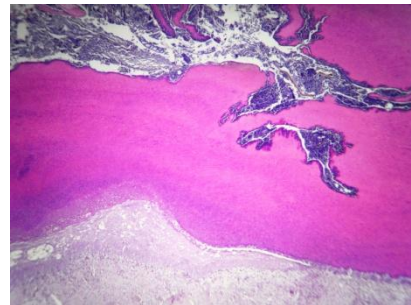


Fig. (4) Microscopic view of a skin section obtained from the bumblefoot lesion in one of the diseased chickens. Ulcerative epithelial damage and marked hyperkeratosis are apparent associated with an extensive suppurative exudate found on the surface of the skin and within the epithelial layer. H and E stain, X 200.

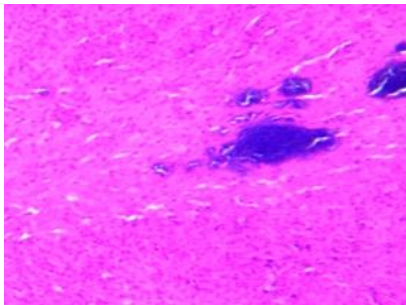


Fig. (5) Microscopic view of a skin tissue section obtained from the bumblefoot lesion in one of the diseased chickens. Granular basophilic structures, probable to be bacterial colonies, are seen within the epithelial layer. H and E stain, X 400.

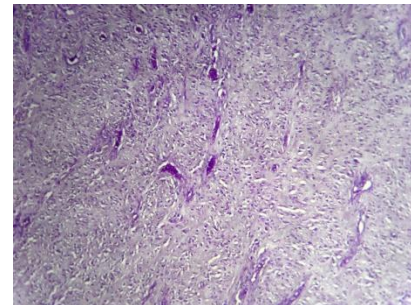


Fig. (6) Microscopic view of a skin tissue section obtained from one of the diseased chickens. Marked fibrovascular granulation tissue response is evident as indicated by the extensive fibrous connective tissue proliferation and angiogenesis in the dermis. H and E stain, X 400.

Table (1) Bacterial isolates recovered from the bumblefoot lesion in diseased chickens

Bacteria	Number of isolates
<i>Staphylococcus aureus</i>	16
<i>Escherichia coli</i>	10
<i>Proteus mirabilis</i>	2
Total	28

Discussion

Exploring the environmental status of the farm showed that the chickens were bred under crowded conditions with an average of 7.2 chickens per each square meter instead of the recommended 3.5-5.5 chickens per square meter (16). They were bred in humid weather on old, thick and muddy litter, were feeding commercial layer ration not subjected to quality control confirmation and were allowed to lay their eggs in laying nests with sharp-edged perches. Such poor management and dietary conditions play an important role in establishment of the bumblefoot lesion in chickens since the crowded conditions of breeding encourage the chickens to fight each other giving a chance for traumatic injuries to take a place on the chicken feet and such traumatic injuries may become worse in the presence of humid weather, muddy litter and sharp-edged egg laying nests which by themselves are considered important predisposing factors for initiation and progression of bumblefoot lesion (8, 12). The gross pathological examination of diseased chickens in the present study showed that the affected feet were swollen due to presence of abscess and ulcerated areas on the pads and toes of the foot. These pathological findings are generally in agreement with description of bumblefoot lesion mentioned by other authors (11, 17, 18, 19) and it can be ascribed to accumulation of pus due to an ascending infection of the foot by opportunistic environmental pyogenic bacteria following exposure of the foot to traumatic injuries (19) in the presence of bad management and dietary conditions mentioned above. The microscopic examination of the skin sections obtained from bumblefoot lesion dealt in the current study showed ulcerative epithelial damage, hyperkeratosis and extensive epithelial suppuration associated with the presence of granular basophilic structures, probable to be bacterial colonies. In addition, marked fibrovascular granulation tissue response was apparent in the dermis. These pathological changes are possibly precipitated by exposure of the foot to traumatic injuries and by the bad management and dietary conditions encountered in the current study which together change the mechanics of weight bearing on the metatarsal pads, leading to reduced circulation, micro-epithelial damage, microthrombosis, localized impairment of the immune system and invasion of opportunistic pathogens (1). The partial loss of the first toe observed in some of the diseased chickens is most probably attributed to the gangrenous ulceration of the bumblefoot lesion. Gangrenous ulcers were observed on the feet of some of the diseased chickens in this study and they can be ascribed to contamination of the bumblefoot lesions by some pathogenic bacteria capable of causing gangrenous skin necrosis; such bacteria are found in the wet litter of the poultry farms and they include various anaerobic and aerobic bacteria such as *Clostridium septicum*, *Clostridium perfringens* type A, *Staphylococcus aureus* and *Escherichia coli* (1, 20, 21). However, the results of the bacterial isolation and identification performed in the present study revealed recovery of 28 facultatively anaerobic bacterial isolates belonging to three different species; *Staphylococcus aureus*, *Escherichia coli* and *Proteus mirabilis*. No strictly anaerobes were recovered. *Staphylococcus aureus* was the most frequent bacterial isolate encountered; it was recovered from all the 16 chickens that revealed positive bacterial isolation. This result is generally in agreement with findings of Degernes (1) and Satterfield and O'Rourke (22) who mentioned that *Staph. aureus* has been cultured from 90% of the spontaneously occurring cases of bumblefoot in birds. *Staphylococcus aureus* is present in high concentrations in the dust of poultry houses, animal feed, and gut contents and even on the skin of animals (23, 24), so when the skin becomes compromised due to traumatic injuries, *Staphylococcus aureus* can invade the dermis, proliferate and cause inflammation (22). *Escherichia coli* was the second most frequent bacterial isolate, it was recovered from 10

out of the 16 chickens that revealed positive bacterial isolation. In chickens, there are about 10^6 colony forming units of *E. coli* per one gram of feces (25, 26) and this bacterium is found everywhere in poultry houses including food and water and it has been associated with a variety of disease problems in birds including bumblefoot (27, 28). *Proteus mirabilis* was also isolated from bumblefoot lesions of the diseased chickens involved in this study but in a lower proportion compared to *Staphylococcus aureus* and *E. coli*, it was recovered from only 2 out of the 16 chickens that revealed positive bacterial isolation. This finding can be attributed to the opportunistic nature of this pathogen following exposure of the foot to traumatic and infectious insults (29) and is in agreement with that of Ahmed and El Amin (30) who mentioned that *Proteus mirabilis* was isolated from an 18-month-old hen with bumblefoot and it was able to re-induce the disease experimentally when inoculated into the food pad of chickens.

References

1. Degernes, L. A. (1994). Trauma Medicine. In: Ritchie, B. W.; Harrison, G. J.; and Harrison, L. R. (Eds.). Avian Medicine: Principles and Application. Wingers Publishing Inc. Florida.
2. Hester, P. Y. (1994). The role of environment and management on leg abnormalities in meat-type fowl. Poultry. Sci., 73:904-915.
3. Barnes, H. J. (2003). Other Bacterial Diseases. In: Saif, Y. M.; Barnes, H. J.; Fadly, A. M.; Glisson, J. R.; McDougald, L. R. and Swayne, D. E. (eds). Diseases of Poultry, 11th edition. Iowa State Press.
4. McNamee, P. T. & Smyth, J. A. (2000). Bacterial chondronecrosis with osteomyelitis (femoral head) of broiler chicken: A review. Avian Pathol., 29: 253-270.
5. Abrahamsson, P.; Tauson, R. & Appleby, M. C. (1996). Behaviour, health and integument of four hybrids of laying hens in modified and conventional cages. Br. Poult. Sci., 37:521-540.
6. Barbour, E. K.; Hamadeh, S. K.; Hilan, C.; Kallas, M.; Eid, A. & Sakr, W. (1997). National surveillance of poultry diseases in Lebanon. Rev. Sci. Tech. Off. Int. Epiz., 16:770-775.
7. McMullen, P. (2004). A Pocket Guide to Poultry Health and Disease. 5M Enterprises Ltd., Poultry Health Services, Sheffield, UK.
8. Rodriguez-Lainz, A. J.; Hird, D. W.; Kass, P. H. & Brooks, D. L. (1997). Incidence and risk factors for bumblefoot (pododermatitis) in rehabilitated raptors. Prev. Vet. Med., 31: 175-184.
9. Reidarson, T. H.; McBrian, M. C.; Laurie, J. & Laurie, B. (1999). A novel approach to the treatment of bumblefoot in penguins. J. Avian Med. Surg., 13:124-127.
10. Müller, M. G.; Wernery, U. & Kösters, J. (2000). Bumblefoot and lack of exercise among wild and captive-bred falcons tested in the United Arab Emirates. Avian Dis., 44: 676-680.
11. Tarello, W. (2002). A possible relationship between bumblefoot responsive to potassium arsenite and micrococci in the blood of three birds of prey. Acta Vet. Hung., 50: 143-150.
12. Rose K. (2005). Common Diseases of Urban Wildlife: Birds. Part 2. The Australian Registry of Wildlife Health.
13. Luna, L. G. (1968). Manual of Histologic Staining Methods of the Armed Forces Institute of Pathology. 3rd edition. McGraw-Hill, New York.

14. Carter, G. R. (1990). Isolation and Identification of Bacteria from Clinical Specimens. In: Carter, G. R.; Cole, J. R. (Eds.) Diagnostic Procedures in Veterinary Bacteriology and Mycology. 5th edition, Academic Press Inc., San Diego, California.
15. Carter, G. R.; Chengappa, M. M. & Roberts, A. W. (1995). Essentials of Veterinary Microbiology. 5th edition, Williams & Wilkins, Baltimore, Philadelphia.
16. Aviagen Incorporated (2008). Parent Stock Management Manual of Ross 308. Aviagen™, Alabama, USA (www.aviagen.com).
17. Davidson, W. R.; Nettles, V. F.; Couvillion, C. E. & Howerth, E. W. (1985). Diseases diagnosed in wild turkeys (*Meleagris gallopavo*) of the southeastern United States. J. of Wildlife Dis., 21: 386-390.
18. Clark, S.; Hansen, G.; Mclean, P.; Bond, P. Jr.; Wakeman, W.; Meadows, R. & Buda, S. (2002). Pododermatitis in turkeys. Avian Dis., 46: 1038-1044.
19. Marques, M. V. R.; de Resende J. S.; Donatti R. V.; da Rocha Vilela D. A.; Ecco R. & da Silva Martins N. R. (2009). A bumblefoot outbreak and fatal septicemia in captive aquatic birds in Brazil. Ciência Rural (Santa Maria), 39: 1905-1907.
20. Ritter, G. D. (2008). Proposed pathogenesis of gangrenous dermatitis in chickens and attempts at experimental reproduction. Zoo Tecnica Int. World's Poult. J., 21: 52.
21. Kahn, C. M. & Line, S. (2010). The Merck Veterinary Manual. 10th Ed., Merck Publishing Group.
22. Satterfield, W. C. & O'Rourke, K. I. (1981). Staphylococcal bumblefoot [claw disease of birds]: Vaccination and immunomodulation in the early treatment and management. J. Zoo Anim. Med., 12: 95-98.
23. Cotter, P. F. & Taylor, R. L. (1987). *Staphylococcus aureus* carriage in commercial layers. Poult. Sci., 66 (Suppl. 1): 86.
24. Zhu, X. Y.; Wu, C. C. & Hester, P. Y. (1999). Induction of the delayed footpad and wattle reaction to killed *Staphylococcus aureus* in chickens. Poult. Sci., 78: 346-352.
25. Pleydell, E. J.; Brown, P. E.; Woodward, M. J.; Davies, R. H. & French, N. P. (2007). Sources of variation in the ampicillin-resistant *Escherichia coli* concentration in the feces of organic broiler chickens. Appl. Environ. Microbiol., 73: 203-210.
26. Lutful kabir, S. M. (2010). Avian colibacillosis and salmonellosis: A closer look at epidemiology, pathogenesis, diagnosis, control and public health concerns. Int. J. Environ. Res. Public Health, 7: 89-114.
27. Wallach, J. D. & Boever, W. J. (1983). Gamebirds, waterfowl, and ratites. In Diseases of Exotic Animals: Medical and Surgical Management, Philadelphia, WB Saunders Co.
28. Olsen, J. H. (1994). Anseriformes. In: Ritchie, B. W.; Harrison, G. J. & Harrison, L. R. (Eds.). Avian Medicine: Principles and Application; Abridged edition; Wingers Publishing Inc. Florida
29. Timoney, J. F.; Gillespie, J. H.; Scott, F. W. & Barlough, J. E. (1988). Hagan and Bruner's Microbiology and Infectious Diseases of Domestic Animals. 8th Ed. Cornell University Press, Ithaca and London.
30. Ahmed, H. E. & El Amin, E. D. M. (2008). Pathogenicity of *Proteus mirabilis* in bumble-foot in chickens. The Sudan j. Vet. Res., 23: 91-95.