



Epidemiological aspects of some equine viral diseases

E.B. Ata¹ , R.M. Shaapan² , A.A. Ghazy¹ , O.M. Kandil¹  and H.A. Abou-Zeina¹ 

¹Department of Parasitology and Animal Diseases, ²Department of zoonosis, Veterinary Research Institute, National Research Centre, Giza, Egypt

Article information

Article history:

Received March 11, 2022

Accepted June 06, 2022

Available online December 18, 2022

Keywords:

Epidemiology

Equines

Viral diseases

Prevalence

Transmission and control

Correspondence:

R.M. Shaapan

rmshaapan2005@yahoo.com

Abstract

Although different equine viruses' outbreaks have been recorded. However, the most important ones are the African horse sickness virus (AHSV), equine influenza virus (EIV), equine viral arteritis (EVA), Equine infectious anaemia virus (EIAV), and equine herpes viruses (EHV). To combat these diseases, it is imperative to understand their epidemiological aspects. So, the current review aims to highlight some epidemiological aspects including; causative agents, clinical forms, history, prevalence and geographical distribution, source of infection, and methods of transmission. The AHSV mainly causes pulmonary, and cardiac forms with high morbidity and mortality rates in Africa. The EIV is found all over the world and results in respiratory signs. The EVA has low morbidity and mortality rates and is mainly found in the Americas and Europe, its significance is due to the reproductive problems as abortion in mares and subfertility in stallions. The EIAV has low morbidity and mortality rates and causes long time course disease mainly of fever, and chronic anaemia or death. The EHV are the current most important pathogens due to their endemicity all over the world and their high morbidity. It causes respiratory, abortion, neonatal, and sometimes neurological manifestations. Aerosols and body excretions are the main sources of infection with EIV, EVA, and EHV. Venereal EVA transmission occurs through natural breeding or artificial insemination with the semen of infected or carrier stallions. The spreading of arboviruses is greatly affected by the vector activity like the AHSV which transmitted by the *Culicoides imicola* biting midges, and the EIAV by family *Tabanidae*. In general, it is recommended to take all epidemiological measures, including vaccinations and vector control, to limit the spread of such diseases and reduce economic losses.

DOI: [10.33899/ijvs.2022.133255.2195](https://doi.org/10.33899/ijvs.2022.133255.2195), ©Authors, 2023, College of Veterinary Medicine, University of Mosul.

This is an open access article under the CC BY 4.0 license (<http://creativecommons.org/licenses/by/4.0/>).

Introduction

The economic value of the horses is highly considerable. So, any infectious threat not only affects the endemic areas but also affects the exportation and importation process (1,2). Viral diseases are colossal threats to the human and animal populations. They have extended their geographic distribution and emerged in new regions of the world (3-6). Many diseases were underestimated due to using of serological methods as it more available and easier to practice (7-9). But, in the recent decades, molecular

detection and phylogeny become so important in monitoring the spreading (10,11). Morbidity and mortality from these diseases might affect the draft power, thereby, affecting food security and poverty level especially in rural areas (12).

Most equine viral diseases are notifiable ones but the African horse sickness (AHSV), equine influenza virus (EIV), equine viral arteritis (EVA), Equine infectious anaemia virus (EIAV), and equine herpesviruses (EHV) are the most important ones (13). The low economic importance of natural reservoirs (donkeys and mules) adding to its natural resistance to show clear clinical manifestations

affects the conducted studies and surveys. Accordingly, they must have the same focus of interest since they are abundant in number and have close contact with horses in several regions (14). The African horse sickness virus (AHSV) is one of the OIE notifiable diseases due to its devastating nature. It is endemic in some South and East countries of Africa adding to Asian South-East countries. The virus's endemicity depends mainly on the presence of the vertebrate reservoir and the lack of safe and effective vaccines for effective control strategies (15). The EIV is one of the most economically re-emerging pathogens causing respiratory problems due to its rapid spread and highly contagious nature adding to a wide range of affected hosts (16). The EVA disease has a significant economic impact on the breeding farms due to the occurrence of EVA-associated abortion outbreaks and the virus's ability to create carrier stallions (17). The "swamp fever" is a chronic infectious disease caused by the EIAV of the family Retroviridae. It has a significant economic effect on the equine industry due to its worldwide distribution adding to the obligatory elimination of infected cases (18). The Equine herpes viruses are the most important equine disease not only for their wide spread, but also due to their responsibility for causing different clinical forms adding to developing a latent infection status which prevents complete control of the disease (4,7). Not all available vaccines provide complete protection against abortion or even viremia (19). Egypt is an important centre for raising and marketing the pure breed of Arabian horses. The absence of appropriate monitoring surveys might threaten the horse industry locally and internationally (20). To combat equine diseases, it is imperative to understand their epidemiological situation (21). Accordingly, the presented review aims to outline the epidemiological situation of the most notifiable equine viral diseases, including causative agents, clinical signs, history and incidence, geographical distribution, and prevalence with special concern to the source of infection, and methods of transmission.

Causative agents

The AHSV is a double-stranded RNA virus belonging to the *Orbiviruses* genus in the family *Reoviridae*. With a diameter around 80 nm, it has nine antigenically different serotypes. The genome is composed of ten segments. The *Orbiviruses* are characterised by intragenic recombination occurrence. In AHSV, it was a result of exchanges between live attenuated vaccine viruses and field isolates. This mechanism resulted in increased virulence, expanded host range, increasing viral survival against host defences (22). The EIV type A is classified under the genus *Influenza A*, family *Orthomyxoviridae*, it has 8 segments of RNA strands with a negative sense, type D was also found in human and equines. The virus hemagglutinin (HA) and neuraminidase (NA) proteins are the essential surface spikes and antibodies produced against the first one can block virus-cell entrance

and antigenic drift at this gene could result in the problem of vaccine failure. While antibodies against NA result in virus aggregation inside the host cell and hinder its release (23). The EVA is an enveloped virus with a 12.7-kb positive-sense, single-stranded, infectious RNA genome. It is classified as the prototype member of the family Arteriviridae, the new genus *Equarterivirus*. There is only one known serotype. It is highly species specific as it only infects members of the family *Equidae* (24). The EIAV has a diameter of 115 nm. It contains two copies of single-stranded, positive-sense RNA genome about 8.2 Kbp and is classified under the genus *Lentivirus*, subfamily of *Orthoretrovirinae*, and family of *Retroviridae*. It is related to bovine immunodeficiency virus (BIV) and HIV. As they were derived from a single ancestor. Although viral proteins are immunogenic, but the provoked antibodies do not have the capability of infection elimination (25). Nine herpesviruses have been identified to infect the family *Equidae*. The EHV1 is classified under genus *Varicellovirus*, subfamily *Alphaherpesvirinae*, family *Herpesviridae*, the virion is 200-250 nm in diameter and has a double stranded DNA of 150 kbp (26). EHV-1 and EHV-4 have extensive antigenic cross-reactivity, and both were discriminated as the primary cause of abortion and respiratory signs in different outbreaks (27). (Figure 1).

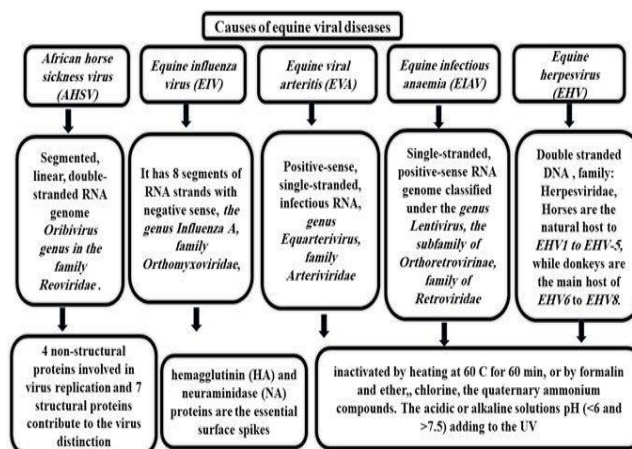


Figure 1: Causative agents and genetic criteria of some equine viral diseases (4).

Clinical signs

Infection of horses with African horse sickness (AHSV) may result in developing one of the 4 clinical forms cardiac, pulmonary, mixed pulmonary and cardiac, adding to the sickness fever form. Mules usually develop pulmonary and mixed forms. Zebras rarely develop serious clinical signs. The mildest form tends to be in resistant species such as donkeys, or horses with partial immunity. This form can also occur in zebras, although mostly are asymptomatic (28) (Figure 2).

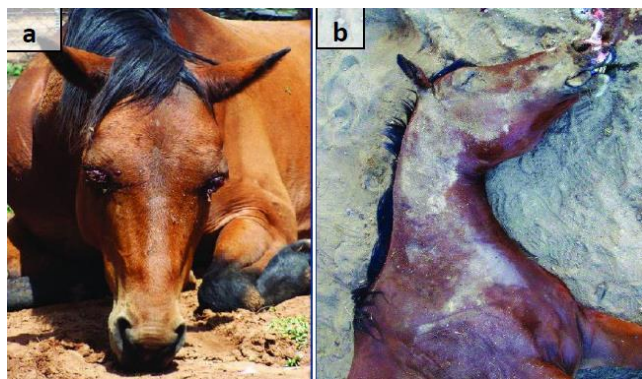


Figure 2: Sub-acute (a) & per-acute-acute-(b) form of African-horse-sickness (28).

The equine influenza virus (EIV) infected donkeys could develop more severe clinical respiratory signs compared to other equids due to bacterial broncho-interstitial pneumonia or due to coinfection with pulmonary nematodes. Usually, the infected horses did not develop carriers, and the vaccinated animals may exhibit no clinical signs and may go unnoticed (29). Although the disease is classified as a self-limiting disease and not life-threatening, but the presence of secondary bacterial infection complicates the case (30) (Figure 3).



Figure 3: Coughing-horse during equine influenza viral infection (6).

Natural infection with equine viral arteritis (EVA), results in subclinical or mild symptoms, the most significant losses are due to the reproductive form expressed as abortion in 70% of mares. It could occur at any time but mainly after the first third of pregnancy with or without previous signs (24). The infected stallions suffer from deterioration of semen quality, resulting in subfertility status for 2 months (31).

All equines are susceptible for the equine infectious anaemia virus (EIAV), infection. Although any of the

disease's signs could appear, the donkeys showed reduced fever and less or no clinical manifestations. The chronic form was developed in horses recovered from the acute infection with moderate to severe haemolytic anaemia, recurrent febrile episode, and weight loss. The resistant animals become inapparent carriers with a reduced intensity of signs within 1-2 years and remain infected for all life span but stress or immunosuppression induce these viremia and reactivation episodes (32).

The equine herpes viruses (EHV) infection usually results in one of respiratory, abortion, neonatal, and equine herpes myeloencephalopathy (EHM) forms. Lesions were more severe in the mare's aborted foetuses in comparison with those from she-donkey. The aborted foetuses showed pulmonary oedema with bronchial secretions, necrotic hepatic areas adding to oedematous and congested placenta (33). The nervous signs are due to ischemic degeneration in the central nervous system. The incubation period for the EHM is challenging to determine because the primary infection could occur a long time before (34).

Prevalence and geographical distribution

Although morbidity and mortality rates due to AHSV are very high, it depends on different factors. The disease is endemic in tropical and subtropical areas of Africa, south of the Sahara, from Senegal in the west to Ethiopia and Somalia in the east and extending as far south as South Africa (35). Most of the serological studies indicated circulating of the disease with a high seroprevalence rate of 75% in the studied donkeys and 63% in horses of Ethiopia and Zimbabwe (36). In Gambia, 96% of the tested horses and donkeys were seropositive for AHS serotype 9 (37). All AHSV serotypes are circulating in Namibia, and Zimbabwe except for AHSV-8 with the AHSV-9 and AHSV-6 were the most prevalent serotypes detected in donkeys (38). A recent outbreak was reported in Thailand with afraid of being a threat to other Asian countries as sometimes the virus jumps out of endemic regions and spread far away as India and Pakistan (39) (Figure 4).

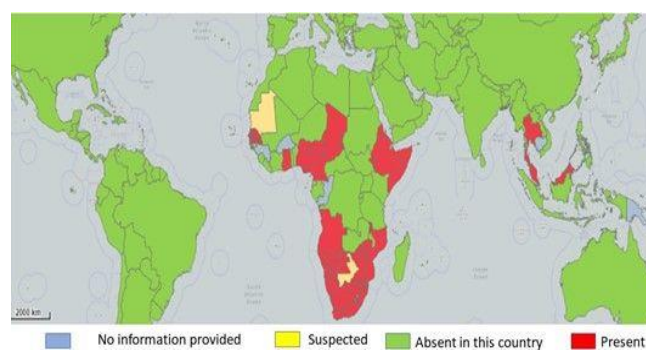


Figure 4: World map shows the prevalence of African horse sickness virus (AHSV) (13).

The EIV infection is characterised by high morbidity and low mortality rates. In the spring of 2003, the virus was confirmed in a large outbreak in the UK. In 2020 many outbreaks occurred even in the vaccinated animals (40). Since 2007, many South Asian and European countries reported the presence of multiple outbreaks. All of the viruses belong to Florida sub lineage clade 1. Many countries in Africa in 2018 and 2019 reported multiple mortalities in horses and donkeys (35). In Canada, a survey revealed a 56% morbidity rate with the H3N8 was the predominant type. While in a previous study on racing horses the prevalence was 76%. Recently, only 49 samples were positive out of 140 horses and 40 donkeys (41). In Brazil, Antibodies against *EIV* were detected in 44.7 % of the tested horses. Widespread outbreaks caused by Florida clade 1 viruses were recorded in 2018/2019. It started in South America and transferred to many European countries (16) (Figure 5).

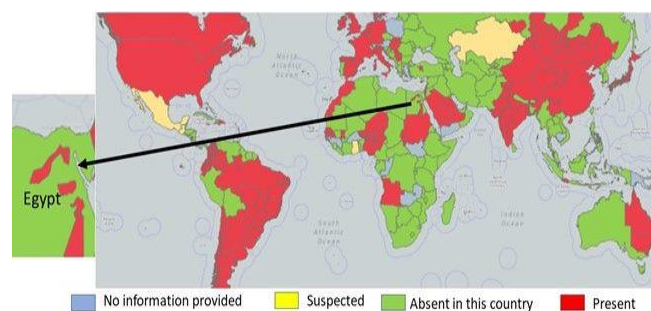


Figure 5: World map shows the prevalence of equine influenza virus (EIV) (13).

The EVA has low morbidity and low mortality rates, the worldwide epidemiological studies showed its prevalence across parts in North and South America, Africa, Asia, and Europe. Iceland and Japan are apparently healthy. New Zealand succeeded in the virus's eradication. The seroprevalence of *EVA* infection varies between and within the same countries (42). In 1998 only 0.6% of the horses showed seropositivity to the *EVA* in the USA but during 2007, a significant rise was recorded (43). The virus was detected for the first time in Serbia in 2017, with a low rate of 16 % (44). In Poland, the rate raised to be 92% and 71% in tested mares and stallions respectively (45). In the last 20 years, *EVA* in donkeys was recorded in many countries of Asia, Europe, and America (Figure 6).

Since the beginning of the 21th century, multiple outbreaks of EIAV were reported in areas with intensive equine industry. In 2009, a major outbreak was reported in France (46), Germany during 2020 although the country was free since 2017. In Mongolia during 2016, only 1.4% overall seroprevalence rate was recorded, positive samples were relatedness to genotypes from Europe with no relation with those near China and Japan (47). Nearly 3.3% of the examined Brazilian Donkeys sera were found to be positive.

Interestingly, no clinical signs were observed which magnifies their epidemiological role. The disease is highly endemic in South American countries have one of the largest equine populations (48). EIAV tends to reoccur after a long gap of time as in India 1999 then 2012 (32). In France during 2000 and 2009 (46). Surveillance of the most important infectious diseases including the *EIAV* in the UK during 2000 showed an absence of clinical cases (49). Recent surveys in Middle East countries revealed an absence in Israel, Saudi Arabia, and the Gulf area (50) (Figure 7).

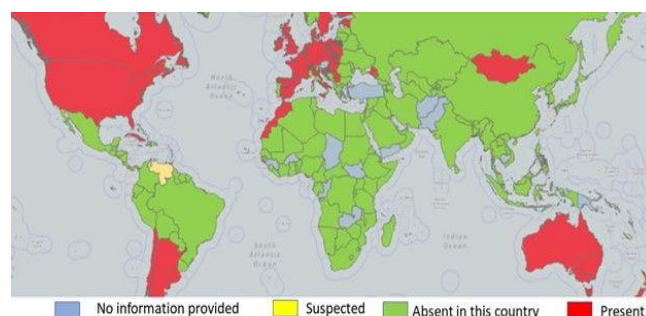


Figure 6: World map shows the prevalence of equine viral arteritis (EVA) (13).

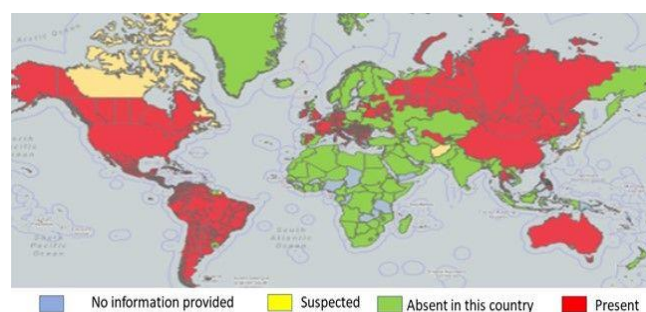


Figure 7: World map shows the prevalence of equine infectious anaemia virus (EIAV) (13).

The EHV disease is characterised by high morbidity and low mortality rates, however, sometimes deaths could be up to 40%. The disease is endemic worldwide even in countries using the vaccine for control. Outbreaks are notified to the OIE periodically from many countries; France, Great Britain, and Belgium, in the United States, in New Zealand, Australia, Chile, Argentina, Israel, and United Arab Emirates (51) (Figure 8).

Source of infection and methods of transmission

The *Culicoides imicola* biting midges is the main biological vector for AHSV transmission. Also, *Anopheles stephensi* and *Aedes aegypti* were involved in the biological transmission of AHSV. The, but the importance of these types in the epidemiology of the virus remains unclear (52). AHSV was also isolated from the camel tick with transstadial

transmission only (53). Furthermore, the brown dog tick was capable of transmission to dogs and horses. An earlier study suggested that *Stomoxys calcitrans* can mechanically transmit the virus (54). Regarding EIAV, blood from infected cases is the main source of infection. Mechanical transmission usually occurs through horseflies and deerflies of the family *Tabanidae*. Stable flies (*Stomoxys calcitrans*), and mosquitoes can transmit the virus but less efficiently. Also, it could be transmitted iatrogenically through transfusion with contaminated blood or its products or blood-contaminated needles and other veterinary surgical instruments (55).

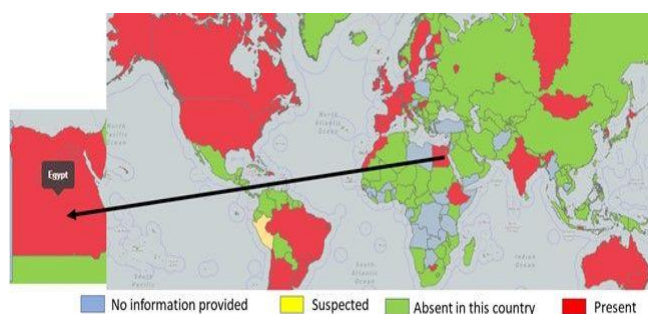


Figure 8: World map shows the prevalence of equine herpesviruses (EHV) (13).

Excretion of virus particles in the different body secretions from sub-clinically infected (partially immunized) or those incubating the disease is the main source of horizontal transmission of many viruses. The EIV is highly contagious and spreads rapidly between susceptible hosts horses as a result of coughing, ocular and nasal discharge. The aerosol can spread effectively through the air up to 1-2 km of distance (56). The same route was cleared in EVA (57), and EHV transmission (58). The aborted tissues and placental fluids contain a high amount of viruses so they are the main source of infection either directly or indirectly through contaminated fomites. Many studies considered latently infected cases are the main source of infection after their reactivation (4).

Venereal virus transmission occurs through natural breeding or artificial insemination with infective semen obtained from acutely infected or carrier stallions (the only reservoir) or even embryo transfer from mares inseminated with infective semen to native recipient ones as in EVA (57). In EIAV possibly could occur if the mare's vagina had lacerations as experimental subcutaneous inoculation of infected semen resulted in disease occurrence (59). Although EHV1 was detected by PCR in the stallion's semen but the risk of transmission by venereal route is unclear (60). Lastly, vertical transmission of EIAV might happen in utero, at parturition, or following the ingestion of infected colostrum or milk. But trans-placental transmission appears to be very rare (25), and sometimes in AHSV (Figure 9).

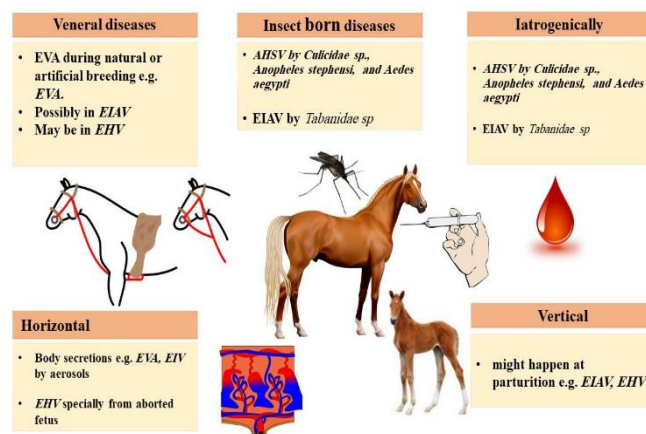


Figure 9: Schematic diagram explains the sources and methods of equine viral diseases transmission (54).

Conclusion

Equines are of great economic importance in the old and recent history. Most of the equine viral diseases were recorded a long time ago even with different names but with similar clinical signs. Some of these viruses could persist for a long time and form carrier status. Aerosols and body excretions are the main sources of infection with EIV, EVA, and EHV but insect vectors have an important role in the transmission of arboviruses like AHSV and EIAV. Accordingly, adherence to the scientific rules of preventive immunizations and taking all health measures to combat insects, which are the main carriers of some viral diseases that affect horses, are very important ways to reduce horse infection and reduce economic losses.

Acknowledgments

Author wishes to thank knowledge his colleges in the both Department of Parasitology and Animal Diseases and Department of Zoonotic Diseases, Veterinary Research Institute NRC for supporting and providing facilities.

Conflict of interest

The authors of the current work declare that they have no conflicts of interest in this work.

References

- Shaanpan RM, Abo-ElMaaty AM, Abd El-Razik KA, Abd El-Hafez SM. PCR and Serological Assays for Detection of *T. gondii* Infection in Sport Horses in Cairo, Egypt. *Asian J Anim Vet Adv.* 2012;7(2):158-165. [\[available at\]](#)
- Cassidy R. *The Global Horseracing Industry: Social, Economic and Ethical Perspectives* by Phil Mcmanus, Glenn Albrecht, And Raewyn Graham, Routledge, London, UK and New York, NY, USA, ISBN 978 0 4156 7731 8 (hardback), 2014;52, 110-111. DOI: [10.1111/1745-](https://doi.org/10.1111/1745-)

- [5871.12045](#)
3. Abou-Zeina HA, Nasr SM, Nassar SA, Farag TK, El-Bayoumy MK, Ata EB, Hassan NMFF, Abdel-Aziem SH. Beneficial effects of antioxidants in improving health conditions of sheep infected with foot-and-mouth disease. *Trop Anim Hlth Prod.* 2019;51:2379-2386. DOI: [10.1007/s11250-019-01952-9](#)
 4. Ata EB, Zaghawa A, Ghazy AA, Elsify A, Shaapan RM. Equine herpes virus type-1 infection: Etiology, epidemiology, pathogenesis, identification and recent published in Asian J Epidemiol. 2018;11(1):34-45. DOI: [10.3923/aje.2018.34.45](#)
 5. Mahmoud MA, Ghazy AA, Shaapan RM. Diagnosis and control of foot and mouth disease (FMD) in dairy small ruminants; Sheep and goats. *Int J Dairy Sci.* 2019;14:45-52. DOI: [10.3923/IJDS.2019.45.52](#)
 6. Yang Wen-Tao, Yang W, Jin YB, Ata EB, Zhang RR, Huang H, Shi CW, Jiang YL, Wang JZ, Kang YH, Yang GL, Wang CF. Synthesized swine influenza NS1 antigen provides a protective immunity in a mice model. *J Vet Sci.* 2020;21:e66. DOI: [10.4142/jvs.2020.21.e66](#)
 7. Ata EB, Ghazy AA, Shaapan RM. Equine herpesvirus-1 infection, clinical features, treatment and control. *Adv Anim Vet Sci.* 2020;8:368-378. DOI: [10.17582/journal.aavs/2020/8.6.668.679](#)
 8. Kandil OM, Hassan NMF, Sedky D, Ata EB. Studies on the specific immunodiagnosis of cystic echinococcosis in camels using enzyme-linked immunosorbent assay. *Bulg J Vet Med.* 2019;22:305-313. DOI: [10.15547/bjvm.2136](#)
 9. Mahmoud MA, Ghazy AA, Shaapan RM. Review of diagnostic procedures and control of some viral diseases causing abortion and infertility in small ruminants in Egypt. *Iraqi J Vet Sci.* 2021;35(3):513-521. DOI: [10.33899/ijvs.2020.127114.1461](#)
 10. Ata EB, Allam AM, Elbayoumy MK, Mahmoud MA. Electron microscopy and phylogenetic analysis of bovine papillomavirus infection in cattle from four Egyptian governorates. *Trop Anim Hlth Prod.* 2021;53:160. DOI: [10.1007/s11250-021-02607-4](#)
 11. Kandil OM, Abdelrahman KAA, Mahmoud MSS, Mahdy OA, Ata EB, Aloufi AS, Al-Olayan E. Cystic echinococcosis: Development of an intermediate host rabbit model for using in vaccination studies. *Exp Parasitol.* 2020;208:107800. DOI: [10.1016/j.exppara.2019.107800](#)
 12. Shaapan RM, Toaleb NI, Abdel-Rahman EH. Detection of *Toxoplasma gondii*-specific immunoglobulin (IgG) antibodies in meat juice of beef. *Iraqi J Vet Sci.* 2021;35(2):319-324. DOI: [10.33899/ijvs.2020.126829.1390](#)
 13. OIE-WAHIS, 2021. Diseases situation. [[available at](#)]
 14. Al-Saadi MH. Development of in-house Taqman qPCR assay to detect equine herpesvirus-2 in Al-Qadisiyah city. *Iraqi J Vet Sci.* 2020;34(2):365-371. DOI: [10.33899/ijvs.2019.126076.1229](#)
 15. Castillo-Olivares J. African horse sickness in Thailand: Challenges of controlling an outbreak by vaccination. *Equine Vet J.* 2021;53:9-14. DOI: [10.1111/evj.13353](#)
 16. Daly JM, Megid J, Langoni H, de Nardi Júnior G, Ribeiro MG. Retrospective serological survey for influenza in horses from Brazil. *Braz J Microbiol.* 2021;52:461-466. DOI: [10.1007/s42770-020-00398-8](#)
 17. Cruz-Lopez F, Newton R, Sanchez-Rodriguez A, Ireland J, Mughini-Gras L, Moreno MA, Fores P. Equine viral arteritis in breeding and sport horses in central Spain. *Res Vet Sci.* 2017;115:88-91. DOI: [10.1016/j.rvsc.2017.01.022](#)
 18. Machado G, Corbellini LG, Frias-De-Diego A, Dieh GN, dos Santos DV, Jara M, de Freitas Costa E. Impact of changes of horse movement regulations on the risks of equine infectious anemia: A risk assessment approach. *Prev Vet Med.* 2021;190:105319. DOI: [10.1016/j.prevetmed.2021.105319](#)
 19. Abdelrahman KA, Ghazy AA, Beshir A E. Better understanding of important aspects associated with vaccines development for controlling viral diseases in animals. *Int J Dairy Sci.* 2020;15:114-122. DOI: [10.3923/ijds.2020.114.122](#)
 20. Ata EB, Nasr SM, Mohamed AM, El-Aziz THAA, Fouad EA, Sedky D, Nassar SA, Ghazy AA. Bacteriological, hematological and biochemical diagnostic studies on diarrheic arabian horse foals caused by enterobacterial infections. *Adv Anim Vet Sci.* 2020;8:258-260. DOI: [10.17582/journal.aavs/2020/8.4.412.421](#)
 21. AL-Mola GM, Al-Saad KM. Clinical and pathological study of equine babesiosis in draught horses in Mosul. *Iraqi J Vet Sci.* 2006;20(1):89-101. DOI: [10.33899/ijvs.2006.45787](#)
 22. Ngoveni HG, van Schalkwyk A, Koekemoer JJO. Evidence of intragenic recombination in african horse sickness virus. *Viruses* 2019;11:654. DOI: [10.3390/v11070654](#)
 23. Nedland H, Wollman J, Sreenivasan C, Quast M, Singrey A, Fawcett L, Christopher-Hennings J, Nelson E, Kaushik RS, Wang D, Li F. Serological evidence for the co-circulation of two lineages of influenza D viruses in equine populations of the Midwest United States. *Zoon Pub Heal.* 2018;65:e148-e154. DOI: [10.1111/zph.12423](#)
 24. James N, MacLachlan E, Dubovi J. *Arteriviridae and Roniviridae*. NY: Elsevier; 2017. 463-476 p. DOI: [10.1016/B978-0-12-800946-8.00025-8](#)
 25. Gomez-Lucia E. *Animal Lentiviruses*. NY: Elsevier; 2021. 56-67 p. DOI: [10.1016/B978-0-12-814515-9.00005-9](#)
 26. Badr Y, Okada A, Abo-Sakaya R, Beshir E, Ohya K, Fukushi H. Equine herpesvirus type 1 ORF51 encoding UL11 as an essential gene for replication in cultured cells. *Arch Virol.* 2018;163:599-607. DOI: [10.1007/s00705-017-3650-4](#)
 27. Saklou NT, Burgess BA, Ashton LV, Morley PS, Goehring LS. Environmental persistence of equid herpesvirus type-1. *Equine Vet J.* 2021;53:349-355. DOI: [10.1111/evj.13313](#)
 28. Wernery U, Joseph S, Raghavan R, Dyer B, Spendrup S. African horse sickness fever in vaccinated horses: Short communication. *J Equine Vet Sci.* 2020;88:102967. DOI: [10.1016/j.jevs.2020.102967](#)
 29. Yang H, Xiao Y, Meng F, Sun F, Chen M, Cheng Z, Chen Y, Liu S, Chen H. Emergence of H3N8 equine influenza virus in donkeys in China in 2017. *Vet Microbiol.* 2018;214:1-6. DOI: [10.1016/j.vetmic.2017.11.033](#)
 30. Newton JR, Elton D, Cullinane A. World status of equine influenza. NY: Elsevier; 2015. 165-170 p. DOI: [10.1016/B978-1-4557-4555-5.00039-X](#)
 31. Balasuriya UBR, Equine Viral Arteritis. *Vet Clin North Am Equine Pract.* 2014;30:543-560. DOI: [10.1016/j.cveq.2014.08.011](#)
 32. Malik P, Singha H, Sarkar S. *Equine Infectious Anemia*. China: Springer International Publishing; 2017. 215-235 p. DOI: [10.1007/978-3-319-47426-7_8](#)
 33. Ali AA, Refat NA, Algabri NA, Sobh MS. Fetal lesions of EHV-1 in equine. *An Acad Bras Cienc.* 2020;92. DOI: [10.1590/0001-376520200180837](#)
 34. Brosnahan MM, Al Abri MA, Brooks SA, Antczak DF, Osterrieder N. Genome-wide association study of equine herpesvirus type 1-induced myeloencephalopathy identifies a significant single nucleotide polymorphism in a platelet-related gene. *Vet J.* 2019;245:49-54. DOI: [10.1016/j.tvjl.2018.12.013](#)
 35. OIE (World Organisation for Animal Health), African horse sickness, aetiology epidemiology diagnosis prevention and control references. *Anim Heal Inf Database.* 2021;1-4. [[available at](#)]
 36. Gordon SJG, Bolwell C, Rogers CW, Musuka G, Kelly P, Guthrie A, Mellor PS, Hamblin C. The sero-prevalence and sero-incidence of African horse sickness and equine encephalosis in selected horse and donkey populations in Zimbabwe. *Onderstepoort J Vet Res.* 2017;84:1-5. DOI: [10.4102/ojvr.v84i1.1445](#)
 37. Oura CAL, Ivens PAS, Bachanek-Bankowska K, Bin-Tarif A, Jallow DB, Sailleau C, Maan S, Mertens PC, Batten CA. African horse sickness in the Gambia: Circulation of a live-attenuated vaccine-derived strain. *Epidemiol Infect.* 2012;140:462-465. DOI: [10.1017/S095026881100080X](#)
 38. Molini U, Zaccaria G, Kandiwa E, Mushonga B, Khaibeb S, Ntahonshikira C, Chiwome B, Baines I, Madzingira O, Savini G, D'Alterio N. Seroprevalence of African horse sickness in selected donkey populations in Namibia. *Vet World.* 2020;13:1005-1009. DOI: [10.14202/vetworld.2020.1005-1009](#)
 39. Lu G, Pan J, Ou J, Shao R, Hu X, Wang C, Li S. African horse sickness: Its emergence in Thailand and potential threat to other Asian countries. *Transbound Emerg Dis.* 2020;13625. DOI: [10.1111/tbed.13625](#)

40. Bamba W, Daly JM, Kendall NR, Gardner DS, Brennan M, Kydd JH. Equine influenza vaccination as reported by horse owners and factors influencing their decision to vaccinate or not. *Prev Vet Med.* 2020;180:105011. DOI: [10.1016/j.prevetmed.2020.105011](https://doi.org/10.1016/j.prevetmed.2020.105011)
41. Bolfa P, Jeon I, Loftis A, Leslie T, Marchi S, Sithole F, Beck C, Lecollinet S, Zientara S, Hans A, Issel CJ. Detection of West Nile Virus and other common equine viruses in three locations from the Leeward Islands, West Indies. *Acta Trop.* 2017;174:24-28. DOI: [10.1016/j.actatropica.2017.06.023](https://doi.org/10.1016/j.actatropica.2017.06.023)
42. McFadden AM, Pearce PV, Orr D, Nicoll K, Rawdon TG, Pharo H, Stone M. Evidence for absence of equine arteritis virus in the horse population of New Zealand. *N Z Vet J.* 2013;61:300-304. DOI: [10.1080/00480169.2012.755664](https://doi.org/10.1080/00480169.2012.755664)
43. Zhang J, Stein DA, Timoney PJ, Balasuriya UBRR. Curing of HeLa cells persistently infected with equine arteritis virus by a peptide-conjugated morpholino oligomer. *Virus Res.* 2010;150:138-42. DOI: [10.1016/j.virusres.2010.02.013](https://doi.org/10.1016/j.virusres.2010.02.013)
44. Lazić S, Lupulović D, Gaudaire D, Petrović T, Lazić G, Hans A. Serological evidence of equine arteritis virus infection and phylogenetic analysis of viral isolates in semen of stallions from Serbia. *BMC Vet Res.* 2017;13:316. DOI: [10.1186/s12917-017-1226-x](https://doi.org/10.1186/s12917-017-1226-x)
45. Socha W, Sztromwasser P, Dunowska M, Jaklinska B, Rola J. Spread of equine arteritis virus among Hucul horses with different EqCXCL16 genotypes and analysis of viral quaspecies from semen of selected stallions. *Sci Rep.* 2020;10:2909. DOI: [10.1038/s41598-020-59870-y](https://doi.org/10.1038/s41598-020-59870-y)
46. Gaudaire D, Lecouturier F, Ponçon N, Morilland E, Laugier C, Zientara S, Hans A. Molecular characterization of equine infectious anaemia virus from a major outbreak in southeastern France. *Transbound Emerg Dis.* 2018;65:e7-e13. DOI: [10.1111/tbed.12657](https://doi.org/10.1111/tbed.12657)
47. Sharav T, Konnai S, Ochirkhuu N, Ts EO, Mekata H, Sakoda Y, Umemura T, Murata S, Chultendorj T, Ohashi K. Detection and molecular characterization of equine infectious anemia virus in Mongolian horses. *J Vet Med Sci.* 2017;79:1884-1888. DOI: [10.1292/jvms.17-0202](https://doi.org/10.1292/jvms.17-0202)
48. Espasandin AG, Cipolini MF, Forletti A, Díaz S, Soto J, Martínez DE, Storani CA, Monzón NM, Beltrame JI, Lucchesi E, Soto P. Comparison of serological techniques for the diagnosis of equine infectious anemia in an endemic area of Argentina. *J Virol Methods* 2021;291:114101. DOI: [10.1016/j.jviromet.2021.114101](https://doi.org/10.1016/j.jviromet.2021.114101)
49. Newton R, Whitlock F, O'Brien M, Carson D, Smith S. Equine disease surveillance: quarterly update. *Vet Rec.* 2020;187. DOI: [10.1136/vr.m3492](https://doi.org/10.1136/vr.m3492)
50. Alqahtani AS. Investigation of some zoonotic viruses at south western of Saudi Arabia. *Am J Anim Vet Sci.* 2020;15:108-112. DOI: [10.3844/ajavsp.2020.108.112](https://doi.org/10.3844/ajavsp.2020.108.112)
51. Kydd JH, Lunn DP, Osterrieder K. Report of the fourth international havemeyer workshop on equid herpesviruses (EHV) EHV-1, EHV-2 and EHV-5. *Equine Vet J.* 2019;51:565-568. DOI: [10.1111/evj.13141](https://doi.org/10.1111/evj.13141)
52. Riddin MA, Venter GJ, Labuschagne K, Villet MH. *Culicoides* species as potential vectors of African horse sickness virus in the southern regions of South Africa. *Med Vet Entomol.* 2019;33:498-511. DOI: [10.1111/mve.12391](https://doi.org/10.1111/mve.12391)
53. Carpenter S, Mellor PS, Fall AG, Garros C, Venter GJ. African horse sickness virus: History, transmission, and current status. *Annual Rev Entomol.* 2017;62:343-358. DOI: [10.1146/annurev-ento-031616-035010](https://doi.org/10.1146/annurev-ento-031616-035010)
54. Mellor PS, Boorman J. The transmission and geographical spread of African horse sickness and bluetongue viruses. *Ann Trop Med Parasitol.* 1995;39:1-15. DOI: [10.1080/00034983.1995.11812923](https://doi.org/10.1080/00034983.1995.11812923)
55. De Liberato C, Magliano A, Autorino GL, Di Domenico M, Sala M, Baldacchino F. Seasonal succession of tabanid species in equine infectious anaemia endemic areas of Italy. *Med Vet Entomol.* 2019;33:431-436. DOI: [10.1111/mve.12360](https://doi.org/10.1111/mve.12360)
56. Chambers TM. A Brief introduction to equine influenza and equine influenza viruses. *Methods Mol Biol.* 2020;355-360. DOI: [10.1007/978-1-0716-0346-8_26](https://doi.org/10.1007/978-1-0716-0346-8_26)
57. Lattimer J, Roberts H, Barnard M, Paterson A, Bell I, Hepple R, Holland S, George A. Investigating an outbreak of equine viral arteritis at two connected premises. *Vet Rec.* 2020;187:e113-e113. DOI: [10.1136/vr.m4756](https://doi.org/10.1136/vr.m4756)
58. OIE (World Organisation for Animal Health). Equine rhinopneumonitis (infection with Equid herpes 1). 2017. [[available at](#)]
59. Noakes D, Parkinson T, England G. Dystocia and other disorders associated with parturition. Noakes DE, Parkinson TJ, England GCW. *Veterinary reproduction and obstetrics.* 9th ed. NY: Elsevier; 2009. 207-305 p.
60. Walter J, Balzer HJ, Seeh C, Fey K, Bleul U, Osterrieder N. Venereal shedding of equid herpesvirus-1 (EHV-1) in naturally infected stallions. *J Vet Intern Med.* 2012;26:1500-1504. DOI: [10.1111/j.1939-1676.2012.00997.x](https://doi.org/10.1111/j.1939-1676.2012.00997.x)

الجوانب الوبائية لبعض الأمراض الفيروسية التي تصيب الفصيلة الخيلية

عماد بشير عطا^١، رأفت محمد شعبان^٢، علاء عبد المنعم غازي^١،
أمينة محمد قنديل^١ و هالة عبدالله أبو زينة^١

^١ قسم الطفيليات وأمراض الحيوان، قسم الأمراض المشتركة، معهد البحوث البيطرية، المركز القومي للبحوث، الجيزة، مصر

الخلاصة

على الرغم من تسجيل إصابة الفصيلة الخيلية بالعديد من الفيروسات. لكن على مستوى مصر والعالم فإن أهمها هو فيروس مرض الخيل الأفريقي، فيروس إنفلونزا الخيول، التهاب الشرايين وفيروس فقر الدم المعدي، فيروسات هربس الخيول. وللسيطرة على أمراض الخيول من الضروري فهم الجوانب الوبائية لها. لذلك فإن هذه المراجعة البحثية تهدف إلى تسليط الضوء على المسببات، الصور المرضية، تاريخ ونشأة ظهور الأمراض، التوزيع الجغرافي، مصادر العدوى وطرائق انتقالها. يسبب فيروس مرض الخيل الأفريقي أعراضاً رئوية أو قلبية مع ارتفاع معدلات الانتشار والوفيات في أفريقيا بينما ينتشر فيروس إنفلونزا الخيول في جميع أنحاء العالم ويسبب أعراضاً تنفسية. أما فيروس التهاب الشرايين فهو قليل الانتشار قليل الوفيات ويوجد غالباً في الدول الأمريكية والأوروبية وأهميته الكبرى تعزى إلى الإجهاض في الإناث وانخفاض معدل الخصوبة في الطلائق. إن فيروس فقر الدم المعدي لديه معدلات إصابة ووفيات منخفضة ويؤدي إلى صورة مزمنة من الحمى وفقر الدم أو الوفاة. وتعد فيروسات هربس الخيول من أهم الأمراض الفيروسية حالياً بسبب توطنها في جميع أنحاء العالم وارتفاع معدلات الإصابة بها. على الرغم من انخفاض معدل الوفيات، إلا أنها تؤدي إلى أشكال سريرية متعددة إما تنفسية، أو الإجهاض، موت حديثي الولادة، وأحياناً أعراضاً عصبية. يعتبر الرذاذ وإفرازات الحيوانات المصابة هي المصادر الرئيسة للعدوى بالإنفلونزا والتهاب الشرايين والهربس. وينتقل أيضاً فيروس التهاب الشرايين عبر التلقيح الطبيعي أو الاصطناعي بالسائل المنوي من الطلائق الحاملة للفيروس. بينما تلعب النواقل الحشرية دوراً هاماً في نقل فيروس الخيل الإفريقي وفقر الدم. بشكل عام يوصى باتخاذ جميع التدابير الوبائية وبضمنها إجراء التحصينات والسيطرة على النواقل للحد من انتشار مثل هذه الأمراض والإقلال من الخسائر الاقتصادية.