

Role of Hydroxyapatite in Healing of Experimentally Induced Cutaneous Wound in Rabbits

A. A. Majeed and R. A. Al Naimi

College of Veterinary Medicine\ University of Baghdad

Abstract

The study was carried out to throw some light on the effect of intra-incisional application of hydroxyapatite on healing of recovered skin documented by histopathological evaluation in rabbit. Thirty adult local breed rabbits were used, divided randomly and equally into two groups: the first group (Control group), subjected to wound of the skin from their back (about 5 cm in length) then sutured with silk (No. 4-0). Similar technique was used for treated group with the exception of local application of hydroxyapatite powder inside the incision prior to closure it. The operation was performed under the effect of general anesthesia represented by a mixture of xylazine-ketamine in a dose of 20 mg/kg and 35 mg/kg B.W., respectively, which were administered intramuscularly. During a clinical- follow of all animals, we trapped two cases of stitch abscess in the control group and one in treated group, which showed a response to medical treatment. Histopathological examination was performed on (3, 5, 7, 14 and 21) days post-wounding. Results revealed infiltration of large numbers of neutrophils with the formation of granulation tissue in the first periods in both groups, while fibrous connective tissue rich in dense collagen fibers were noticed in control group covered with necrotic tissue containing dead neutrophils and complete resolution of the skin with formation of fibrous connective tissue in the treatment group at the end of experiment. In conclusion, the Hydroxyapatite, promote wound healing because it attracts the macrophages and fibroblasts rapidly to the wound site.

دور الهيدروكسي أبيتايت في شفاء الجروح الجلدية المحدثّة تجريبياً في الأرانب

عبير احمد مجيد وراحة عبد الستار النعيمي

كلية الطب البيطري/ جامعة بغداد

الخلاصة

استهدفت الدراسة تسليط الضوء على دور الهيدروكسي ابيتايت في خياطة الجروح الجلدية المحدثّة تجريبياً في الأرانب معززة بدراسة مرضية- نسجية. اختير للبحث 30 أرنباً محلياً بالغاً، قسمت الحيوانات عشوائياً وبالتساوي إلى مجموعتين حيث عدت المجموعة الأولى (مجموعة سيطرة)، عمل لها جرح جلدي بطول 5 سم في جلد منطقة الظهر وتمت خياطته بخيط الحرير رقم (4.0)؛ أما المجموعة الثانية (مجموعة المعالجة) فعمل لها جرح جلدي بنفس الطول ثم وضع مسحوق الهيدروكسي ابيتايت داخل الجرح ثم تمت خياطته. أجري التداخل الجراحي لكل المجموعتين تحت تأثير المخدر العام المتمثل بمزيج الزايلازين- الكيتامين حيث حقن بالعضلة وبجرعة 20 ملغم/ كغم و 35 ملغم/ كغم على التوالي. ثم متابعة الحيوانات سريرياً حيث لوحظ وجود خمج لجرح الجلد في حيوانين عائدين لمجموعة السيطرة وحيوان واحد لمجموعة المعالجة حيث استجابوا للعلاج الطبي. أخذت مقاطع للفحص المرضي- النسجي من كافة الحيوانات خلال الفترات (3 و 5 و 7 و 14 و 21) يوماً من إحداث الجرح حيث أظهرت النتائج ارتشاح عدد كبير من خلايا العدلات مع تكون نسيج حبيبي في الفترات الأولى لكننا المجموعتين، وفي نهاية التجربة تكون نسيج ليفي غني بألياف الكولاجين مغطى بطبقة متخثرة تحتوي على العدلات الميتة في مجموعة السيطرة ولوحظ شفاء تام للجلد في مجموعة المعالجة. يمكن ان نستدل من النتائج التي حصلنا عليها بأن مسحوق الهيدروكسي ابيتايت له دور مهم في تسريع شفاء الجروح لأنه يجذب خلايا البلاعم وخلايا مولدة الكولاجين وبسرعة إلى الجرح.

Introduction

Hydroxyapatite is a component of bone. It is a calcium phosphate mineral that also found in rocks and sea coral (1). Plastic surgeons use Hydroxyapatite implants made from sea coral since have been treated to that their structure and chemical make-up is almost identical to the Hydroxyapatite of bone. When implanted in the body the synthetic implant is accepted by the body and because of its porous nature allow normal tissue integration to take place. Also, the process to create Hydroxyapatite implant from sea coral involves intense heat that removes all proteins thus rendering the structure totally non-immunogenic (i.e. it does not provoke allergic reaction). In addition to solid Hydroxyapatite implants there is also injectable Hydroxyapatite. Also, there is past which is non-porous so bone and soft tissue growth does not occur (2,3). Many modern implants e.g. hip replacement and dental implants are coated with Hydroxyapatite. It has been suggested that this may promote osseointegration. Also, Hydroxyapatite is marked as a "bone-building" supplement with superior absorption in comparison to calcium. It is a second-generation calcium supplement derived from bovine bone (4,5). Facial augmentation with Hydroxyapatite has been used for correction of cheek, chin, jaw, nose, and brow bone. Solid Hydroxyapatite can be carved and trimmed to the requirements of the correction. Because bone and soft tissue grows into pores of the implant is securely held in place. One time the implant is partially resorbed and replaced by natural bone. Implants are usually well tolerated and causes some discomfort directly after the implantation. There may be swelling, aching, and numbness but these usually resolve after a week or so (6,7). The aim of the present study is concentrated on the role of Hydroxyapatite in healing of experimentally induced cutaneous wound in rabbits supported by clinico- histopathological evaluations.

Materials and Methods

- **Experimental Animals:** A total of thirty adult local breed rabbits, of average age about (8-10) months and average weight (1.5-2) kg were used in this study. All rabbits were supplied from the same breeder, housed at the same conditions of temperature and humidity in especially designed wired cages in the animal housing of College of Veterinary Medicine, Baghdad University.
- **Pre-Operative Considerations:**
 1. Animals were fastened for 24 hrs for food and 12 hrs for water.
 2. The operative sites were prepared aseptically for surgical cutaneous incision.
 3. Anesthesia was accomplished by IM injection of Xylazine-Ketamine mixture in a dose of 20 mg/kg and 35 mg/kg B.W. respectively (8).
- **Experimental Design:** Animals were allocated into two main groups (15 rabbits for each group). The first group served as a control and the second group was the treatment group.
- **Technique of Skin Wound:** Animals were placed in ventral position, approximately 5 cm length incision was made on the skin of the back, bleeding was carefully arrested with fine hemostat. In the first group, skin was restitched with simple interrupted suture using non-absorbable thread (Silk No. 4-0). Then skin incision covered with sterile gauze to avoid contamination. In the second group, the same steps were applied with the exception of adding Hydroxyapatite powder (0.5 mg) inside the wound prior to suture it.

- **Post-Operative Cares and Follow-up:**
- 1. Animals were received broad spectrum antibiotics represented by penicillin-streptomycin in a dose of 50.000 IU/kg and 30 mg/kg B.W. respectively injected IM for 5 days.
- 2. The vital parameters which include, body temperature, pulse, and respiratory rate were monitored daily for the first week post-wounding.
- 3. All animals were followed-up for one month post-surgically to record any abnormalities which may happen.
- 4. The skin stitches were taken-off after 10 days when assuring complete healing or when secondary complications are not observed.
- **Histopathological Examination:** After 3, 5, 7, 14, and 21 days post-surgery, about 1 cm³ from the skin and S/C tissue were retrieved for histopathological examination, 15 animals used for each group (3 animals\ period). Tissue samples were fixed in 10% buffered neutral formalin passed routinely and section into 5-6 micron, stained with Hematoxylin and Eosin (H & E) (9) and examined under light microscope.

Results

- **Clinical Follow-up:** The cardinal signs of inflammation (i.e. redness, swelling, heat and pain) were seen locally at the incision site. The signs gradually subsided, particularly from 48 hrs post-operation onward, and disappeared within (4-5) days. Decreased body activity and anorexia was found in all rabbits during the first 48 hrs post wounding. The skin wound in all rabbits healed by first intention with the exception of two rabbits related to the control group and one rabbit related to treated group which revealed partial sutures dehiscence due to sepsis (stitch abscess), which was drained by removing of one stitches in the dependent part and the cavity was cleaned, debrided then inserted with a dressing gauze soaked in 1% solution of tincture of iodine.

All the vital parameters (body temperature, pulse, and respiratory rate) were within the normal range except of three rabbits that showed wound infection in which there is fever which responded to treatment used as post-operative cares.

- **Histopathological Findings:**
- **At Three Days:** In control group, the microscopical picture showed ulceration of the skin surface with infiltration of large numbers of neutrophils within the dermal area (Fig.1), while in treatment group, deep ulceration of the skin surface with infiltration of large number of neutrophils deeply in the dermis and on the ulcerated surface with deposition of small amount of calcium salt (Fig.2).
- **At Five Days:** The control group show similar pathological lesions as mentioned in previous period. In treatment group, there were large area of calcifications within the dermis and subcutaneous tissue (Fig.3).
- **At Seven Days:** In control group, the ulcerated surface was infiltrated with large number of neutrophils with hydropic degeneration of remnant epithelial cells of the epidermis with large numbers of dead neutrophils on the surface (Fig.4). In treatment group, there was proliferation of granulation tissue containing large number of congested blood capillaries and young fibroblasts beneath the hyalinized and the ulcerated surface which infiltrated with large number of dead neutrophils (Fig.5).
- **At 14 Days:** Histopathological section in control group revealed proliferation of granulation tissue beneath the ulcerated surface which was covered by fibrin network (Fig.6). Also in treatment group, there was formation of granulation tissue containing large numbers of dilated blood capillaries with complete regeneration of the surface epithelium (Fig.7).

- **At 21 Days:** At this time, in control group, there was formation of fibrous connective tissue with dense collagen fibers infiltrated with dead neutrophils and covered with necrotic tissue (Fig.8). In treatment group, complete resolution of the skin with formation of fibrous connective tissue in between and surrounding the calcified areas (Fig.9).

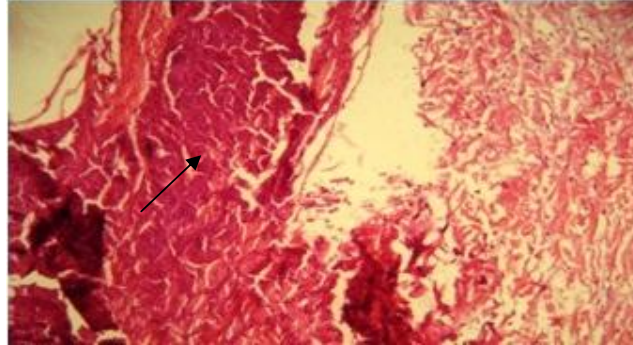


Fig. (1) Microscopic picture of skin related to control group at 3 days showed ulceration of the surface with infiltration of large number neutrophils (arrow) (H & E×10)

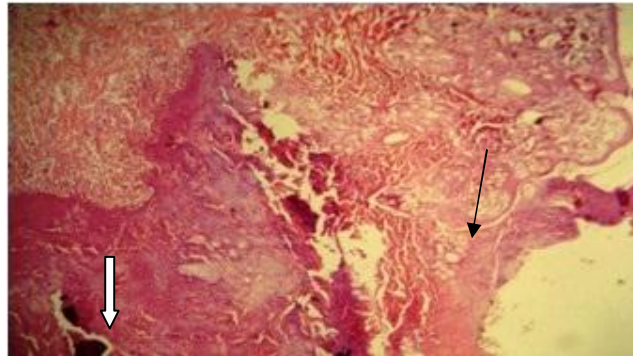


Fig. (2) Microscopic picture of treated group at 3 days showed deep ulceration of the skin surface (black arrow) with infiltration of large number of neutrophils and small areas of calcification (white arrow) (H & E × 40)

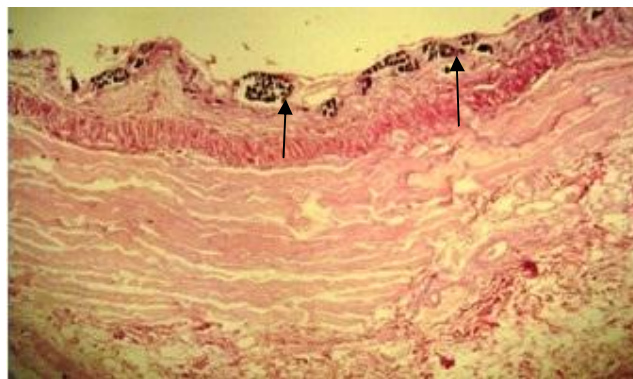


Fig. (3) Microscopic picture of treated group at 5 days showed multiple areas of calcification (arrows) within the subcutaneous tissue (H & E×10)

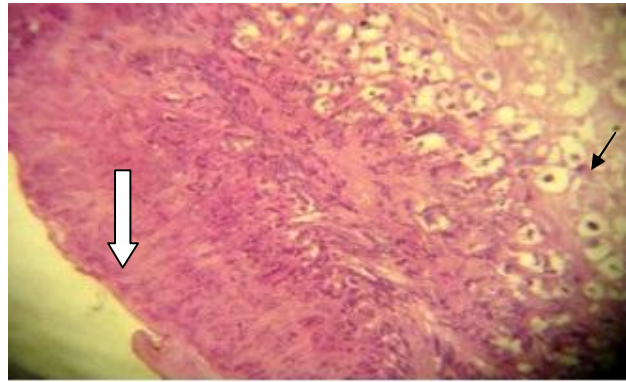


Fig. (4) Microscopic picture of control group at 7 days showed infiltration of neutrophils with hydropic degeneration (black arrow) and large number of dead neutrophils on the surface (white arrow) (H & E ×10)

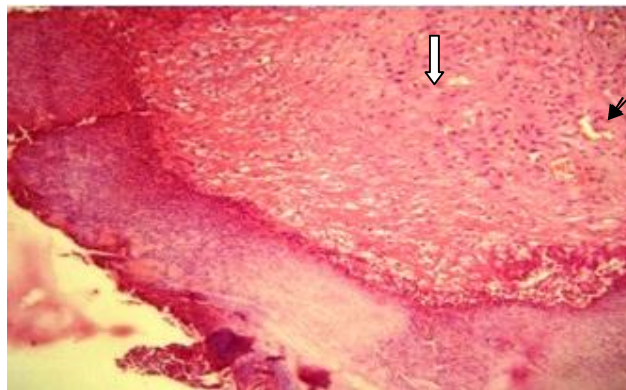


Fig. (5) Microscopic picture of treated group at 7 days showed proliferation of granulation tissue containing large numbers of congested blood capillaries (black arrow) and young fibroblast cells (white arrow) beneath the hyalinized and ulcerated surface (H & E ×40)

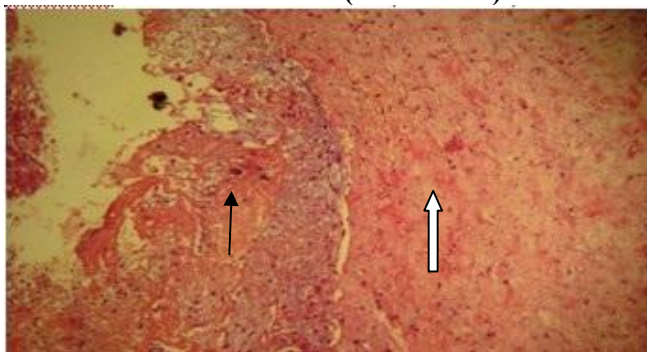


Fig. (6) Microscopic picture of control group at 14 days showed proliferation of granulation tissue (white arrow) beneath the ulcerated surface which is covered with fibrin network (black arrow) (H & E ×40)

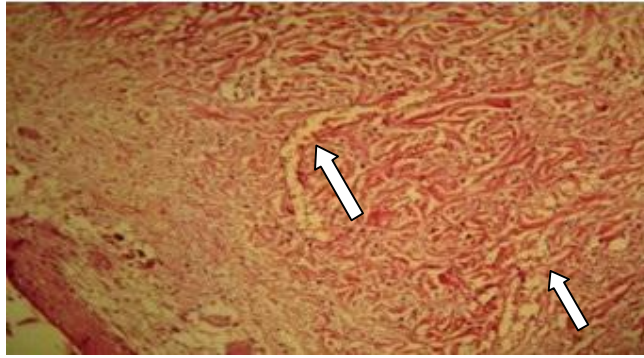


Fig (7) Microscopic picture of treatment group at 14 days showing formation of granulation tissue containing dilated blood capillaries(white arrows)with complete regeneration of surface epithelium (H & E ×40)

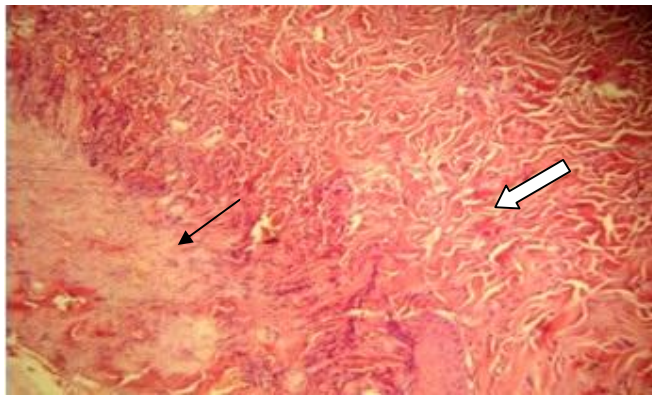


Fig (8) Microscopic picture of control group at 21 days showed formation of dense fibrous connective tissue(white arrow)covered with necrotic tissue containing dead neutrophils (black arrow) (H & E ×40)

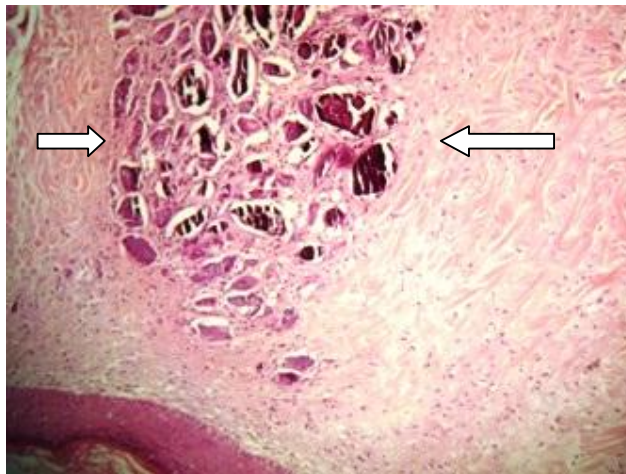


Fig. (9) Microscopic picture of treatment group at 21 days showed complete resolution of ulcerated surface with formation of fibrous connective tissue in between and surrounding the calcified areas (white arrows) (H & E ×10)

Discussion

Based upon the results obtained, it gave a clarity of the success of Hydroxyapatite in promoting of wound healing. No serious health problems were recorded after the follow-up with the exception of three rabbits suffered from minor non-specific complications represented by wound infection which can be explained as a possible complication of surgery. Schessel *et al.*, (10) referred that bacteria can enter the body during surgery or after surgery through suture and drain site or by way of open wound. Some infections could occur later (perhaps weeks or months) after surgery and could be related to trauma or minor injuries, such as scratch, this might induce infection, initiated in the skin then spreading inside. Hydroxyapatite has been widely used to produce biomaterials. It had a higher promoting effects on wound healing, re-epithelialization and matrix formation (11). The present results showed inflammatory reaction and an intense foreign body reaction and infiltration of large numbers of neutrophils were observed by day three post-operation, where as tissue growth into the uncoated control implants was much slower and took place mainly on their surface. The reaction in apatite-coated groups decline after post-operative day 14 because Hydroxyapatite favored angiogenesis and attract macrophages and fibroblasts to the wounded area (12). Tissue damage leads to the release of basic fibroblast growth factor normally sequestered within intact cells and extracellular matrix (13). In addition, bleeding and hemostasis in a wound, up regulated cellular receptors for vascular endothelial growth factor and potentiates this growth factor's effects (14). Endothelial cells exposed to thrombin also release gelatinase A, which promotes the local dissolution of basement membrane which is an essential early step of angiogenesis (15). Wound angiogenesis is amplified by inflammation, macrophages and monocytes release myriad angiogenic factors as they migrate into the wound bed (16). It is well known that Hydroxyapatite attract macrophages to the wound area. Recent studies have identified macrophages as critical regulators of fibrosis like myofibroblasts which are derived from either resident tissue populations, or from bone marrow immigrants. Studies now suggest that pathogenesis of fibrosis is tightly regulated by distinct macrophages population that exerts unique functional activities throughout the initiation, maintenance, and resolution phases of fibrosis (17). The promotion of further calcification by Hydroxyapatite supports previous observations which referred that the presence of Hydroxyapatite nucleators enhanced further accumulation of calcium, due to low-activation energy pathways provided by the presence of Hydroxyapatite particles (18). In conclusion, the Hydroxyapatite materials promote wound healing and degraded *in vivo* and can be good candidate in area when fast proliferation of connective tissue is desirable.

References

1. Straub, D. A. (2007). Calcium supplementation in clinical practice: A review of forms, doses and indications. *Nutri. Clin. Pract.*, 22(3): 286-296.
2. Rigo, E. C.; Boschi, M. O.; Yoshimoto, S. J.; Konig, M. J. & Carbonari, A. S. (2004). Evaluation *in vitro* and *in vivo* of biomimetic hydroxyapatite coated on titanium dental implants. *Mater. Sci. and Engineering*, 24: 647-651.
3. Kundu, B.; Soundrapandian, C.; Nandi, S. K.; Datta, B. K. & Mandal, T. K. (2010). Development of new localized drug delivery system based on ceftriaxone-sulbactam composite drug impregnated porous hydroxyapatite: A systemic approach for *in vitro* and *in vivo* animal trial. *Pharm. Res.*, 27(8):1659-1576.
4. Rungsiyakull, C. O.; Li, W.; Li, R. & Swian, M. (2008). Effect of fully porous-coated technique on osseointegration of dental implants. *Aust. J. Basic and Appl. Sci.*, 32: 189-193.

5. Woo, A. S.; Jang, J. L.; Liberman, R. F. & Weinzweig, J. (2010). Creation of a vascularized composite graft with cellular dermal matrix and Hydroxyapatite. *Plast. Reconstr. Surg.*, 125(6): 1661-1669.
6. Lobato, J. V.; Hussain, N. A. & Lopes, M. A. (2008). Clinical applications of titanium dental implant coated with Hydroxyapatite composite. *J. of Nanomanufacturing*, 2: 135-144.
7. Fouda, M. F.; Nemat, A.; Gawish, A. & Ayman, R. B. (2009). Does the coated of titanium implants by Hydroxyapatite affect the elaboration of free radicals? An experimental study. *Aust. J. Sci.*, 3(2): 1122-1129.
8. Gary, L. W. & Donald, D. H. (1996). A comparison of ketamine and the combination of ketamine-xylazine for effective surgical anesthesia in the rabbit. *Lab. Anim. Sci.*, 26(5): 804-806.
9. Prophet, E. B.; Mills, B. & Arrington, J. B. (1992). *Laboratory methods in histotechnology*. Washington: Armed Forced Institute of Pathology, P. 275.
10. Schessel, S.; Ralph, G. & Ran, K. (2002). The management of postoperative disrupted abdominal wall. *Am. J. Surg.*, 184(3): 263-268.
11. Okabayashi, R.; Nakamura, M.; Tanaka, Y.; Nagal, A. & Yamashita, K. (2009). Efficacy of polarized Hydroxyapatite and silk fibroin composite dressing gel on epidermal recovery from full-thickness skin wounds. *Biomed. Mater. Res.*, 90(2): 641-646.
12. Tommila, M.; Jokinen, J.; Wilson, T.; Forsback, A.; Saukko, P.; Penttinen, R. & Ekholm, E. (2008). Bioactive glass-derived Hydroxyapatite-coating promotes granulation tissue growth in subcutaneous cellulose implants in rats. *Acta Biomater.*, 4: 354-361.
13. Vlodayski, I.; Fuks, Z. & Ishai, R. (1991). Extracellular matrix resident basic fibroblast growth factor implication for the control of angiogenesis. *J. Cell. Biochem.*, 45: 167-176.
14. Tsopanoglon, N. E. & Maragoudakis, M. E. (1999). On the mechanism of thrombin induced angiogenesis. Proliferation of vascular endothelial growth factor activity on endothelial cells by up regulation of its receptors. *J. Biol. Chem.*, 274: 23969-23976.
15. Nguyed, M.; Arkell, J. & Jackson, C. J. (2001). Human endothelial gelatinases and angiogenesis. *Int. Biochem. Cell. Biol.*, 33: 960-970.
16. Growther, M.; Brown, N. J.; Bishop, E. T. & Lewis, C. F. (2001). Microenvironmental influence on macrophage regulation of angiogenesis in wound. *J. Leukoc. Biol.*, 70: 478-490.
17. Wynn, E.; Thomas, A. & Luke, Barron, F. (2010). Macrophages : Master regulators of inflammation and fibrosis. *Semin. Liver Dis.*, 30(3): 245-257.
18. Blumenthal, N. C. (1989). Mechanisms of inhibition of calcification. *Clin. Orthop. Relat. Res.*, 247: 279-289.