

Collagen Type III in the Bone Marrow of Normal Individuals

Eman Sadiq Jalal, MSc.

Summary:

Background: The reticulin stroma forms an integral component of any given marrow proliferation, and may often be increased in amount, sometimes normal, and occasionally decreased. Silver impregnation technique (Gomori's stain) is used to demonstrate collagen type III (reticulin) fibers. The present study was undertaken, in an attempt to establish specific hematologic criteria for the quantitative measurement of bone marrow reticulin fibers in normal individuals to enable the pathologist and hematologist to early detect myelosclerotic processes.

Method: Twenty two bone marrow biopsy specimens from hematologically normal patients were examined histologically and the reticulin content quantitated utilizing a scoring system.

Result: Reticulin content was evaluated and correlated with patient age, sex, and anatomic site.

Conclusion: The overall normal range is considered to be 0-2+. Scores of 3+ or 4+ are considered sclerotic in any situation.

Keywords: Bone marrow, Collagen type III, Normal content.

J Fac Med Baghdad
2005; Vol. 47, No.4
Received Jun. 2005
Accepted Sep. 2005

Introduction

Evaluation of bone marrow type III collagen (Reticulin) is a useful procedure for determining the degree of bone marrow fibrosis in various diseases, particularly those of the myeloproliferative type. These disorders often terminate as myelofibrosis, and it is the histochemical demonstration of reticulin fiber proliferation that allows early detection of this process. However such a diagnosis must be based on thorough understanding of normal values, and although a lot has been published regarding the histology of the bone marrow reticulin in abnormal state, no adequate discussion of the normal spectrum is available.

Materials and methods

The present study was carried out in the Medical City Teaching Hospital in Baghdad.

Twenty two bone marrow biopsy cores were obtained, thirteen of them from the sternum (open biopsy) from patients undergoing open heart surgery, and nine iliac bone marrow biopsies from patients from patients with normal peripheral blood picture and had no hematological disease. The criteria used to define normal values were:

1. Hemoglobin levels between 12.0 and 16.0 g/ dl.
2. Leukocyte count between $5.0-10.0 \times 10^9/l$.
3. Leukocyte differential counts within the usual range of normal.
4. The absence of abnormal leukocytes or erythrocytes in the circulating blood demonstrated by peripheral smears.
5. Total circulating platelets numbering between 200.000 and 400.000 / mm^3 .

Clinical data from patients included age and sex, as well as the site of the biopsy. Cores less than 0.5x0.5mm were not included, three histological sections, each 5 μ thick were prepared from paraffin blocks of each specimen and were stained with hematoxylin and eosin, and for cytological detail, Gomori's stain for reticulin fibers and VanGiesin's method for collagen fibers were used. All preparations were examined by light microscopy and each section was evaluated purely on a histological basis. Bone marrow reticulin was quantitated using the following scoring system, which is a modification of those described by Kundel et al, Roberts and Bauer: (ref. needed)

- o - No reticulin fibers demonstrable.
- N - Occasional fine individual fibers only.
- 1+ - Occasional fine individual fibers, plus foci of fine fiber network.
- 2+ - Fine fiber network through out most of the section; no coarse fibers demonstrated.
- 3+ - Diffuse, fiber network with scattered thick, coarse fibers but no true collagen {negative VanGiesin's stain}.
- 4+ - Diffuse, often coarse, fiber network with areas of collagenization {positive VanGiesin's stain}.

Reticulin scores were correlated with the clinical information previously outlined

Results

Of the 22 normal bone marrow specimens studied, 13 (59%) demonstrated reticulin scores of N. to 1+, 9 additional cases were classified as 2+; none of the specimens was in the 3+ or 4+ categories.

The reticulin fibers were infrequent and occurred mainly perivascularly, [Fig.1, 2, 3, and 4] the reticulin network rarely appeared to be complete in any section, and there were fairly marked variations between one microscopic field and another in the same section.

* Hematology unit, AlKarama Teaching Hospital
Baghdad, Iraq

Age: The normal control ranged in age from 3.5-51 years, with a mean of 29.9 years, the majority of patients were mature adults more than 20 years old. Table 1 demonstrated the reticulin scores and age distribution in the normal bone marrows.

Table 1: The reticulin scores and age distribution in normal bone marrows. Note: no 3+ or 4+ scores were encountered.

Ages(years)	Total (22patients)	0	N	1+	2+
0-9 years	1	-	1	-	-
10-19 years	2	-	-	-	2
20-29 years	8	-	3	2	3
30-39 years	7	-	2	2	3
40-49 years	2	-	-	1	1
50-59 years	2	-	-	2	-

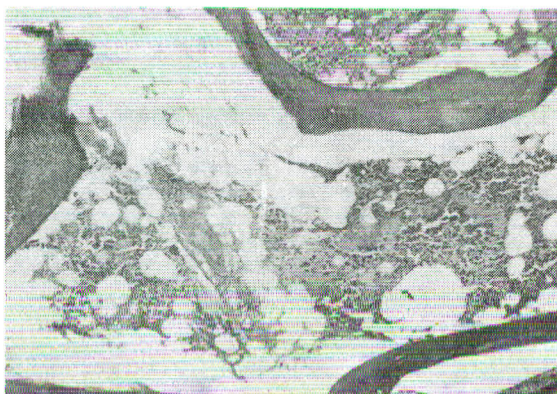


Fig.1 Occasional fine reticular fiber in a normal bone marrow specimen with a reticulin score of N. Gomorireticulin method x 100.

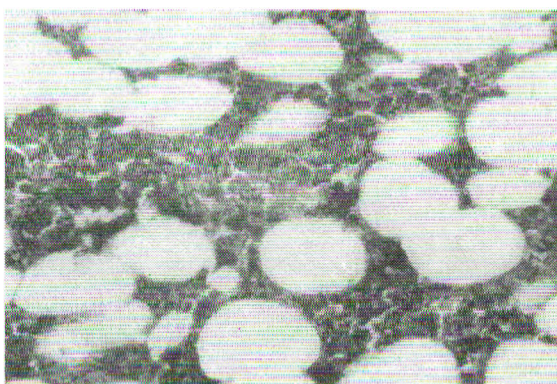


Fig.2 Fine network of reticulin fibers which is scored 1+ when focal & 2+ when diffuse. Gomori reticulin method x 400

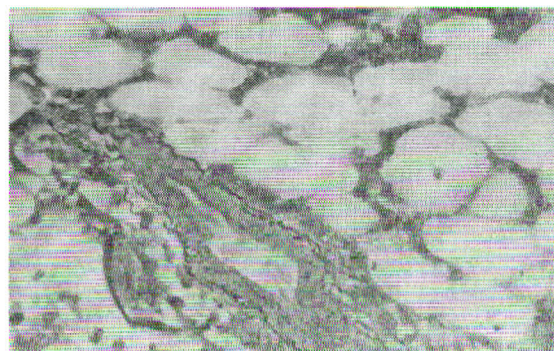


Fig.3 Coarse perivascular reticulin fibers in a normal bone marrow specimen. Similar fibers often surround bone spicules. [Such a pattern should not be confused with focal sclerosis]. Gomori reticulin method x 400.

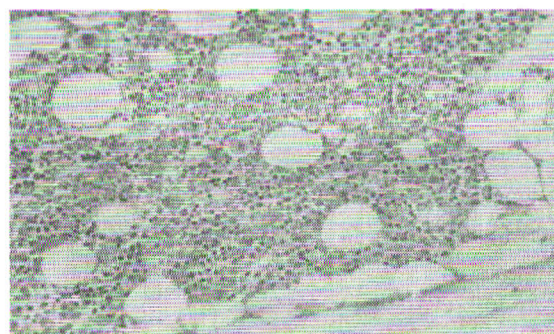


Fig.4 Histotopography of normal haematopoiesis in the bone marrow. Hematoxylin and eosin x 250

Table 2: The reticulin scores and sex distribution in normal bone marrows.

Sex	Total (22patient)	0	N	1+	2+
Males	15		4	6	5
Females	7		2	1	4

Statistically there is no significant difference between age and the content of fibrous tissue in the control group.

Sex: Normal control included 15 males (M) and 7 females (F). Table 2 demonstrated the reticulin scores and sex distribution in normal bone marrows

There was no significant difference between the content of fibrous tissue in the bone marrow biopsy and patient's sex ($X^2=0.98$).

Anatomic site: 13 of the normal marrows were of sternal origin, only nine being from the posterior iliac spine region. Statistically there was no significant difference.

Discussion and conclusions:

The histochemical demonstration of bone marrow reticulin is frequently utilized to evaluate the degree of marrow sclerosis. In the advanced form of this process, the diagnosis usually is obvious, however in the border line situation, a thorough understanding of the normal is essential for proper interpretation.

The basic normal histological structure of bone marrow consists of reticulin fibers arranged in networks mostly concentrated around blood vessels and bone spicules, with fine branching, filaments extending into the adjacent marrow.

Utilizing the histologic criteria previously outlined, the overall normal range for bone marrow reticulin appear to be 0 – 2+. Specimens scored as 3 or 4+ considered definitely sclerotic. One should be aware of reticulin fibers that are normally concentrated around blood vessels and bone spicules. These areas should be disregarded when evaluating the overall reticulin pattern. Needle biopsy may result in crush artifacts and hematoxylin and eosin sections may suggest possible sclerosis; however the reticulin stain will usually demonstrate lack of true sclerosis.

Awareness of these basic principles coupled with the previously described specific quantitative criteria should provide a firm base line for the histological evaluation of bone marrow reticulin.

Acknowledgement

I am so grateful to Prof. Hammed El-Ani, cardiothoracic surgeon in the Medical City Teaching Hospital, for performing the sternal bone marrow biopsies.

References:

1. Weiss L. The hematopoietic stroma *The American Journal of Anatomy* (1984) 170, 447 – 463.
2. Bentley S. Collagen heterogeneity in normal human bone marrow. *Br. J. Haemat.* (1981) 48, 287 – 291.
3. Bentley S. Bone marrow connective tissue and the haemopoietic microenvironment. *Br. J. Haemat.* (1982) 50, 1-6.
4. Puchtler H. Silver impregnation methods for reticulum fibers and reticulin. *Histochemistry*. (1978) 57, 177-187.
5. Kundel DW, Brecker G. Reticulin fibrosis. *Blood* (1984) 23,526-544.
6. Donald m. Fibrosis of bone marrow: content and cause. *Br. J. Haemat.* (1985) 58, 1-7.
7. Lennert K, Schwarze B.W. Pathoanatomical features of the bone marrow. *Clinic in Haematology* (1975) 4, 331-351
8. Bentley S. Collagen Synthesis by bone marrow stromal cells. *British j. Haemat.* (1982) 50, 491-497.
9. Gomori F. Silver impregnation of reticulum in paraffin sections. *Am. J. Pathhol.* (1937) 13,993-1001.