

Investigate the potential lung-protective effects of Hidrosmin and/or Vitamin C in rats with Bleomycin-induced lung fibrosis.

Mohammad Jabbar Makki, Waleed Khalid Ghanim, Muhsin S. G. Al Mozie'l

Department of Pharmacology and Toxicology, College of Pharmacy, University of Basrah, Basrah, Iraq.

Corresponding Author Email Address: pgs.mohamad.jabbar@uobasrah.edu.iq

ORCID ID: <https://orcid.org/0009-0009-6113-8162>

DOI: <https://doi.org/10.23975/bjvr.2024.149340.1082>

Received: 5 May 2024 Accepted: 13 June 2024.

Abstract

As a chemotherapeutic agent, bleomycin is a glycopeptide antibiotic that is used to treat cancer. However, it is linked lung toxicity. Hidrosmin is a man-made flavonoid that reduces inflammation and protects cells from damage. Vitamin C is a water-soluble vitamin with the potential to reduce lung fibrosis. The experiment randomly assigned forty mature male rats into five groups. Group 1: control group with DMSO (5 ml/kg) for 20 days; Group 2: bleomycin intratracheally (5 mg /kg) on day seven of the experiment, Group 3; hidrosmin orally (300 mg/kg/day) for 20 days + BLE intratracheally (5 mg/kg) on day seven; Group 4: vitamin C orally (100 mg/kg/day) for 20 days + BLE intratracheally (5 mg/kg) on day seven; Group 5: hidrosmin orally (300 mg/kg/day) + vitamin C orally (100 mg/kg/day) daily for 20 days; and BLE (5 mg/kg) on day seven. The experiment randomly assigned forty mature male rats into five groups. The first group got DMSO (5 ml/kg) every day as a control. The second group got bleomycin intratracheally (5 mg/kg) on the seventh day of the experiment. The third group got hidrosmin orally (300 mg/kg/day) for 20 days and BLE intratracheally (5 mg/kg) on the seventh day. The fourth group got vitamin C orally (100 mg/kg/day) for 20 days and BLE intratracheally (5 mg/kg) on day seven. The fifth group got hidrosmin orally (300 mg/kg/day) plus vitamin C orally (100 mg/kg/day) every day for 20 days and BLE intratracheally (5 mg/kg) on the seventh day.

Keywords: hidrosmin, vitamin C, bleomycin, lung toxicity, rats.

Introduction

Inflammation (pneumonitis) or scarring (fibrosis) can cause lung damage, a pathological condition known as lung toxicity. Inflammation diminishes the lungs' capacity to absorb oxygen, scarring diminishes lung function, and pulmonary toxicity can arise from several factors, such as chemotherapy, radiation therapy impacting the lungs, exposure to pollutants, specific drugs, or hereditary susceptibility (1).

Bleomycins are a class of glycopeptide antibiotics first identified by Umezawa and his coworkers in 1966 (2). Bleomycin (BLE) is an antitumor antibiotic derived from *Streptomyces verticillus* (3). Bleomycin is an effective medication for treating various types of cancer, such as Hodgkin's lymphoma, non-Hodgkin's lymphoma, testicular cancer, ovarian cancer, and cervical cancer (4). The primary adverse effect of bleomycin is pulmonary fibrosis, which has not been resolved yet. These medications can cause substantial damage to the lungs as a notable side effect, although it is believed to be triggered by the production of reactive oxygen species (ROS) that generate free radical oxidants (5). The intra-tracheal administration of bleomycin in rats is well-established since it closely resembles the fibrotic lung illness that affects humans. The model of lung fibrosis is well-accepted and frequently used. (6). Type I pneumocytes in the lungs go through apoptosis when they are exposed to bleomycin-induced free radicals. This lets the contents of the cells escape, which can activate neutrophils and pulmonary

macrophages. Afterward, these cells release cytokines and chemokines, which help to attract more inflammatory cells and strengthen the immune response (7). The symptoms and signs of bleomycin encompass coughing, difficulty breathing, rapid breathing, bluish discoloration of the skin, crackling sounds in the lower parts of the lungs, rubbing sounds in the chest cavity, inward movement of the muscles between the ribs, decreased ability to engage in physical activity, and episodes of elevated body temperature (8).

Hidrosmin is a synthetic flavonoid developed for the treatment of venous Insufficiency, Hidrosmin is derived from diosmin, a hesperidin- derivative bioflavonoid whose antioxidant, anti-inflammatory, antihypertensive, and anti-ischemic properties have been studied in several experimental models (9). Hidrosmin is a phenolic compound that possesses anti-inflammatory and antioxidant properties and has lower toxicity by being effective in chelating metals and scavenging free radicals (10). Administration of Hidrosmin also inhibited the activation of NF- κ B and JAK/STAT through mechanisms that reduced the expression of inflammatory chemokines and cytokines (11).

Vitamin C is a water-soluble vitamin (12). It is required for the functioning of several enzymes and is important for immune system function (13). It is a crucial nutrient that possesses redox characteristics under normal physiological conditions (14). Ascorbic acid acts as a potent antioxidant, effectively eliminating oxygen free radicals and replenishing other cellular antioxidants (15). Researchers found that the combined

effect of flavonoids and ascorbate on bleomycin-induced DNA degradation was more significant than the effect of flavonoids (16). These findings are consistent with previous studies on rats (17). The present investigation is to evaluate the protective effects of hidrosmin and/or vitamin C against bleomycin-induced lung damage.

Materials and Methods

A total of forty adult male rats were selected to eliminate any potential impact of gender variations on the inflammatory and oxidative biomarkers (18). The rats weighing 250-280 grams were obtained from the animal house of the College of Pharmacy at Dhi Qar University. They were then placed in carefully regulated environments ($22 \pm 2^\circ\text{C}$ and 12–12 h/light-dark cycle) in the animal house of the College of Pharmacy at Basra University. The rats were given regular pellets and had unrestricted access to the water source throughout the whole study. Animals are kept for at least two weeks to ensure that they do not have any abnormal health conditions.

Drugs

Bleomycin vials were bought from Al-Hikma Company, Jordan, dissolved in normal saline, calculated according to the weight of the rats, and delivered using the intratracheal route by directly inserting the needle into the trachea. Hidrosmin capsule, FEAS Pharma company, Bulgaria, Hidrosmin was dissolved in dimethyl sulfoxide (DMSO) and administered orally

using a gavage technique. The dosage was determined based on the previous research findings according to the weight of each rat (9). A vitamin C (500 mg tablet) was provided by a healthcare company, Australia. Vitamin C was dissolved in distal water to create a stock solution and then administered orally to the rats according to the weight of each rat by using a gavage technique (19).

Study Design

Rats in this study were split into 5 groups, each one containing eight rats as follows:

Group 1: Represent the control group received DMSO orally (5 ml/kg) for 20 days.

Group 2: Rats were administered BLE 5 mg/kg via intratracheal injection (by directly inserting the needle into the trachea) on the seventh day of the experiment.

Group 3: Rats were administered hidrosmin orally 300 mg/kg daily (9) for 20 days and BLE intratracheally 5 mg/kg on day seven.

Group 4: Rats were administered vitamin C orally 100 mg/kg daily (20) for 20 days and BLE intratracheally 5 mg/kg on day seven.

Group 5: Rats were administered orally a combination of hidrosmin 300 mg/kg and vitamin C 100 mg/kg daily for twenty days and BLE intratracheally 5 mg/kg on day seven of the experiment.

At the end of the experiment, (on day twenty), rats were anesthetized and sacrificed, and the lungs of the rats were excised and stored in phosphate buffer saline (21) for the measurement of inflammatory

parameters by using a rat ELISA kit purchased from Bioassay Technology Laboratory company, USA, inducible Tumor Necrosis Factor-alpha (TNF- α) and Total Antioxidant Status (TAS), also by using a rat ELISA kit purchased from SunLong Biotech Co., Ltd, inducible glutathione (GSH) and Transforming Growth Factor- β (TGF- β).

Statistical Analysis

The statistical analysis was conducted using SPSS version 26, a software package specifically designed for social sciences data analysis. The data were reported as the mean \pm standard error of the mean (SEM). An analysis of variance (ANOVA) using the Tukey test was conducted to assess the statistical significance of the variations among the experimental groups. Statistically significant differences were identified when P-values were ≤ 0.05 .

Results

Measuring the biomarkers (GSH, TNF- α , TGF- β , and TAS) by using the tissue homogenization process, after excising the lungs of the rats, stored in phosphate-buffered saline, then taking a small piece of lung and homogenizing it with dry ice using a variable-speed laboratory blender, and then by using the Elisa kit that is specific for each biomarker, the result was as follows:

Table 1 and Figure 1 demonstrate that rats injected with BLE intratracheally at a dose

of 5 mg/kg (Group 2), produced a highly significant reduction ($P < 0.001$) in GSH levels in lung tissue homogenate compared to the levels that match in control (Group 1) rats. Mean \pm SEM of GSH levels in lung tissue homogenate were, respectively, 181.625 ± 0.263 and 430.875 ± 0.295 .

Moreover, there was a highly significant elevation ($P < 0.001$) in GSH level in lung tissue homogenate in groups treated with Hidrosmin (300mg/kg/day) for 20 days to BLE (IT 5 mg/kg) (Groups 3) , Vitamin C (100 mg/kg/day) for 20 days to BLE (IT 5 mg/kg) (Group 4), and a combination of Hidrosmin (300 mg/kg/day) with vitamin C (100 mg/kg/day) prior to BLE (IT 5 mg/kg) (Group 5) compared to the GSH levels that match in (Group 2) rats IT injected with BLE (5 mg/kg). The mean \pm SEM of GSH levels in lung tissue homogenate were, respectively, 251.25 ± 0.25 , 291.375 ± 0.263052 , 341.25 ± 0.25 , 181.625 ± 0.263052 .

Furthermore, a combination of hidrosmin and vitamin C (Group 5) produced a highly significant elevation ($P < 0.001$) in GSH level in lung tissue homogenate when compared with either the use of Hidrosmin or vitamin C alone (Group 3 and Group 4) respectively. The mean \pm SEM of GSH levels in lung tissue homogenate were, respectively, 341.25 ± 0.25^c , 251.25 ± 0.25^c , 291.375 ± 0.263^d .

Table 1: Protective effects of Hidrosmin and Vitamin C on GSH level in lung tissue homogenate.

Group/Treatment	GSH- tissue ng/ml \pm SEM
Group 1	430.875 \pm 0.295 ^a
Group 2	181.625 \pm 0.263 ^b
Group 3	251.25 \pm 0.25 ^c
Group 4	291.375 \pm 0.263 ^d
Group 5	341.25 \pm 0.25 ^e

Each data is expressed as mean \pm standard error of the mean (SEM). Values with small letters (a, b, c, d, and e) are highly significantly different between each group (P<0.001). Number of rats in each group 8: Group 1: a, Group 2: b, Group 3 :c, Group 4 :d, Group 5:e.

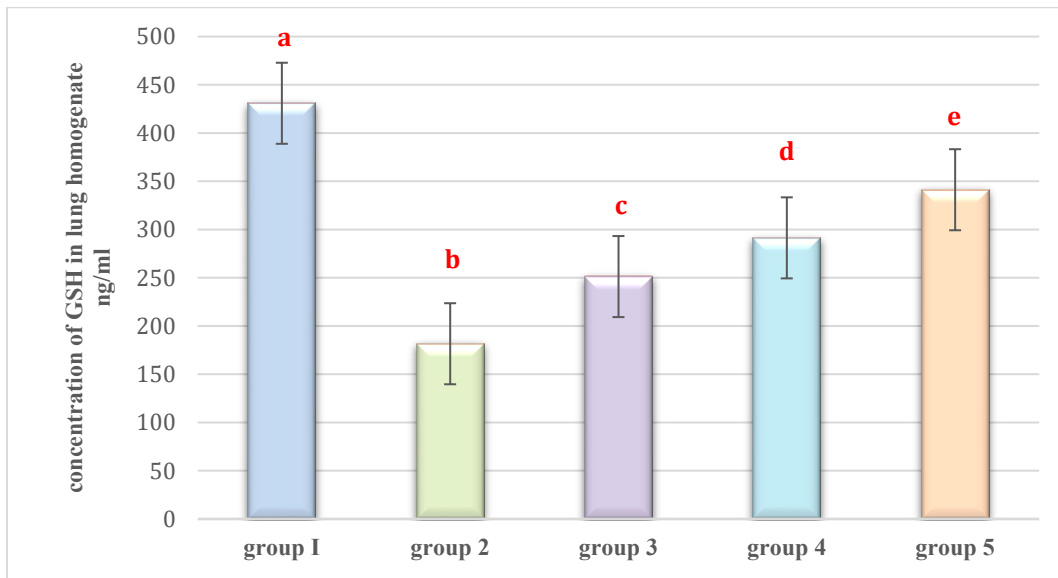


Figure 1: Effects of Hidrosmin and Vitamin C on GSH Level in lung tissue homogenate - Values demonstrated mean \pm standard error of the mean (SEM). Values represented in different small letters (a, b, c, d, and e) are a highly significantly different between each group (P<0.001). Number of animals in each group=8

Table 2 and Figure 2 demonstrate that rats injected with BLE intratracheally at a dose of 5 mg/kg (Group 2), produced a highly significant elevation ($P<0.001$) in TNF- α level in lung tissue homogenate compared to the TNF- α levels that match in control (Group 1) rats. The mean \pm SEM of TNF- α levels in lung tissue homogenate were, respectively, 471.1250 ± 0.29 and 81.3750 ± 0.46 .

Moreover, there was a highly significant reduction ($P<0.001$) in TNF- α level in lung tissue homogenate in groups treated with Hidrosmin (300 mg/kg/day) for 20 days to BLE (IT 5 mg/kg) (groups 3) , Vitamin C (100 mg/kg/day) for 20 days to BLE (IT 5 mg/kg) (Group 4), and a combination of Hidrosmin (300 mg/kg/day) with vitamin C

(100 mg/kg/day) prior to BLE (IT 5 mg/kg) (Group 5) compared to the TNF- α levels that match in (Group 2) rats IT injected with BLE (5mg/kg). The m Mean \pm SEM of TNF- α levels in lung tissue homogenate were, respectively, 271.5000 ± 0.26726 , 262.5000 ± 0.18898 , 196.2500 ± 1.23563 , 471.1250 ± 0.29505 .

Furthermore, the combination of hidrosmin and vitamin C (Group 5) produced a highly significant reduction ($P<0.001$) in TNF- α level in lung tissue homogenate when compared with either the use of Hidrosmin or vitamin C alone (Group 3 and Group 4) respectively. Mean \pm SEM of TNF- α level in lung tissue homogenate were, respectively, 196.2500 ± 1.23563^e , 271.5000 ± 0.26726^c , 262.5000 ± 0.18898^d .

Table 2: Protective effects of Hidrosmin and Vitamin C on TNF- α level lung tissue homogenate.

Group/Treatment	TNF- α tissue ng/ml \pm SEM
Group 1	81.3750 ± 0.46049^a
Group 2	471.1250 ± 0.29505^b
Group 3	271.5000 ± 0.26726^c
Group 4	262.5000 ± 0.18898^d
Group 5	196.2500 ± 1.23563^e

Each data is expressed as mean \pm standard error of the mean (SEM). Values with small letters (a, b, c, d, and e) are a highly significantly different ($P<0.001$). Number of rats in each group= 8

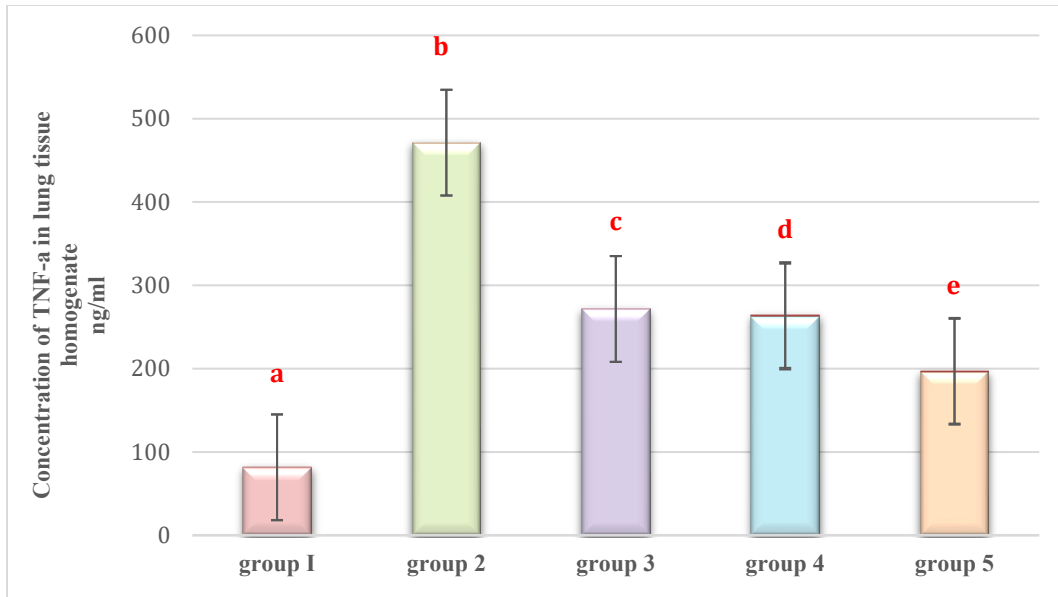


Figure 2: Effects of Hidrosmin and Vitamin C on TNF- α Level in lung tissue homogenate. Values demonstrated mean \pm standard error of the mean (SEM). Values expressed in different small letters (a, b, c, d, and e) are a highly significantly different ($P < 0.001$). Number of animals in each group=8.

Table 3 and Figure 3 demonstrate that rats injected with BLE intratracheally at a dose of 5 mg/kg (Group 2), produced a highly significant elevation ($P < 0.001$) in TGF- β level in lung tissue homogenate compared to the TGF- β levels that match in control (Group 1) rats. The mean \pm SEM of TGF- β levels in lung tissue homogenate were respectively, 285.6250 ± 0.18298 and 70.6250 ± 0.18298 .

Moreover, there was a highly significant reduction ($P < 0.001$) in TGF- β level in lung tissue homogenate in groups treated with Hidrosmin (300 mg/kg/day) for 20 days to BLE (IT 5mg/kg) (Groups 3), Vitamin C (100 mg/kg/day) for 20 days to BLE (IT 5 mg/kg) (Group 4), and a combination of Hidrosmin (300 mg/kg/day) with vitamin C

(100 mg/kg/day) prior to BLE (IT 5 mg/kg) (Group 5) compared to the TGF- β levels that match in (Group 2) rats IT injected with BLE (5 mg/kg). The mean \pm SEM of TGF- β levels in lung tissue homogenate were, respectively, 231.1250 ± 0.29505 , 212.2500 ± 0.31339 , 191.2500 ± 0.31339 , 285.6250 ± 0.18298 .

Furthermore, the combination of hidrosmin and vitamin C (Group 5) produces a highly significant reduction ($P < 0.001$) in TGF- β level in lung tissue homogenate when compared with either the use of Hidrosmin or vitamin C alone (Group 3 and Group 4) respectively. The mean \pm SEM of TGF- β level in lung tissue homogenate were, respectively, 191.2500 ± 0.31339^c , 231.1250 ± 0.29505^e , 212.2500 ± 0.31339^d .

Table 3: Protective effects of Hidrosmin and Vitamin C on TGF-β level lung tissue homogenate

Group/Treatment	TGF-β - tissue ng/ml ±SEM
Group 1	70.6250 ± 0.18298 ^a
Group 2	285.6250± 0.18298 ^b
Group 3	231.1250± 0.29505 ^c
Group 4	212.2500 ± 0.31339 ^d
Group 5	191.2500 ± 0.31339 ^e

Each data is expressed as mean ± standard error of the mean (SEM). Values with small letters (a, b, c, d, and e) are a highly significantly different (P<0.001). Number of rats in each group= 8.

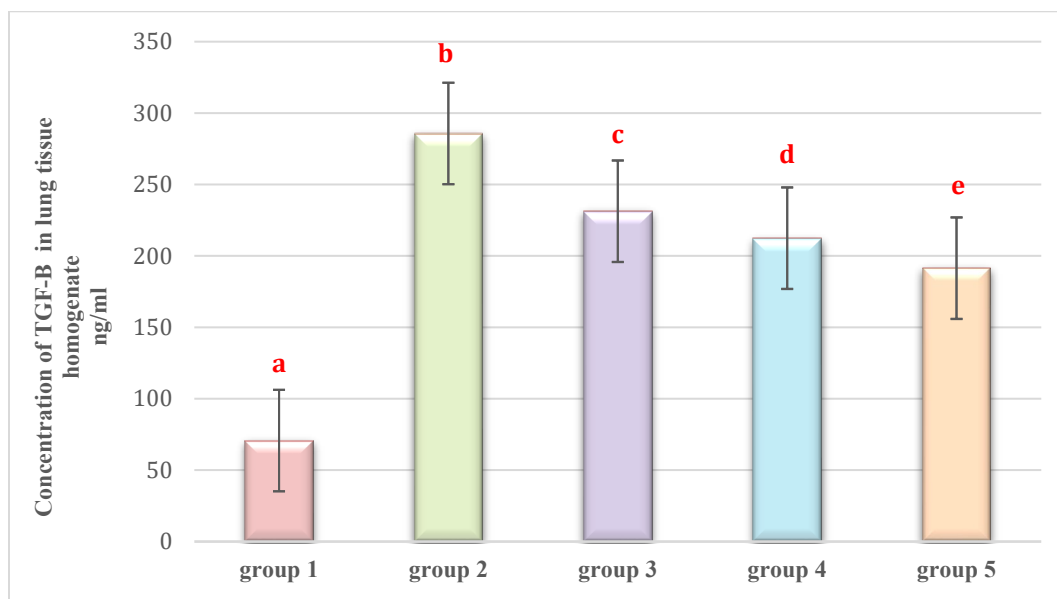


Figure 3: Effects of Hidrosmin and Vitamin C on TGF-β Level in lung tissue homogenate. Values demonstrated mean ± standard error of the mean (SEM). Values expressed in different small letters (a, b, c, d, and e) are a highly significantly different (P<0.001). Number of animals in each group=8 .

Table 4 and Figure 4 demonstrate that rats injected with BLE intratracheally at a dose of 5 mg/kg (Group 2), produced a highly significant reduction ($P<0.001$) in TAS level in lung tissue homogenate compared to the TAS levels that match in control (Group 1) rats. The mean \pm SEM of TAS levels in lung tissue homogenate were, respectively, 20.8750 ± 0.29505 and 58.6250 ± 0.18298 .

Moreover, there was a highly significant elevation ($P<0.001$) in TAS level in lung tissue homogenate in groups treated with Hidrosmin (300 mg/kg/day) for 20 days to BLE (IT 5mg/kg) (Groups 3) , vitamin C (100 mg/kg/day) for 20 days to BLE (IT 5 mg/kg) (Group 4), and a combination of Hidrosmin (300 mg/kg/day) with vitamin C (100 mg/kg/day) prior to BLE (IT 5 mg/kg)

(Group 5) compared to the TAS levels that match in (Group 2) rats IT injected with BLE (5 mg/kg). The mean \pm SEM of TAS levels in lung tissue homogenate were, respectively, 44.3750 ± 0.26305 , 49.0000 ± 0.32733 , 54.5000 ± 0.18898 , 20.8750 ± 0.29505 .

Furthermore, a combination of hidrosmin and vitamin C (Group 5) produced a highly significant elevation ($P<0.001$) in TAS level in lung tissue homogenate when compared with either use of Hidrosmin or vitamin C alone (Group 3 and Group 4) respectively. The mean \pm SEM of TAS level in lung tissue homogenate were, respectively, 54.5000 ± 0.18898^e , 44.3750 ± 0.26305^c , 49.0000 ± 0.32733^d .

Table 4: Protective effects of Hidrosmin and Vitamin C on TAS level lung tissue homogenate.

Group/Treatment	TAS- tissue ng/ml \pm SEM
Group 1	58.6250 ± 0.18298^a
Group 2	20.8750 ± 0.29505^b
Group 3	44.3750 ± 0.26305^c
Group 4	49.0000 ± 0.32733^d
Group 5	54.5000 ± 0.18898^e

Each data is expressed as mean \pm standard error of the mean (SEM). Values with small letters (a, b, c, d, and e) are a highly significantly different ($P<0.001$). Number of rats in each group= 8

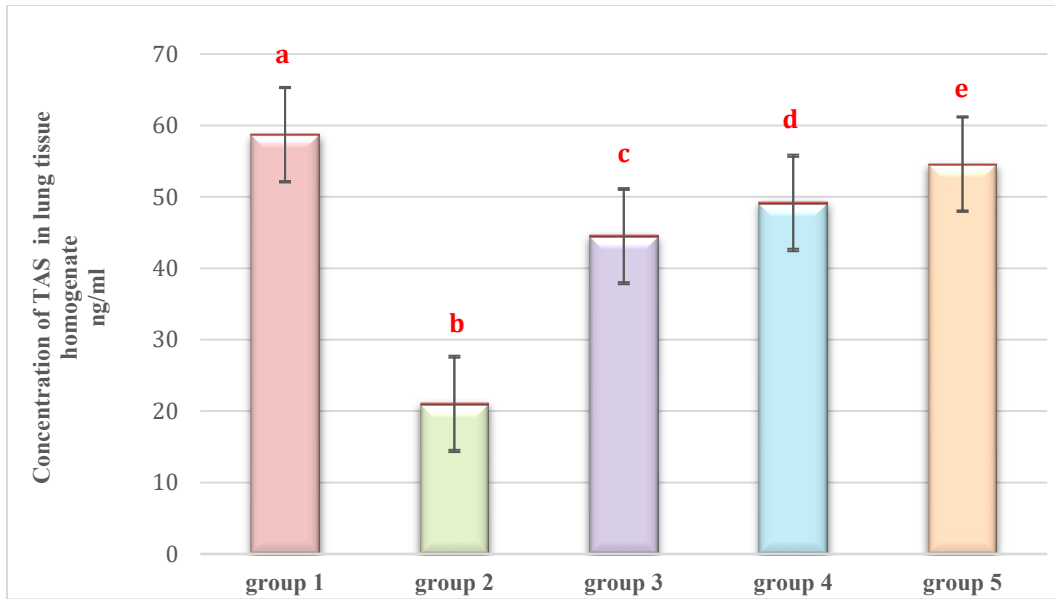


Figure 4: Effects of Hidrosmin and Vitamin C on TAS Level in lung tissue homogenate. Values demonstrated mean \pm standard error of the mean (SEM). Values expressed in different small letters (a, b, c, d, and e) are a highly significantly different ($P < 0.001$). Number of animals in each group=8

Discussion

The current study found that Bleomycin led to a notable increase in $TNF-\alpha$ and $TGF-\beta$ levels in lung tissue homogenate and a decrease in GSH and TAS levels in lung tissue homogenate as shown in (Group 2). The observed effects can be related to the progression of pulmonary fibrosis, a condition defined by an increased synthesis and accumulation of collagen and other matrix constituents (22). Exposure to Bleomycin causes the creation of excessive free radicals, leading to an inflammatory reaction. In this response, pro-inflammatory cytokines are released and immune cells are stimulated. This mimics acute lung injury caused by pro-inflammatory cytokines, specifically $TNF-\alpha$ and $TGF-\beta$, which have been linked to the development of fibrosis in animal models treated with bleomycin. (23).

In addition, it causes harm to the thin layer of cells that line small blood vessels and capillaries, resulting in the blockage of blood flow and increased leakage of fluids, which triggers an inflammatory reaction (24). The immune cells release inflammatory mediators and pro-fibrogenic cytokines, which stimulate the growth of myofibroblasts, the deposition of collagen, and ultimately lead to organ failure. This might potentially result in the death of the organism (25).

While rats treated with hidrosmin plus bleomycin (Group 3) exhibited a significant reduction in $TNF-\alpha$ and $TGF-\beta$ levels in lung tissue homogenate and a significant elevation in GSH and TAS levels in lung tissue homogenate, this can be attributed to the lung-protective and antioxidant properties of hidrosmin. These findings are

consistent with previous studies that have shown a reduction in TGF- β , and TAS levels in lung tissue homogenate (9). Additionally, according to the use of hidrosmin, subsequent research revealed that the administration of hidrosmin leads to an increase in the transcription of the NRF2 activation pathway, while also inhibiting NF- κ B, which governs and controls the generation of reactive oxygen species (ROS) (26). Another study showed that prior treatment with hidrosmin reversed the redox balance genes are regulated by blocking the prooxidant enzyme NADPH oxidase (specifically the NOX1 and NOX4 isoforms) and increasing the production of antioxidant enzymes Superoxide dismutase-1 (SOD1) and Catalase (CAT) (9).

In addition, rats that received vitamin C treatment (Group 4) exhibited a substantial decrease in TNF- α and TGF- β levels in lung tissue homogenate, and a significant elevation in GSH and TAS levels in lung tissue homogenate compared to Group 2. This could be referred to as vitamin C reducing unstable species of oxygen, nitrogen, and sulfur radicals in addition to regenerating other antioxidants in the body (27).

Furthermore, rats that were treated with a combination of hidrosmin and vitamin C (Group 5) showed a significant decrease in TNF- α and TGF- β levels in lung tissue homogenate and a significant elevation in GSH and TAS levels in lung tissue homogenate compared to Group 2. This combination treatment had better effects than using hidrosmin or vitamin C alone (group 3 and group 4, respectively).

These effects are caused by the antioxidant activity of both hidrosmin and vitamin C which can decrease the effects of reactive oxygen species on the lungs. Additionally, a combination of hidrosmin and vitamin C provides a synergistic effect that is more pronounced than using each substance alone (28).

Conclusion

Bleomycin may increase the risk of developing lung injury through the production of reactive oxygen species and oxidative stress, according to the present finding. Hidrosmin's anti-inflammatory and antioxidant activity protects against this effect. Additionally, using both Hidrosmin and Vitamin C has a synergistic benefit against the lung toxicity caused by BLE.

Acknowledgement

The authors express their gratitude to the College of Pharmacy, University of Basrah, for providing support for this study.

Conflicts of interest

The authors declare that there is no .conflict of interest

Funding

No funding had been received by the . authors

Ethical Clearance

The Research Ethical Committee in Iraq regulates scientific research that has received ethical approval from the

References:

1. Baqir, M., Vasirreddy, A., Vu, A. N., Moua, T., Chamberlain, A. M., Frank, R. D., & Ryu, J. H. (2021). Idiopathic pulmonary fibrosis and gastroesophageal reflux disease: A population-based, case-control study. *Respiratory Medicine*, 178. <https://doi.org/10.1016/J.RMED.2021.106309>
2. Bylund, K. C. (2015). Testicular Cancer. *Reference Module in Biomedical Sciences*. <https://doi.org/10.1016/B978-0-12-801238-3.05341-1>
3. Karshieva, S. S., Babayeva, G., Pokrovsky, V. S., Shlyapnikov, Y. M., Shlyapnikova, E. A., Bugrova, A. E., Kononikhin, A. S., Nikolaev, E. N., & Kanev, I. L. (2023). Antitumor Effect of Bleomycin Nanoaerosol in Murine Carcinoma Model. *Molecules*, 28(10). <https://doi.org/10.3390/molecules28104157>
4. Brandt, J. P., & Gerriets, V. (2023). Bleomycin. *XPharm: The Comprehensive Pharmacology Reference*, 1–6. <https://doi.org/10.1016/B978-008055232-3.61328-5>
5. Hay, J., Shahzeidi, S., & Laurent, G. (1991a). Mechanisms of bleomycin-induced lung damage. In *Arch Toxicol* 65).
6. Williamson, J. D., Sadofsky, L. R., & Hart, S. P. (2015). The pathogenesis of bleomycin-induced lung injury in animals and its applicability to human idiopathic pulmonary fibrosis. *Experimental Lung Research*, 41(2), 57–73. <https://doi.org/10.3109/01902148.2014.979516>
7. Seo, S. U., Jeong, J. H., Baek, B. S., Choi, J. M., Choi, Y. S., Ko, H. J., & Kweon, M. N. (2021). Bleomycin-Induced Lung Injury Increases Resistance to Influenza Virus Infection in a Type I Interferon-Dependent Manner. *Frontiers in Immunology*, 12. <https://doi.org/10.3389/FIMMU.2021.697162/FULL>
8. Travis, W. D., Costabel, U., Hansell, D. M., King, T. E., Lynch, D. A., Nicholson, A. G., Ryerson, C. J., Ryu, J. H., Selman, M., Wells, A. U., Behr, J., Bouros, D., Brown, K. K., Colby, T. V., Collard, H. R., Cordeiro, C. R., Cottin, V., Crestani, B., Drent, M., ... Valeyre, D. (2013). An official American Thoracic Society/European Respiratory Society statement: Update of the international multidisciplinary classification of the idiopathic interstitial pneumonias. *American Journal of Respiratory and Critical Care Medicine*, 188(6), 733–748. <https://doi.org/10.1164/RCCM.201308-1483ST>
9. Jiménez-castilla, L., Marín-royo, G., Orejudo, M., Opazo-ríos, L., Caro-ordieres, T., Artaiz, I., Suárez-cortés, T., Zazpe, A., Hernández, G., Gómez-guerrero, C., & Egido, J. (2021). Nephroprotective effects of synthetic flavonoid hidrosmin in experimental diabetic nephropathy. *Antioxidants*, 10(12). <https://doi.org/10.3390/antiox10121920>

10. Srinivasan, S., & Pari, L. (2012). Ameliorative effect of diosmin, a citrus flavonoid against streptozotocin-nicotinamide generated oxidative stress induced diabetic rats. *Chemico-Biological Interactions*, 195(1), 43–51.
<https://doi.org/10.1016/J.CBI.2011.10.003>
11. Mingchuan, Y., Xiang, C., Yuhong, X., Jing, Y., Yu, L., Di, W., Haili, X., & Jun, L. (2023). WITHDRAWN: Hidrosmin Attenuates Inflammatory Response Induced by IL1 β by Suppressing the Activation of NF- κ B Involving Nrf2/HO1 Pathway in Human Osteoarthritis Chondrocytes. *Current Cancer Drug Targets*, 23.
<https://doi.org/10.2174/1568009623666230209120520>
12. Castro, S. M., Guerrero-Plata, A., Suarez-Real, G., Adegboyega, P. A., Colasurdo, G. N., Khan, A. M., Garofalo, R. P., & Casola, A. (2006). Antioxidant Treatment Ameliorates Respiratory Syncytial Virus-induced Disease and Lung Inflammation. *American Journal of Respiratory and Critical Care Medicine*, 174(12), 1361.
<https://doi.org/10.1164/RCCM.200603-319OC>
13. Hemilä, H., & Chalker, E. (2013). Vitamin C for preventing and treating the common cold. *The Cochrane Database of Systematic Reviews*, 2013(1).
<https://doi.org/10.1002/14651858.CD000980.PUB4>
14. Figueroa-Méndez, R., & Rivas-Arancibia, S. (2015). Vitamin C in Health and Disease: Its Role in the Metabolism of Cells and Redox State in the Brain. *Frontiers in Physiology*, 6(DEC), 397.
<https://doi.org/10.3389/FPHYS.2015.00397>
15. May, J. M., & Harrison, F. E. (2013). Role of Vitamin C in the Function of the Vascular Endothelium. *Antioxidants & Redox Signaling*, 19(17), 2068.
<https://doi.org/10.1089/ARS.2013.5205>
16. Sugihara, N., Kaneko, A., & Furuno, K. (2005). Synergistic effects of flavonoids and ascorbate on enhancement in DNA degradation induced by a bleomycin-Fe complex. *Free Radical Research*, 39(3), 237–244.
<https://doi.org/10.1080/10715760500043058>
17. Corcostegui, R., Labeaga, L., Arteché, J. K., & Orjales, A. (1998). Protective Effect of Hidrosmin Against Cisplatin-induced Acute Nephrotoxicity in Rats. In *Pharm. Pharmacol. Commun* (Vol. 4).
<https://doi.org/10.1111/j.2042-7158.1998.tb00732.x>
18. Martínez de Toda, I., González-Sánchez, M., Díaz-Del Cerro, E., Valera, G., Carracedo, J., & Guerra-Pérez, N. (2023). Sex differences in markers of oxidation and inflammation. Implications for ageing. *Mechanisms of Ageing and Development*, 211.
<https://doi.org/10.1016/J.MAD.2023.111797>

19. pathy, K. (2018). Process for Preparation of Vitamin C and Method for Determination of Vitamin C in Tablets. *Surgery & Case Studies: Open Access Journal*, 1(3). <https://doi.org/10.32474/scsoaj.2018.01.000114>
20. Boretti, A., & Banik, B. K. (2020). Intravenous vitamin C for reduction of cytokines storm in acute respiratory distress syndrome. In *PharmaNutrition* (Vol. 12). Elsevier B.V. <https://doi.org/10.1016/j.phanu.2020.100190>
21. Wu, G. R., Dai, X. P., Li, X. R., & Jiang, H. P. (2017). Antioxidant And Anti-Inflammatory Effects of Rhamnazin on Lipopolysaccharide-Induced Acute Lung Injury and Inflammation In Rats. *African Journal of Traditional, Complementary, And Alternative Medicines*, 14(4), 201. <https://doi.org/10.21010/Ajtcam.V14i4.23>
22. Reinert, T., Baldotto, C. S. da R., Nunes, F. A. P., & Scheliga, A. A. de S. (2013). Bleomycin-Induced Lung Injury. *Journal of Cancer Research*, 2013, 1–9. <https://doi.org/10.1155/2013/480608>
23. Ishida, Y., Kuninaka, Y., Mukaida, N., & Kondo, T. (2023). Immune Mechanisms of Pulmonary Fibrosis with Bleomycin. *International Journal of Molecular Sciences*, 24(4). <https://doi.org/10.3390/IJMS24043149>
24. Hay, J., Shahzeidi, S., & Laurent, G. (1991b). Mechanisms of bleomycin-induced lung damage. *Archives of Toxicology*, 65(2), 81–94. <https://doi.org/10.1007/BF02034932>
25. Vats, A., & Chaturvedi, P. (2023). The Regenerative Power of Stem Cells: Treating Bleomycin-Induced Lung Fibrosis. In *Stem Cells and Cloning: Advances and Applications* (Vol. 16, pp. 43–59). Dove Medical Press Ltd. <https://doi.org/10.2147/SCCAA.S419474>
26. Ahmed, S., Mundhe, N., Borgohain, M., Chowdhury, L., Kwatra, M., Bolshette, N., Ahmed, A., & Lahkar, M. (2016). Diosmin Modulates the NF-kB Signal Transduction Pathways and Downregulation of Various Oxidative Stress Markers in Alloxan-Induced Diabetic Nephropathy. *Inflammation*, 39(5), 1783–1797. <https://doi.org/10.1007/s10753-016-0413-4>
27. Gao, L. P., Li, Z., Guo, Z. Y., & Zhao, Y. M. (2013). The effects of vitamin C on DDP-induced anemia in rats. *Toxicology Mechanisms and Methods*, 23(6), 383–388. <https://doi.org/10.3109/15376516.2013.769656>
28. Noroozi, M., Angerson, W. J., & Lean, M. E. J. (1998). Effects of flavonoids and vitamin C on oxidative DNA damage to human lymphocytes. *The American Journal of Clinical Nutrition*, 67(6), 1210–1218. <https://doi.org/10.1093/AJCN/67.6.1210>

التحقق من التأثيرات الوقائية المحتملة للرئة، للهيدروسمين و/أو فيتامين ج في الجرذان المصابة بتليف الرئة الناجم عن البليوميسين

محمد جبار مكي، وليد خالد غانم، محسن صغير المزيعل

فرع علم الأدوية والسموم، كلية الصيدلة، جامعة البصرة، البصرة، العراق.

الخلاصة

البليومايسين هو علاج كيميائي ينتمي الى المضادات الحيوية الجليكوبيبتيدية تستخدم لعلاج الاورام الخبيثة، ولكن استخدامه مرتبط بتليف الرئة، الهيدروزمين هو فلافونويد مصنع يعتبر مضاد للالتهابات ومضاد للأكسدة، فيتامين ج هو فيتامين قابل للذوبان بالماء له القدرة على تقليل امراض الرئة. اربعون ذكر من الجرذان الناضجة مقسمة الى خمسة مجموعات، المجموعة 1: مجموعة التحكم تلقت (DMSO) عن طريق الفم (5 مل/كغم) لمدة 20 يوماً. المجموعة 2: تلقت الجرذان البليومايسين الحقن داخل الرغامي (5 ملغم/كغم) في اليوم السابع من التجربة. المجموعة 3: تلقت الجرذان الهيدروزمين عن طريق الفم (300 ملغم /كغم/يوم) لمدة 20 يوم وايضاً تلقت البليومايسين داخل الرغامي (5 ملغم /كغم) في اليوم السابع من التجربة. المجموعة 4: تلقت الجرذان فيتامين ج عن طريق الفم (100 ملغم /كغم/يوم) لمدة 20 يوم وايضاً تلقت البليومايسين داخل الرغامي (5 ملغم /كغم) في اليوم السابع من التجربة. المجموعة 5: تلقت الجرذان كل من الهيدروزمين عن طريق الفم (300 ملغم/كغم/يوم)، فيتامين ج عن طريق الفم (100 ملغم /كغم/يوم) لمدة 20 يوم لكل منهما، وايضاً تلقت البليومايسين بالحقن داخل الرغامي (5 ملغم /كغم) في اليوم السابع من التجربة. في اليوم 20 تم قتل الحيوانات لغرض قياس TNF- α and, GSH, TNF- α , TGF- β , and TAS ، اظهرت النتائج في المجموعة 3 انخفاضاً معنوياً ($P < 0.001$) في TGF- β وارتفاعاً معنوياً في مستوى GSH and TAS مقارنة في المجموعة 2، بالإضافة الى ان المجموعة 5 اظهرت انخفاضاً معنوياً ($P < 0.001$) في مستوى TNF- α and, TGF- β وارتفاعاً معنوياً في مستوى GSH and TAS عند المقارنة في المجموعة 2 والمجموعة 3 ، ذلك لان الهيدروزمين اظهر تأثيراً علاجياً للرئة المتعرضة للجرع الحادة من البليومايسين ، علاوة على ذلك فعند مزج الهيدروزمين مع فيتامين ج اظهر تأثيراً تآزرياً مقارنة من استخدامهم كل منهم على حده.

الكلمات المفتاحية: هيدروزمين، فيتامين ج، بليوميسين، سمية الرئة، الجرذان.