

## **HISTOLOGICAL AND PHYSIOLOGICAL STUDY OF DIANABOL ON THE THYROID GLAND OF FEMALE ALBINO RATS (*Rattus rattus*)**

Ekhlās Abid Hamza, Salim Salih Ali, Lubab Aqeel Jafer  
Isam Mohamed Jaber

College of Veterinary Medicine, Al-Qasim Green University, Babylon, Iraq

Corresponding author: [ekhlasalwany@yahoo.com](mailto:ekhlasalwany@yahoo.com)

**Key word:** dianabol, thyroid gland, TSH.

### **ABSTRACT**

The random uses of androgenic anabolic steroids such as dianabol (Alpha pharma) especially among young people and adolescent could have harmful effects on health. The aim of this study is to investigate the possible harmful effects of oral administration of dianabol on the histology and hormones levels of the thyroid gland in female rats. The study was carried out in the animal house ( College of veterinary Medicine / University of Al-Qasim Green ). Twenty four female rats (*Rattus rattus*) were divided into 4 groups, three groups were given dianabol orally at the concentrations of (0.05, 0.1, 0.2) mg/kg respectively on daily basis for six weeks, and the fourth group, served as a control group, was injected by (0.9%NaCl). Thyroxine (T4), triiodothyronine (T3) and thyroid stimulating hormone (TSH) were estimate, Histological study included the histopathological changes in thyroid gland tissue. The results showed a significant increase ( $p < 0.05$ ) in the levels of TSH, T4, and T3 compared with the control group. This study also showed changes in the thyroid tissue that included hyperplasia of thyroid follicles, colloid material in most follicles, little or no increase in the size of follicles which suggest that increased dose of dianabol leads to pathological (Physiological and histological) changes noticeable in most of the studied criteria.

## **INTRODUCTION**

In females, the testosterone circulating levels are about 10% of those observed in males. This hormone is known to have an effect on the muscle growth and build up properties. The development of the male phenotype, observed in men, is under the influence of this hormone. Other functions such as blood production, plasma lipids, protein and bone metabolism are also documented (1). Due to the anabolic effects of testosterone, it has the efficacy in the treatment of many disorders such as renal and hepatic failure, anaemia associated with hepatic failure and hypogonadism (2), whereas the effects caused by anabolic androgenic drugs such as dianabol include cardiovascular disorders, liver and kidney diseases as well as other problems on human body (3). A reduction in HDL (High Density Lipoprotein) cholesterol, increased inflammatory markers and oxidative stress in AAS users (4).

### **Relationship between using Dianabol and hormones**

The elevated concentrations of Testosterone, DHT or Estrogens leads to the suppression of gonadotropic hormones (5). (6) investigated the suppressing influence of steroids on male sexual behavior after high-dose administration of (17 $\alpha$ -alkylated) steroids (stanozolol, oxymetholone or methyltestosterone), whereas the application of metandienone, nandrolonedecanoate or testosterone, cypionate had little influence on the amounts, intromissions or ejaculations of male rats. According to self-reports of bodybuilders, boldenone, trenbolone and nanrolone were considered as the most unpleasant steroids due to their suppression of libido (7).

### **Doping in Sport**

Testosterone hormone most important steroids used in sports which affects the body in two directions is building body tissue and muscle and strength building from intramuscularly as soon as, and this hormone gives the male characteristics to the athlete, and adrenal hormones such as cortisol, which used to increase metabolism, leading to a temporary increase in efficiency, but this hormone works on hair to appear in unexpected places and the collapse of the adrenal gland, and the hormone adrenaline and its derivative works to increase the number of heartbeat, high blood pressure and increases the vulnerability of the body's metabolism of carbohydrates

which leads to degradation of glycogen in the body to modulate the simple sugar used for energy production, but the hormone has a direct effect on the heart and use it in larger amounts than usual may lead to stop working (8).

## MATERIALS AND METHODS

**Animals:** Twenty four female albino Rats (*Rattus rattus*) were used in this study, their weight ranged between 200-250 gm. aged 2 months. The rats were given food and water *ad libitum*. In sprig section, then rats were housed in controlled conditions of temperature ( $25 \pm 3$  C°) and 12 hours light – dark cycles.

**Experimental animals:** The female rats were randomly divided into four groups, each group consisted of 5 rats, one group served as control group and the other three served as the experimental groups. The control group was (NaCl 0.09%) orally once a week for six weeks. The experimental groups were given (0.05, 0.1) and 0.2mg/kg of dianabol for a period of six weeks.

**Blood and tissues sampling:** Chloroform was used as anesthetic and female rats were sacrificed. 5 ml of blood were obtained directly from the heart using sterile syringe. Left to clot in plastic tubes at room temperature for 30 minutes, centrifuged at 3000 rpm for 10 minutes, and serum was taken for thyroid hormones (TSH, T3, T4) estimation. Thyroid gland was removed, fixed in Bouin solution, stained with Harris hematoxylin & eosin (9, 10) for histological study.

**Hormonal estimation:** Enzyme Linked Immune Sorbent Assay (ELISA), which was used to estimate the levels of hormones in serum at absorbance of 450 nm wavelength. According to the procedure provided by Metra company (Italy) several steps were followed to determine the levels of T3 and T4 and TSH. ELISA Reader device, consisting of three pieces, a Washer - USA, Bio - ELISA Reader - Aspani, Epson – LQ.

**Histological Processing and Staining:** Thyroid gland fixed in Bouin solution was dehydrated with ascending concentrations of ethanol, embedded in paraffin, sectioned by using rotary microtome, stained with Haematoxylin & Eosin, mounted on slides using Canada balsam (11).

**Microscopic examination and photomicrography:** The slides were examined by using light microscope (Olympus) to detect the histopathology changes, and photographed by using the camera of phase contrast light microscope.

**Statistical analysis:** SPSS software (Genstat) version (1995) was used to compare the differences between experimental groups and control group. L.S.D, (Least Significant Differences) was calculated for this purpose.

## RESULTS

### Estimation the levels of thyroid hormones

The results in figures (1,2,3) respectively, revealed that there was an increase ( $P < 0.05$ ) in TSH, T3, T4 of female rats given dianabol in comparison with control group.

### Histological study of thyroid gland

The main histopathological changes of thyroid gland sections stained with hematoxylin-eosin in female rats treated by different concentrations of dianabol showed that there was a range of changes from moderate to severe, at the concentration 0.05 mg / kg body weight. Hyperplasia of follicle cells and a few empty of colloid follicles (figure 5) were observed. While at the concentration of 0.1 mg / kg body weight of dianabol columnar lining epithelial, faint colloid material, variable in size of follicles and hyperplasia of follicle cells were noticed (figure 6). Furthermore, severe changes at 0.2 mg / kg body weight of dianabol, such as columnar hyperplasia of thyroid follicles, empty colloid material in most of follicles and increase in size of follicles were observed (figure 7) in comparison with control group (figure 4).

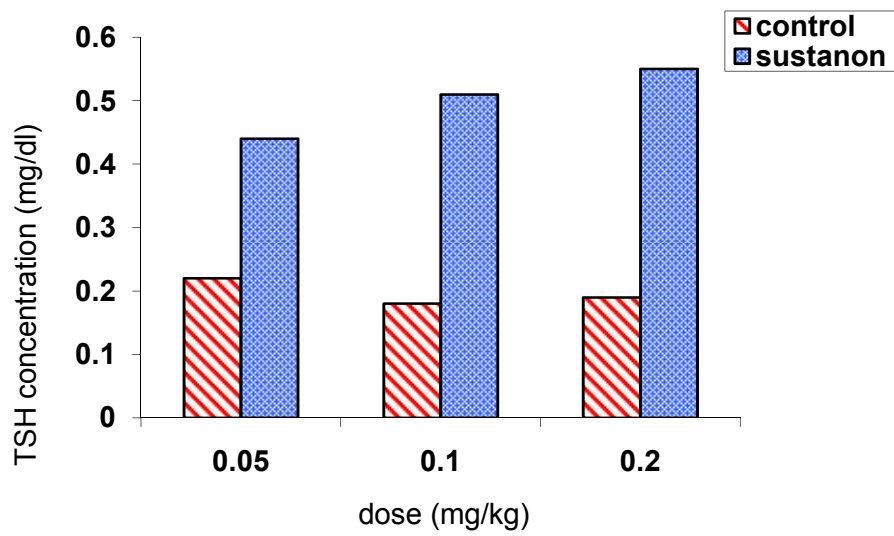


Figure (1) : TSH levels of serum rats treated with different doses of dianabol

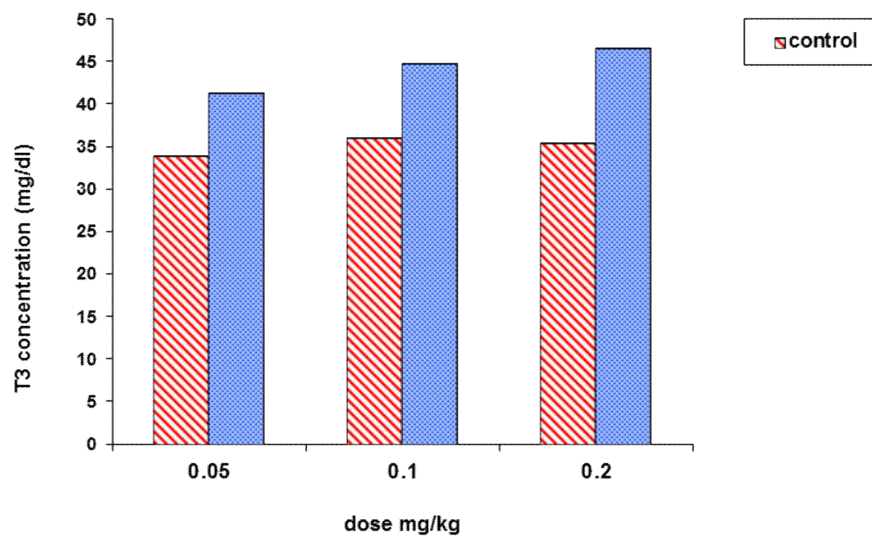


Figure (2) : T3 levels in serum rats treated with different doses of dianabol

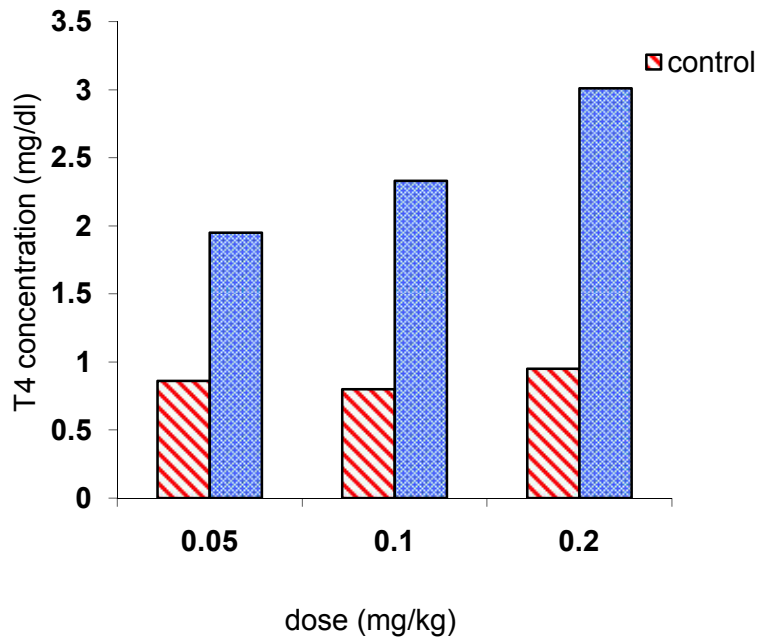


Figure (3): T4 levels of serum female rats treated with different doses of dianabol

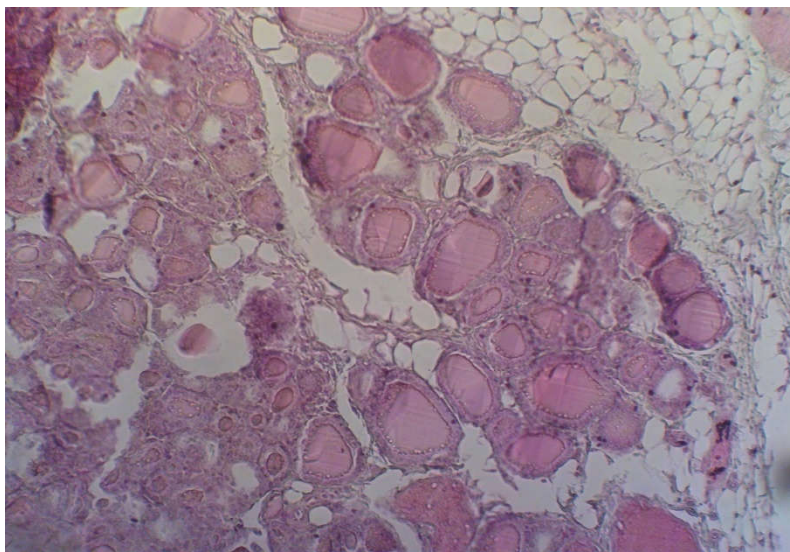


Figure (4): cross section of control thyroid gland in female rats treated by different doses of dianabol (H& E 100X )

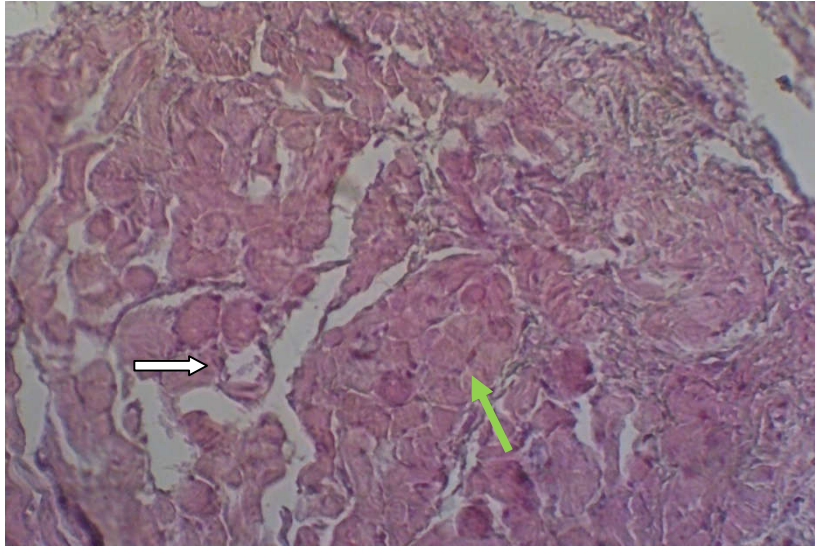


Figure (5): cross section of thyroid gland in female rats treated by 0.05 mg/kg of dianabol observed hyperplasia of follicle cells (green arrow) and a few follicles showed empty (white arrow) (H& E 100X)

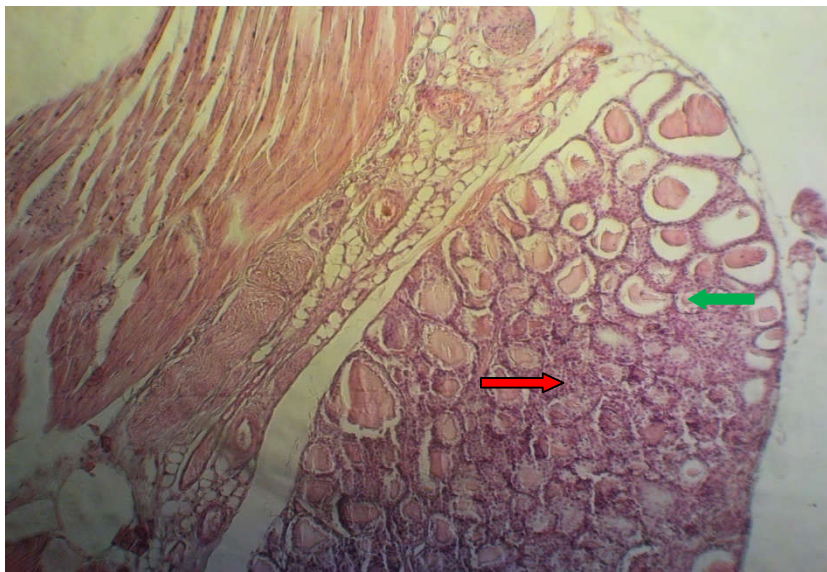

Figure (6): cross section of thyroid gland in female rats treated by 0.1 mg/kg of dianabol showed faint colloid material (green arrow), variable in size of follicles and hyperplasia of follicle cells (red arrow) (H& E 100X)

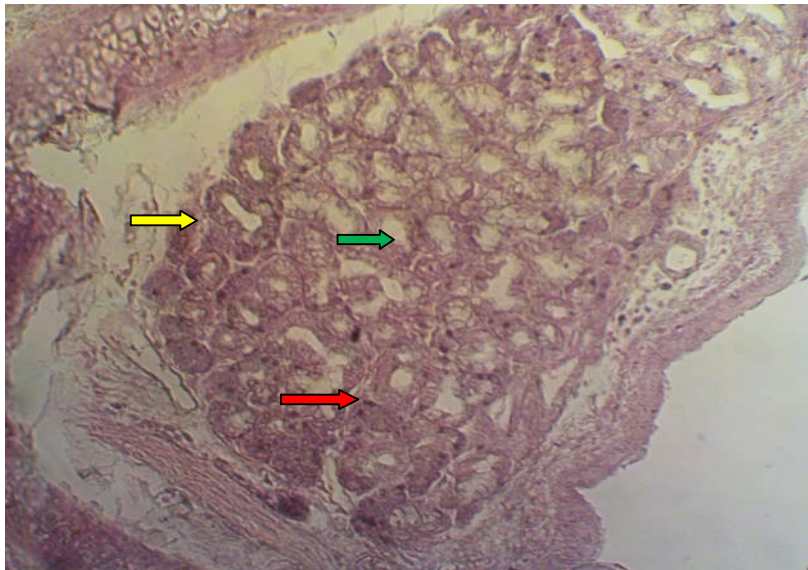


Figure (7): cross section of thyroid gland in female rats treated by 0. 2 mg/kg of dianabol showed hyperplasia of thyroid follicles (red arrow) , empty colloid material in most of follicles (green arrow) and increase in size of follicles (yellow arrow) (H& E 100X )

## DISCUSSION

The significant increase in TSH, T3, T4 (Figures 1,2,3) could be due to the hyperandrogenism which is associated with varying type of steroid used. The misuse of steroid may result in partial pituitary atrophy thyroid hormones changes (12). Thyroid gland is another target of testosterone when this hormone stimulates thyrotropin secretion and increase the growth of the thyroid gland (13). In contrast, the administration of steroids to patients with thyroid diseases causes changes in regard to thyroid medications (14). Meanwhile, there may be indirect effect dianabol on the pituitary-thyroid axis as a consequence of increased serum levels of thyroxin binding globulin, and the associated changes in thyroid function as a result of increased of metabolic rate, through uptake of anabolic steroids by athletes (15).

The histological changes of thyroid gland in female rats suggest that anabolic androgenic steroid (dianabol) may have caused hormonal effects which led to proliferative tissue responses, including hyperplasia and neoplasia as well as a decrease of colloid by hyper active thyroid gland (16).



## REFERENCES

- 1-**Evans, N. A. (2004)** Current concepts in anabolic-androgenic steroids. *American Journal of Sports Medicine*, 32, 534–542
- 2-**Basaria, S., Wahlstrom, J. T. & Dobs, A. S. (2001)** Anabolic androgenic steroid therapy in the treatment of chronic diseases. *Journal of Clinical Endocrinology and Metabolism*, 86, 5108–5117
- 3-**Mader, S.S. (2010)**. *Biology*. 10th ed., McGraw-Hill companies. New York.
- 4-**Santos, R.L.; Silva, F.B.; Ribeiro, R.F.; and Stefanon, I. (2014)**. Sex hormones in the cardiovascular system. *Horm Mol Biol Clin Investig* 18: 89–103.
- 5- **Gårevik, N.; Strahm, E.; Garlw, M.; Lundmark, J.; Ståhle, L.; Ekström, L., and Rane, A. (2011)**. Long term perturbation of endocrine parameters and cholesterol metabolism after discontinued abuse of anabolic androgenic steroids. *J. Steroid Biochem., 669 and Molec. Biol.*, 127 : 295-300.
- 6- **Clark, A.S., and Harrold, E.V. (1997)**. Comparison of the effects of stanozolol, oxymetholone, and testosterone cypionate on the sexual behavior of castrated male rats. *Behav. Neurosci.* 111:1368–1374.
- 7- **Bachmann, M. and Sinner, D. (2007)**. Anabolic steroid. *J. BMS –Verlag*, 86 :816.
- 8- **Johnson, J. M., Nachtigall, L. B., and Stern, T. A. (2013)**. The effect of testosterone levels on mood in men: A review. *Psychosomatics*, 54(6): 509-514.
- 9- **Humason, G.L. (1997)**. *Animal tissue techniques*, 5th ed. Baltimore, J.A., University Press.
- 10- **Bancroft, J.D. and Stevens, A. (1982)**. *Theory and practice of histological techniques* 2nd ed. Churchill Livingstone, Edinburgh, London, 622.
- 11- **Bancroft, J. D.; Layton, C. and Suvarna, S.K. (2013)**. *Bancroft's theory and practice of histological techniques*. 7th ed. Churchill Livingstone Elsevier. Elsevier Limited.
- 12- **Abech DD, Moratelli HB, Leite SC, Oliveira MC(2005)**: Effects of testosterone replacement therapy on pituitary size, prolactin and thyroid-stimulating hormone concentrations in menopausal women. *Gynecol Endocrinol*, 21(4):223-6.
- 13- **Tahboub R, Arafah BM.(2009)** Sex steroids and the thyroid. *Best Pract Res Clin Endocrinol Metab.* Dec 23(6):769-780.

- 14- Jansen HT, Kirby JD, Cooke PS, Arambepola N & Iwamoto GA.(2007)** Impact of neonatal hypothyroidism on reproduction in the male hamster. *Mesocricetus auratus*. *Physiol Behav* ; 90(5):771-81
- 15- Dickerman, R. D. & Jaikumar, S. (2001)** Secondary partial empty sella syndrome in an elite body builder. *Neurological Research*, 23, 336–338.
- 16- Harleman J. H.; Hargreaves A.; Andersson H.; and Kirk, S. (2012).** Incidence and co-incidence of uterine tumours in Wistar and Sprague Dawley rats based on the RITA database—Evaluation of carcinogenicity results needs awareness of interdependency of tumour in pathogenesis. *Toxicol. Pathol.*, 40: 926–930.