



Experimental study on the effect of bft toxin isolated and purified from clinical isolates of Enterotoxigenic *Bacteroides fragilis* on the liver, spleen and intestine of mice

Hussein Ali Khaleefah, Ashwak Basim Jasim

Institute of Genetic Engineering & Biotechnology for Postgraduate Studies, University of Baghdad, Baghdad, Iraq.

Corresponding Author Email Address: Ashwakbio2006@yahoo.com

ORCID ID: 0000-0001-9256-234X

Accepted: Nov. 2022

Abstract

This study includes three parts: isolation of Enterotoxigenic *Bacteroides fragilis* from 94 stool samples collected from different hospitals in Baghdad city from the beginning of March/2020 to the end of April/2021. Stool samples were streaked on BBE media in an anaerobic condition for 24-48h. Identification of *Fragilis* was done based on morphological characteristics on BBE media: gray convex small rounded colonies surround black zone colonies and molecular method using specific genes 16S rRNA and bft gene. Results showed 34 *Fragilis* isolates were positive for the 16S rRNA gene and 5 *Fragilis* positive for the bft gene were classified as Enterotoxigenic *Fragilis* (ETBF). ETBF isolate which was positive for the bft gene and 16S rRNA was purified by using the Van Tassel method. 30 male mice were divided into three groups with 10 mice for each group the first group as control, the second group is positive control mice administered daily 2% dextran sulfate sodium for 30 days, the third group mice administered by stomach tube 2%DSS for 10 days after 10 days mice administered with 20 µg of bft toxin by stomach tube for 30 days. At the end of the experiment, all groups of mice were killed by euthanized ethics. Tissue samples (liver, intestine, and spleen) from mice were removed. The organs were fixed in 10% neutral buffered formalin for histological techniques. Histopathological changes in the third group, in the liver section of a mouse inoculated with DSS+bft toxin, showed: necrotic hepatocytes and dilated sinusoids with hemorrhage. Histopathological changes in the intestine section of a mouse inoculated with DSS+bft toxin showed: sloughing and degenerated villi and shorten villi. Histopathological changes in the spleen section of a mouse inoculated with DSS+bft toxin showed: amyloid infiltration and all lymphoid follicles depleted with necrotic lymphocytes.

Key words: *Bacteroides fragilis*, bft toxin, liver.

Introduction

Enterotoxigenic *Bacteroides fragilis* (ETBF) is a human colonic commensal associated with juvenile diarrhea as well as high-grade colorectal cancer (1, 2)

B. fragilis toxin (BFT) which is referred to as fragilysin is commonly expressed by enterotoxigenic *B. fragilis* (ETBF) (3,4). BFT is a heat-labile zinc-dependent metalloprotease with a molecular mass of 21 kDa. BFT produces proenzymes with a molecular mass of 44.4 kDa that contains an N-terminal pro-domain, a C-terminal catalytic domain, and a flexible linker (5). Three isoforms of BFT have been demonstrated including BFT1, BFT2, and BFT3 of which isoform BFT1 is the most common (6,7). BFT is a biologically active molecule and different activities have been described for it, including morphological effects on intestinal epithelial cells, induction of chloride release, and elevated permeability of human gut mucosa and epithelial cell monolayers (8). Signaling pathways affected by the toxin cause differential gene expression and epigenetic changes in HT29 cells (9). In animal models, BFT is sufficient and necessary to induce colitis in both mice and gerbils (10, 11). BFT also triggers ROS generation, DNA cleavage, and cell proliferation due to the induction of the cellular inhibitor of apoptosis protein-2 (c-IAP2) and spermine oxidase (SMO) (12,13). The induction of pro-carcinogenic signaling by BFT due to NF- κ B activation in the response to Th17 has been reported which induces myeloid-cell-mediated colon carcinogenesis (14).

This study aimed to investigate the effectiveness of bft toxin on the liver, intestine, and spleen of mice.

Materials and Methods

Collection of samples: A total number of 94 stool samples included :(50 for diarrheal and 44 for healthy control) were collected from different hospitals in Baghdad city from the beginning of March/2020 to the end of April/2021.

Isolation and Identification of *B.fragilis* from stool sample A small portion from 94 : stool samples was taken by using a sterile swab suspended in thioglycollate broth (TB) as transport media and were streaked on *Bacteroides* Bile Esculin Agar Base (BBE) and incubated for 24-48 hours at 37 °C under anaerobic conditions. The pure the bacterial culture was further diagnosed based on morphological characteristics, biochemical test, and 16S rRNA gene for conformation of *B.fragilis* isolates and bft gene for identification of Enterotoxigenic *B.fragilis* from Non-ETB using specific primers Table (1). Genomic was isolated from bacterial growth according to the protocol of QIAamp DNA Mini Kit. Qantas fluorometer was used to detect the concentration of extracted DNA. DNA bands were detected by using the Agarose gel electrophoresis technique (1.5% agarose).

Purification of bft toxin from ETBF isolates:

1- All isolates of ETBF which contain the gene of bft depending on PCR technique were used. In the preparation of culture supernatant which was recovered by centrifugation at 2000mg for 40min at 4°C. Determination of protein concentration was done by (17).

2- Purification steps of metalloproteases toxin bft were carried out according to the Van Tassel method (18).

3- Dextran sulfate sodium: 40kDa was purchased from sigma: prepared by dissolving 20 gm in 1liter of D.W.

Experimental study on mice

1-Animal grouping: Thirty (n = 30) juvenile albino male mice, *Mus musculus* BALB /C strain aged (3-5) weeks and weighing (20-25) g. Animals were housed in plastic cages 30 x 10 x 10 c.m³ placed in the room for two weeks for adaptation. Standard rodent diet (Commercial feed pellets) and drinking water were given regularly. Housing conditions were maintained at 22± 4°C, and the air of the room was changed continuously by using ventilating vacuum and light/dark cycle (14/10) h/day. The litter of cages were changed every seven days.

The experiments of this study were conducted in the animal house of the AL-Nahrain research center /AL-Nahrain University. /Baghdad/ Iraq.

Mice were divided randomly and equally into 3 groups each group contains 10 mice:

First group (control group): mice given drinking water for 30 days. Second group (positive control): mice were given daily with drinking water freshly prepared 2% Dextran sulfate sodium by stomach tube for 30 days. Third group: mice administered by stomach tube 2% DSS for 10 days, in the 10 days after that mice were administered by stomach tube with 20µg bft toxin by stomach tube (19) for 30 days.

2-Histopathological study

At the end of the experiment, all groups of mice were killed by euthanized ethics. Tissue samples (liver, intestine, and spleen) from mice were removed. The organs were fixed in 10% neutral buffered formalin and processed for paraffin embedding. The histopathological sections 5 µm were stained with hematoxylin-eosin, with the following procedure as mentioned by (20).

Table (1): sequence of primers used for conventional PCR

Target gene	Primer Sequence	Amplicon size (bp)	References
<i>16S rRNA</i>	F TCRGGAAGAAAGCTTGCT	162	(15)
	R CATCCTTTACCGGAATCCT		
<i>bft</i>	F GACGGTATGTGATTTGTCTGAGAGA	294	(16)
	R ATCCCTAAGATTTTATCCCAAGTA		

Table (2): PCR cycling program for amplifying *16S r RNA* and *bft* genes

NO	steps	Temperature (°C)	Time	Number of cycles
1	Initial denaturation	95	5 min	1
2	Denaturation	95	30sec	30
3	Annealing	a-56 b-52	30sec 30sec	
4	Extension	72	30sec	
5	Final extension	72	7min	1

a= Annealing temperature for *16S rRNA* gene, b Annealing temperature for *bft* gene.

Result

1-isolation and identification of *B.fragilis* bacteria from stool samples:

From 94 stool samples, A total of 34 suspected *B.fragilis* bacteria were isolated from the BBE agar depending on the morphological characteristics of the colonies, they were gray convex small rounded colonies surrounding black zone colonies due to esculin hydrolysis. *B.fragilis* produced esculin and dextrose by esculin hydrolysis. further diagnosis depending on biochemical tests recorded that all 34 isolates were *B.fragilis*. Conventional PCR techniques were used for further conformational diagnosis of all (34) isolates of *B.fragilis* bacteria depending on specific primers for the 16S rRNA gene, which are specific for diagnosis. All isolates gave positive results and the amplified fragments(162bp) were separated by electrophoresis stained with ethidium bromide and photographed using a gel imaging system Fig(1). Furthermore the investigation showed the presence of *bft* gene 5(14.7%) from 34 *B.fragilis* that indicated by *16S rRNA* gene.

Histopathological Examination:This work focused on the effect of purified bft toxin

from ETBF on some organ sections (liver, intestine, and spleen) of mice stained with HE. The results of the control group showed normal architecture of the liver, intestine, and spleen, Figures (3-5) respectively. While the result of the second group (positive control group) / mice received only 2% dextran sulfate sodium for 30 days revealed histopathological changes in the liver section included: congested central vein, all hepatocytes degenerated, vacuolated hepatocytes, and narrow sinusoids Fig. (6). The histopathological changes in the intestine section: increase mucin of goblet cells in villi, congestion, and hemorrhage in submucosa and oedema in submucosa Fig. (7). Histopathological changes in the spleen section in Fig. (8) appear with extensive red pulp hemorrhage, most lymphocyte pyknotic and depleted lymphoid follicles. Besides the histopathological in the third group demonstrated necrotic hepatocytes and dilated sinusoids with hemorrhage in the liver Fig (9). In addition to sloughing and degeneration of villi, shorten villi in the intestine and amyloid infiltration and all lymphoid follicles depleted with necrotic lymphocytes in the spleen, Figs. (10,11) respectively.

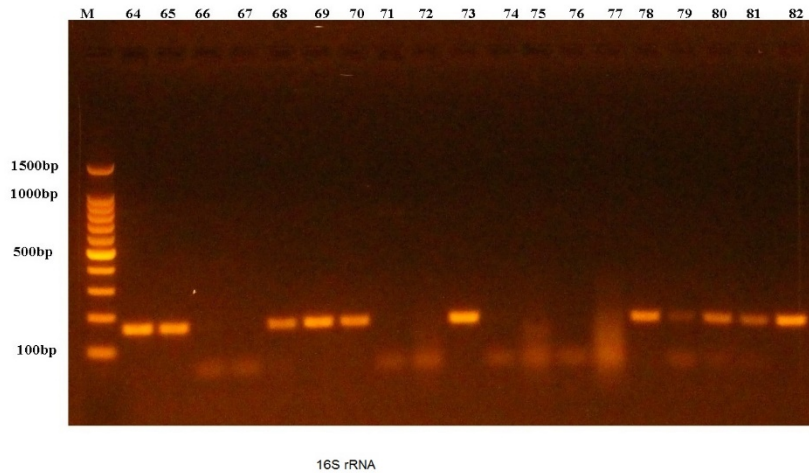


Figure (1): Gel electrophoresis of amplified *16S rRNA* housekeeping gene (162bp) using conventional PCR. Agarose 1.5 %, 100 V for 60 minutes stained with ethidium bromide dye and visualized on a UV transilluminator. Lane M: 100 bp DNA ladder. Lanes: 66,67,71,72,74,75,76,77,79 show negative results and lanes 64,65,68,69,70,,73,78,80,81,82. Show positive results.

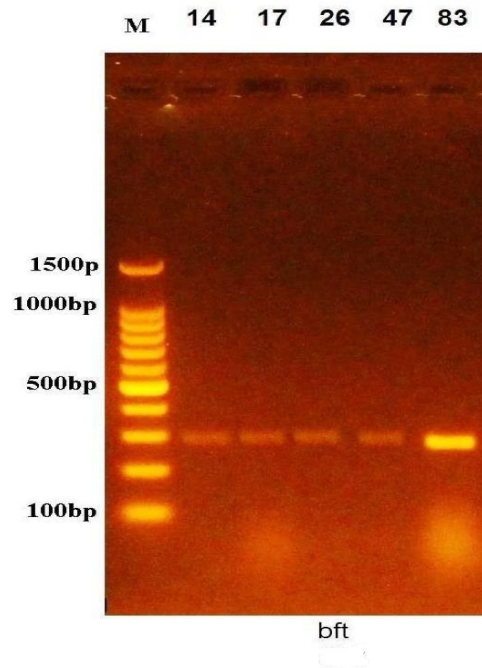


Figure (2) : Gel electrophoresis of amplified *bft* gene (294bp). Agarose 1.5 %, 100 V/cm for 60 minutes, stained with ethidium bromide dye and visualized on a UV transilluminator. Lane M: 100 bp DNA ladder. All Lanes show positive result: Amplicons *bft* gene for ETBF.

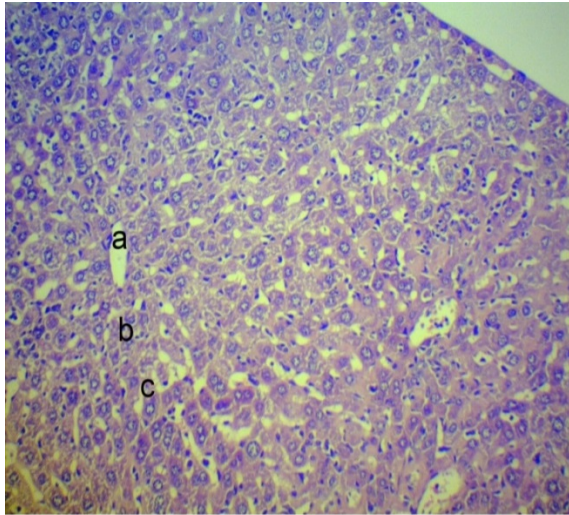


Figure (3): Normal section of liver of control mouse showed: a: Central vein
b: hepatocytes c: sinusoids (H&E stain X20)

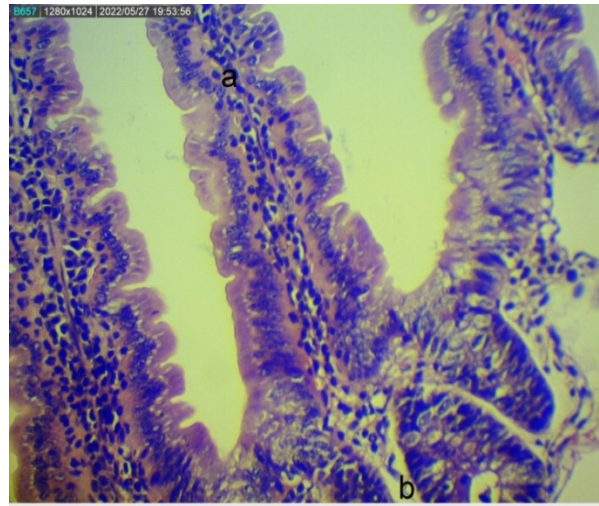


Figure (4): Normal intestine section of control mouse showed: a) Mucosa)
submucosa layer (H&E stain X20)

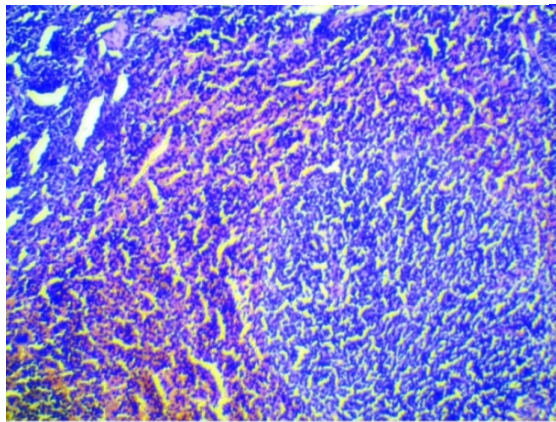


figure (5): Normal spleen section of control mouse showed: a) normal lymphocytic follicle (H&E stain X20)

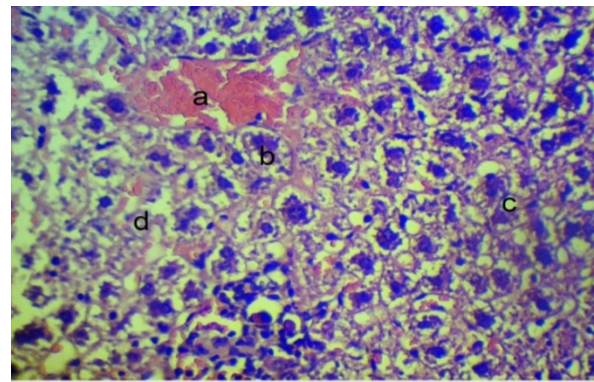
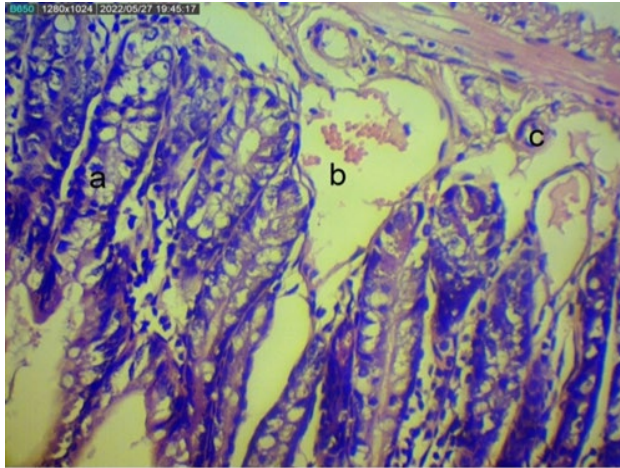
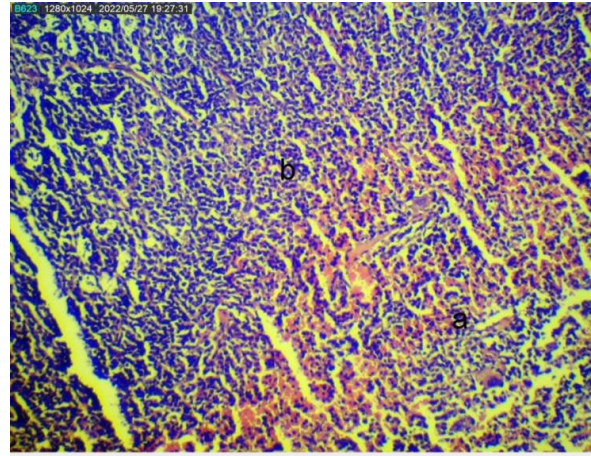


Figure (6) : Histopathological changes in liver section of positive group of mice showed :a)congested central vein b)all hepatocytes degeneratedc) vacuolated hepatocytes d)narrow sinusoids (H&E stain, 40x).



Figure(7):Histopathological changes in intestine section of mouse inoculated with DSS showed :a)increase mucin of goblet cells in villi b)congestion and hemorrhage in submucosa c)oedema in submucosa (H&E stain, 40x).



Figure(8):Histopathological changes in spleen section of mouse inoculated with DSS showed :a)extensive red pulp hemorrhage b)most lymphocyte pyknotic and depleted lymphoid follicles(H&E stain, 20X).

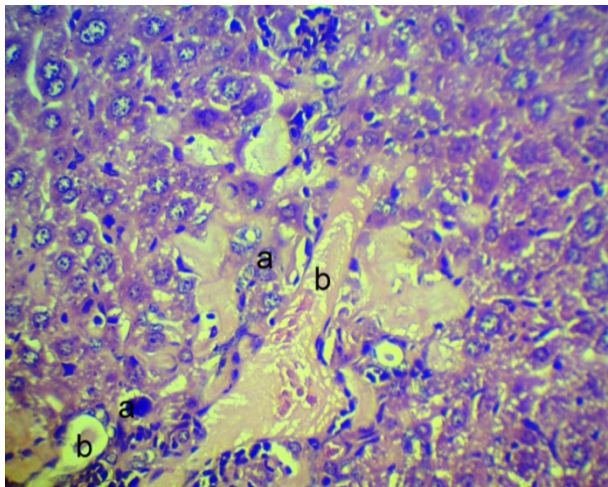


Figure (9) Histopathological changes in liver section of mouse inoculated with DSS+bft toxin showed:a)necrotic hepatocytes ,b)dilated sinusoids with hemorrhage (H&E stain, 40x).

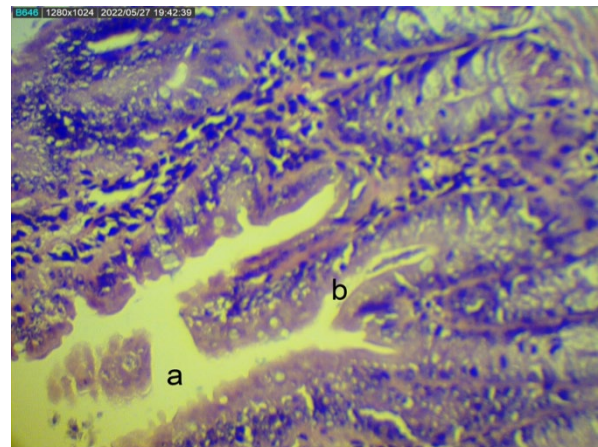


Figure (10) : Histopathological changes in intestine section of mouse inoculated with DSS+bft toxin showed : a)sloughing and degenerated of villi,b)shorten villi (H&E stain, 40x).

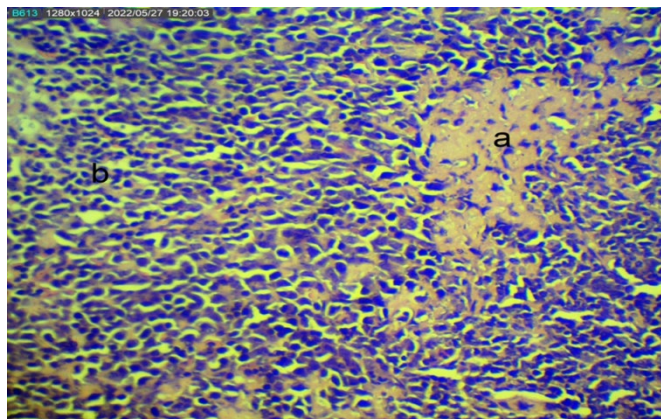


Figure (11): Histopathological changes in spleen section of mouse inoculated with DSS+bft toxin showed:a) amyloid infiltration ,b)all lymphoid follicles depleted with necrotic lymphocytes (H&E stain, 40x)

Discussion

The results of the present study demonstrated that 34 isolated *B.fragilis* depending on the 16S *rRNA* gene, these results matched with a study done by [21] who showed that 19 *B.fragilis* were positive for the 16S *rRNA* gene. The results denounce that 5 isolates of *B.fragilis* contain the *bft* gene (ETBF), and the remaining isolates were NTBF. The results observed here correspond to the results reported in Baghdad (22).

As far as we know, this is the first study in Iraq focused on the purification of bft toxin and its effect on the liver, intestine, and

spleen in mice. The only virulence factor identified as being unique to ETBF strains is BFT. Our study demonstrates that BFT stimulates intestine inflammation and that

biologically active BFT expression is necessary and sufficient to induce murine colitis. Metalloprotease toxins (bft) may act as virulence factors in microorganisms. In some instances, they directly damage the tissue during the infection or inactivate endogenous factors that normally are involved in the host response regulation to infections (23). Current results of the positive control in the liver section of mice disagreed with a study done by (24) who reported that neither morphological differences nor hepatocellular necrosis was observed in the DSS-treated groups of mice. The typical histological changes induced by acute DSS include mucin and goblet cell depletion, epithelial erosion, ulceration, and infiltration of granulocytes into the lamina propria and submucosa resulting in immune responses (25, 26). The successful and reproducible induction of DSS-induced colitis depends on several critical variables, including the DSS source, molecular weight, concentration, duration, mouse strain, source, age, gender, and body weight as well

as ambient factors like the status of the vivarium's hygiene (27). Third group, histopathological changes for the liver section shown in Figure (7): necrotic hepatocytes and dilated sinusoids with hemorrhage, whereas a study by (28) reported that ETBF colonization alone of mice induce splenomegaly in mice. ETBF colonization with gnotobiotic mice, histopathological changes in the liver showed diffuse congestion with few mononuclear inflammatory cells.

Conclusion:

There were significant differences between the three genetic lines on egg external traits and between the collecting age and their infarctions. May its helpful for future studies to establish lines special for egg production, us to make studies on molecular levels.

conflict of Interest

The author(s) declared that there is no conflict of interest.

Reference

1. Boleij, A.; Hechenbleikner, E. M.; Goodwin, A. C.; Badani, R.; Stein, E. M.; Lazarev, M. G.; ... & Sears, C. L. (2015). The *Bacteroides fragilis* toxin gene is prevalent in the colon mucosa of colorectal cancer patients. *Clinical Infectious Diseases*, 60(2): 208-215.
2. Sears, C. L.; Islam, S.; Saha, A.; Arjumand, M.; Alam, N. H.; Faruque, A. S. G.; ... & Qadri, F. (2008). Association of enterotoxigenic *Bacteroides fragilis* infection with inflammatory diarrhea. *Clinical Infectious Diseases*, 47(6): 797-803.
3. Franco, A. A.; Buckwold, S. L.; Shin, J. W.; Ascon, M. & Sears, C. L. (2005). Mutation of the zinc-binding metalloprotease motif affects *Bacteroides fragilis* toxin activity but does not affect propeptide processing. *Infection and immunity*, 73(8): 5273-5277.
4. Chen, L. A.; Van Meerbeke, S.; Albesiano, E.; Goodwin, A.; Wu, S.; Yu, H.; ... & Sears, C. (2015). Fecal detection of enterotoxigenic *Bacteroides fragilis*. *European Journal of Clinical Microbiology & Infectious Diseases*, 34(9): 1871-1877.
5. Goulas, T.; Arolas, J. L. & Gomis-Rüth, F. X. (2011). Structure, function and latency regulation of a bacterial enterotoxin potentially derived from a mammalian adamalysin/ADAMxenolog. *Proceedings of the National Academy of Sciences*, 108(5): 1856-1861.
6. d'Abusco, A. S.; Del Grosso, M.; Censini, S.; Covacci, A. & Pantosti, A. (2000). The alleles of the bft gene are distributed differently among enterotoxigenic *Bacteroides fragilis*

- strains from human sources and can be present in double copies. *Journal of clinical microbiology*, 38(2): 607-612.
7. Ulger, N.; Rajendram, D.; Yagci, A.; Gharbia, S.; Shah, H. N.; Gulluoglu, B. M.; ... & Soyletir, G. (2006). The distribution of the bft alleles among enterotoxigenic *Bacteroides fragilis* strains from stool specimens and extraintestinal sites. *Anaerobe*, 12(2): 71-74.
 8. Wu, S.; Morin, P. J.; Maouyo, D. & Sears, C. L. (2003). *Bacteroides fragilis* enterotoxin induces c-Myc expression and cellular proliferation. *Gastroenterology*, 124(2): 392-400.
 9. Allen, J.; Hao, S.; Sears, C. L. & Timp, W. (2019). Epigenetic changes induced by *Bacteroides fragilis* toxin. *Infection and immunity*, 87(6): e00447-18.
 10. Wu, S.; Rhee, K. J.; Albesiano, E.; Rabizadeh, S.; Wu, X.; Yen, H. R.; ... & Sears, C. L. (2009). A human colonic commensal promotes colon tumorigenesis via activation of T helper type 17 T cell responses. *Nature medicine*, 15(9):1016-1022.
 11. Yim, S., Gwon, S. Y.; Hwang, S.; Kim, N. H.; Jung, B. D. & Rhee, K. J. (2013). Enterotoxigenic *Bacteroides fragilis* causes lethal colitis in Mongolian gerbils. *Anaerobe*, 21: 64-66.
 12. Kim, J. M.; Lee, J. Y. & Kim, Y. J. (2008). Inhibition of apoptosis in *Bacteroides fragilis* enterotoxin-stimulated intestinal epithelial cells through the induction of c-IAP-2. *European journal of immunology*, 38(8): 2190-2199.
 13. Goodwin, A. C.; Shields, C. E. D.; Wu, S.; Huso, D. L.; Wu, X.; Murray-Stewart, T. R.; ... & Casero Jr, R. A. (2011). Polyamine catabolism contributes to enterotoxigenic *Bacteroides fragilis*-induced colon tumorigenesis. *Proceedings of the National Academy of Sciences*, 108(37): 15354-15359.
 14. Chung, L.; Orberg, E. T.; Geis, A. L.; Chan, J. L.; Fu, K.; Shields, C. E. D.; ... & Housseau, F. (2018). *Bacteroides fragilis* toxin coordinates a pro-carcinogenic inflammatory cascade via targeting of colonic epithelial cells. *Cell host & microbe*, 23(2): 203-214.
 15. Tong, J.; Liu, C.; Summanen, P.; Xu, H. & Finegold, S. M. (2011). Application of quantitative real-time PCR for rapid identification of *Bacteroides fragilis* group and related organisms in human wound samples. *Anaerobe*, 17(2): 64-68.

16. Prindiville, T. P.; Sheikh, R. A.; Cohen, S. H.; Tang, Y. J.; Cantrell, M. C. & Silva Jr, J. (2000). Bacteroides fragilis enterotoxin gene sequences in patients with inflammatory bowel disease. *Emerging infectious diseases*, 6(2): 171.
17. Classics Lowry, O.; Rosebrough, N.; Farr, A. & Randall, R. (1951). Protein measurement with the Folin phenol reagent. *J Biol Chem*, 193(1): 265-75.
18. Van Tassell, R. L.; Lyerly, D. M. & Wilkins, T. D. (1992). Purification and characterization of an enterotoxin from Bacteroides fragilis. *Infection and immunity*, 60(4): 1343-1350.
19. Choi, V. M.; Herrou, J.; Hecht, A. L.; Teoh, W. P.; Turner, J. R.; Crosson, S. & Wardenburg, J. B. (2016). Activation of Bacteroides fragilis toxin by a novel bacterial protease contributes to anaerobic sepsis in mice. *Nature medicine*, 22(5): 563-567.
20. Bancroft, J. D. & Gamble, M. (Eds.). (2008). *Theory and practice of histological techniques*. Elsevier health sciences.
21. Ignacio,A.;Fernandes,MR.;Avila-Campos,MJ.;Nakano,V.(2015). Enterotoxigenic and non-enterotoxigenic Bacteroides fragilis from fecal microbiota of children. *Brazilian Journal of Microbiology*. 46(4): 1141-1145.
22. Jasim,D.A.and Melconian,A.K(2020). Prevalence of Enterotoxigenic Bacteroides Fragilis in stool specimens collected from children less than 5 years of age in Iraq. *Iraqi Journal of Science*. 61(12): 3179-3186.
23. Nakano, V.; Gomes, D. A.; Arantes, R. M.; Nicoli, J. R. & Avila-Campos, M. J. (2006). Evaluation of the pathogenicity of the Bacteroides fragilis toxin gene subtypes in gnotobiotic mice. *Current microbiology*, 53(2): 113-117.
24. Kim, S. H.; Lee, W.; Kwon, D.; Lee, S.; Son, S. W.; Seo, M. S.; ... & Jung, Y. S. (2020). Metabolomic analysis of the liver of a dextran sodium sulfate-induced acute colitis mouse model: implications of the gut–liver connection. *Cells*, 9(2): 341.
25. Chassaing, B.; Aitken, J. D.; Malleshappa, M. & Vijay-Kumar, M. (2014). Dextran sulfate sodium (DSS)-induced colitis in mice. *Current protocols in immunology*, 104(1): 15-25.
26. Eichele, D. D., & Kharbanda, K. K. (2017). Dextran sodium sulfate colitis murine model: An indispensable tool for advancing our understanding of inflammatory bowel diseases

- pathogenesis. *World journal of gastroenterology*, 23(33), 6016.
27. Nell, S.; Suerbaum, S. & Josenhans, C. (2010). The impact of the microbiota on the pathogenesis of IBD: lessons from mouse infection models. *Nature Reviews Microbiology*, 8(8): 564-577.
28. Rabizadeh, S.; Rhee, K. J.; Wu, S.; Huso, D.; Gan, C. M.; Golub, J. E.; ... & Sears, C. L. (2007). Enterotoxigenic *Bacteroides fragilis*: a potential instigator of colitis. *Inflammatory bowel diseases*, 13(12): 1475-1483.

دراسة تجريبية لتأثير الذيفان bft المعزول والمنقى من العزلات *Enterotoxigenic B.fragilis* على الكبد والامعاء والطحال في الفئران

حسين علي خليفة, اشواق باسم جاسم

معهد الهندسة الوراثية، جامعة بغداد.

الخلاصة

شملت هذه الدراسة ثلاث اجزاء: عزل جرثومة *Enterotoxigenic B.fragilis* من 94 عينة براز تم جمعها من مستشفيات مختلفة في مدينة بغداد من بداية آذار / 2020 حتى نهاية نيسان / 2021. تم زرع عينات البراز على وسط BBE في حالة لاهوائية لمدة 24-48 ساعة. تم التعرف على بكتيريا *B.fragilis* بناءً على الخصائص المورفولوجية على وسائط BBE: مستعمرات دائرية صغيرة محدبة باللون الرمادي تحيط بالمنطقة السوداء حول المستعمرات والطرق الجزيئية باستخدام جينات محددة *bft*, *16S rRNA*. اظهرت النتائج 34 عزلة *B.fragilis* كانت موجبة لجين *16S rRNA* و *B.fragilis* موجبة لجين *bft* صنفت على أنها سموم معوية (ETBF). تم تنقية العزلة ETBF التي كانت موجبة للجينات *bft* و *16S rRNA* باستخدام طريقة Van Tassel. تم تقسيم ثلاثين ذكر من الفئران إلى ثلاث مجموعات مع 10 فئران لكل مجموعة المجموعة الأولى كمجموعة سيطرة. المجموعة الثانية عبارة عن فئران تحكم إيجابية يتم تناولها يوميًا 2٪ كيرينات ديكستران الصوديوم، فئران المجموعة الثالثة تم إعطاؤها بواسطة أنبوب معدني 2٪ DSS لمدة 10 أيام بعد 10 أيام الفئران تم إعطاؤها 20 ميكروغراماً من الذيفان bft عن طريق أنبوب المعدة لمدة 30 يوم. في نهاية التجربة، قُتل جميع مجموعات الفئران بأخلاق القتل الرحيم. تمت إزالة عينات الأنسجة (الكبد والأمعاء والطحال) من الفئران. تم تثبيت الأعضاء في 10٪ فورمالين مخزون محايد للتقنيات النسيجية. التغيرات النسيجية المرضية في المجموعة الثالثة في الكبد في الفئران أظهرت: خلايا كبدية نخرية وأشباه جيوب متوسعة مصحوبة بنزيف. كما أظهرت التغيرات النسيجية المرضية في الجزء المعوي من الفئران: تقشر وتآكل الزغابات وتقصير الزغابات. أظهرت التغيرات النسيجية المرضية في الطحال: تسلل أميلويد (الداء النشواني) وجميع البصيلات اللمفاوية مستنفدة مع الخلايا الليمفاوية النخرية.

الكلمات المفتاحية: *Bacteroides fragilis* ذيفان bft, الكبد.