



Histopathological and immunohistochemical assessment of the using platelets rich fibrin to reinforce ventral hernioplasty in the sheep model

I.A. Zedan¹, L.M. Alkattan¹ and S.S. Al-Mahmood²

¹Department of Surgery and Theriogenology, ²Department of Pathology and Poultry Disease, College of Veterinary Medicine, University of Mosul, Mosul, Iraq

Article information

Article history:

Received March 22, 2023

Accepted May 10, 2023

Available online September 9, 2023

Keywords:

Histopathology

Immunohistochemistry

PRF

Hernioplasty

Sheep

Correspondence:

S.S. Al-Mahmood

saevan981@uomosul.edu.iq

Abstract

The guidelines for this experiment were designed to assess the histopathological and immunohistochemical parameters after the topical application of plasma-rich fibrin during hernioplasty in sheep. Twenty-four rams enrolled into two groups, 12 of each. In the control group, hernioplasty was done with polypropylene mesh and a modified sub-lay technique; in the treatment group done the same as the control and reinforced with plasma-rich fibrin (PRF). Tissue samples were collected for histopathological and immunohistochemical investigations. The clinical investigation results indicated developing seroma at the lower region of the surgical site that continued 25 days post-surgery in the control group as a comparison of group PRF which indicated mild seroma. The histopathological examination at 30 days in the control group indicated the presence of focal infiltration of mononuclear inflammatory cells around the mesh and hyperplasia of fibrocytes, deposition of collagen with edema as compared with the treatment group at 15th days post-surgery; there was a high number of new blood vessels, deposition of collagen fibers. Immunohistochemistry indicated a strong positive reaction at seven days post-surgery in control, and the PRF group with IL-6 appeared as golden-brown granules in the cytoplasm of cells around the surgical mesh. At seven days post-surgery, the reaction of VEGF antibody IHC indicated negative and strong positive reactions with VEGF appearing as golden-brown granules in the cytoplasm of cells in the treatment group. In conclusion, using PRF to repair the hernia reduces the incidence of inflammation, and histopathological and immunohistochemistry investigations emphasize an improvement in the healing process of hernia.

DOI: [10.33899/ijvs.2023.139183.2900](https://doi.org/10.33899/ijvs.2023.139183.2900), ©Authors, 2023, College of Veterinary Medicine, University of Mosul.

This is an open access article under the CC BY 4.0 license (<http://creativecommons.org/licenses/by/4.0/>).

Introduction

The surgery is indicated in the case of a defective abdominal wall, represented by one of the most abdominal hernias (1). The main causes of hernias are related to disorders of collagen as well as to the surgical tension technique used; any damage or injuries to the abdominal muscle leads to fibrosis, which means that it does not have the same strength to keep the integrity of the wall when facing any sustained internal pressure (2). Several prosthetic agents were used to repair the hernial defects different types

of materials to perfectly minimize the frequency of recurrences reduction of recovery time of hernia and its complication incidence rates (3) as a non-resorbable synthetic polymeric agent (polyethylene), which widely applied to reinforce the abdominal wall (4) or using of biomaterials which may reduce the incidence in pain as a cellular bubaline diaphragm matrix (3), Aloe Vera leave juice (5). The reconstruction of a large intraabdominal hernia represents a challenge for veterinary practice (6,7). It is reconstituted using synthetic polypropylene mesh in different animals as bovine and equine (8,9), and in sheep

using decellularized fish skin as biological materials to reconstitute intraabdominal hernia. This material is the perfect source of collagen, as type 1 and 2, which is considered a biodegrade and biocompatible scaffold and perfect natural ECM (10). Its accelerated wound healing process due encouraged cell proliferation differentiation, and adhesion, so last year, the collagen used successfully for scaffolds production as a natural polymer (11). The autologous platelet-rich fibrin sealant (P-RFS) eliminates the risk of infection and adhesion. It has additional advantages, such as hemostatic and antibacterial effects (12,13). Its second generation of concentrates platelet is Known as PRF. Its obtained simply by centrifugation of peripheral autogenous blood without activation by biochemical agents. This substance contains many compounds, such as platelets, leucocytes, and various essential healing proteins inside a dense fibrin matrix, which can be considered an autologous healing biomaterial agent. This crude bioactive membrane can improve the soft/hard tissue healing process while shielding surgical approaches and implanted materials from outside aggressions to its robust fibrin architecture, glycoproteins, and gradual release of growth factors over several days (14). PRF can contribute to bone regeneration grafting (15). Combining PRF with grafting material is considered a regenerative agent, which is important in improving the healing process in soft tissue (16). PRF was used successfully with mesh for repairing inguinal hernias as a safe and effective option for an enhanced healing process (17).

The guidelines for this experiment were designed to assess the histopathological and immunohistochemical parameters after the topical application of plasma-rich fibrin during hernioplasty in sheep.

Materials and methods

Ethical Approve

This Research was approved by the Ethics Committee of the Faculty of the College of Veterinary Medicine Medicine/ Mosul University No. UM.VET.2021.055.

Experimental design

The present trial enrolled twenty-four rams whose weight and age were 41 ± 0.4 kg and 12 ± 0.2 kg, respectively. Two equal groups were distributed randomly, twelve of each. Anesthesia protocol included sedation with 0.01 mg/kg Bwt of 2% xylazine (Alfasan, Holland) and local infiltration of lidocaine 3.4 mg/kg Bwt (18). An experimental hernias defect was induced with a 12 cm vertical incision that approached through the skin and subcutaneous tissue without peritoneum layer opening. The defective opening lifted for one month to form the hernia component. The hernia was reconstituted by polypropylene mesh 30×30 cm (Betatech®)-Turkey, fixed firmly by a modified sub-lay

technique, the edges of mesh put between the peritoneum and abdominal muscle (Figure 1).

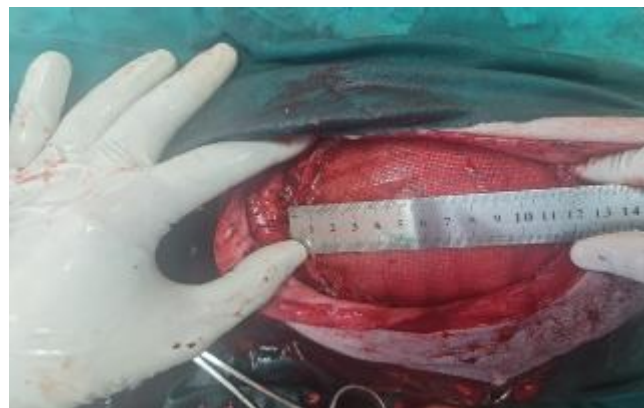

Figure 1: Shows hernioplasty with polypropylene mesh by modified sub-lay method.

Tissue processing and sectioning

The collected samples were prepared by several steps, including fixation with 10% neutral buffered formalin for 72 hours, then processed to be embedded in paraffin wax (19), the sample dehydrated with 70% ethyl alcohol overnight, then 80% ethyl alcohol for one hour, 90% ethyl alcohol for one hour at two changes, then clearing the tissue, after that samples were transferred to hot paraffin wax at 55-58°C for one hour at three changes, after paraffin block completed the rotary microtome at 4-6 μ m was used, and slide transferred to the floatation water bath, and lifted using labeled clean glass slide, and dried at room temperature for 24 hours, then slide put on a hot plate to complete drying for one hour at 55-60°C, the slide was ready to stain. The slide was stained by Harris hematoxylin and alcoholic eosin (19).

Immunohistochemistry analysis

Immunohistochemistry was achieved by using the avidin-biotin immunoperoxidase technique. The tissue sections were deparaffinised, rehydrated, deactivated then submitted to IHC protocol. Endogenous peroxidase blocked by 3% hydrogen peroxide-methanol solution for 10 min. Washed in PBS at pH 7.4. Blocked by 0.5% goat serum for 30 minutes at room temperature. The slides were incubated with primary antibodies for *IL-6* (Cat# E-AB-30095, Elabscience, China) (20) and *VEGF-A* (Cat# E-IR-R217B, Elabscience, USA) (21), which is a rabbit polyclonal antibody at dilution equal to 1:100 (Elabscience, China) overnight at 4°C. Later, slides were washed with PBS three times each, then incubated with polyperoxidase-anti-rabbit IgG as a secondary antibody at dilution 1:400 (Cat# E-AB-19306, Elabscience, China) for 30 minutes at 37°C, then washed with PBS, the stained using Dab system. The slides were counterstained with haematoxylin, rinsed in distal

water, dehydrated, and cover slipped. Using Image J program, *IL-6* and *VEGF-A* staining.

PRF preparation

PRF was prepared according to the PRF protocol in the dog (22-24) 10 mm of sheep blood was collected aseptically and centrifuged at 3000 rpm for 10 min. After centrifugation, the blood in the tube was separated into three distinct zones, the upper layer of platelet-poor plasma, PRF in the middle, and RBC at the bottom (Figure 2), and this applied directly at the borders of mesh.

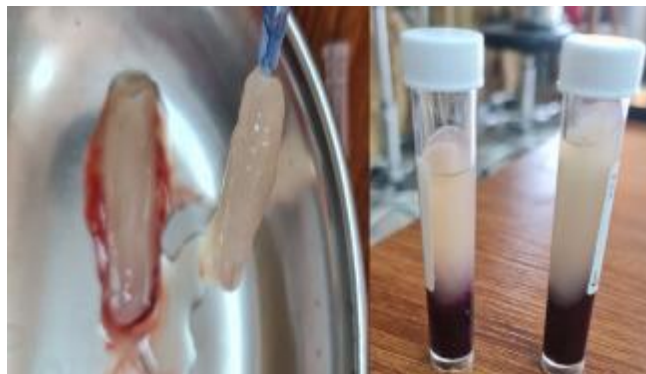

Figure 2: Shown the method of preparing PRF.

Results

The surgical wounds healed without any complications; throughout the follow-up periods until the hernias were treated, no signs of bleeding, hematoma, infection, stitches, or abscess were noted. Each animal showed success on day 30 following hernia induction. A clear, palpable hernia ring with thick, rounded edges and an inverting hernia sac had developed as a reducible ventrolateral hernia which emphasizes the hernia components (Figure 3).

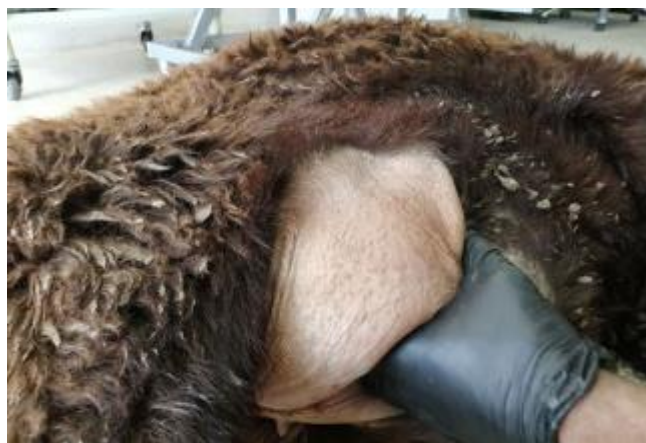

Figure 3: Shows an induced hernia after 30 days; the hernia compartments were tested by hand.

Following henioplasty, a seroma developed at the lower region of the surgical site; an accumulation of serous fluid at the site of hernioplasty this signs continued for a few days post-surgery and gradually subsided during 25 days post-surgery (Figure 4); this sign in mild degree within group PRF as a comparison to the control group (Figure 5).

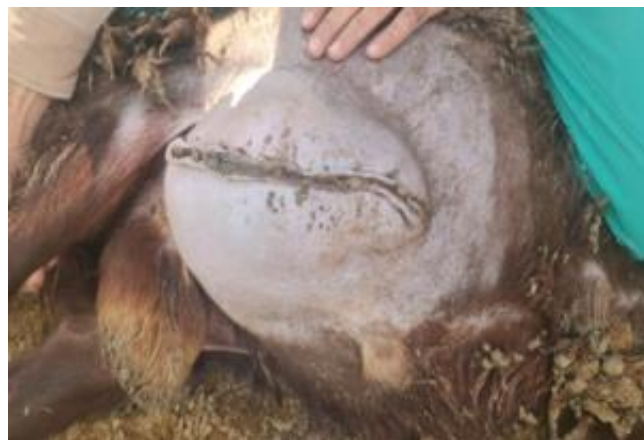

Figure 4: Shows seroma a few days post-surgery.



Figure 5: Shows seroma a few days post-surgery in the control group in the PRF group.

Histopathological and immunohistochemical findings

No abscess formation was found in all experimental animals, there were no signs of gangrene, necrosis, and rejection throughout the study, no signs of hernia recurrence were seen in any of the experimental animals, and the hernia ring and hernia sac completely vanished in all experimental animals of two groups. Histopathological investigations at the 7th-day post-surgery in the control group exhibited space of surgical mesh, hyperplasia of fibrocytes, deposition of collagen fibers, granulation tissue formation, and infiltration of mononuclear inflammatory cells around surgical mesh

(Figure 6). At 15 days post-surgery showed focal infiltration of mononuclear inflammatory cells around the surgical mesh, hyperplasia of fibrocytes, deposition of collagen fibers with edema, and granulation tissue formation (Figure 7).

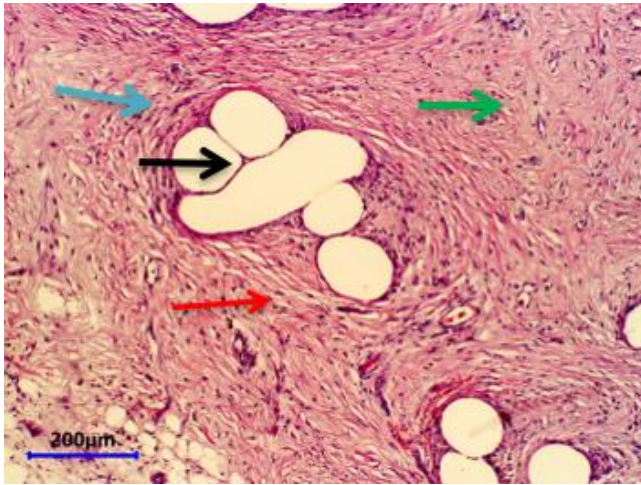


Figure 6: Micrograph at seven days in the control group showed space of surgical mesh (black arrow), hyperplasia of fibrocytes (blue arrow), deposition of collagen fibers (red arrow), and granulation tissue formation (green arrow). H&E.

At 30 days showed focal infiltration of mononuclear inflammatory cells around the surgical mesh, hyperplasia of fibrocytes, deposition of collagen fibers with edema, and granulation tissue formation with new blood vessels (Figure 8). In the treatment group with PRF on the seventhth-day post-surgery. The results indicated space of surgical mesh, hyperplasia of fibrocytes, deposition of collagen fibers, granulation tissue formation, and few infiltrations of mononuclear inflammatory cells around the surgical mesh; new blood was present in vessels (Figure 9). On the 15th day post-surgery, the results indicated a few focal infiltrations of mononuclear inflammatory cells around the surgical mesh, many new blood vessels, deposition of collagen fibers with edema, and granulation tissue formation (Figure 10). At 45 days, the treatment group with PRF Showed space left by surgical mesh, mature collagen fibers, and mature granulation tissue (Figure 11). Immunohistochemistry investigation at seven days post-surgery in the control group indicated a strong positive reaction with IL-6 appearing as golden-brown granules in the cytoplasm of cells around the surgical mesh (Figure 12). At 30 days, the results exhibited a positive reaction with IL-6 appearing as golden-brown granules in the cytoplasm of cells around the surgical mesh (Figure 13). The results of the investigation of vascular endothelial growth factor antibodies in the control group at seven days post-surgery indicated a negative reaction with VEGF C (Figure 14).

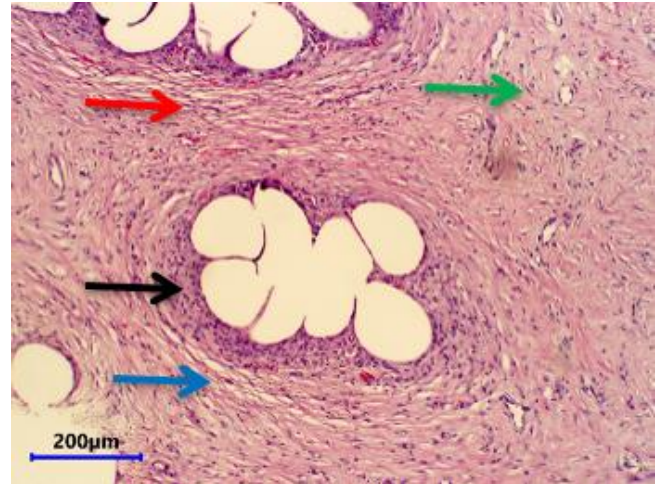


Figure 7: Micrograph at 15 days in the control group showed focal infiltration of mononuclear inflammatory cells around surgical mesh (black arrow), hyperplasia of fibrocytes (blue arrow), deposition of collagen fibers with edema (red arrow), granulation tissue formation (green arrow). H&E.

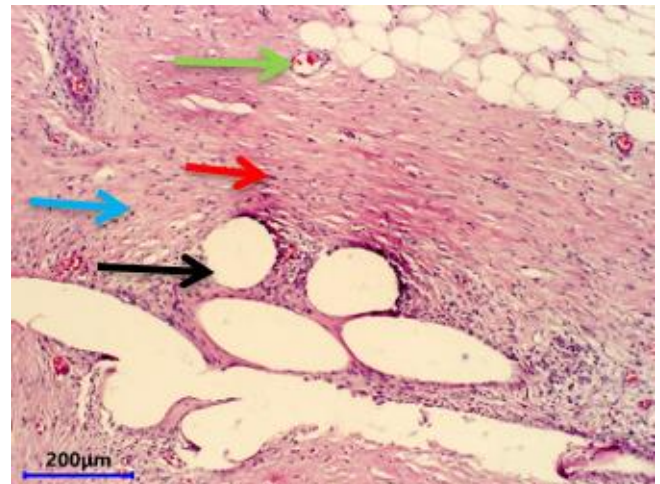


Figure 8: Micrograph at 30 days post-surgery days in the control group showed focal infiltration of mononuclear inflammatory cells around surgical mesh (black arrow), hyperplasia of fibrocytes (blue arrow), deposition of collagen fibers with edema (red arrow), granulation tissue formation with new blood vessels (green arrow). H&E.

At 15 days post-surgery, a weak positive reaction with VEGF appears as golden-brown granules in the cytoplasm of cells around the surgical mesh (Figure 15). Seven days post-surgery in the treatment group indicated a strong positive reaction with IL-6 appearing as golden-brown granules in the cytoplasm of cells around the surgical mesh (Figure 16). At 30 days Showed weak positive reaction in a few cells with IL-6 appeared as golden-brown granules in the cytoplasm of

cells around surgical mesh (Figure 17). The results of the investigation of vascular endothelial growth factor antibodies in the treatment group at 7 and 15 days indicated that a strong positive reaction with VEGF appeared as golden-brown granules in the cytoplasm of cells around the surgical mesh (Figures 18 and 19). Whereas 45 days post-surgery indicated a negative reaction with VEGF (Figure 20).

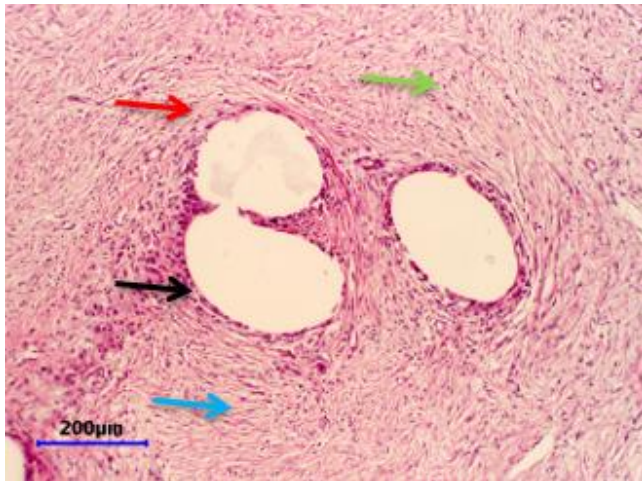


Figure 9: Micrograph at seven days in the treatment group with PRF showed space of surgical mesh (black arrow), hyperplasia of fibrocytes (blue arrow), deposition of collagen fibers (red arrow), and granulation tissue formation (green arrow). H&E.

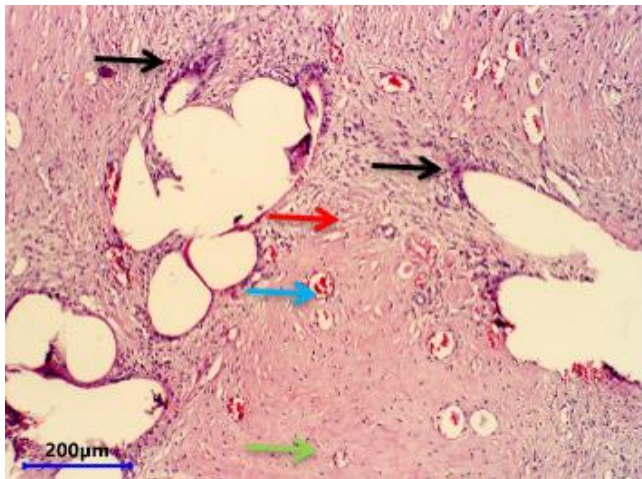


Figure 10: Micrograph at 15 days in the treatment group with PRF showed few focal infiltrations of mononuclear inflammatory cells around surgical mesh (black arrow), a high number of new blood vessels (blue arrow), deposition of collagen fibers with edema (red arrow), granulation tissue formation (arrow). H&E.

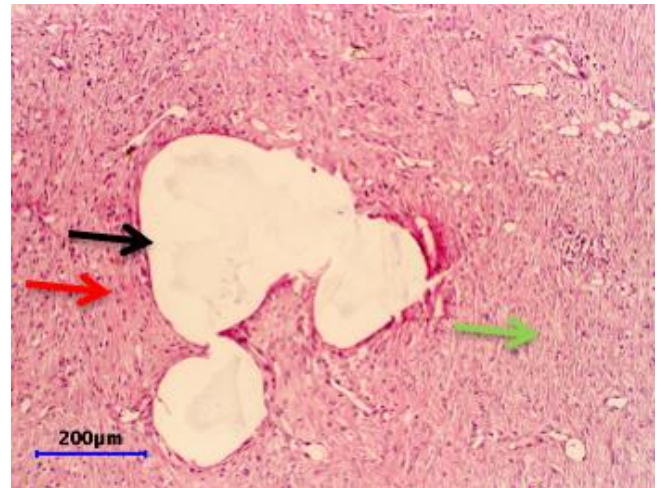


Figure 11: Micrograph at 45 days in the treatment group with PRF Showed space left by surgical mesh (black arrow), mature collagen fibers (red arrow), and mature granulation tissue (green arrow). H&E.

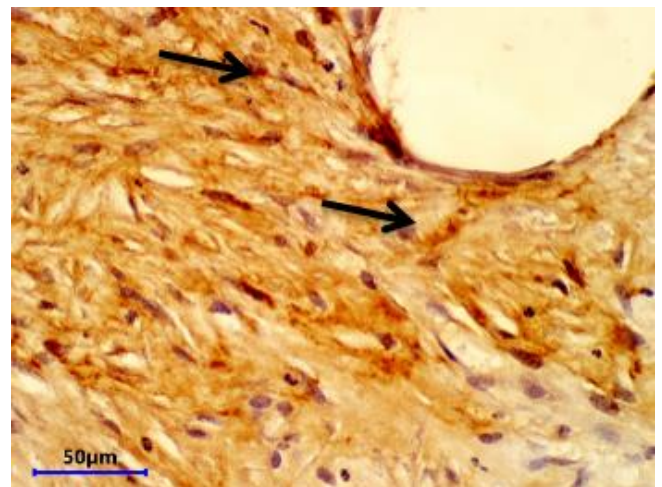


Figure 12: Micrograph at seven days post-surgery in the control group indicated a strong positive reaction with IL-6 appearing as golden-brown granules in the cytoplasm of cells around surgical mesh (arrow). IL-6 antibody IHC.

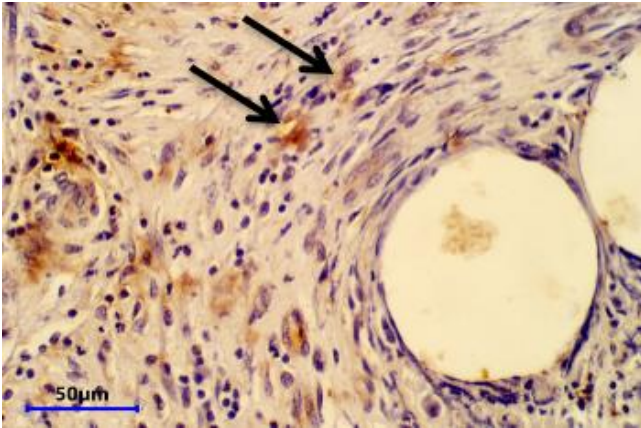


Figure 13: Micrograph at 30 days post-surgery in the control group indicated a positive reaction with IL-6 appearing as golden-brown granules in the cytoplasm of cells around surgical mesh (arrow). IL-6 antibody IHC.

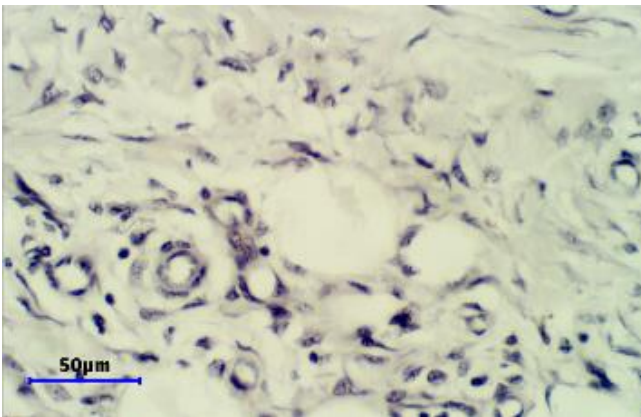


Figure 14: Micrograph at seven days post-surgery indicated a negative reaction with VEGF. VEGF antibody IHC.

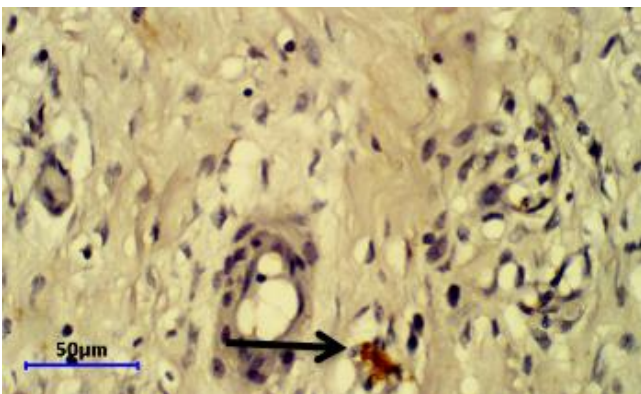


Figure 15: Micrograph at 15 days post-surgery indicated a weak positive reaction with VEGF appearing as golden-brown granules (arrow) in the cytoplasm of cells around the surgical mesh. VEGF antibody IHC.

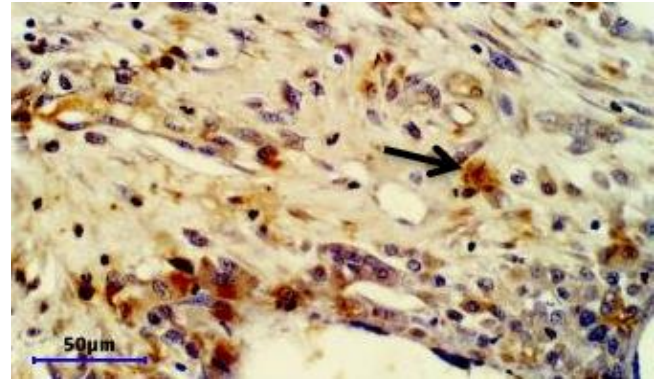


Figure 16: PRF. Abdominal wall. Seven days. Showed a strong positive reaction with IL-6 and appeared as golden-brown granules in the cytoplasm of cells around the surgical mesh (arrow). IL-6 antibody IHC.

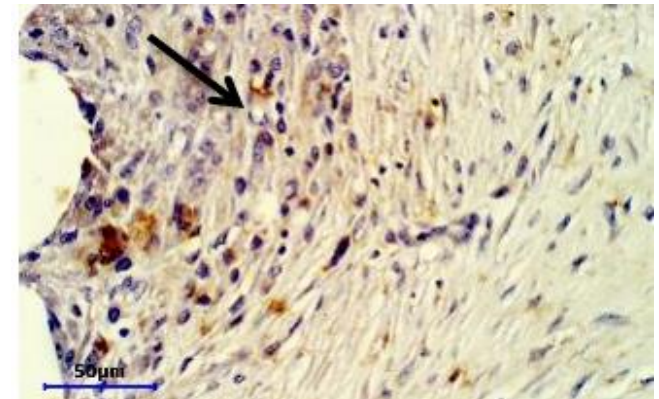


Figure 17: The treatment group with PRF At 30 days Showed a weak positive reaction in a few cells with IL-6 that appeared as golden-brown granules in the cytoplasm of cells around the surgical mesh (arrow). IL-6 antibody IHC.

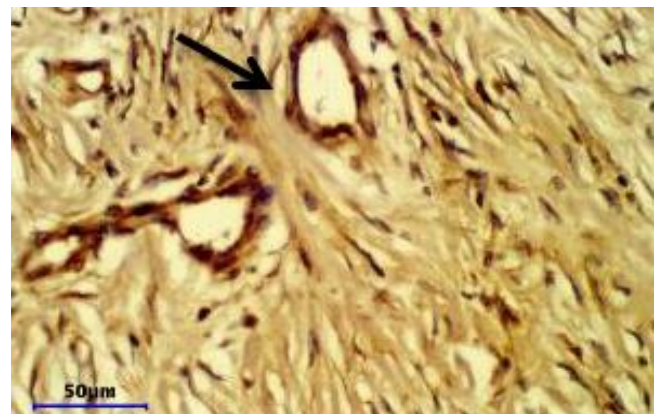


Figure 18: Micrograph at seven days post-surgery in the PFR group indicated a strong positive reaction with VEGF appearing as golden-brown granules in the cytoplasm of cells around surgical mesh (arrow). VEGF antibody IHC.

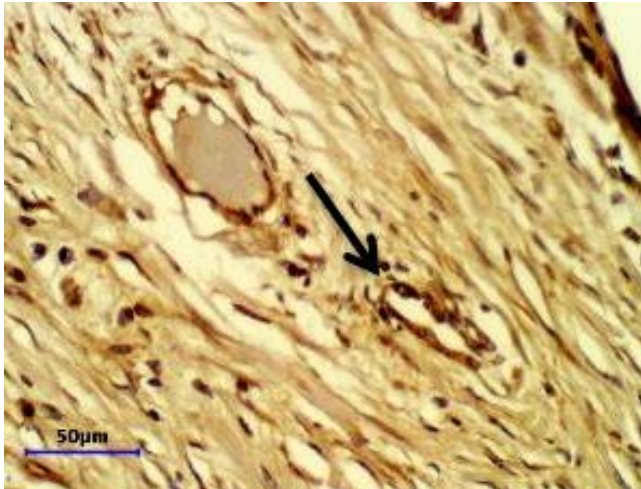


Figure 19. The micrograph at 15 days post-surgery indicated that the PFR group had a strong positive reaction with VEGF and appeared as golden-brown granules in the cytoplasm of cells around the surgical mesh (arrow). VEGF antibody IHC.

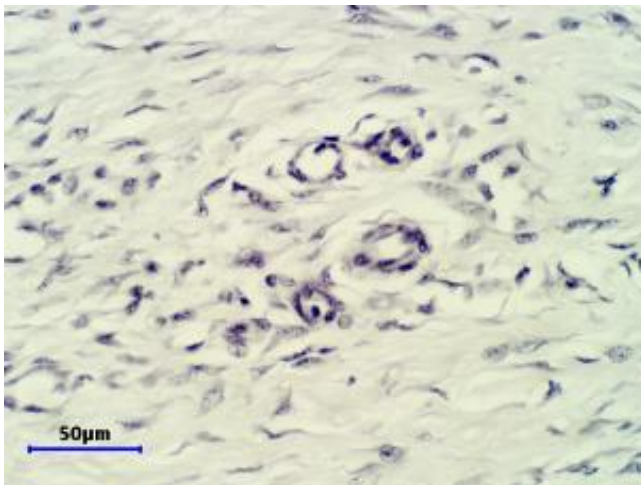


Figure 20: Micrograph at 45 days post-surgery indicated negative reaction with VEGF. VEGF antibody IHC.

Discussion

In this manuscript, the seroma was indicated mainly in the first group (control group); it indicated that the formation of dead space, as a result, detached a considerable amount of subcutaneous tissue due to operation as well as the injury of the blood vessels during dissection may result in seroma formation this result indicated in another study which suggested that the abdominal wall access in hernia repairing lead to accumulation of serum and blood and among the various layers of surgical wound resulting in dead space or seroma (25-27).

The current study showed that the PRF group showed rapid healing histological changes compared with control groups, in which the deposition and maturation of collagen fibers, granulation tissue formation, and expression of IL-6 and IL-12 in the PRF group took place faster than in the control group.

The angiogenic activity of PRF has a great effect on wound healing; this effect is appeared as increasing expression of VEGF in the epithelial cells of blood vessels in the wound site in the epithelial cells of new blood vessels, the increase in the number of these vessels will bring more fluid to dilute the causative agent effect and bring more cell to the site of reaction to faster the healing process and these cells also act to remove any cellular debris that accumulates in the wound site (28,29). In addition, the PRF can greatly increase the differentiation of epithelial cells and their proliferation; these processes help in fast reepithelization and promote healing (30-32). Since the PRF contains a huge amount of cytokines, PRF exerts as a chemokines reservoir, which secretes inflammatory cytokines to promote the healing process and give an additional feed effect to the natural cytokines produced due to wound formation; these massive pulses of cytokines cause rapid expression of IL-6 gene in the site of action to increase IL-6 formation for affect cells and PRF materials, to exert its effect by the increase in chemical attraction of phagocytes to neutralize the causative agent, removal of dead tissues, and promote the healing process especially newly blood vessels formation (33). IL-6 play an important role in the first three days of the healing process, and the decline in IL-6 concentration leads to an increase in IL-12 concentration in the wound site, which promotes the deposition of collagen fibers and their maturation, so the rapid formation of IL-6 (anti-inflammatory cytokines) means it will rapidly decrease in its concentration, that means rapid elevation in the IL-12 concentration (post-inflammatory cytokines) these will lead to rapid granulation tissue formation, collagen deposition, and maturation, all these accelerating events will lead to shorten the time for the wound to be healed (34).

Conclusion

The use of PFR hastens the healing of repaired hernia, reduces the incidence of adhesion, and proved by histopathological and immunohistochemistry examination indicated an improvement in the healing process.

Acknowledgment

We thank the College of Veterinary Medicine, University of Mosul, for supporting this study.

Conflict of interest

The manuscript has no conflict of interest.

References

1. See CW, Kim T, Zhu D. Hernia mesh and hernia repair: A review. *Eng Regen.* 2020;1:19-33. DOI: [10.1016/j.engreg.2020.05.002](https://doi.org/10.1016/j.engreg.2020.05.002)
2. Falco EE, Roth JS, Fisher JP. Skeletal muscle tissue engineering approach to abdominal wall hernia repair. *Birth Defects Res C Embryo Today.* 2008;84:315-321. DOI: [10.1002/bdrc.20134](https://doi.org/10.1002/bdrc.20134)
3. Rathore HS, Raghuvansi PS, Gautam D, Mohan D, Singh AK, Singh AP, Maiti SK, Kumar N. Use of the bubaline acellular diaphragm matrix (ADM) for repair of abdominal wall defects in four different species of animals. *Int J Chem Stud.* 2018;6(4):157-161. [\[available at\]](https://doi.org/10.1016/j.jss.2018.11.054)
4. Miserez M, Jairam AP, Boersema GA, Bayon Y, Jeekel J, Lange JF. Resorbable synthetic meshes for abdominal wall defects in preclinical setting: A Literature Review. *Jof Surg Res.* 2019;(237):67-75. DOI: [10.1016/j.jss.2018.11.054](https://doi.org/10.1016/j.jss.2018.11.054)
5. Zedan IA, Alkattan LM, Al Iraqi OM. An evaluation of Aloe vera leaves gel with polypropylene mesh to repair of ventrolateral abdominal hernia in rams. *Iraqi J Vet Sci.* 2022;36(1):19-25. DOI: [10.33899/ijvs.2022.134989.2430](https://doi.org/10.33899/ijvs.2022.134989.2430)
6. Kumar V, Kumar N, Mathew DD, Gangwar AK, Saxena AC, Remya V. Repair of abdominal wall hernias using a cellular dermal matrix in goats. *J Appl Anim Res.* 2012;4(1):117-120. DOI: [10.1080/09712119.2012.738222](https://doi.org/10.1080/09712119.2012.738222)
7. Kumar N, Mathew DD, Gangwar AK, Remya V, Umar MA, Muthala VI, Maiti SK, Sharma A K, Uthala VI. Reconstruction of large ventro-reconstruction of large ventrolateral hernia in a buffalo with acellular dermal matrix. *Vet Arhiv.* 2014;84:691-699. [\[available at\]](https://doi.org/10.1111/vsu.12773)
8. Tóth F, Schumacher J. Prosthetic mesh repair of abdominal wall hernias in horses. *J Vet Surg.* 2018;47(4):536-542. DOI: [10.1111/vsu.12773](https://doi.org/10.1111/vsu.12773)
9. Singh K, Mahajan SK, Sangwan V, Kumar A, Gopinathan A, Saini NS. Ventral abdominal hernioplasty using polypropylene mesh in a cow. *Indian J Vet Surg.* 2011;32(1):71. [\[available at\]](https://doi.org/10.1016/j.jss.2018.11.054)
10. Bassam HJ. A Comparative study of using freshwater and marine fish acellular dermal matrices in reconstruction of ventro-lateral abdominal wall hernia in Bucks [Ph.D. dissertation]. Iraq: University of Baghdad, Baghdad. 2021. 70 p.
11. Bezerra LR, Filho MO, Bruno ZV, Junior EM, Alves AP, Bilhar, AP, Dias MT and Rios LC. Tilapia fish skin: A new biological graft in gynecology. *Rev Med UFC.* 2018;58(2):6-8. DOI: [10.20513/2447-6595.2018v58n2p6-8](https://doi.org/10.20513/2447-6595.2018v58n2p6-8)
12. Hingde de IH, Nienhuijs SW, Overdeves EP, Scheele K, Everts PA. Mesh fixation with autologous platelet-rich fibrin sealant in inguinal hernia repair. *Eur Surg Res.* 2009;43(3):306-309. DOI: [10.1159/000233526](https://doi.org/10.1159/000233526)
13. Bielecki TM, Gazdzik TS, Arendt J, Szczepanski T, Krol W, Wielkoszynski T. Antibacterial effect of autologous platelet gel enriched with growth factors and other active substances: An in vitro study. *J Bone Joint Surg Br.* 2007;89:417-420. DOI: [10.1302/0301-620X.89B3.18491](https://doi.org/10.1302/0301-620X.89B3.18491)
14. Ehrenfest DM, Doglioli P, Peppo Gi M de, Del Corso M, Charrier JB. Choukroun's platelet-rich fibrin (PRF) stimulates in vitro proliferation and differentiation of human oral bone mesenchymal stem cell in a dose-dependent way. *Arch Oral Biol.* 2010;55(3):185-94. DOI: [10.1016/j.archoralbio.2010.01.004](https://doi.org/10.1016/j.archoralbio.2010.01.004)
15. Easa MS, Alkhawas MB, Gobran HG, Islam TM. Evaluation of the effect of PRF on bone healing in diabetic animals after peridicular surgery. *Al-Azhar J Den Sci.* 2021;24(4):379-385. DOI: [10.21608/AJDSM.2020.45472.1122](https://doi.org/10.21608/AJDSM.2020.45472.1122)
16. Moheb ME, Al-Zarea B, Sghaireen MG, Toriya J, Mizohata A, Patil S, Siada A, Brad B, Kochaji N, Alam MK, Osuga N. Mineralized plasmatic matrix to enhance the bone grafting technique. *J Hard Tissue Bio.* 2017;26:289-92. DOI: [10.2485/JHTB.26.289](https://doi.org/10.2485/JHTB.26.289)
17. Valerio DN, Giovanni DT. Platelet-rich fibrin-mesh technique for inguinal hernia repair: Results of a feasibility pilot study. *Surg Tech Int.* 2021;38. DOI: [10.52198/21.STI.38.HR1354](https://doi.org/10.52198/21.STI.38.HR1354)
18. Green S, Thurmon JC. Xylazine a review of its pharmacology and use in vet medicine. *J Vet Pharmacol Ther.* 1988;11:295-313. DOI: [10.1111/j.1365-2885.1988.tb00189.x](https://doi.org/10.1111/j.1365-2885.1988.tb00189.x)
19. Luna LG. Manual of histologic staining methods of the armed forces institute of pathology. 3rd ed. USA: McGraw-Hill: 1968. 18-20 p.
20. Post GR, Bell RC, Rjoop A, Lobo RH, Yuan Y, Post SR. Diagnostic utility of interleukin-6 expression by immunohistochemistry in differentiating castelman disease subtypes and reactive lymphadenopathies. *Ann Clin Lab Sci.* 2016;46(5):474-479. [\[available at\]](https://doi.org/10.1016/j.jss.2018.11.054)
21. Maae E, Nielsen M, Steffensen K D, Jakobsen EH, Jakobsen A, Sørensen FB. Estimation of immunohistochemical expression of VEGF in ductal carcinomas of the breast. *J Histochem Cytochem.* 2011;59(8):750-760. DOI: [10.1369/0022155411412599](https://doi.org/10.1369/0022155411412599)
22. Liu Y, Sun X, Yu J, Wang J, Zhai P, Chen S, Liu M, Zhou Y. Platelet-rich fibrin as a bone graft material in oral and maxillofacial bone regeneration: Classification and summary for better application. *BioMed Res Int.* 2019;2019:1-16. DOI: [10.1155/2019/3295756](https://doi.org/10.1155/2019/3295756)
23. Saluja H, Dehane V, Mahindra U. Platelet-rich fibrin: A second generation platelet concentrate and a new friend of oral and maxillofacial surgeons. *Ann Maxillofacial Surg.* 2011;1(1):53. DOI: [10.4103/2231-0746.83158](https://doi.org/10.4103/2231-0746.83158)
24. Gobbi G, Vitale M. Platelet-rich plasma preparations for biological therapy: Applications and limits. *Oper Tech Orthop.* 2012;22:10-15. DOI: [10.1053/j.oto.2012.01.002](https://doi.org/10.1053/j.oto.2012.01.002)
25. Tsimoyiannis EC, Tsimoyiannis KE, George P, Konstantinos N, Karfis E. Seroma and recurrence in laparoscopic ventral hernioplasty. *J Soc Laparoendosc Surg.* 2008;12(1):51-57. [\[available at\]](https://doi.org/10.1016/j.jss.2018.11.054)
26. Raftopoulos I, Vanuno DL, Khorsand J, Kouraklis G, Lasky P. Comparison of open and laparoscopic prosthetic repair of large ventral hernias. *J Soc Laparoendosc Surg.* 2003;7(3):227-32. [\[available at\]](https://doi.org/10.1016/j.jss.2018.11.054)
27. Alhamdany MS, Alkattan LM. Laparoscopic and hand-assisted cystorhaphy strengthened with omental pedicle in dogs: Radiographic and ultrasonographic. *Iraqi J Vet Sci.* 2019;33(2):347-352. DOI: [10.33899/ijvs.2019.163026](https://doi.org/10.33899/ijvs.2019.163026)
28. Ratajczak J, Vanganswinke T, Gervois P, Merckx G, Hilken PL, Quiryren M, Lambrechts I, Bronckaers A. Angiogenic properties of 'leukocyte- and platelet-rich fibrin'. *Sci Rep.* 2018;8:14632. DOI: [10.1038/s41598-018-32936-8](https://doi.org/10.1038/s41598-018-32936-8)
29. Martinez CE, Smith PC, Palma Alvarado VA. influence of platelet-derived products on angiogenesis and tissue repair: a concise update. *Front Physiol.* 2015;6:290. DOI: [10.3389/fphys.2015.00290](https://doi.org/10.3389/fphys.2015.00290)
30. Kathrina L, Marcelo I, Lauren CG, Karen KH. Regulation of endothelial cell differentiation and specification. *Circ Res.* 2013;112(9):1272-1287. DOI: [10.1161/CIRCRESAHA.113.300506](https://doi.org/10.1161/CIRCRESAHA.113.300506)
31. Allawi AH, Alkattan LM, Al Iraqi OM. The effect of autogenous peritoneal graft augmented with platelets- plasma rich protein on the healing of induced Achilles tendon rupture, in dogs. *Iran J Vet Med.* 2020;14 (2):291379. DOI: [10.ijvm.2020.291379.1005037](https://doi.org/10.ijvm.2020.291379.1005037)
32. Allawi AH, Alkattan LM, Alirazi OM. Clinical and ultrasonographic study of using autogenous venous graft and platelet-rich plasma for repairing Achilles tendon rupture in dogs. *Iraqi J Vet Sci.* 2019;33(2):453-460. DOI: [10.33899/ijvs.2019.163199](https://doi.org/10.33899/ijvs.2019.163199)
33. Nasirzade J, Kargarpour Z, Hasannia S, Strauss FJ, Grube R. Platelet-rich fibrin elicits an anti-inflammatory response in macrophages in vitro. *J Periodontol.* 2020;91:244-252. DOI: [10.1002/JPER.19-0216](https://doi.org/10.1002/JPER.19-0216)
34. Dittrich A, Kemper WH, Schaper F. Systems biology of IL-6, IL-12 family cytokines. *Cytokine Growth Factor Rev.* 2015;26(5):595-602. DOI: [10.1016/j.cytogfr.2015.07.002](https://doi.org/10.1016/j.cytogfr.2015.07.002)

معداً إضافة البلازما الغني بالفيرين. تم اخذ العينات النسيجية في فترات مختلفة لأجراء الفحص النسيجي المرضي والنسيجي المناعي. أظهرت نتائج الفحص السريري ظهور علامات تجمع مصلي في المنطقة السفلية من موضع الجراحة حيث استمرت خمسة وعشرين يوماً بعد العملية الجراحية في مجموعة السيطرة إذا ما قورنت بمجموعة البلازما الغني بالفيرين والتي كان التجمع المصلي فيها بدرجة طفيفة. أشارت نتائج الفحص النسيجي المرضي بعد ثلاثين يوماً في مجموعة السيطرة ارتشاح خلايا متعددة النواة حول الشبكة الجراحية ووجود فرط تنسج في الخلايا الليفية وترسب الكولاجين مع وجود الوذمة مقارنة بالمجموعة المعاملة لبلازما الغني بالفيرين بعد خمسة عشر يوماً من العملية الجراحية حيث وجود أوعية دموية فنية وترسب الليف الكولاجين. أشارت نتائج الفحص النسيجي المناعي وجود تفاعل إيجابي مناعي قوي بعد سبعة أيام في مجموعة السيطرة ومجموعة البلازما الغني بالفيرين مع الانترولوكين السادس حيث ظهر على شكل حبيبات ذهبية بنية في هيولي الخلايا حول الشبكة الجراحية بينما أشار مضاد عامل النمو لبطانة الوعاء في اليوم السابع تفاعل سلبي أما في مجموعة المعاملة ب مجموعة البلازما الغني بالفيرين فكان التفاعل إيجابي قوي على شكل حبيبات ذهبية بنية في هيولي الخلايا. خلاصة ذلك أن استخدام إضافة البلازما الغني بالفيرين في إصلاح الفتوق قلل من نسبة التهاب وان التحري النسيجي المرضي والنسيجي المناعي أكد تحسن عمليات التئام الفتوق.

تقييم نسيجي مرضي ونسيجي مناعي لاستخدام الصفائح الدموية الغنية بالفيرين لتعزيز إلتئام الفتق البطني في نموذج الأغنام

إبراهيم احمد زيدان¹، ليث محمود القطان¹
و سيفان سعد المحمود²

¹ فرع الجراحة وعلم تناسل الحيوان، ² فرع الأمراض وأمراض الدواجن، كلية الطب البيطري، جامعة الموصل، الموصل، العراق

الخلاصة

تم تصميم دلائل هذه التجربة لتقييم العوامل النسيجية المرضية والنسيجية المناعية بعد الاستخدام الموضعي للبلازما الغني بالفيرين أثناء إصلاح الفتق البطني في الأغنام. تم استخدام أربعة وعشرين كبشاً قسمت الى مجموعتين احتوت كل مجموعة على اثني عشر كبشاً. مجموعة السيطرة، تم إصلاح الفتق باستخدام شبكة البولي بروبيلين والخياطة بتقنية تحت الطبقات المحورة، في المجموعة المعاملة باستخدام البلازما الغني بالفيرين تمت العملية بنفس مجموعة السيطرة