



Effect of aspartame in bone formation of young female rats

E.M. Al-Khashab , H.M. Al-Hashemi  and A.A. Hussein 

Department of Physiology, Biochemistry and Pharmacology, College of Veterinary Medicine, University of Mosul, Mosul, Iraq

Article information

Article history:

Received 14 February 2023

Accepted 10 May 2023

Available online 09 September 2023

Keywords:

Sweetener
Calcium
Phosphorus
Albumin

Correspondence:

A.A. Hussein

ahmvvet@hotmail.com

Abstract

Aspartame is a popular artificial sweetener with a few calories and is widely used, it is used in over 90 countries around the world. The current study was aimed to assess the effect of different doses of aspartame 0.4, 0.8, and 1.2 g/kg on the bone formation of young female rats. Twenty-four female rats aged 1.5 months and weighing 90-100 gm were grouped as the following: control group (G1), group treated with 0.4 g/kg (G2), group treated with 0.8 g/kg (G3) and group treated with 1.2 g/kg (G4). After 30 days of treatment blood samples were drawn and serum separated for estimation the biochemical parameters rat-vitamin D, rat-Insulin like growth factor-1 (rat-IGF-1), alkaline phosphatase, calcium, inorganic phosphate, and albumin. For bone histopathological examination the left femur of rats was taken after the animals were killed. The results revealed a significant elevation in serum vitamin D, IGF-1, ALP, and albumin in all treatment groups comparison to the control group. However, calcium in serum showed a significant reduction after being treated with 0.4 g/kg and 0.8 g/kg, but a significant elevation was noticed after treatment with 1.2 g/kg of aspartame. High doses of aspartame at 1.2 g/kg exhibited histopathological changes in bone sections. We concluded from the current study that excessive doses of aspartame have an unfavorable effect on bone formation and structure of growing rats.

DOI: [10.33899/IJVS.2023.138355.2793](https://doi.org/10.33899/IJVS.2023.138355.2793), ©Authors, 2023, College of Veterinary Medicine, University of Mosul.

This is an open access article under the CC BY 4.0 license (<http://creativecommons.org/licenses/by/4.0/>).

Introduction

Aspartame is a synthetic non saccharide sweetener and it has a sweeter taste than sucrose by 200 times (1). Aspartame was discovered in 1965 and then the Food and Drug Administration (FDA) approved it using in the 1981 (2). Aspartame is an ingredient of nearly 6000 commercial products widespread in all over the world, whether they are food or pharmaceutical products (3). Aspartame has brand names such as Equal and NutraSweet, and it used widely in many products, especially those classified as diet foods, which include breakfast cereal products, chewing gum, yogurt, instant coffee, and pharmaceuticals (4). It is a methyl ester from aspartic acid with phenylalanine dipeptide (5). By actions of the esterase and the peptidases, aspartame can hydrolyze it absorbed through the gut, and released its components aspartic acid 40%, phenylalanine 50% and

methanol 10%. At high doses and prolonged aspartame consumption, these releasing components have harmful effect and it may be more toxic than aspartame (6). At first, methanol is oxidized to formaldehyde, which is then converted in the liver to formic acid. In fact, both formaldehyde and formic acid are known as harmful substances for the liver and damage its cells (7,8). Also, the superoxide anion and the hydrogen peroxide are produced through the aspartame hydrolysis, which caused the denaturation of protein that affect the structures of enzymes (9). Carcinomas in renal pelvis, was observed in the females' ureter and breast, who consumed excessive amounts of aspartame (10), and in males malignant of peripheral nerves was noted (11,12). Some studies have showed, that consumption of soft drink which contain caloric sweeteners causes a negative effect on health, and these effects may extend to bone, since adolescents who consumed soft drink

showed a reduction in the mineral density of bone also growing in bone fractures risks (13,14).

We aimed in current research to study the effect of aspartame in bone formation of young ages was the goal of the present study, since the bone growth is greater.

Materials and methods

Ethical approve

The approval of ethics for the current study was obtained from the laboratory animals housed in the College of Veterinary Medicine of Mosul University with a number of approvals UM.VET.2022.029.

Laboratory animals and experimental design

Twenty-four females rat 1.5 months old, weighting 90-100 gm were maintained under controlled conditions involved, 12h -12h light-dark in the animal's house in College of Veterinary Medicine /University of Mosul. The rats were given the standard diet and water, and were grouped into four groups, each group included six rats. Group 1 (G1) as control group were given distilled water. Group 2 (G2) rats were given aspartame 0.4 g/kg/day orally. Group 3 (G3) rats were given aspartame 0.8 g/kg/day orally. Group 4 (G4) rats were given aspartame 1.2 g/kg/day orally.

Chemicals

Pure aspartame (C₁₄H₁₈N₂O₅) powder was purchased from Hugestone Enterprise Co., Ltd., China.

Collection of the blood

After the experimental period 30 days blood samples were drawn and collected from the optical vein, and left to clot, then centrifuged for a duration 15 minutes, the serum was isolated and saved in -18°C in order to estimate the biochemical parameters (15).

Biochemical examination

Vitamin D specific for rats and Insulin Like Growth Factor -1 specific for rats were estimated in serum by using ELISA kits (Elabscience-company) (16). Biomerieux kit method of Belfeld and Goldbery was used to determine alkaline phosphatase activity in serum (17). Serum calcium, inorganic phosphate and albumin were estimated by spectrophotometer kits using Biolabo, France (18-20).

Histopathological of bone

Rats were killed and left femurs were excised and cleaned, and fixed in 10 % formaldehyde in the phosphate-buffered solution, followed by decalcification by formic acid-sodium citrate solution, then dehydrated by the alcohol and cleared by the xylol after that embedded in the paraffin and sectioned into 5 µm by using a rotatory microtome. The slides were stained using hematoxylin and eosin (21).

Statistical analysis

The one-way analysis of variance (ANOVA) test was used to analyze all data, which were expressed as means standard deviation (SD), using SPSS selector test used for detecting the statistical significance between all groups at P≤0.05 probability (22).

Results

The results indicated that there was a significant elevation P≤0.05 in vitamin D and IGF-1 levels in the all groups that gave 0.4 g/kg, 0.8 g/kg and 1.2 g/kg in comparison to control group. However, serum vitamin D and IGF-1 levels between the group that treated 0.8 g/kg and the group that treated 1.2 g/kg did not differ significantly as shown in table 1.

Table 1: Aspartame effects in serum vitamin D and IGF-1

Groups	Vitamin D (pg/ml)	IGF-1 (pg/ml)
G1	133.90±21.2 ^d	98.87±15.54 ^d
G2	136.67±7.54 ^c	104.15±24.36 ^c
G3	197.621±21.96 ^a	124.02±36.47 ^{ab}
G4	197.84±24.39 ^{ab}	124.51±8.56 ^a

The values expressed as mean± SD for 6 animals/group. Letters that different in the vertically mean a significant variance P≤0.05.

Also, a significant elevation P≤0.05 in ALP activity was noticed in treated groups when comparison to control group, so this elevation was proportional to the rise in the doses. In addition, serum calcium showed a significantly P≤0.05 decrease in the groups that treated with 0.4 g/kg and 0.8 g/kg respectively, and a significant P≤0.05 increase in the group that was treated with 1.2 g/kg when compared to the control groups. However, serum inorganic phosphate was not changed significantly in all groups in comparison to control group. Serum albumin significantly elevated P≤0.05 in treated groups in comparison to control group (Table 2).

In the histopathological examination, the bone sections of control group revealed, normal thickness of trabecular bone, normal osteogenic tissue, and regular vacuole between bony tissue and osteogenic tissue as shown in figure 1. Treated rats with 0.4 g/kg of aspartame showed little thickness of trabecular bone and osteogenic tissue, regular vacuole between bony and osteogenic tissue as shown figure 2. The group 3 that treated with 0.8 g/kg aspartame showed a slight thin trabecular bone and poor developed osteogenic tissue, as well as a wide vacuole between bony and osteogenic tissue as shown in figure 3. The left femur of rats that treated by 1.2 g/kg of aspartame showed the negative effects that seen through the very little thickness of trabecular bone (TB), low quantity of osteogenic tissue, wide vacuole between bony tissue and osteogenic tissue, and reducing osteoblasts as shown in figure 4.

Table 2: Aspartame Effects in serum ALP activity, calcium, inorganic phosphate and albumin

Groups	ALP (U/L)	Ca (mg/dl)	Pi (mg/dl)	Albumin (g/dl)
G1	100±12.85 ^d	10.85±1.25 ^b	5.56±0.28 ^a	4.86±0.61 ^d
G2	128.36±9.29 ^c	7.64±0.34 ^d	5.95±0.58 ^a	7.76±0.99 ^{ac}
G3	131.30±16.68 ^b	9.76±0.63 ^c	5.48±0.37 ^a	8.17±0.81 ^{ab}
G4	136.08±14.60 ^a	11.10±0.28 ^a	5.31±0.50 ^a	8.33±0.73 ^a

The values expressed as mean± SD for 6 animals/group. Letters that different in the vertically mean a significant variance $P \leq 0.05$.

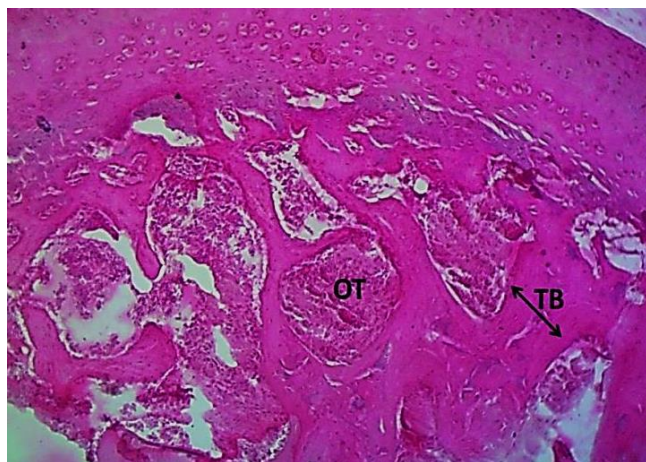

Figure 1: The photomicrograph for the left femur of the control group reveals the trabecular bone TB thickness, and the osteogenic tissue OT, regular vacuole between bony tissue and osteogenic tissue. H&E stain, 100X.

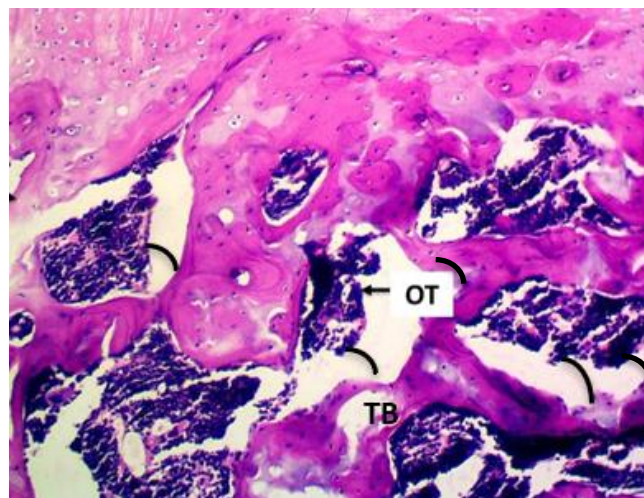


Figure 3: The photomicrograph in the left femur of the group 2 (treated with aspartame 0.8 g/kg) reveals the little thickness of trabecular bone TB and low quantity of osteogenic tissue OT, wide vacuole between bony tissue and osteogenic tissue. H&E stain, 100X.

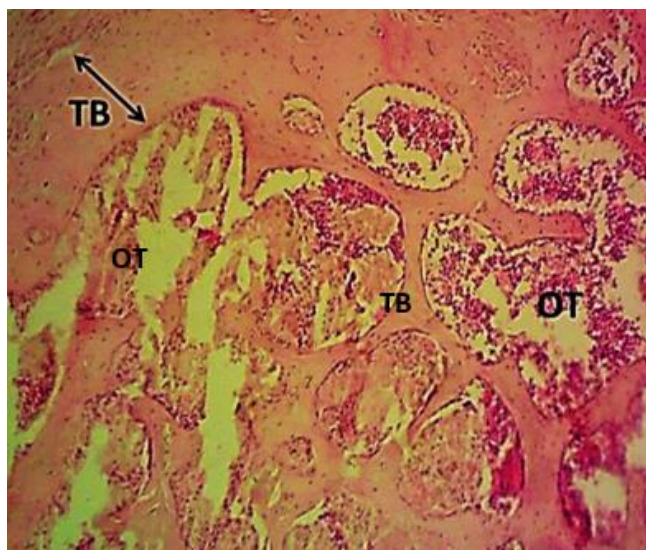


Figure 2: The photomicrograph in the left femur of the group 1 (treated with aspartame 0.4 g/kg) reveals the little thickness in trabecular bone TB and osteogenic tissue OT, regular vacuole between bony tissue and osteogenic tissue. H&E stain, 100X.

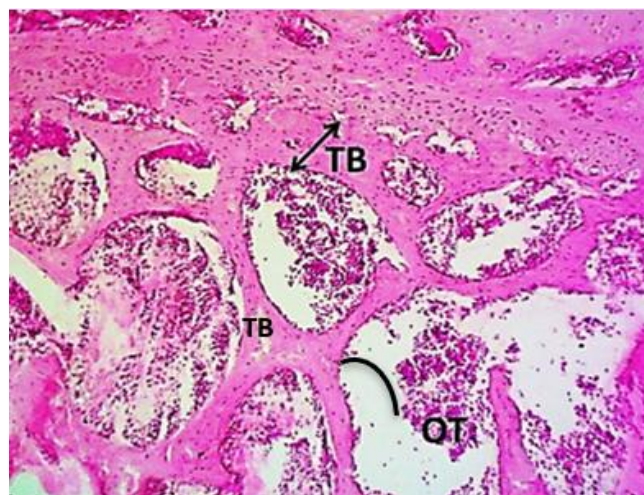


Figure 4: The photomicrograph in the left femur of the group 3 (treated with aspartame 1.2 g/kg) reveals the very little thickness of trabecular bone TB and low quantity of osteogenic tissue OT, wide vacuole between bony tissue and osteogenic tissue. H&E stain, 100X.

Discussion

Administration of aspartame to the young rats caused an elevation in vitamin D levels, and this elevation was proportional to the dose of aspartame that was used in this work. That excess doses from vitamin D in serum may affect bone tissues, and this was confirmed in the histological changes that were seen when the rats were treated with 1.2 g/kg, as shown in fig. 4, which showed the negative effects by reducing bone density and very little thickness of trabecular bone. Our results about the negative effect of high levels of vitamin D in bone tissues agree with results from Laure *et al.*, that high doses of vitamin D are related to bone loss since high doses of vitamin D may inhibit PTH hormone through its action on the parathyroid gland or through its enhancement of calcium absorption from the intestine, affecting bone formation and the activity of osteoclast cells (23). Also, the administration of aspartame caused a significant elevation in serum IGF-1. This increase in IGF-1 may result from the increase of the metabolites of aspartame after its ingestion. It is converted to aspartic acid, phenylalanine, and methanol which agreement with study by Sun *et al.*, that documented an increase in IGF-1 levels in aspartame intake group (24). The increase in aspartic acid and phenylalanine levels, which are essential amino acids for protein and peptide synthesis, is also important for binding proteins that correlate with IGF levels (25). The activity of ALP was elevated when the dose of aspartame increased, which agrees with (26). This elevation in alkaline phosphatase may be related to bone turnover and increased bone resorption (27,28). Alkaline phosphatase used as an indicator of the osteoblast activity; it is a useful to monitor formation of bone (29,30). Alkaline phosphatase is considered a good biomarker for bone formation, and it elevated in several metabolic disorders and in osteoporosis (31). Alkaline phosphatase plays a great role in the hard tissue, also it reduces the pyrophosphate level in the extracellular. It also has an effect on the calcification of bone metabolism (32,33). The elevation in alkaline phosphatase activity in this study also agreement with findings of Sary *et al.*, since they reported that aspartame led to increases in ALT, AST and ALP activities (34). These findings were supported by the histological findings, which seen reduced bone density and very little thickness of trabecular bone. Serum calcium was reduced after being given 0.4 g/kg of aspartame; this may refer to the negative effect of aspartame. However, serum calcium was elevated when the dose of aspartame was increased by 0.8 g/kg and also by 1.2 g/kg. This elevation may be attributed to the high levels of vitamin D, because vitamin D enhances calcium absorption in the intestine (35). High level of vitamin D in serum causes a high concentration of calcium in the blood, and this case leads to soft tissue calcification (36,37). Calcium is a major element and has biological functions in the body that are regulated in serum through the resorption and excretion through the

kidney and the absorption via the intestine along with the exchanges with the bony tissue, which is regarded as a reservoir for calcium and phosphate (38,39). On the other hand, the high level of calcium after 0.8 g/kg also with 1.2 g/kg aspartame administration may be due to the stimulation of the PTH by low calcium level, so this causes calcium release from the bone in order to normalize calcium concentration (40). This study showed that oral administration of aspartame caused an increase of albumin concentration this elevation was proportional to the increasing aspartame dose. These results are consistent with the findings of Sary *et al.* since they noticed a very significant elevation in serum albumin and total protein in both female and male rats after treatment with aspartame. This may refer to the negative effect of aspartame (34). The elevation in serum albumin may also be attributed to the level of aspartic acid and phenylalanine that were produced from aspartame hydrolysis. Both amino acids are occurred in the proteins (41).

Conclusions

The current study concluded, that aspartame taken at high doses causes harmful effects on bone formation, while low doses have moderate effects.

Acknowledgments

The authors express their gratitude to the veterinary medicine college at Mosul University for their excellent support and assistance, with a special thanks to assistant professor Nadhim Ahmed Hassan for all facilities.

Conflict of interests

No conflict

References

1. Khidr B, El-Sokkary G, Saleh S. Study on morphological changes induced by aspartame on liver of normal and diabetic male albino rat. *J Histol Histopathol.* 2017;4(1):1-7. DOI: [10.7243/2055-091X-4-1](https://doi.org/10.7243/2055-091X-4-1)
2. Karim M, Fatame R. A theoretical and experimental study of calcium, iron, zinc, cadmium, and sodium ions absorption by aspartame. *J Biol Phys.* 2017;43:87-103. DOI: [10.1007/s10867-016-9435-2](https://doi.org/10.1007/s10867-016-9435-2)
3. Fitch C, Keim K. Position of the academy of nutrition and dietetics: Use of nutritive and nonnutritive sweeteners. *J Acad Nutr Diet.* 2012;112(8):1279. DOI: [10.1016/j.jand.2012.03.009](https://doi.org/10.1016/j.jand.2012.03.009)
4. Huff J, Ladou J. Aspartame bioassay findings portend human cancer hazards. *Int J Occup Med Env.* 2007;13(4):446-8. DOI: [10.1179/oeh.2007.13.4.446](https://doi.org/10.1179/oeh.2007.13.4.446)
5. Zafar T, Naik Q, Shrivastava V. Aspartame: Effects and awareness. *MOJ Toxicol.* 2017;3(2):23-26. DOI: [10.15406/mojt.2017.03.00046](https://doi.org/10.15406/mojt.2017.03.00046)
6. Humphries P, Pretorius E, Naudé H. Direct and indirect cellular effects of aspartame on the brain. *Eur J Clin Nutr.* 2008;62:451-462. DOI: [10.1038/sj.ejcn.1602866](https://doi.org/10.1038/sj.ejcn.1602866)
7. Zhai R, Zheng N, Rizak J, Hu X. Evidence for Conversion of methanol to formaldehyde in nonhuman primate brain. *Anal Cell Pathol.* 2016;1-5. DOI: [10.1155/2016/4598454](https://doi.org/10.1155/2016/4598454)

8. Pohanka M. Toxicology and the biological role of methanol and ethanol. Biomed Pap Med Fac Univ Palacky Olomouc Czech Repub. 2016;160(1):54-63. DOI: [10.5507/bp.2015.023](https://doi.org/10.5507/bp.2015.023)
9. Rycerz K, Jaworska J. Effects of aspartame metabolites on astrocytes and neurons. Folia Neuropathol. 2013;51(1):10-17. DOI: [10.5114/fn.2013.34191](https://doi.org/10.5114/fn.2013.34191)
10. Schubert C. Aspartame linked to increased cancer risk in rats. Nature. 2005. DOI: [10.1038/news051114-15](https://doi.org/10.1038/news051114-15)
11. Landrigan P, Straif K. Aspartame and cancer—new evidence for causation. Int J Hyg Environ Health. 2021;20(42):1-5. DOI: [10.1186/s12940-021-00725-y](https://doi.org/10.1186/s12940-021-00725-y)
12. Al-Mahmood SS, Al-Qadhi AS, Al-Ajeli RR, Al-Kattan L. Mixed thymic tumor in a rooster: Gross and histological features. Iraqi J Vet Sci. 2019;33(2):201-204. DOI: [10.33899/ijvs.2019.125536.1058](https://doi.org/10.33899/ijvs.2019.125536.1058)
13. Santos N, de Araujo L, Canto D, Silva Guerra E, Coelho M, Borin HO. Metabolic effects of aspartame in adulthood: A systematic review and meta-analysis of randomized clinical trials. Crit Rev Food Sci Nutr. 2018;58(12):2068-2081. DOI: [10.1080/10408398.2017.1304358](https://doi.org/10.1080/10408398.2017.1304358)
14. Mustafa HH, Ali AK, Cheng C, Radzi R, Fong L, Mustapha N, Dyary HO. Development of experimentally-induced periodontitis in a Sprague Dawley rat model. Iraqi J Vet Sci. 2021;35(4):765-769. DOI: [10.33899/ijvs.2021.128422.1573](https://doi.org/10.33899/ijvs.2021.128422.1573)
15. Chawla R. Practical clinical biochemistry: Methods and interpretations. 4th ed. India: Jaypee Brothers Medical Pub; 2014. 318 p.
16. Oster M, Fielder P, Levin N, Cronin J. Adaptation of the growth hormone and insulin-like growth factor-I axis to chronic and severe calorie or protein malnutrition. J Clin Invest. 1995;95(5):2258-2265. DOI: [10.1172/JCII17916](https://doi.org/10.1172/JCII17916)
17. Belfield A, Goldberg D. Revised assay for serum phenyl phosphatase activity using 4 amino-antipyrine. Enzyme. 1971;12(5):561-73. DOI: [10.1159/000459586](https://doi.org/10.1159/000459586)
18. Tietz N. Text book of clinical chemistry. 3rd ed. Philadelphia: W.B. Saunders; 1999. 1395-1406,1435-1439 pp.
19. Daly J, Ertingshausen G. Direct method for inorganic phosphate determination. Clin Chem. 1972;18:263-265. DOI: [10.1093/clinchem/18.3.263](https://doi.org/10.1093/clinchem/18.3.263)
20. Doumas B, Watson W, Biggs H. Albumin standards and the measurement of serum albumin with bromocresol green. Clin Chim Acta. 1971;31:87-96. DOI: [10.1016/0009-8981\(71\)90365-2](https://doi.org/10.1016/0009-8981(71)90365-2)
21. Al-Ameen SA, Jirjees EH, Tawfeeq FK. Effect of sodium benzoate on some biochemical, physiological and histopathological aspects in adult male rats. Iraqi J Vet Sci. 2022;36(2):267-272. DOI: [10.33899/ijvs.2021.129935.1705](https://doi.org/10.33899/ijvs.2021.129935.1705)
22. Umakantha N. A new approach to probability theory with reference to statistics and statistical physics. J Mod Phys. 2016;7:989-1003. DOI: [10.4236/jmp.2016.79090](https://doi.org/10.4236/jmp.2016.79090)
23. Lauren A, Emma O, Marianne S, Duncan A, David A, Steven K. Effect of high-dose vitamin D supplementation on volumetric bone density and bone strength: A randomized clinical trial. J Am Med Assoc. 2019;322(8):736-745. DOI: [10.1001/jama.2019.11889](https://doi.org/10.1001/jama.2019.11889)
24. Sun D, Liu L, Mao S, Zhu W, Liu J. Aspartame supplementation in starter accelerates small intestinal epithelial cell cycle and stimulates secretion of glucagon-like peptide-2 in pre-weaned lambs. J Anim Physiol Anim Nutr. 2019;00:1-13. DOI: [10.1111/jpn.13159](https://doi.org/10.1111/jpn.13159)
25. Flynn N, Shaw M, Becker J. Amino acids in health and endocrine function. Adv Exp Med Biol. 2020;1265:97-109. DOI: [10.1007/978-3-030-45328-2_6](https://doi.org/10.1007/978-3-030-45328-2_6)
26. Abhilash M, Sauganth PM, Varghese M, Harikumaran N. Effect of long term intake of aspartame on antioxidant defense status in liver. Food Chem Toxicol. 2011;49(6):1203-7. DOI: [10.1016/j.fct.2011.02.019](https://doi.org/10.1016/j.fct.2011.02.019)
27. Delmas P. Biochemical markers of bone turnover. J Bone Miner Res. 1993;8(2):549-555. DOI: [10.1002/jbmr.5650081323](https://doi.org/10.1002/jbmr.5650081323)
28. Bhattarai T, Bhattacharya K, Chaudhuri P. Correlation of common biochemical markers for bone turnover, serum calcium, and alkaline phosphatase in post-menopausal women. Malays J Med Sci. 2014;21(1):58-61. [\[available at\]](#)
29. Yilmaz B, Seyran A, Aandal S, Aydin M, Colakoglu N, Carpenter D. Modulatory effects of aroclors 1221 and 1254 on bone turnover and vertebral histology in intact and ovariectomized rats. Toxicol Lett. 2006;166:276-284. DOI: [10.1016/j.toxlet.2006.08.003](https://doi.org/10.1016/j.toxlet.2006.08.003)
30. Shetty S, Kapoor N, Dian Bondu J, Thomas N, Vizhalil T. Bone turnover markers: Emerging tool in the management of osteoporosis. Indian J Endocrinol Metab. 2016;20:846-852. DOI: [10.4103/2230-8210.192914](https://doi.org/10.4103/2230-8210.192914)
31. Romero B, Manrique A, Rodríguez M. Biochemical markers in osteoporosis: Usefulness in clinical practice. Reumatol Clin. 2012;8(3):149-152. DOI: [10.1016/j.reuma.2011.05.010](https://doi.org/10.1016/j.reuma.2011.05.010)
32. Vimalraj S. Alkaline phosphatase: Structure, expression and its function in bone mineralization. Gene. 2020;754:144855. DOI: [10.1016/j.gene.2020.144855](https://doi.org/10.1016/j.gene.2020.144855)
33. Ansari S, Ito K, Hofmann S. Alkaline Phosphatase activity of serum affects osteogenic differentiation cultures. ACS Omega. 2022;7(15):12724-12733. DOI: [10.1021/acsomega.1c07225](https://doi.org/10.1021/acsomega.1c07225)
34. Sary Kh, Mohamed A, Mohamed F, Wala M. Protective effects of some antioxidants against long-term intake of aspartame toxicity on liver and kidney: Biochemical and histopathological approach in rats. J Basic Appl Zool. 2021;82:50. DOI: [10.1186/s41936-021-00244-9](https://doi.org/10.1186/s41936-021-00244-9)
35. Conti G, Chirico V, Lacquaniti A, Silipigni L, Fede C, Vitale A, Fed C. Vitamin D intoxication in two brothers: Be careful with dietary supplements. J Pediatr Endocrinol Metab. 2014;27(7-8):763-7. DOI: [10.1515/jpem-2013-0220](https://doi.org/10.1515/jpem-2013-0220)
36. Morrow C. Cholecalciferol poisoning. J Vet Med. 2001;96(12):905-911. [\[available at\]](#)
37. Peterson M, Fluegeman K. Cholecalciferol. Top Companion Anim Med. 2013;28(1):24-27. DOI: [10.1053/j.tcam.2013.03.006](https://doi.org/10.1053/j.tcam.2013.03.006)
38. Salih S, Al-Khashab E. Effect of atorvastatin on bone formation in ovariectomized rats. Iraqi J Vet Sci. 2023;37(1):239-244. DOI: [10.33899/ijvs.2022.133734.2287](https://doi.org/10.33899/ijvs.2022.133734.2287)
39. Salih S, Al-Khashab E. Role of rosuvastatin in bone metabolism of ovariectomized adult rats. Iraqi J Vet Sci. 2023;37(1):267-273. DOI: [10.33899/ijvs.2022.133840.2309](https://doi.org/10.33899/ijvs.2022.133840.2309)
40. Nagareddy PR, Lakshmana M. *Withania somnifera* improves bone calcification in calcium-deficient ovariectomized rats. J Pharm Pharmacol. 2006;4:513-519. DOI: [10.1211/jpp.58.4.0011](https://doi.org/10.1211/jpp.58.4.0011)
41. Woodrow C. Monte and methanol. J Appl Nutr. 1984;36(1):1-15. DOI: [10.1017/S1743921308021327](https://doi.org/10.1017/S1743921308021327)

تأثير الاسبارتام في بناء العظم لإنات الجرذان الصغيرة

الهام محمد الخشاب، هديل محمد الهاشمي و احمد علي حسين

فرع الفسلجة والكيمياء الحياتية والأدوية، كلية الطب البيطري، جامعة الموصل، الموصل، العراق

الخلاصة

الأسبارتام هو مُحلي صناعي شهير يحتوي على عدد قليل من السرعات الحرارية ويستخدم على نطاق واسع، ويستخدم في أكثر من 90 دولة حول العالم. هدفت الدراسة الحالية إلى تقييم تأثير الجرعات المختلفة من الأسبارتام 0، 4، 8، 16 و 32 جم / كغم على بناء عظام إنات الجرذان الصغيرة. تم استخدام 24 من إنات الجرذان تراوحت أعمارهن 1، 5 شهرا وتزن 90-100 غرام كانت بمجاميع على النحو التالي: المجموعة السيطرة، المجموعة المعاملة بجرعة 4، 8، 16 جم/كغم، المجموعة المعاملة بجرعة 8، 16 جم / كغم والمجموعة المعاملة بجرعة 16، 32 جم / كغم. في نهاية فترة التجربة بعد 30 يوم تم سحب الدم وفصل المصل لتقدير المتغيرات الكيمحيوية والتي شملت فيتامين د الخاص بالجرذان وعامل النمو الشبيه بالأنسولين-1 الخاص بالجرذان وأنزيم الفوسفات القاعدي والكالسيوم والفوسفات الغير العضوي والألبومين. لفحص نسيج

ارتفاع معنوي بعد المعاملة بجرعة ١,٢ غم / كغم من الأسبارتام. أظهرت الجرعات العالية من الأسبارتام عند جرعة ١,٢ غم / كغم تغيرات نسيجية مرضية في مقاطع العظام. نستنتج من الدراسة الحالية إلى أن الجرعات الزائدة من الأسبارتام لها تأثير سلبي على بناء العظام وتركيبها في الجرذان النامية.

العظام تم أخذ عظم الفخذ الأيسر من الجرذان بعد قتل الحيوانات. أظهرت النتائج ارتفاعا معنويا في فيتامين د، عامل النمو الشبيه بالأنسولين -١، أنزيم الفوسفات القاعدي والألبومين في الدم في جميع المجموعات المعاملة مقارنة بمجموعة السيطرة. ومع ذلك، أظهر الكالسيوم في مصّل الدم انخفاضا كبيرا بعد معاملته بجرعة ٠,٤ و ٠,٨ غم/كغم، ولكن لوحظ