

## **Histochemical Effect of Capsaicin Alone or in Combination with The Metformin on Ovaries Structure After Induced a Polycystic Ovary Syndrome by Letrozole in Rats**

Alia Mohammed Khudier<sup>1</sup>, Karim H. Al-derawi<sup>2</sup>, Labeed A. Al- saad<sup>3</sup>

1-Department of Anatomy and Histology, College of Veterinary Medicine, University of Basrah.

2-Department of Biology, College of Science, University of Basrah.

3-Department of Intelligent Medical System, Collage of Computer Sciences and Information Technology, University of Basrah.

**Corresponding Author Email Address:** [alia.khudier@uobasrah.edu.iq](mailto:alia.khudier@uobasrah.edu.iq)

**ORCID ID:** <https://orcid.org/0000-0002-0096-8244>

**DOI:** [10.23975/bjvr.2024.182902](https://doi.org/10.23975/bjvr.2024.182902)

**Received:** 21 December 2023 **Accepted:** 19 February 2024.

### **Abstract**

The current study, we investigated the effect of capsaicin alone or combined with metformin on induced polycystic ovary syndrome in rat adult females. The total number of animals was used (70). The study was divided into two experiments: The first experiment was to induce polycystic ovary syndrome in (50) animals were divided as follows: GI (n= 10) (CMC) served as a control group. The reminder (n = 40) GII were given Letrozole 1 mg/kg. The duration of this experiment continued (21 day). At the end of experiment, (n=10) females that received letrozole were scarified and considered as (PCOS subgroup). The GI (n=10) CMC were also scarified to ensured PCOS accrued. For histochemical analysis, the ovaries of female rats were isolated and fixed in a formalin solution 10%. In a second experiment, the reminder of female rats from first experiments GII (PCOS group n=30) divided into three subgroups (10 animals/subgroup: (Capsaicin + letrozole) subgroup, was given 0.5 mg/kg of capsaicin, (metformin) subgroup was given metformin 9 mg/kg and (metformin + capsaicin + letrozole) subgroup. The remainder of the total number of animals studied (n = 20) (PCOS not induced) were divided into (10 animals/subgroup) (alcohol subgroup) as control group that was given 0.5 ml from alcohol and (capsaicin) without induction of polycystic ovary syndrome as a positive control subgroup, was given capsaicin (0.5 mg/kg). The second experiment continued for 21-days after the end of the experiment. All animals were sacrificed and the ovaries were removed, fixed (10% buffered formalin), and prepared for histochemical study using Mallory's trichrome stain. The study, we recorded multiple cysts, bleeding and mucin in the PCOS subgroup compared with the CMC group. Histochemical examinations of the treated subgroups with capsaicin alone or with metformin showed an improvement in ovarian tissue, disappearance of cysts and bleeding compared with the control groups and the PCOS subgroup. We thought that capsaicin alone or in combination with metformin showed an improvement in ovarian tissue.

**Key words:** Polycystic ovary syndrome, Capsaicin, Metformin.

## Introduction

The polycystic ovary syndrome is generally of interest to researchers even though it was discovered in 1935 (1). A diagnosis of polycystic ovary syndrome (PCOS) requires two to three criteria: Excess androgen, dysfunctional ovulation, and morphological changes, in contrast, thyroid disease and hyperprolactinemia are common disorders in women (2). Furthermore, Barber and Franks (3) found a connection between PCOS and obesity. In recent years, researchers have also been interested in capsaicin for its ability to control body weight by inhabiting adiposeness (4, 5). As biomedical research is increasingly focused on natural products (6,7), this is one of the important reasons why it is recommended to use capsaicin (the important natural compound derived from several fruits of the capsicum plant such as hot peppers) for the treatment of POCS (8). The impact of capsaicin on physiological and biochemical processes has been investigated interestingly in humans, animals, and plants (9, 10), also on the ovarian health (11). However, there are no available studies involving the capsaicin effect on POCS. According to that, the current study focused on investigation of the ability of capsaicin on development and management the PCOS with and without support of metformin by comparing histological and histochemical effects in female rats.

## Materials And Methods

### Experimental design

**Material:** The capsaicin (sigma Aldrich, German) was prepared for oral administration by dissolving (0.5 mg/kg of capsaicin was dissolved in 0.5 ml of absolute ethanol. The mixture was completed to 100 ml by distilled water). The letrozole was administrated orally (1 mg/kg) using aqueous solution (1%) of carboxy methyl cellulose (Sunlong\ China) as a vehicle solution (12).

**Animals:** A total of 70 adult Norwegian female rats fourth day in of regular vaginal cycle were considered as an experimental unit. The animals weight ranged between 150-200 gm, which was provided by the animal house of Veterinary Medicine college of Basrah University. The animals were hosted in a plastic cage, lined with a standard environmental condition that include (Temperature:  $25 \pm 2^{\circ}\text{C}$ , humidity: about  $55 \pm 10\%$ ) and constant light/dark cycle. The rats were fed with standard pellet (the contents of the pellet) diet and water ad libium. This study was approved by College of Science in Basrah University. The study included two stages:

### First Stage: Induction of PCOS.

Fifty female rats were divided into two general groups: CMC group GI (n=10) was received (carboxy methyl cellulose CMC 1mg/kg dissolved in distilled water) once daily for 21 day only as a control group. PCOS GII (n=40) female rats was induced PCOS by gavage letrozole (1 mg/kg dissolved in 1% CMC) for 21 regular days. At the end of the last week of administration experiment, the PCOS group (n=10) and the CMC group (n=10) were sacrificed to

examine the histochemical examination of ovary after (PCOS) induction.

### **Second Stage: Treatment**

After ensuring induction of PCOS, the rest of the animals of PCOS GII (n=30) also divided into three subgroups (0.5 mg/kg capsaicin + letrozole), (9 mg/kg metformin) subgroup, and (metformin + capsaicin + letrozole) subgroup. The remaining twenty animals that were not induced for PCOS were divided into two subgroups (10 animals/subgroup), which were 0.5 ml alcohol subgroup as a control group, and 0.5 mg/kg capsaicin as a positive control subgroup. The experiment lasted for 21 days.

### **Determination of Estrus cycle**

To determine the estrus cycle (EC) and to assess the (EC) regularity daily, vaginal smear examination was performed for each female. Briefly, vaginal secretion was collected by pushing normal saline into vagina by sterile eye drop (2-3 drops), pulling the secretion in the same time, the pulled drop in clean glass slide. One drop of Giemsa stain was then added and covered by a cover slip (Jourilabs, Ethiopia). The slides were then examined using light microscope under 40x magnification power. The microscopic test of the smear was performed to examine the predominate nucleated epithelial cell (pro-estrus phase), cornified epithelial cells predominant (estrus phase), both cornified squamous epithelial cells and

leukocytes referred to metestrus phase and predominate leukocytes indicated the diestrus phase (13).

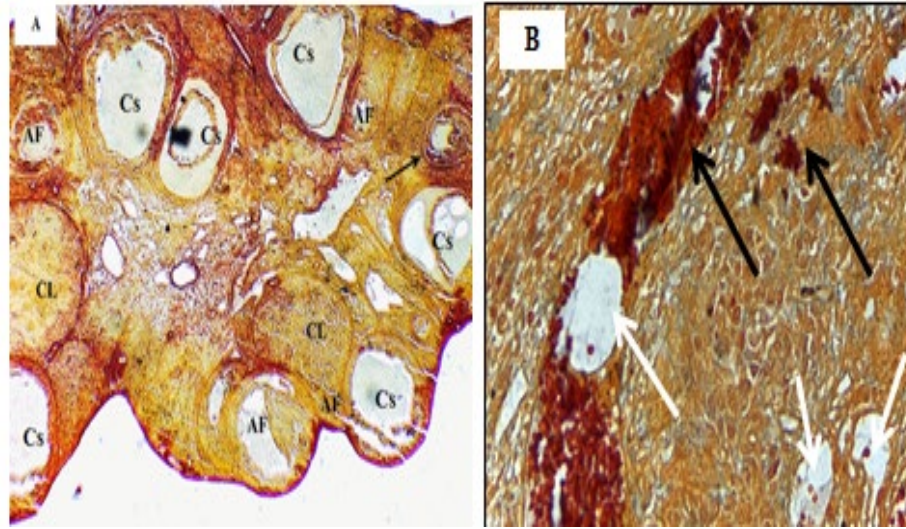
### **Histochemical Examinations**

After the treatment trials ended, all animals were sacrificed for histochemical study. The ovaries were isolated, fixed in buffered formalin (10%), dehydrated in an ascending series of ethanol 50%, 70%, 80%, 90%, 100% and once again 100%, cleared in xylene, embedded in paraffin sectioned (thickness= 5µm), mounted on slides, and stained with Mallory's stain for histochemical study.

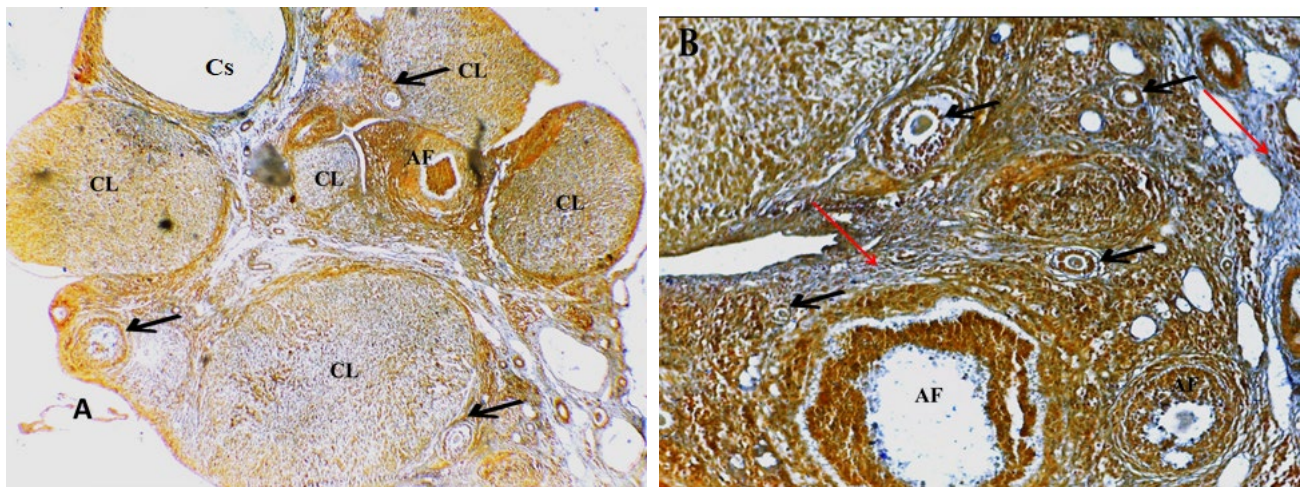
### **Result**

#### **Microscopic Examination**

**Histochemical Examination of Polycystic Ovary Syndrome group:** Microscopic examination showed that the ovaries with PCOS group had multiple cysts surrounded by multiple fibers. The corpora luteal and corpora albuginea was absent or observed in few numbers. In addition, the tertiary follicle appeared only once with damaged antrum. Ovaries had distinct region of bleeding. The collecting of fat cells was observed with a few atretic follicles (Figs. 1) compared with CMC group, which had normal ovarian histochemical structure (Fig. 2)



**Figs. (1)** ovarian structure of polycystic ovary syndrome group with Mallory's stain under light microscope showing (A:4x) multiple cysts (Cs), atretic follicles (Af) and the black arrow indicted to tertiary follicle. (B: 10x) congested (black arrows) and collecting of fat cells (white arrows)



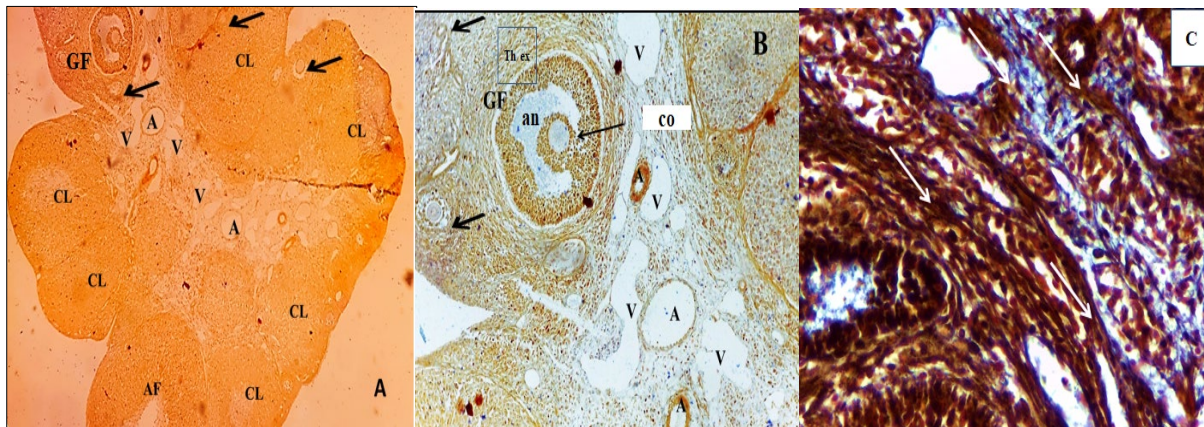
**Figs. (2):** CMC control group with Mallory's trichrome staining examined under light microscope showing (A: 4x) normal ovarian structure with multiple corpora lutea (CL), (black arrows) referred to numerus ovarian development stages and appearance of atretic follicle (AF). (B: 10x) showing multiple ovarian development stages indicated by black arrows, atretic follicle (AF) and collagen fibers (red arrows).

### Histochemical Examination of Capsaicin administration treated group

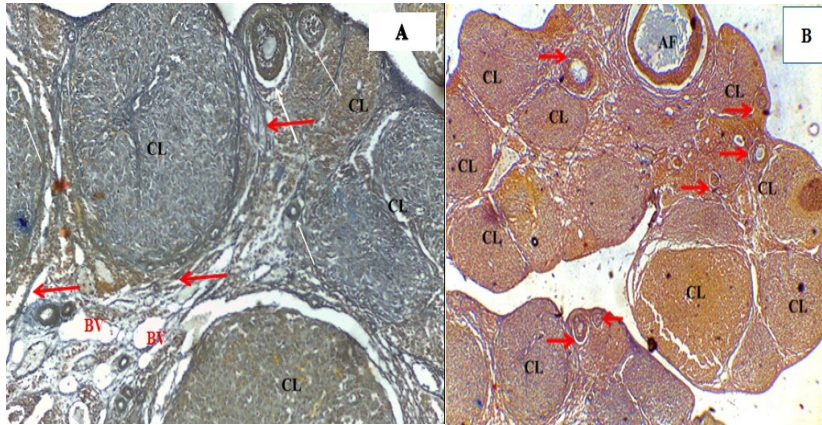
The ovarian histochemical investigation of capsaicin treated after induction of PCOS by Letrozole recorded improvement of ovarian histological changed. The cysts disappeared; the hemorrhage was notably disappeared. Obviously, we recorded numerous types of follicles in the cortical region, and multiple corpora lutea. In medulla, the dilation of blood vessels was observed. The reticular and collagen fibers were also appeared clearly (Figs. 3) compared with other administration control groups (capsaicin as a positive control group and alcohol administration control group) (Figs 4), other treated group in addition to PCOS group (Figs 1).

### Histochemical examination of ovarian structure with metformin alone or in combination with the capsaicin administration subgroups.

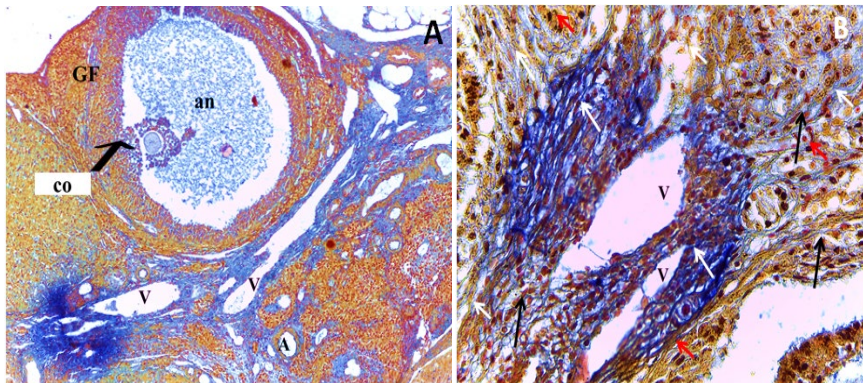
Histochemical examination of ovarian Mallory's-stained sections of groups treated with metformin alone or in combination with capsaicin showed an improvement of PCOS. The metformin treated group revealed a decrease in cysts and development of ovarian stages. However, it was notable that a few of erythrocytes were randomly distributed, abundant of collagen and reticular fibers surrounded the blood vessels and between granulosa cells, in addition to multiple fibroblast cells compared with the control and other treated subgroups (Fig. 5). The combination of metformin with capsaicin showed enhancement of PCOS, which presented a decrease in red blood cells and cysts with a development of ovarian stages in contrast with other treated subgroups, PCOS group and control subgroups (Fig. 6).



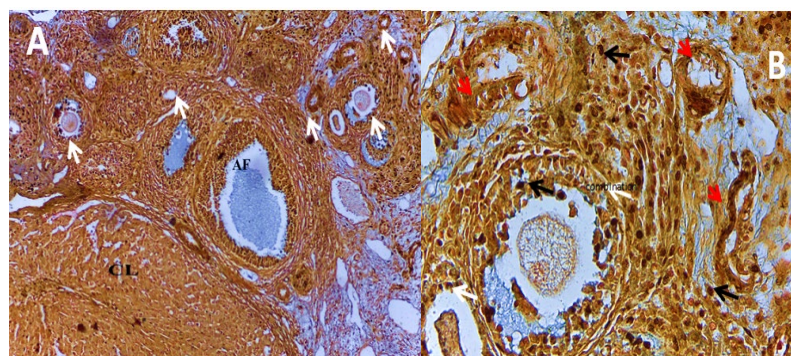
**Figs. (3):** Ovarian structure with Mallory's Trichrome stain of capsaicin administration treated subgroup under light microscope showing (A: 4x) decrease in cysts and increase of corpora lutea (CL), numerous ovarian development stages (black arrows) (B: 10x) Growth of follicle (GF) consisted of antrum (an), cumulus oophorus (co) and theca (Th ex). (C: 40x) a net of collagen fibers (white arrows).



**Fig. (4): (A: 4x):** Mallory's-stained ovaries of alcohol administration as control subgroup showing normal ovarian structure with a dense layer of fibers surrounded by the corpora lutea (CL) and blood vessels (BS) in medulla pointed by red arrows. **(B: 4x)** Capsaicin as positive control subgroup showing multiple corpora luteal (CL) and numerous ovarian follicles assigned by red arrows.



**Figs. (5):** Histochemical examination of metformin a lone treatment **(A: 10x):** A notable disappearance of cysts, development ovarian stages, and growth follicle (GF). **(B: 40x):** Abundance of collagen fibers and reticular fibers (white arrow), few of red blood cells (red arrows), and multiple of fibroblast cells (white arrows).



**Figs. (6) Mallory's-stained Capsaicin+metformin treatment (A: 10x): Development of ovarian structure (white arrows) and atretic follicle (AF) filled with fluid. (B:40x): A few of fibroblast cells (black arrows) and a huge of blood vessels red arrows surround by dense of collagen fibers and the growth of follicle was clearly appeared.**

## Discussion

Polycystic ovary syndrome is a companion of many endocrine factors and morphological signs changes during women health life (14).

The study, focused on the most important histochemical changes of ovarian structure after induction of the PCOS by Letrozole. In addition, recorded the most important histochemical changes of ovarian structure after treatment of capsaicin alone or in combination with metformin. The induction of the PCOS by letrozole was significantly caused appearance of multiple cysts in cortical region with a decrease in corpora luteal. Letrozole play an important role in the control of some reproductive hormone levels especially estrogen, testosterone and LH hormones, any changes in the level of these

hormones in female lead to an abnormal change of histological ovarian structure (15).

Capsaicin as a natural compound has wide medical aspects (16). The low dose of capsaicin administration after induction the PCOS improved the ovarian histochemical structure especially increasing the collagen fibers it has been found that the increase of numerous types of collagens provides support and improvement of ovulation (17).

Using of low dose of capsaicin enhances the ovarian structure and ovulation (18). A number of studies reported that the importance of metformin on PCOS management (19-22). We noted a huge distribution of blood vessels in medulla which were surrounded by a dense collagen fiber. This finding agreed with

previous study (23), which revealed that the increase of blood vessels enhances ovarian development stages and ovulation. Capsaicin in combination with metformin gave a best ovarian stages development and improved the PCOS.

According to previous study (24), capsaicin is a strong antioxidant scavenged the free radical. Finally, the histochemical results obtained in the present study suggest that the capsaicin alone or in combination with metformin can regulate the development of ovarian stages and improved the PCOS. This finding was supported by similar study suggesting that ovarian hormones were regulated by sensory ovarian innervation (25). According to previous study (26), capsaicin produced the eNOS that plays an important role in repairing damaged tissue.

**conclusion:** The capsaicin alone or in combination with metformin revealed an improvement in ovarian tissue.

## References

- 1-Stein, I.F. and Leventhal, M.L. (1935) Amenorrhea Associated with Bilateral Polycystic Ovaries. *American Journal of Obstetrics and Gynecology*; (29): 181-185. [https://doi.org/10.1016/S0002-9378\(15\)30642-6](https://doi.org/10.1016/S0002-9378(15)30642-6)
- 2-Legro, R. S.; Arslanian, S. A.; Ehrmann, D. A.; Hoeger, K. M.; Murad, M. H.; Pasquali, R., et al. (2013). Diagnosis and treatment of polycystic ovary syndrome: an Endocrine Society clinical practice guideline. *J. Clin. Endocrinol. Metab.* (98); 4565–4592. doi: 10.1210/jc.2013-2350.
- 3-Barber TM and Franks S. (2021) Obesity and polycystic ovary syndrome. *Clin Endocrinol (Oxf)*. (95)4 :531-541. doi: 10.1111/cen.14421. Epub 2021 Jan 31. PMID: 33460482.
- 4-Thamer, S. J. (2021) Body Fat Distribution and the Levels of Some Biochemical, Hormonal and Inflammatory Biomarkers in Obese Healthy Women. *Annals of R.S.C.B.*; 25(14);1348 – 1359.
- 5-Zhang, L.L.; Yan Liu, D.; Ma, L.Q.; Luo, Z.D.; Cao, T.B.; Zhong, J.; Yan, Z.C.; Wang, L.J.; Zhao, Z.G.; Zhu, S.J.; et al. (2007) Activation of transient receptor potential vanilloid type-1 channel prevents adipogenesis and obesity. *Circ. Res.*; (100) 1063–1070.
- 6-Alwan S. A. and Alsaeed M. H. (2021) Biosynthesized silver nanoparticles (using *Cinnamomum zeylanicum* bark extract) improve the fertility status of rats with polycystic ovarian syndrome. *Biocatalysis and Agricultural Biotechnology*, 38 (102217),
- 7-Abd-Alqader, S. M.; Zearah, S. A.; and Al-Assadi, I. J. (2023). Effect of Curcumin (Standard and Supplement) with Zinc on Reproductive Hormones in Polycystic Ovary Syndrome (PCOS) Rats: <http://www.doi.org/10.26538/tjnpr/v7i3>.
12. *Tropical Journal of Natural Product Research (TJNPR)*; 7(3), 2540–2546. Retrieved from <https://tjnpr.org/index.php/home/article/view/1794>



- 8-Singh, S. M. uddin, M. M. A. ;khan, S. ; singh, A. S. ; chishti, and U. H. bhat (2022). Therapeutic properties of capsaicin: a medicinally important bio-active constituent of chilli pepper *Asian Journal of Pharmaceutical and Clinical Research*;15 (7); 47-58, doi:10.22159/ajpcr.2022.v15i7.44405.
- 9-Kato – noghuchi H. and Tanaka Y. (2003). Effect of Capsaicin on plant growth. *Biologia plantarum*, 47(1):157-159.
- 10-Fattori V.; Hohmann M. S.; Rossaneis A.C.; Pinho-Ribeiro F.A. and Verri W.A. (2016) Capsaicin: Current Understanding of Its Mechanisms and Therapy of Pain and Other Pre-Clinical and Clinical Uses. *Molecules*; 21 (7):844. doi: 10.3390/molecules21070844. PMID: 27367653; PMCID: PMC6273101.
- 11-Zik, B.; Altunbas K.; Tutuncu S.; Ozden O.; Ozguden Akkoc, C. G.; Peker, S.and Sevimli, A. (2011). Effects of capsaicin on nitric oxide synthase isoforms in prepubertal rat ovary. *Biotechnic & Histochemistry*, 87(3): 22-218.DOI:10.3109/10520295.2011.608716
- 12-Kafali H.; Iriadam M.; Ozardali I. and Demir N. (2004) Letrozole-induced polycystic ovaries in the rat: a new model for cystic ovarian disease. *Arch Med Res*. 35(2):103-8.
- 13-Matsuzaki, T.; Tungalagsuvd, A.; Iwasa, T.;Munkhzaya, M.;Yanagihara, R.;Tokui, T.;Yano, K.; Mayila, Y.; Kato, T.; Kuwahara, A. and Matsui, S. (2017) Kisspeptin mRNA expression is increased in the posterior hypothalamus in the rat model of polycystic ovary syndrome. *Endocr. J.*; (64), 7–14.
- 14-Azziz R.; Carmina E.; Dewailly D.; Diamanti-Kandarakis E.; EscobarMorreale H.F.; Futterweit W. et al. (2006) Positions statement: criteria for defining polycystic ovary syndrome as a predominantly hyperandrogenic syndrome: an androgen excess society guideline. *J Clin Endocrinol Metab.*; (91) 4237–45.
- 15-Abdel Hakim, S. M.and Saad, A. H. (2019): Omega-3 Ameliorates Effects of Letrozole-Induced Polycystic Ovary Syndrome in Adult Female Rats. *MJMR*, 30 (1), 12-26 pp.
- 16-Munjuluri S.; Wilkerson D.A.; Sooch G.; Chen X.;White F.A. and Obukhov A.G.(2021) Capsaicin and TRPV1 Channels in the Cardiovascular System: The Role of Inflammation. *Cells.*;11(1):18. doi: 10.3390/cells11010018.
- 17-Lind A.K.; Weijdegård B.;Dahm-Kähler P.; Mölne J.; Sundfeldt K. and Brännström M. (2006) Collagens in the human ovary and their changes in the perifollicular stroma during ovulation. *Acta Obstet Gynecol Scand.*; 85(12):1476-84. doi: 10.1080/00016340601033741. PMID: 17260225.
- 18-Fattori V.; Hohmann M. S.; Rossaneis A.C.; Pinho-Ribeiro F.A. and Verri W.A. (2016) Capsaicin: Current Understanding of Its Mechanisms and Therapy of Pain and Other Pre-Clinical and Clinical Uses. *Molecules*; 21 (7):844. doi:

10.3390/molecules21070844. PMID: 27367653; PMCID: PMC6273101.

19-Palomba, S.; Russo, T.; Orio Jr.F.; Falbo, A.; Manguso, F.; Cascella, T. and *et al.* (2006) Uterine effect of metformin administration in anovulatory women with polycystic ovary syndrome. *Hum Reprod*; (21): 457465.

20-Nestler, J.E. (2008) Metformin for the treatment of the polycystic ovary syndrome. *N Engl J Med*; (358): 47-54

21-Johnson NP. (2014) Metformin use in women with polycystic ovary syndrome. *Ann Transl Med.*; 2(6):56. doi: 10.3978/j.issn.2305-5839.2014.04.15. PMID: 25333031; PMCID: PMC4200666.

22-Ye Z.R.; Yan C.Q.; Liao N.; Wen S.H.; (2023) The Effectiveness and Safety of Exenatide Versus Metformin in Patients with Polycystic Ovary Syndrome: A Meta-Analysis of Randomized Controlled Trials. *Reprod*

*Sci.* ;30(8):2349-2361. doi: 10.1007/s43032-023-01222-y. Epub 2023 Mar 31. PMID: 37002532; PMCID: PMC10354168.

23-Galano A. and Martínez A. ( 2012) Capsaicin, a tasty free radical scavenger: mechanism of action and kinetics. *J Phys Chem B.*;116(3):1200-8. doi: 10.1021/jp211172f. Epub 2012 Jan 13. PMID: 22188587.

24-Trujillo A.; Morales L. and Domínguez R. (2015) The effects of sensorial denervation on the ovarian function, by the local administration of capsaicin, depend on the day of the oestrous cycle when the treatment was performed. *Endocr.*;48:321–8.

25-Ching L.C.; Kou Y.R.; Shyue S.K. and *et al.* (2011) Molecular mechanisms of activation of endothelial nitric oxide synthase mediated by transient receptor potential vanilloid type 1. *Cardiovasc Res*; (91):492–501.

## التأثير النسجي الكيميائي للكابيسين وحده أو بالاشتراك مع الميتفورمين على بنية المبيض بعد استحداث تكيس المبايض المتعدد الكيسات في الجرذان

عليه محمد خضير<sup>1</sup> كريم هلال ثامر الديراوي<sup>2</sup> لبيد عبد الله السعد<sup>3</sup>

- 1- فرع التشريح والانسجة - كلية الطب البيطري-جامعة البصرة- البصرة - العراق.
- 2- قسم علوم الحياة - كلية العلوم - جامعة البصرة - البصرة - العراق.
- 3- قسم الانظمة الطبية الذكية، كلية علوم الحاسبات وتكنولوجيا المعلومات، جامعة البصرة

### الخلاصة

في دراستنا الحالية، تحققنا من تأثير الكابيسين لوحده او مع الميتفورمين على استحداث متلازمة تكيس المبايض في اناث الجرذان المختبرية البالغة. العدد الكلي من الحيوانات المستخدمة بالدراسة (70)، الدراسة قسمت الى تجربتين: التجربة الاولى استحداث التكريس في (50) حيوان منها (ن= 10) ج أ كمجموعة سيطرة اعطيت كاربوكسي ميثيل سيليلوز فمويًا 1ملغم \كغم و (ن=40) اعطيت مادة اليتروزول 1 ملغم | كغم استمرت التجربة لمدة 21 يوم في نهاية التجربة. ضحينًا (ن=10) من اناث الجرذان التي اعطيت ليتروزول واعتبرت كمجموعة فرعية لمتلازمة تكيس بالاضافة الى قتل (مجموعة الكاربوكسيل ميثيل سيليلوز). لغرض التأكد من استحداث متلازمة تكيس المبايض ولدراسة الكيمياء النسيجية تم عزل المبايض من اناث الجرذان ووضعت في محلول الفورمالين 10%. التجربة الثانية ما تبقى من اناث الجرذان في تجربة استحداث تكيس المبايض (ن=30) قسمت الى ثلاثة مجاميع فرعية المجموعة الفرعية الاولى (مجاميع فرعية حيوانات 10) (الكابيسين + ليتروزول) مجموعة فرعية اعطيت 0.5 ملغم | كغم من الكابيسين , المجموعة الفرعية ( الميتفورمين) اعطيت الميتفورمين 9 ملغم | كغم و ( الميتفورمين + الكابيسين + اليتروزول). ما تبقى من العدد الكلي (ن=20) التي لم يستحث فيها متلازمة تكيس المبايض قسمت الى (ن= 10) ( المجموعة الفرعية للكحول ) مجموعة السيطرة التي اعطيت الكحول 0.5 مل و (ن= 10) ( المجموعة الفرعية فقط) بدون استحداث لمتلازمة تكيس المبايض كمجموعة سيطرة موجبة اعطيت الكابيسين ( 0.5 ملغم | كغم). استمرت التجربة الثانية لمدة 21 يوم بعد انتهاء التجربة جميع الحيوانات قتلت وتم عزل المبايض وتثبيتها في (10 %) فورمالين وجهزت لغرض الدراسة الكيمياء النسيجية باستخدام صبغة مالوري الثلاثية اللون. سجلنا في دراستنا الحالية العديد من الاكياس , والنزف والرشح في المجموعة الفرعية لمتلازمة تكيس المبايض مقارنة بمجموعة كاربوكسيل ميثيل سيليلوز اظهرت الفحوصات الكيمياء النسيجية في مجاميع المعالجة الكابيسين لوحده او مع الميتفورمين تحسن بالتركيب النسيجي اختفاء الاكياس والنزف مقارنة مع مجاميع السيطرة والمجموعة الفرعية لمتلازمة تكيس المبايض . نحن نعتقد ان الكابيسين لوحده او مصاحباً مع الميتفورمين يحسن في انسجة المبيض.

**الكلمات المفتاحية:** متلازمة تكيس المبايض، الكابيسين، الميتفورمين.