

Protective Effect of Zinc Sulfate on Hypo-and Hyperthyroidism Induced in Adult Male Rabbits

Nooralhuda Hussein Falih; Jassim M. A. Alkalby

Department of Physiology, Pharmacology and Chemistry, College of Veterinary Medicine, University of Basrah, Basrah, Iraq

Correspondence author: jassim.ahmed@uobasrah.edu.iq

Received: Oct. 8, 2021; Accepted: Oct. 24, 2021; Available Online: Dec. 2021

Abstract

The present study was conducted to investigate the effect of co-administration of zinc sulfate with Carbimazole (CBZ) and, Levothyroxine (L-T₄) on thyroid gland function in adult male rabbits. Fifty adult male rabbits, were divided randomly into five equal groups (6 rabbits/group) as follows: The first group (control group): Rabbits were given oral doses of distilled water daily by gavage; second group (Hypothyroidism): Rabbits were given oral doses of carbimazole (5 mg/kg. bw) daily by gavage; the third group; Rabbits were given oral doses of carbimazole (5 mg/kg. bw) + zinc sulfate (20 mg/kg.bw); fourth group (Hyperthyroidism): Rabbits were given oral doses of L-T₄ (100µg/kg.bw) daily by gavage; Fifth group: Rabbits were given oral doses of L-T₄(100µg/kg.bw) + Zinc sulfate (20mg/kg.bw) daily by gavage. The treatment continued for 30 days. The results revealed the following: A significant elevation in serum TSH level and a significant reduction in serum T₄, T₃ and, FT₃ levels in CBZ treated rabbits group compared with the control group, while a significant reduction in serum TSH level and a significant elevation in serum levels of T₄, FT₄ and FT₃ in animals group treated with the L-T₄ compared with the control group. Histopathological changes of hypothyroidism were observed in CBZ treated group characterized by small thyroid follicles, increase the height of thyrocytes hyperplasia, and vacuolation of colloid. L-T₄ and L-T₄-Zinc treated groups showed large follicles distended with homogenous acidophilic colloid. No significant changes in thyroid architecture were observed in CBZ-Zinc treated group compared with the control group.

Key words: *Carbimazole, L-T₄, Zinc Sulfate, Thyroid hormones levels*

Introduction

The thyroid gland is considered one of the most important endocrine glands in the body in the human which carries out different functions. Thyroid hormones triiodothyronine (T_3) and tetraiodothyronine (T_4) are the main fundamental, to several metabolic functions and these hormones are also demand by almost all body tissues for performing of normal functions. These hormones impact basal metabolic rate and oxygen consumption (1). The thyroid dysfunctions could be one of the most critical disorders in the rabbit (2; 3). Hypothyroidism is a prevalent disturbance of the endocrine system in which the thyroid gland does not produce a sufficient amount of thyroid hormones (THs). Hypothyroidism (HT) is characterized by a decrease in metabolic rate which leads to an adverse impact on numerous organs and system activities (4). Hyperthyroidism is a defect in which thyroid hormone is synthesized in excess amount and secreted by the thyroid gland. Variations in thyroid gland functions influence nearly all physiological systems (5; 6).

Various trace elements such as selenium (Se) and zinc (Zn) are included in the synthesis and metabolism of THs (7). Zinc is considered, an essential element for the synthesis of thyroid hormones in addition to its effects on target tissues,

Zinc is wanted for the synthesis of the thyrotropin-releasing hormone (TRH), it plays an important role in the binding of T_3 to its nuclear receptor, in the anterior pituitary Zinc participates in the synthesis of the thyroid-stimulating hormone (TSH), and it acts as an inhibitor or cofactor of type 1 and type 2 deiodinases (8; 9; 10). The normal function of the thyroid gland depends on the presence of several trace elements such as iodine, selenium, zinc, iron, and copper, for both the synthesis and metabolism of THs, insufficiency of these elements can lead to hypothyroidism (11). This study aimed to investigate the possible protective role of Zinc sulfate against hypothyroidism and hyperthyroidism induced by Carbimazole and L- T_4 in adult male rabbits.

Materials and Methods

The Experimental Animals:

This study experiment was carried out at the Animal House of the College of Veterinary Medicine/ University of Basrah, Iraq. A total of 30 well-experienced adult male rabbits, weighed (1320 ± 239.36) gm at the beginning of the study, were used in this study. They were maintained under light dark cycle (14/10) hours, at a temperature (25 ± 2) $^{\circ}\text{C}$. All rabbits were supplied food and water *ad libitum*. The rabbits were kept for two

weeks for an acclimatization period before the commencement of the experiment.

The Experimental Design:

This experiment was carried out on 30 adult male rabbits; they were divided into five equal groups (n=6) each, as follows: The first group (control group): Rabbits were given oral doses of distilled water(0.2µl/kg.bw) daily by gavage. The second group (Hypothyroidism): Rabbits were given oral doses of carbimazole (5mg/kg. bw) daily by gavage. The third group: Rabbits were given oral doses of carbimazole (5mg/kg.bw) + Zinc sulfate (20mg/kg.bw) daily by gavage. The fourth group (Hyperthyroidism): Rabbits were given oral doses of L-T₄ (100µg/kg.bw) daily by gavage. The fifth group: Rabbits were given oral doses of L-T₄(100µg/kg.bw) + Zinc (20mg/kg.bw) daily by gavage. The experiment continued for 30 days.

At the end of the experimental period, the rabbits were euthanized via chloroform asphyxiation, blood samples were collected from the heart directly by cardiac puncture using gel separator tubes. Following collection, the blood was centrifuged at 3000 rpm for 15 minutes for the separation of serum samples. Serum samples were collected after centrifugation and kept in Eppendorf tubes and stored at -20 C° until measurement of thyroid hormones level. Thyroid specimens were removed and

maintained in 10% formalin for histological examination.

Measurement of thyroid hormones

Serum levels of T₄, T₃, FT₄, FT₃, and TSH, were determined by using ELISA kits supplied by Monobind Inc. lake forest CA 92630, USA). All the procedures were performed according to the manufacturer's instructions (12).

Histopathological study

Tissue samples of the thyroid gland fixed in buffered formalin were embedded in paraffin, then a tissue section of 6 µm was taken and stained with eosin and hematoxylin. The sections were examined by using a light microscope for histopathological changes (13).

Results

The results as presented in Table (1) revealed a significant ($p \leq 0.5$) increase in serum TSH concentration in CBZ-treated group compared with the control group. While CBZ+Zinc treated group recorded a significant ($p \leq 0.5$) decrease in serum TSH concentration compared with the CBZ-treated group as the TSH value was not significantly different compared to the control group. A significant ($p \leq 0.5$) decrease in serum TSH concentration was recorded in L-T₄ treated group compared with CBZ and CBZ+Zinc groups. Whereas L-T₄+Zinc group showed an attenuated increase in TSH concentration with no

significant differences compared to the control group. On the other hand, a significant ($p \leq 0.5$) decrease in serum T_4 concentration was recorded in CBZ treated group compared with the control group. While no significant differences were observed in T_4 values between CBZ + Zinc group and the control group. Whereas a significant ($p \leq 0.5$) increase in serum T_4 concentrations were recorded in L- T_4 and L- T_4 +zinc treated groups compared with the control and other treated groups. There was an insignificant ($p \geq 0.05$) decrease in FT_4 value in CBZ group compared with the control group. Furthermore, a significant ($p \leq 0.5$) increase in FT_4 values were recorded in both L- T_4 and L- T_4 + zinc treated groups compared with the CBZ group. An insignificant decrease and increase in serum T_3 values were recorded in CBZ and CBZ+ Zinc groups respectively compared with the control group.

A significant ($p \leq 0.5$) increase in serum T_3 value was recorded in L- T_4 group compared with the control and other treated groups except L- T_4 treated group where no significant was found. A significant ($p \leq 0.5$) increase in serum T_3 value was recorded in L- T_4 group compared with the control and other treated groups except L- T_4 treated group where no significant was found. Finally, a significant ($p \leq 0.5$) decrease in serum FT_3 concentration was recorded in CBZ treated group compared with the control and all other treated groups. While no significant difference was observed in FT_3 values between CBZ+ Zinc treated group and the control group. Moreover, a significant ($p \leq 0.5$) increase in FT_3 values were recorded in L- T_4 and L- T_4 + zinc groups compared with the control and other treated groups.

Table (1) Effect of Carbimazole, LT-4 and Their Co-treatment with Zinc on Thyroid Function in Adult Male Rabbits (M±SD)

Parameters Groups	TSH(μ U/ml)	T ₄ (μ g/dl)	T ₃ (ng/ml)	FT ₄ (ng/dl)	F T ₃ (pg/ml)
Control	1.15±0.122 bc	2.89±0.43 b	1.55±0.75 b	1.01±0.48 ab	4.02±0.73 b
CBZ	2.67±0.86 a	1.34±0.46 c	0.37±0.12 c	0.66±0.54 b	1.42±0.52 c
CBZ+Zinc	1.21±0.26 b	3.03±0.89 b	2.34±0.66 b	1.24±0.49 ab	3.23±1.06 b
L-T4	0.33±0.17 c	4.96±0.89 a	3.37±1.11 ab	2.25±1.36 a	5.80±0.70 a
L-T4+Zinc	0.59±0.49 bc	4.36±0.72 a	4.59±1.70 a	2.20±.84 a	5.91±1.65 a
LSD	0.88	1.33	2.24	1.53	1.81

(n=6) The different letters refer to significant differences among groups at ($p \leq 0.5$) level, n= numbers of animals in each group

Histopathological Results

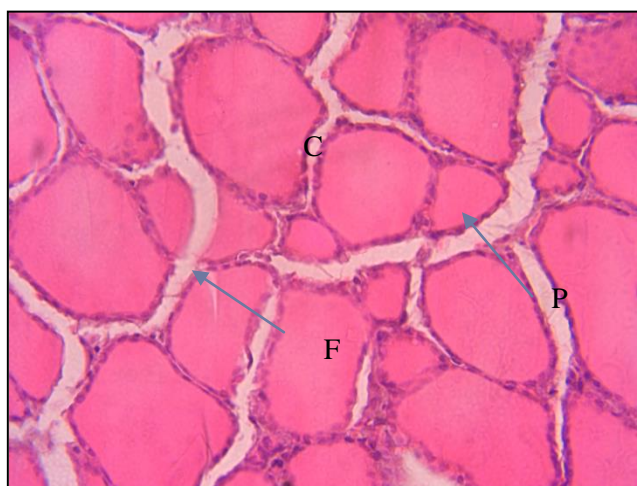

Figure (1): Thyroid tissue section of control group rabbits showing, thyroid follicles (F) of different sizes, lined by low cuboidal epithelium, filled with homogenous acidophilic colloid (C) and Interfollicular connective tissue with C - cells (P). (H and E, 400X).

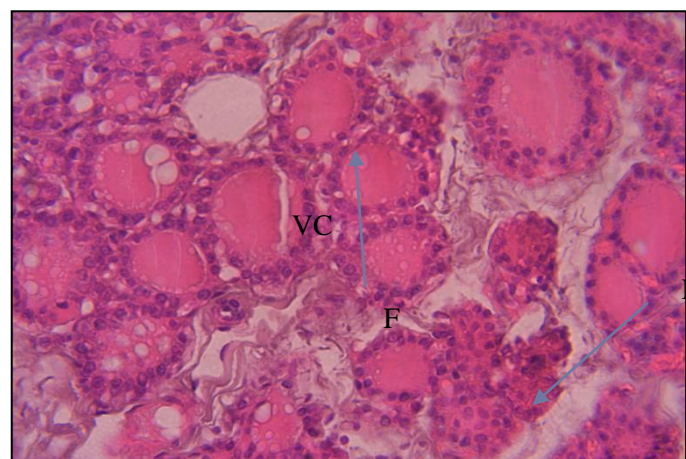


Figure (2): Thyroid tissue section of rabbits group treated with CBZ showing, small follicles (F) ,lined by high cuboidal thyrocytes, with little dense and vacuolated colloid(VC), and Hyperplasia of some follicular epithelium(H). (H and E, 400X).

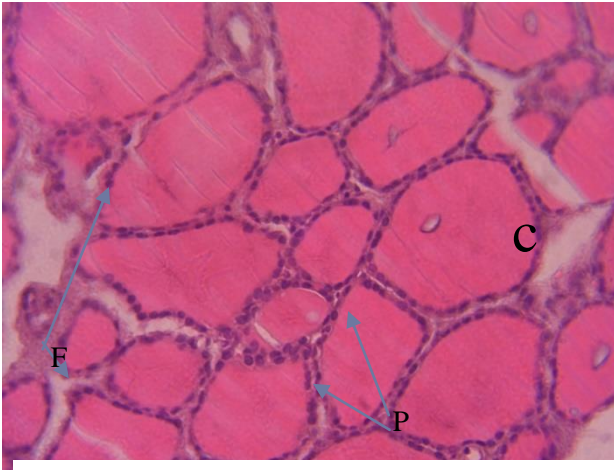


Figure (3): Thyroid tissue section of rabbits group treated with CBZ + Zinc showing, normal thyroid follicles of different sizes(F), lined by low cuboidal epithelium(C), filled with homogenous acidophilic colloid, normal interfollicular connective tissue with C-cells(P). (H and E. 400X).

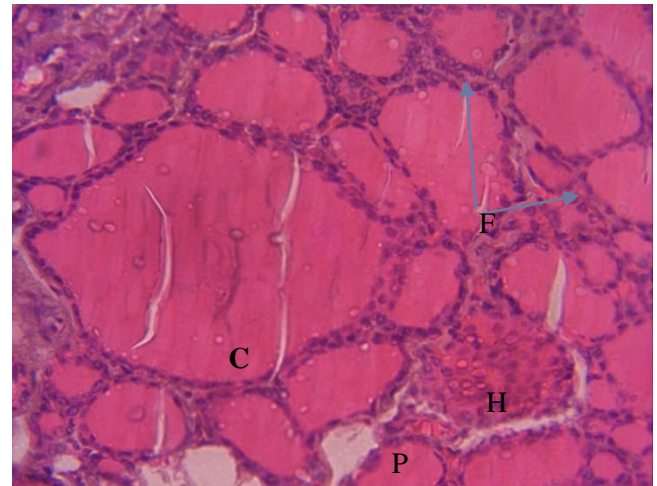


Figure (4): Thyroid tissue section of rabbits group treated with L-T4 for 30 days showing, follicles of different sizes distended (F) by a large quantity of homogenous acidophilic colloid (C), lined by flattened epithelial cells, hyperplasia of some follicles(H), normal interstitial tissues with C-cells(P). (H and E 400X).

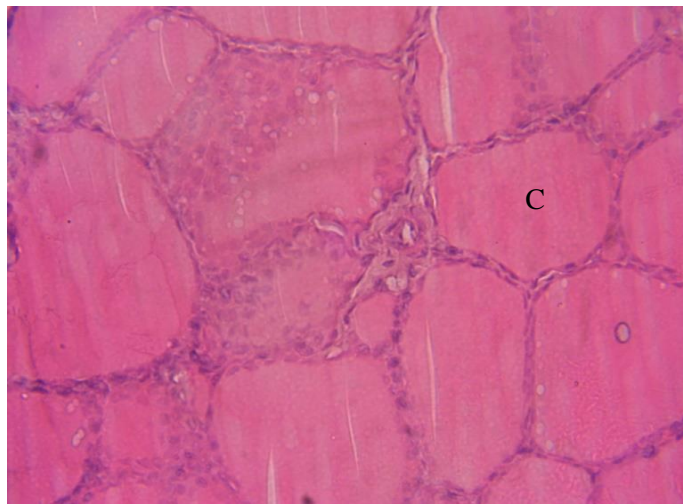


Figure (5): Thyroid tissue section of rabbits group treated with L-T4 + Zinc showing, different sizes of thyroid follicles(F) distended with homogenous acidophilic colloid(C), lined by flattened epithelium , hyperplasia of some follicles epithelium(H) and interfollicular C-cells. (H and E 400X).

Discussion

The results of the present study revealed a significant increase in serum concentration of TSH and a significant decrease in serum T_4 and FT_3 concentrations and insignificant decrease in serum T_3 and FT_4 concentrations in CBZ-treated group for 30 days compared with the control group. These results are in agreement with (14; 15; 16) who all found a significant reduce in serum T_3 and T_4 levels and elevation in serum TSH level in CBZ-treated adult groups, compared with the control group. The results of the current study are in accordance with (17; 18; 19) who all found that a significant reduction in serum T_3 and T_4 levels and a significant increase in serum TSH levels in adult male rats treated with propylthiouracil (PTU) compared with the control group. The present results are in line with those of (20;21; 22) they concluded that hypothyroidism and hyperthyroidism induced in adult male rats by treatment with CBZ and thyroxine respectively revealed a significant increase in serum TSH level and a significant decrease in serum T_3 and T_4 levels in CBZ treated group compared with the control group while a significant reduction in

serum TSH and a significant elevation were recorded in L- T_4 treated group

compared with the control group. Carbimazole is converted to methimazole (its active form) which in turn prevents the thyroid peroxidase enzyme from a couple with residues of tyrosine and prevents the iodination process on thyroglobulin, thus, the production of T_3 and T_4 will be decreased consequently, leading to increase the level of TSH (23).

The results obtained in animals group treated with L- T_4 were matched with the results obtained in rabbits by (24) who found a significant increase in serum T_3 and T_4 levels in animals group treated with different doses (25, 50 and 100 mg T_4 /Kg Body weight) for five weeks. Our results agreed with that previously mentioned by (25; 26) who indicated that treatment of adult male rats with L- T_4 induced a significant increase in T_3 and T_4 levels and decrease in serum TSH level compared with the control group. Similarly, (27; 28) they mentioned that adult male rats treated with the L- T_4 causes a significant elevation in serum FT_3 and FT_4 levels and reduction in serum TSH level compared with the control group. It was found that the mean value of T_3 , T_4 , FT_3 , and FT_4 were higher and the mean value of TSH was lower in hyperthyroid patient's compared with that of the control group (29; 30). The significant reduction of serum zinc

concentration obtained in the current results may contribute to the development of hypothyroidism in CBZ treated group.

No significant differences in all thyroid hormones were observed between animals group treated with a combination of CBZ+zinc and the control group. These results are in consistent with the results observed by (31; 18) they found that administration of the different levels of zinc causes significant elevation in serum FT₃ and FT₄ in PTU-induced hypothyroidism male rats and causes reduction in TSH level compared with the positive control group. Zinc prevent reduction in thyroid hormones due to its antioxidant activity. Zinc is an important element necessary for the optimal activity of numerous hormones, including TH (32). Zinc, in particular, is necessary for THs synthesis as well as its effect on the target tissues. Zinc is demand for synthesis of thyrotropin-releasing hormone (TRH), It plays an important role in linking T₃ to its Receptor in the nucleus participates in the synthesis of stimulating the thyroid gland Hormone (TSH) in the anterior pituitary gland, works inhibitor or cofactor of type 1 and type 2 deiodinases (10). A probable role of zinc in the thyroid gland function is the preservation of antioxidant balance and zinc acts as a cofactor for superoxide dismutase and is

substantial, for the activity of glutathione peroxidase (33).

The reduction in TSH level in the hyperthyroid group may result from a negative feedback effect of elevated T₃ and T₄ levels on the pituitary and /or hypothalamus. Results of the current study revealed that co-administration of zinc with L-T₄ has no effect on the elevated THs levels in hyperthyroid rabbits group. In the group of animals treated with T₄ and zinc, thyroid hormones remained elevated compared to the control group. This may be due to availability of zinc keeps thyroid hormones on high activity, in addition to the fact that zinc availability increases zinc absorption from the intestine.

Histopathological Study

Histopathological examination of thyroid gland of rabbits treated with CBZ for 30 days revealed small follicles, lined by height cuboidal thyrocytes, with little dense and vacuolated colloid, and Hyperplasia of some follicular epithelium. These changes are in accordance with those mentioned by (34) who found that thyroid gland of PTU-treated rats showed hyperplasia of the cells thyroid follicles revealing a promoted thyroid activity, increased vascularity and the number of thyroid follicles, and reduction in the colloid content. The results of the thyroid

gland treated with a combination of CBZ and Zinc indicated that no histopathological changes of the thyroid gland compared with the control group. In the same line the histological section of rat thyroid gland treated with PTU showed that thyroid follicles were and displayed copious granular cytoplasm with decrease in luminal size and entire absence of colloid material (19).

The present results are in consistent with that observed by (35) who found that rabbits treated with the CBZ for 30 days showed hypertrophy of epithelial cells lined the thyroid follicles, contain non homogenous colloid, congestion of blood vessels and hemorrhage. Similarly, PTU-induced hypothyroidism showed thyroids follicles with different sizes, filled with a variable amount of small dense and extremely vacuolated colloid, the follicles lined by cuboidal and sometimes columnar epithelial cells, with occasionally eosinophilic and vacuolated cytoplasm and hyperchromatic nuclei, furthermore, a pool of follicular cells depleted of the lumen and follicles lined by one or more layers of epithelial cells (36; 37; 38). In the same line, thyroid tissue section sections of methimazole treated rats showed degenerative alterations of different follicles with the empty follicular lumen. Most of the

follicles appeared irregularly shaped and narrowed due to depleted colloid. The epithelial cells lining the follicles were enlarged and less or more cylindrical in shape (15). The increase in follicular activity may be attributed to the reduction in T₄ levels which causes an elevation of TSH secretion from pituitary gland as obtained in this study, which leads to an increase in the proliferative activity of thyrocytes. The histological section of L-T₄ treated group showed thyroid follicles with different sizes distended with homogenous acidophilic colloid, lined by flattened epithelial cells, similar results was obtained by (26). In contrast to the present results thyroid follicles of hyperthyroid rats induced by L-T₄ appeared in variable sizes, lined by cuboidal thyrocytes with basophilic rounded nuclei and the lumen of numerous follicle lumen were empty from colloid. Various follicular cells displayed vacuolated cytoplasm and pale nuclei. Some other follicles are atrophied and minute blood capillaries were noted (39; 25). The biochemical results of the present study assured the histopathological manifestations of the rabbit's thyroid glands treated with both CBZ and L-T₄.

As for the group that was treated with carbimazole with zinc, no histological changes were observed in the thyroid

tissue compared to the control group. This may be due to the fact that the addition of zinc maintains the level of zinc in the body, which is necessary for the functioning of thyroid hormones and thyroid homeostasis, as it was found from the results of the current study that there was a decrease in zinc concentration in the group. While the thyroid tissue in the group treated with T4 and zinc showed similar changes to the thyroid of the group treated with T4 compared to the control group, this may be because zinc in hyperthyroidism acts as a stimulator for thyroid activity.

Conclusion: Based on the results of this study, we can conclude that administration of zinc sulfate is more effective in the protection of thyroid function in hypothyroidism induced by carbimazole than hyperthyroidism induced by L-T4 in adult male rabbits.

Acknowledgements: Authors acknowledge the College of Veterinary medicine, university of Basrah for providing facility.

Conflict of Interest: The authors report no conflicts of interest.

References

1. Kologlu, S. and Erdogan, G. (2005). Thyroid: general remark and information. In: Erdogan G, editor.
2. Rodriguez-Castelan, J; Martinez–Gomez, M; Castelan, F. and Cuevas, E. (2015). Hypothyroidism Affects Vascularization and Promote Immune Cells Infiltration into Pancreatic Islets of Female Rabbits. *Int. J. Endocrinol.*; 917806.1–9.
3. Rodriguez-Castelan, J; Mendez-Tepepa, M; Carrillo-Portillo, Y; Anaya-Hernandez, A; Rodriguez –Antolin, J; Zambrano E; Castlan, F. and Cuevas-Romero, E. (2017). Hypothyroidism Reduces the Size of Ovarian Follicles and Promotes Hypertrophy of Periovarian Fat with Infiltration of Macrophages in Adult Rabbits. *Biomed Res Int.* 1- 11.
4. Golden, S.H. Robinson, K.A; Saldanha, I; Anton, B. and Ladenson, P.W. (2009): "Clinical review: Prevalence and incidence of endocrine and metabolic disorders in the United States: a comprehensive review", *J Clin Endocrinol Metab.* 94:1853-78.
5. Mariani, L.H. and Berns, J.S. (2012). The renal manifestations of thyroid disease. *J. Am. Soc. Nephrol.* 23:22-26.
6. Kahaly, G.J; Bartalena, L; Hegedüs. L; Leenhardt, L; Poppe, K. and Simon,

Kologlu Endocrinology. *Basis and Clinic. 2nd ed. Ankara: Nobel Bookstore.*Pp.;155-72.

- H. Pearce, S.H. (2018). European Thyroid Association Guideline for the Management of Graves' Hyperthyroidism. *Eur Thyroid J.* 7:167-86.
7. Rasic-Milutinovic, Z; Jovanovic, D; Bogdanovic, G; Trifunovic, J. and Mutic, J. (2017). Potential influence of selenium, copper, zinc and cadmium on l-thyroxine substitution in patients with hashimoto thyroiditis and hypothyroidism, *Experimental and Clinical Endocrinology & Diabetes.* 125(02) :79-85.
 8. Ertek, S; Cicero, A. F. G; Caglar, O. and Erdogan, G. (2010). Relationship between serum zinc levels, thyroid volume following successful iodine supplementation. *Hormones.* 9: 263.
 9. Marques, L. F. J. C; Donangelo, C. M; Franco, J. G; Pires, L; Luna, A. S; Casimiro-Lopes, G; [Lisboa](#), P. C. and [Koury](#), J. C. (2011). Plasma zinc, copper, and serum thyroid hormones and insulin levels after zinc supplementation followed by placebo in competitive athletes. *Biol. Trace Elem. Res.* 142(3):415-23.
 10. Baltaci A. K; Mogulkoc, R. and Belviranli, M. (2013) Lthyroxine-induced hyperthyroidism affects elements and zinc in rats. *Bratisl. Lek. Listy.* 114, 125.
 11. Betsy, A; Binitha, M.P. and Sarita, S. (2013): "Zinc Deficiency Associated with Hypothyroidism: An Overlooked Cause of Severe Alopecia" *nt J. Trichology.*, 5(1): 40–42.
 12. Ma, H; Shieh, K. and Lee, S. (2006). Study of ELISA Technique. *Natu. Scie.*4(2):36-37.
 13. Luna, H. T. and Lee, G. (1968). Manual histological staining methods of the armed forces institute and pathology, 3rd. ed the Blakis. Mc Graw – Hillbook Co. New yourk. USA.
 14. Jasim, W. K. (2017). Protective effects of dehydroepiandrosterone (DHEA) against Carbimazol-induced toxicity in male mice. *Int. J. Res. Pharm. Sci.*, 8(3), 277-281.
 15. Ezz, M.E; Hassan, R.E. and Esmat, A.Y. (2017). Pineapple juice supplementation activates thyroid gland and attenuates hyperlipidemia in rats. *International Journal of Biosciences (IJB)*, 10(3): 173-184.
 16. Nam, S.M; Kim, J.W; Yoo, D.Y; Jung, H.Y; Chung, J. Y; Kim, D.W; Hwang, I.K. and Yoon, Y.S. (2018). Hypothyroidism increases cyclooxygenase-2 levels and pro-inflammatory response and decreases cell proliferation and neuroblastoma differentiation in the

- hippocampus. *Molecular Medicine Reports*. 17: 5782-5788.
17. Dons, R.F. and Wians, F.H. (2009). Endocrine and Metabolic Disorders. *Clinical Lab Testing Manual (4th ed.)*, Boca Raton: CRC Press. Pp.: 10.
 18. Rabeh, N.M. and El-Ghandour, H. A. (2016). "Effect of Iron, Zinc, Vitamin E and Vitamin C Supplementation on Thyroid Hormones in Rats with Hypothyroidism. *International journal of Nutrition and Food Science*.5(3);201-210.
 19. Singh S; Panda V; Sudhamani S. and Dande P. (2020). Protective effect of a polyherbal bioactive fraction in propylthiouracil induced thyroid toxicity in rats by modulation of the hypothalamic–pituitary–thyroid and hypothalamic–pituitary–adrenal axes. *Toxicology Reports*. 7: 730–742.
 20. Uduak, O.A; Ani, E.J; Etoh, E.C.I. and Macstephen, A.O. (2014). Comparative effect of Citrus sinensis and carbimazole on serum T4, T3 and TSH levels. *Niger Med. J.*; 55(3): 230–234.
 21. Hashem, H.R. and Saad, S. A. (2019). Comparative study of the effect of experimentally induced hyperthyroidism and hypothyroidism on the parotid gland in adult male albino rats. *EJH*. 43(3):971-807.
 22. Hammad, A. Y; Adam, S. I. Y and Abdelgadir, W. S (2021). Comparative Effects of Bisphenol A, Carbimazole and Thyroxine Administration on the Thyroid Gland, Serum Selenium and Iodine Concentration of Wistar Rats. *Asian Journal of Research and Reports in Endocrinology*. 4(1): 8-18.
 23. Nayak, B. and Burman, K. (2006). Thyrotoxicosis and Thyroid Storm. *Endocrinology Metabolism Clinics of North America*. 35:663-686.
 24. Elnagar, S. A. (2004). Thyroid Hormone Administration and Growing Rabbits Metabolism. *Eygp. j.Rabbit.Sci*.14(1);49-64.
 25. Ahmed, S. B; Asmaa, M; Moghazy, A. M. and Ahmed, F O. A. and Esebery, H. A. (2018). Effects of aqueous extract of polyherbal formulation against hyperthyroidism induced by L-thyroxin in a rat model. *Biomedical Research and Therapy*. 5(12):2876- 2887.
 26. Kim, S-M; Kim, S-C; Chung, I-K; Cheon, W-H, and Ku, S-K (2012). Antioxidant and Protective Effects of Bupleurum falcatum on the l-Thyroxine-Induced Hyperthyroidism in Rats. *Evidence-Based*

- Complementary and Alternative Medicine*. Article ID 578497, Pp.12.
27. Bahtiyar, N; Yoldaş, A; Aydemir, B. and Toplan, S. (2020a). Investigation of renal and testicular pro-inflammatory cytokine levels in experimental hyperthyroidism: Effects of selenium supplementation. *Med Science*. 9(2):393-398.
 28. Bahtiyar, N; Yoldaş, A; Aydemir, B. and Toplan, S. (2020b). Influence of hyperthyroidism on hepatic antioxidants and cytokines levels: An experimental study. *Medical Science and Discovery*. 7(3):439-44.
 29. Sharma, V. K; Pant, V; Aryal B. and Baral, S. (2017). Assessment of Liver Enzymes, Creatine Phosphokinase and Electrolytes in Patients with Hyperthyroidism Visiting Tertiary Center. *International Journal of Health Sciences and Research*. 7(10):93-96.
 30. Lv, L.-F; Jia, H.-Y; Zhang, H.-F. and Hu, Y.-X. (2017). Expression level and clinical significance of IL-2, IL-6 and TGF- β in elderly patients with goiter and hyperthyroidism. *European Review for Medical and Pharmacological Sciences*. 21: 4680-4686.
 31. Ibrahim, H. S; Rabeh, N. M. and Sharaf Elden, A. A. (2016). Effect of Selenium and Zinc Supplementation on Hypothyroidism in Rats. *ARC Journal of Nutrition and Growth (AJNG)*. 2(2): 16-27.
 32. Maxwell, C. and Volpe, S.L. (2007): "Effect of zinc supplementation on thyroid hormone function: A case study of two college females". *Ann Nutr Metab*. 51:188-194.
 33. Galazyn-Sidorczuk, M; Brzóska, M. M; Rogalska, J; Roszczenko, A. and Jurczuk, M. (2012) Effect of zinc supplementation on glutathione peroxidase activity and selenium concentration in the serum, liver and kidney of rats chronically exposed to cadmium. *J. Trace Elem. Med. Biol*. 26(1):46-52.
 34. El-Mehi, A.E. and Amin, S.A. (2012): "Effect of Lead Acetate on the Thyroid Gland of Adult Male Albino Rats and the Possible Protective Role of Zinc Supplementation: A Biochemical, Histological and Morphometric Study", *Journal of American Science*, 8(7):61-71.
 35. Mehson, F. S.; Rasmi, A.J. and Khaleel, S. J. (2017). Histological study of thyroid gland in case of experimentally induced hypothyroidism bucarbimazole in domestic female rabbits. *Bas. J. Vet. Res*. 16(1):146-156.

36. Ferreira, E; Silva, A.E; Serakides, R; Gomes, A.E.S. and Cassali, G.D. (2007). Model of induction of thyroid dysfunctions in adult female mice. *Arq. Bras. Med. Vet. Zootec.* 59(5): 1245-1249.
37. Elkalawy, S.A.M; Abo-Elnour, R.K; El Deeb, D. F. and Yousry, M. M. (2012). Histological and immunohistochemical study of the effect of experimentally induced hypothyroidism on the thyroid gland and bone of male albino rats. *Egypt. J. Histol.*, 36:92-102.
38. Farrag, O.S; Salman, D; Ali, F.A.Z; Sayed A.S; Mahmoud, M; and Abd-ElRaheem, A.E. A. (2020). Impact of continuous treatment with propylthiouracil on renal and hepatic functions in rabbits. *J. Appl. Vet. Sci.*, 5 (2): 49-60
39. Mullur, R; Liu, Y.Y. and Brent, G.A. (2014). Thyroid hormone regulation of metabolism. *Physiological Reviews.* 94:355–382.

التأثير الوقائي لكبريتات الزنك على قصور وفرط نشاط الغدة الدرقية المستحث في ذكور الأرانب البالغين

نور الهدى حسين فالح و جاسم محمد احمد الكلبي

فرع الفلسفة والادوية والكيمياء، كلية الطب البيطري، جامعة البصرة - البصرة، العراق

الخلاصة

أجريت الدراسة الحالية لمعرفة تأثير الإغذاء المشترك لكبريتات الزنك مع كاربيمازول (CBZ) وليفوثيروكسين (L-) (T_4) على وظيفة الغدة الدرقية في ذكور الأرانب البالغة. وقد أجريت هذه التجربة على ثلاثون من ذكور الأرانب البالغة تم تقسيمها عشوائياً إلى خمس مجموعات متساوية (6 أرانب لكل مجموعة)، المجموعة الأولى (مجموعة السيطرة): أعطيت الأرانب في هذه المجموعة ماء المقطر يومياً بالتجريب عن طريق الفم. المجموعة الثانية (قصور الغدة الدرقية): أعطيت الأرانب في هذه المجموعة كاربيمازول (5 ملغم / كغم من وزن الجسم) يومياً عن طريق الفم. المجموعة الثالثة أعطيت أرانب هذه المجموعة كاربيمازول (5 ملغم / كغم من وزن الجسم) + كبريتات الزنك (20 ملغم / كغم من وزن الجسم)؛ المجموعة الرابعة (فرط نشاط الغدة الدرقية): أعطيت الأرانب في هذه المجموعة الثايروكسين (100 ميكروغرام / كغم من وزن الجسم) يومياً عن طريق الفم، المجموعة الخامسة: أعطيت الأرانب في هذه المجموعة الثايروكسين (100 ميكروغرام / كغم من وزن حي) + كبريتات الزنك (20 مجم / كجم وزن حي) يومياً عن طريق الفم. استمر العلاج لمدة 30 يوماً. أظهرت النتائج ما يلي: ارتفاع معنوي في مستوى TSH في الدم وانخفاض معنوي في مستويات T_4 و T_3 و FT_3 في مصل الأرانب المعاملة بـ CBZ مقارنة بمجموعة السيطرة، مع انخفاض معنوي في مستوى TSH في الدم وارتفاع معنوي في مستويات المصل من T_4 و FT_4 و FT_3 في مجموعة الحيوانات المعاملة بـ $L-T_4$ مقارنة بمجموعة السيطرة كما لوحظت التغيرات النسيجية المرضية لقصور الغدة الدرقية في المجموعة المعالجة CBZ والتي تتميز بصغر حجم حويصلات الغدة الدرقية، وزيادة ارتفاع فرط تنسج الخلايا الدرقية، وتفجي المادة الغروانية. أظهرت المجموعات المعالجة بـ $L-T_4$ و $L-T_4$ -Zinc جريبات كبيرة ممثلة بغروان حمضي متجانس. كما لم يلاحظ أي تغيرات معنوية في بنية الغدة الدرقية في المجموعة المعالجة بالزنك + CBZ مقارنة مع مجموعة السيطرة.