

## The effect of different doses levels of silver nanoparticles (AgNPs) on the kidney and liver in Albino male Rat. Histopathological study

*Ruqayah Ali Salman\**

Received 26, March, 2014

Accepted 4, June, 2014

### Abstract:

**Objective:** In this study ,the effects of silver nanoparticles (Ag NPs)were investigated on the liver and kidney tissues. **Methodology:** The produced nanoparticles have an average particle size of about 30 nm. Eighteen male albino rats were used by dividing them into three groups, each group comprise 6 rats. First group(control group) given food and water like other groups by liberty. Second group was tail injected by (AgNPs) at dose of (0.4 mg/kg. body weight/day). Third group was injected by (AgNPs) at dose of (0.6 mg/kg. body weight/day) for 15 days. All animals were sacrificed at the end of experiment. The liver and kidney tissues specimens were fixed in 10% formalin and histological preparations were carried out then stained with H&E. Pathological changes in liver and kidney tissues were showed. **Results:** Histopathological studies revealed the harmful effect of the silver nanoparticles uses on the liver and kidney rats, second group that treated with Ag NPs (0.4 mg/kg.body.weight/day), kidney sections showed enlargement of collecting tubules, increase in interstitial tissue medulla, necrosis and enlargement in proximal and distal convoluted tubules. Liver showed enlargement of the central vein and degeneration of hepatic cells. Third group that treated with Ag NPs (0.6 mg/kg. body weight/day); kidney sections showed hyperplasia of the interstitial connective tissue of renal medulla with hemorrhages, renal cortex showed, degenerative changes and necrosis of proximal and distal convoluted tubules. Liver section showed congestion and necrosis of hepatic cells. **Conclusion:** Silver nanoparticles cause damage in liver and kidney tissues. **Recommendation:** Further study is needed for the effect of Ag NPs on the other tissues.

**Key words:** Nanoparticles, Silver nanoparticles, Albino male rat, liver and kidney.

### Introduction:

The use of nanotechnological products in human activities has been steadily increasing in recent years. Because of this, it is of vital importance to study the biological effect of various nanoparticles and nanocomposite materials, and especially their effects on animal and human organs. In this context, the number of commercial products comprising nanomaterials is

increasing. Among the commercially available nano-sized materials, silver nanoparticles are by far the most used nanocompounds [1] owing to its potent antimicrobial activity [2]. Indeed, silver nanoparticles (AgNPs) have been used in commercial products such as personal care, household and medical products, as well in textiles, and food products [3], and are known for their antimicrobial properties and

\*Assistant Lecturer, M.sc., Community Health Department, College of Health and Medical Technology/kufa, Foundation of Technical Education, Iraq

have been used in bandages, socks (to prevent foot infections), and laundry detergent [4, 5, 6, 7, 8]. Nanoparticle toxicity, including human health and environmental implications, is still considered not completely elucidated and relatively unexplored [9, 10, 11]. Concerning human health, studies have demonstrated that nanoparticles have toxic effects at the cellular, subcellular and biomolecular levels, such as genes and proteins [12, 13].

Major consumer goods manufacturers have already produced products that take advantage of the antibacterial properties of Ag NPs, despite concerns about safety using AgNPs. In daily life, people may encounter nanosilver-containing room sprays, laundry detergents, water purifiers, and wall paint [14, 15, 16]. Owing to an increasing number of medical applications for Ag NPs and the increased exposure associated with the widespread use of nanosilver, the toxicological and environmental issues related to nanosilver must be addressed [17]. In humans, it is well known that long-term ingestion of silver compounds can cause irreversible skin discoloration [18]. The permissible exposure limit recommended by the National Institute for Occupational Safety and Health is 0.01 mg/m<sup>3</sup> for all forms of silver [19]. In addition, among several metal nanoparticles, silver was found to be the most toxic to germ line stem cells [20]. The toxicity of AgNPs, however, also depends upon their surface chemistry [21].

[22] was reported that AgNPs are released into the aquatic environment during the washing process of silver-treated fabrics. Because silver is a soft white lustrous element, an important use of AgNPs is to give products a silver finish. Still, the remarkably strong antimicrobial activity is the major direction for development of nano-silver products. More than 800

consumer products that contain nanomaterials, roughly 30% are claimed to contain silver particles. An example is the addition of AgNPs to socks to kill the bacteria associated with foot odor. The revealed that the silver can easily leak into waste water during washing, thus potentially disrupting helpful bacteria used in waste-water treatment facilities, or endangering aquatic organisms in lakes and streams. *In vitro* studies have demonstrated that nano-silver has effects on DNA. Furthermore, nano-silver is incorporated in products such as water filters and washing machines; the presence of AgNPs in these products easily leads to a leakage into the aqueous environment and aqueous environmental species [22].

In the current study, such an approach is used to assess the potential toxic effects of Ag NPs on the kidney and liver tissues.

### Materials and Methods:

Ag NPs have been obtained from school of Applied Sciences, University of Technology, Iraq. Eighteen male albino rats were used by dividing them into three groups, each group comprise 6 rats. First group (control group) was given food and water like other groups by liberty. Second group was tail injected by (AgNPs) at concentration (35µm) at dose of (0.4 mg/kg. body weight/day). Third group was injected by (AgNPs) at concentration (35µm) at dose of (0.6 mg/kg. body weight/day) for 15 days. All animals were sacrificed at the end of experiment. The average weight of animals was ranged (170-200) gm; the age of mature male rats was four months.. The environmental conditions were strictly controlled with a temperature of 23±1C°, and a 12h light/ dark cycle.

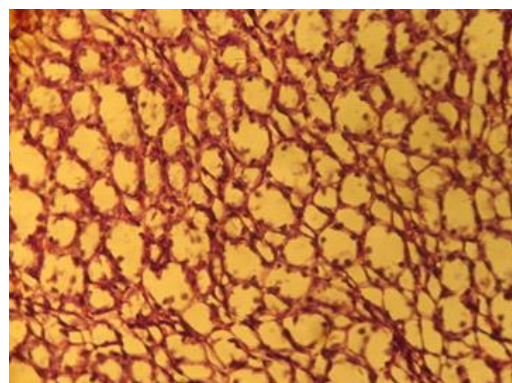
### Histopathology

Kidneys and liver were collected and fixed with 10% formalin,

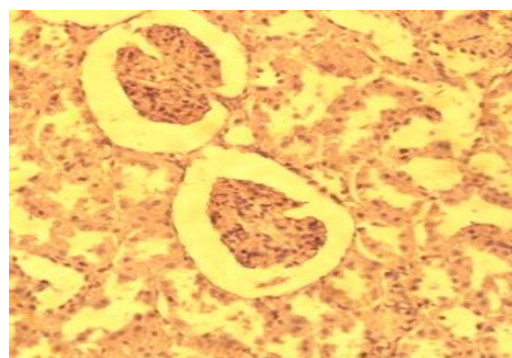
processed by paraffin method, cut at six micrometers in thickness by using rotary microtome and stained with Hematoxylin and Eosin (H&E) [23]. Sections were examined by histopathologist with Olympus Microscope (Japan). Photos were taken by digital camera (Sony-Japan 14 Megapixel).

### Results:

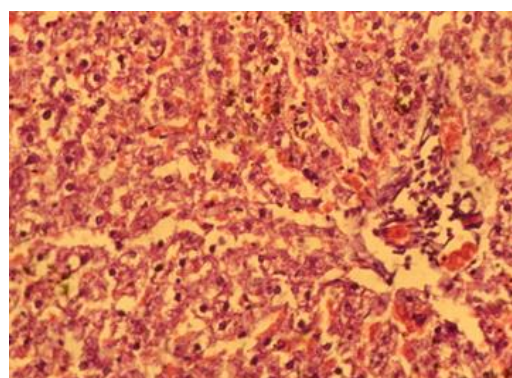
Histopathological changes of kidney and liver are as follows: Control group: kidney sections showed normal nephritic tubules and renal cortex. The liver sections showed normal hepatic portal tract, central vein and normal hepatocytes (Figures 1,2,3). Second group treated with Ag NPs (0.4 mg/kg. body weight/day); kidney medulla, reveals slight enlargement in collecting tubules and increase in interstitial tissue thickness, and the cortex showed shrinkage in renal glomeruli, necrosis and enlargement in the proximal convoluted tubules and distal convoluted tubules (Figures 4,5). Liver showed enlargement in the central vein and degeneration in the hepatic cells cytoplasm (Figure 6). Third group that treated with Ag NPs (0.6 mg/kg. body weight/day); kidney sections showed hyperplasia of the interstitial connective tissue of renal medulla with hemorrhages, renal cortex showed glomerulonephritis, Degenerative changes and necrosis in the proximal convoluted tubules and distal convoluted tubules (Figures 7,8). Liver section showed congestion and necrosis of hepatic cells, central vein enlargement (Figure 9).



**Fig.1. Rat kidney medulla, revealed collecting tubules (1), lined by simple cuboidal epithelium (2). H&E. 200X. (Control group)**

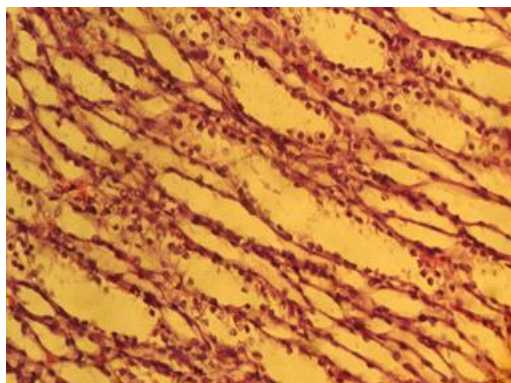


**Fig. 2. Rat kidney cortex, showed normal glomeruli (1), normal proximal convoluted tubules (2), normal distal convoluted tubules (3). H&E. 200X. (Control group)**

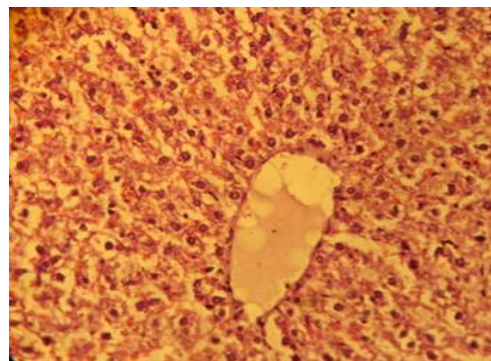


**Fig. 3. Rat liver lobule, showed normal picture of hepatic cord (1), and liver sinusoids (2), located between hepatic cords. H&E. 200X (Control group)**

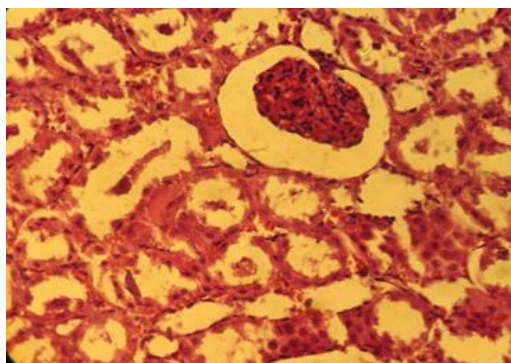




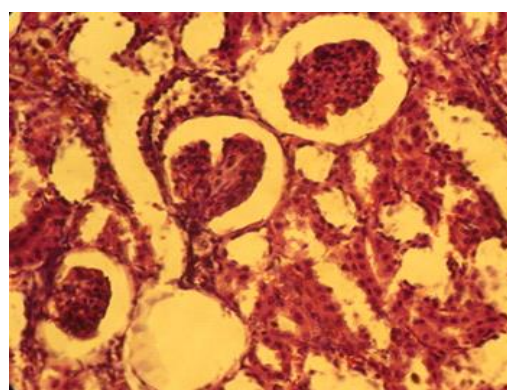
**Fig.4. Rat kidney medulla, revealed slight enlargement in collecting tubules (1) and increase in interstitial tissue thickness (2). H&E. 200X. (Second group)**



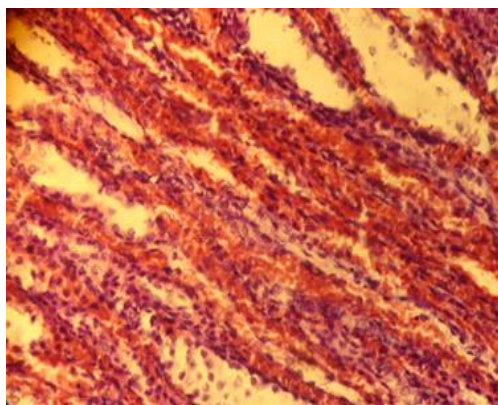
**Fig. 7 Appear rat kidney medulla, noticed hyperaplasia in the interstitial connective tissue (1) among the loops of Henle and collecting tubules with hemorrhage (2). H&E. 200X. (Third group)**



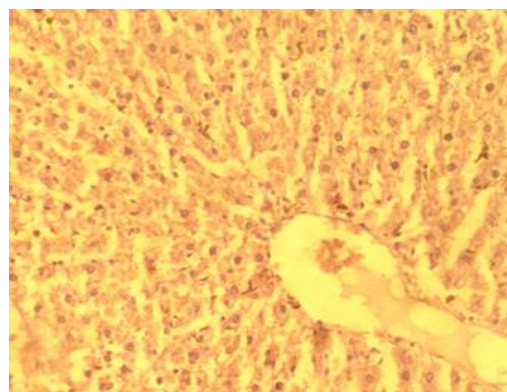
**Fig. 5. Rat kidney cortex, showed shrinkage in renal glomeruli (1), necrosis and enlargement in the proximal convoluted tubules (2) and distal convoluted tubules (3). H&E. 200X. (Second group)**



**Fig. 8. Rat kidney cortex showed glomerulonephritis (1). Degenerative changes and necrosis in the proximal convoluted tubules (2) and distal convoluted tubules (3). H&E.200X. (third group)**



**Fig. 6 Rat liver lobule, showed enlargement in the central vein (1) and degeneration in the hepatic cells cytoplasm (2). H&E. 200X. (second group)**



**Fig. 9. Rat liver lobule, showed central vein enlargement (1). Congestion and necrosis in hepatic cells (2). H&E.200X. (third group)**

**Discussion:**

The present study showed that nanosilver is able to induce changes in tissues of kidney and liver in Albino male rats.

**Conclusion:**

The silver nanoparticles have direct destructive effect on kidneys and liver. whether nano-sized or not, there are always the problems to humans health and environment.

**Reference:**

- 1-Ahamed M, Karns M, Goodson M, Rowe J, Hussain SM, Schlaager JJ, and Hong Y (2008). DNA damage response to different surface chemistry of silver nanoparticles in mammalian cells. *Toxicol Appl Pharm a col*, 233:404-410.
- 2- Durán N, Marcato PD, De Conti R, Alves OL, Costa FTM, and Brocchi M. (2010). Potential use of silver nanoparticles on pathogenic bacteria, their toxicity and possible mechanism of action. *J. Braz. Chem. Soc.* 21: 949–959.
- 3- U.S. Department of Health, Education, and Welfare: Report and Memoranda. NIOSH 1992, publication no. 92-100 .
- 4- Benn TM. and Westerhoff P (2008) Nanoparticle silver released into water from commercially available sock fabrics. *Environ Sci Technol* 42:7025–7026;
- 5- Dai TH, Tegos GP, Burkatovskaya M, Castano AP, and Hamblin MR (2009). Chitosan Acetate bandage as a topical antimicrobial dressing for infected burns. *Antimicrob Agents Chemother* 53: 393–400;
- 6- Duran N, Marcato PD, Alves OL, Souza GI, and Esposito E (2005). Mechanistic aspects of biosynthesis of silver nanoparticles by several *Fusarium oxysporum* strains. *J Nanobiotechnol* 3:8.
- 7- Impellitteri CA, Tolaymat TM, and Scheckel KG (2009). The speciation of silver nanoparticles in antimicrobial fabric before and after exposure to a hypochlorite/detergent solution. *J Environ Qual* 38:1528–1530.
- 8- Lu SY, Gao WJ, and Gu HY (2008). Construction, application and biosafety of silver nanocrystalline chitosan wound dressing. *Burns* 34:623–628).
- 9- Nel A, Xia T, Madler L, and Li N. (2006). Toxic potential of materials at the nanolevel. *Science* 311: 622–627.
- 10- Lewinski N, Colvin V, and Drezedk R. (2008). Cytotoxicity of nanoparticles. *Small* 4: 26 49.
- 11- Ju-Nam Y, and Lead JR. (2008). Manufactured nanoparticles: an overview of their chemistry, interactions and potential environmental implications. *Sci. Total Environ.* 400: 396–414.).
- 12- Gurr JR, Wang AS, Chen CH and Jan KY. (2005). Ultrafine titanium dioxide particles in the absence of photoactivation can induce oxidative damage to human bronchial epithelial cells. *Toxicol.* 213: 66–73.
- 13- Chi Z, Li R, Zhao L, Qin P, Pan X, Sun F and Hao X. (2009). A new strategy to probe the genotoxicity of silver nanoparticles combined with cetylpyridine bromide. *Spectrochim. Acta, Part A* 72: 577–581.
- 14- Cioffi N, Ditaranto N, Torsi L, Picca RA, De Giglio E, Sabbatini L, Novello L, Tantillo G, Bleve-Zacheo T and Zambonin PG (2005). Synthesis, analytical characterization and bioactivity of Ag and Cu nanoparticles embedded in poly-vinyl-methyl-ketone films.

- Anal Bioanal Chem* 382:1912–1918.
- 15- Kumar A, Vemula PK, Ajayan PM and John G (2008). Silvernanoparticle- embedded antimicrobial paints based on vegetable oil. *Nat Mater* 7:236–241.
  - 16- Sung JH, Ji JH, Yoon JU, Kim DS, Song MY, Jeong J, Han BS, Han JH, Chung YH, Kim J, Kim TS, Chang HK, Lee EJ, Lee JH and Yu IJ (2008). Lung function changes in Sprague-Dawley rats after prolonged inhalation exposure to silver nanoparticles. *Inhal Toxicol* 20:567–574.
  - 17- Larissa, V.; Stebounova, Andrea Adamcakova-Dodd; Jong Sung Kim; Heaweon Park; Patrick T O'Shaughnessy; Vicki H Grassian and Peter S Thorne (2011). Nanosilver induces minimal lung toxicity or inflammation in a subacute murine inhalation model. *Particle and Fibre Toxicol.*, 8:5. [IVSL]
  - 18- Greene, RM. and Su, WP.( 1987). Argyria. *Am Fam Physician*, 36:151-154.
  - 19- Braydich-Stolle, L.; Hussain, S.; Schlager, JJ. and Hofmann, MC.(2005). In vitro cytotoxicity of nanoparticles in mammalian germline stem cells. *Tox sci*, 88:412-419.
  - 20- Ahamed, M.; Karns, M.; Goodson, M.; Rowe, J.; Hussain, SM.; Schlaager, JJ. and Hong, Y.( 2008). DNA damage response to different surface chemistry of silver nanoparticles in mammalian cells. *Toxicol Appl Pharm a col*, 233:404-410.
  - 21- Benn, TM and Westerhoff, P.( 2008). Nanoparticle silver released into water from commercially available sock fabrics. *Environ Sci Technol*, 42:4133-4139.
  - 22- Susan, W.P.; Wijnhovenl, W. J.G.M.; Peijnenburg; Carla, A. H.; Werner, I. H.; Agnes, G. O.; Evelyn, H.W. H.; Boris, R.; Julia, B.; Ilse, G.; Dik, V. D. M.; Susan, D.; Wim, H. D. J.; Maaike, V. Z.; Adrie'anne, J.A.M. S. and Robert, E. G.( 2009). Nano-silver \_ a review of available data and knowledge gaps in human and environmental risk assessment. *Nanotoxicol.*, 3(2): 109-138.
  - 23- L. Vacca (1985). Laboratory Manual of Histochemistry (1<sup>st</sup> ed.), Raven Press: New York, USA.

## تأثير جرع مختلفة من جزيئات دقائق الفضة على أنسجة الكلية وكبد ذكور الجرذان البيض. دراسة نسيجية -وظيفية

رقية علي سلمان\*

\*مدرس مساعد، قسم صحة المجتمع، كلية التقنيات الصحية والطبية /كوفة، هيئة التعليم التقني

### الخلاصة:

**الهدف:** اجريت الدراسة للتقصي عن تأثير الجزيئات الدقيقة للفضة على انسجة الكلية والكبد .  
**المنهجية:**الصفات البصرية والتركيبية للفضة تم التقصي ونتج عنها جزيئات دقيقة تمتلك معدل قياس للجزيئة حوالي (300) نانوميتر .استعمل ثمانية عشر جرذا ، قسمت الى ثلاث مجاميع، تضم كل مجموعة ست جرذان، المجموعة الاولى هي مجموعة السيطرة(الضابطة )اطيت عليقة وماء حد الاكتفاء .حقنت المجموعة الثانية بالجزيئات الدقيقة للفضة عن طريق اوريد الذيل بجرعة (0.4) مليغرام/كيلوغرام من وزن الجسم يوميا .حقنت المجموعة الثالثة بالجزيئات الدقيقة للفضة وبجرعة (0.6) مليغرام/كيلوغرام من وزن الجسم يوميا وعلى مدى خمسة عشر يوم .تم التضحية بالحيوانات في نهاية التجربة .أخذت نماذج نسيجية من الكلية والكبد، وثبتت في محلول الفورمالين بتركيز (10%) تم تنفيذ التحضيرات النسيجية على النماذج لحين اجراء عملية التلوين بملون الهيماتوكسلين-أبوسين، ولوحظت التغيرات النسيجية -المرضية على انسجة الكلية والكبد .**النتائج:** أظهرت الدراسة النسيجية-المرضية، تأثيرا ضارا من جراء استعمال الجزيئات الدقيقة للفضة على كلية وكبد الجرذان، لمجموعة المعاملة التي جرعت بـ(0.4)مليغرام/كيلوغرام من وزن الجسم يوميا، لوحظ توسع للنبيبات الجامعة في المقاطع النسيجية للكلية وزيادة في النسيج البيني للب الكلية، وتنخر وتوسع في النبيبات الدانية والقاصية .اما المقاطع النسيجية للكبد، شوهد توسع في الوريد المركزي وتنكس في الخلايا الكبدية .وفي مجموعة الجرذان المعاملة بـ (0.6)مليغرام/كيلوغرام من وزن الجسم يوميا، لوحظ فرط نمو في النسيج الضام البيني للب الكلية مع نزف، كما شوهدت تغيرات تنكسية وتنخر في النبيبات الملتوية الدانية والقاصية، وفي المقاطع النسيجية للكبد لوحظ تنخر واحتقان في الخلايا الكبدية .**الاستنتاج:** سببت الجزيئات الدقيقة للفضة تحطم في أنسجة كل من الكلية والكبد .**التوصيات:**نحتاج الى دراسة مستقبلية لمعرفة تأثير الجزيئات الدقيقة للفضة على الأعضاء الاخرى.