

Pathological effects of Ochratoxin A in brain, heart and lung of chicks

F. A. Jameel

College of Veterinary Medicine\ University of Baghdad

Abstract

This study involved investigation on the toxic effects of Ochratoxin A in various internal organs of chicks (brain, heart and lung). The study showed histopathological effect of Ochratoxin A in group 1 (which were given crude Ochratoxin A orally) and in group 2 (which were fed contaminated feed with toxigenic *Aspergillus ochraceus*). The histopathological sections of the brain especially cerebrum showed perivascular and perineuronal edema and shrinkage of many neurons due to degeneration with central chromatolysis of the others with massive sub meningeal hemorrhage. Cerebellum tissue sections showed degeneration of purkinge cells. The histopathological sections of heart showed edema and infiltration of heterophils between the muscle fibers and the blood vessels of myocardium undergo hypertrophy of tunica media with proliferation of endothelial cells. Other sections of heart showed thickening of pericardium, edema and infiltration of inflammatory cells and congestion. The histopathological sections of the lung showed severe dilation and congestion of pulmonary arteries with large areas of emphysema.

التأثيرات المرضية لسموم الاوكراتوكسين A في دماغ، قلب ورتة أفراخ الدجاج

فدوى عبد الرزاق جميل

كلية الطب البيطري/ جامعة بغداد

الخلاصة

تضمنت هذه الدراسة التحري عن التأثيرات السمية للاوكراتوكسين A في عدد من الأعضاء الداخلية لأفراخ الدجاج والتي شملت (الدماغ، القلب والرئة). أظهرت هذه الدراسة التأثيرات المرضية النسيجية للاوكراتوكسين A في المجموعة الأولى (التي أعطيت سم الاوكراتوكسين A الخام عن طريق الفم) وفي المجموعة الثانية (التي أعطيت عليقة ملوثة بفطر *Aspergillus ochraceus*)، في الدماغ وخاصة في المخ حيث تميزت بوجود خبز حول الأوعية الدموية والعصبونات وانكماش في العديد من الخلايا العصبية نتيجة حدوث التنكس، أما الخلايا العصبية الأخرى فقد تعرضت إلى انحلال الكروماتين المركزي مع نرف شديد تحت السحايا، وفي نسيج المخيخ اظهر وجود تنكس في خلايا بركنجي ولوحظ في القلب وجود خبز وارتشاح خلايا المغايرات بين ألياف عضلات القلب مع تضخم في الغلالة الوسطى للأوعية الدموية وتكاثر في الخلايا البطانية، كما أظهرت نتائج مقاطع القلب النسيجية الأخرى تثخن في التامور الجداري نتيجة حدوث الخبز وارتشاح الخلايا الالتهابية مع الاحتقان. أما في الرئة فقد أظهرت المقاطع المرضية النسيجية حدوث توسع شديد مع احتقان في الشرايين الرئوية مع منطقة واسعة من النفاخ الرئوي.

Introduction

Ochratoxin A (OTA) is natural secondary metabolite produced by *Aspergillus ochraceus* and other moulds, especially *Penicillium verrucosum* (1). OTA is found essentially in cereals, dried fruits, cocoa and also in the blood of animals and humans after consumption of contaminated food (2). OTA is a structural analogue of phenylalanine and contains a chlorinated dihydroisocoumarin moiety. OTA inhibits protein synthesis by competition with phenylalanine in the aminoacylation reaction of phenylalanine-tRNA (3,4). OTA also induces oxidative damage by enhancing lipid peroxidation (5). OTA shown to be nephrotoxic, teratogens, immunosuppressive, genotoxic, mutagenic and carcinogenic in rodents (6). Therefore the aim of present study was to know the other toxic effects of OTA in the brain, heart and lung in chicks.

Materials and Methods

- **Organism:** The fungus used in this study was *Aspergillus ochraceus* isolated from maize, the identification of the fungus based on the macroscopic appearance of the fungus on sabouroud dextrose agar and by the microscopic appearance. The fungus *Aspergillus ochraceus* have been tested to verify their ability for (OTA) production by:
 1. Preparation of spore suspension according to (7).
 2. Production of (OTA) on (natural substrate) maize which include:
 - 50 g of grinded maize was taken then placed in conical flask 500 ml.
 - 11 ml of distilled water was added to the weighted maize in order to increase the moisture content to 28% to obtain 0.95 water activity which estimated according to (7).
 $X=W(Y-a)/100-Y$, where:-
X=water to be added (ml).
Y=required moisture content.
 $a=50(28-13)/100-28=11$.
 - The flasks were sterilized for 20 minutes at 121c° under 15pound/inch².
 - Each flasks was inoculated with 1 ml of spore suspension 1×10^7 spore of *Aspergillus ochraceus* and incubated for (7) days at 25c°.
 - The flasks were shaken every day then dried in oven at 60 c° for 24 h.
- 3. Extraction and quantification of (OTA) by thin layer chromatography (TLC) according to the method of (8).
- **Experimental study:** Fifteen Birds (one day old) were divided randomly into three groups (5 birds for each group)
 1. Group (1) →Birds were given daily orally crude (OTA) as (1ml) contains 0.5µg/g(b.w)for (21)days.
 2. Group (2) →Birds were fed daily on diet contaminated with toxigenic *Aspergillus ochraceus* for (21) days.
 3. Group(3)→control group.

The histopathological sections prepared according to (9). The specimens used were brain, heart and lung

Results and Discussion

The results of histopathological studies in group (1) which are similar to the results of histopathological studies in group (2) and showed The following pathological changes:

- **Brain:**

Cerebrum: Perivascular and perineuronal edema Fig. (1). Shrinkage of many neurons due to degenerative and central chromatolysis of the others Fig. (2). Other sections showed massive sub meningeal hemorrhage Fig. (3).

Cerebellum: Tissue sections showed degeneration of purkinge cells Fig. (4).

The perivascular and perineuronal edema which showed in cerebrum may be related to the increase in the permeability of the blood brain barrier leading to disturbances in the blood dynamics and escape of fluids to the nervous tissue. The edematous changes in the brain with hemorrhage might be due to the vascular damages induced by OTA (10) which are considered to be typical for later stages of this nephropathy. A disturbance of fibrinogen in the blood and an increase in the prothrombin time found in OTA treated animals (11,12) could also contribute to the hemorrhages observed. The degenerative of neurons and purkinge cells of cerebellum represent ischemic changes resulting from injury of blood vessels (13). The perivascular and perineuronal edema and degeneration with sub meningeal hemorrhage which agreed with (10,14,15). In current study it was found that brain may be a primary target of toxicity due to (OTA), this result agreed with (16) and (OTA) accumulated in the whole brain as function of time and (OTA) induced modification of free amino acid concentrated in the brain mainly tyrosine and phenylalanine (16).

- **Heart:**

Myocardium: Sections showed edema and infiltration of heterophils between the muscle fibers Fig.(5). The blood vessels of myocardium undergo hypertrophy of tunica media and proliferation of endothelial cells (hyperplasia) Fig.(6). Thickening of pericardium was due to edema and infiltration of inflammatory cells Fig. (7). Other sections showed congestion and sub epicardical hemorrhage. The myocardial edema with congestion and hemorrhage which agreed with (10,17). In the study (18) which did not observe any gross change in the heart of broiler chicks fed (OTA), however mild edema of inter muscular bundle spaces a long with infiltration of mono nuclear cells in the heart were observed microscopically this result due to higher dose of (OTA). The hyperplasia of endothelial cells lining the blood vessels was attributed to continuous injury causing damage and due to irritation of free amino acid (16).

- **Lung:** Tissue sections showed severe dilation and congestion of pulmonary arteries with large areas of emphysema Fig. (8). The pulmonary emphysema occurred due to alveolar wall destruction and airspace enlargement and these results which agreed with (19).

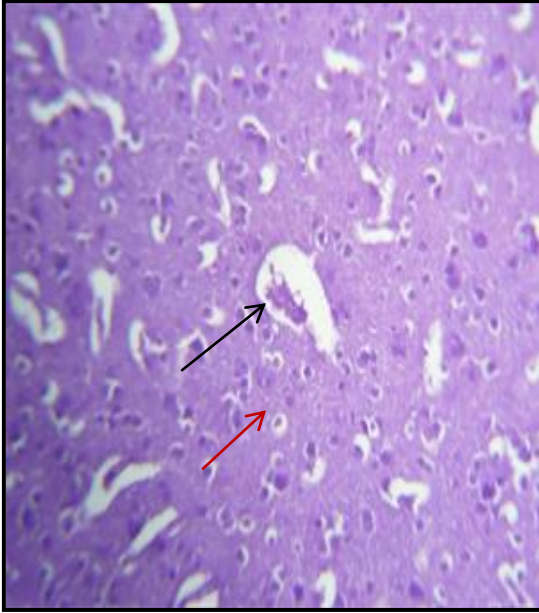


Fig. (1) Histopathological section of cerebrum of chickens in group(1) and in group (2) showing perivascular (→) and perineuronal edema (→) (H and E) 40x.

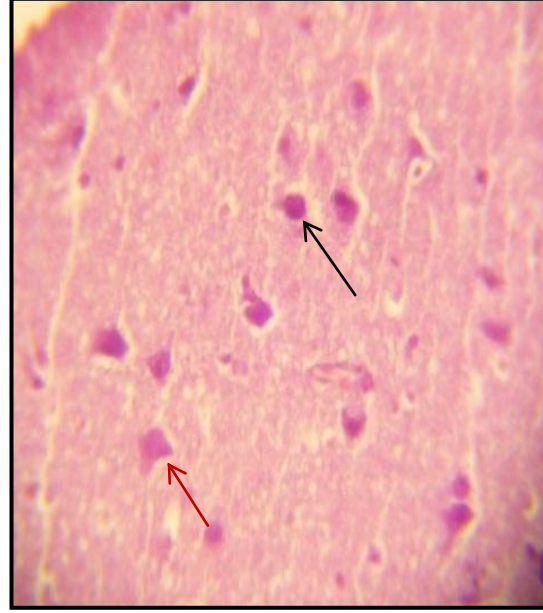


Fig. (2) Histopathological section of cerebrum of chickens in group (1) and in group (2) showing shrinkage of many neurons due to degeneration (→) and central chromatolysis of the other (→) (H and E) 40x.

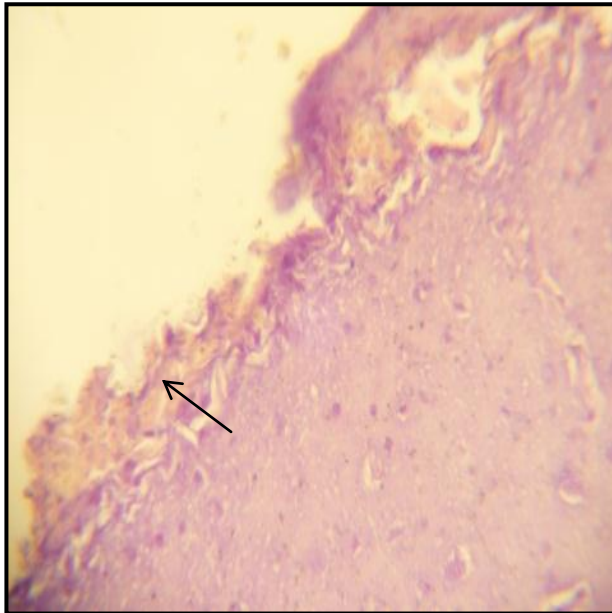


Fig. (3) Histopathological section of cerebrum of chickens in group (1) and in group (2) showing massive sub meningeal hemorrhage (→) (H and E) 40x.

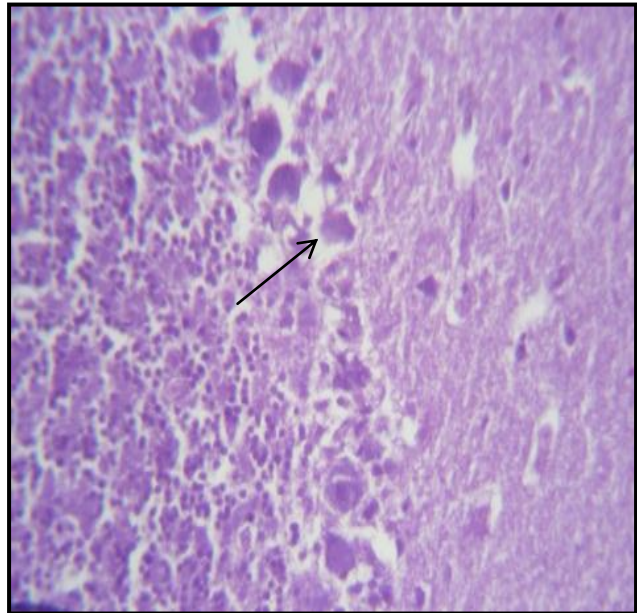


Fig. (4) Histopathological section of cerebellum of chickens in group (1) and in group (2) showing degeneration of Purkinje cells (→) (H and E) 40x.

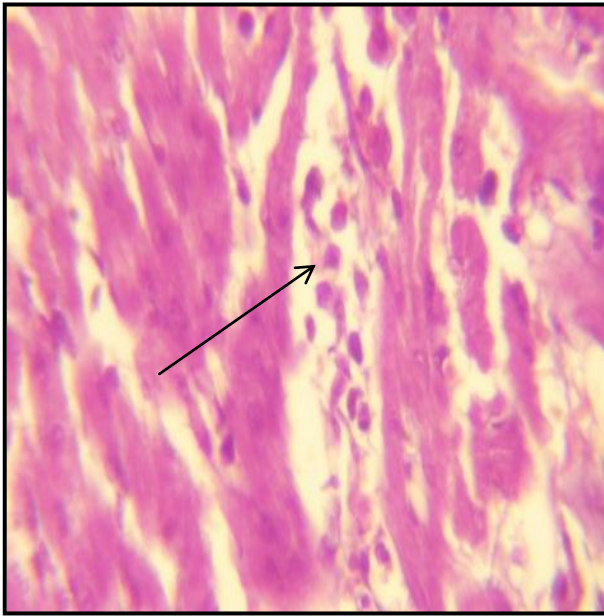


Fig. (5) Histopathological section of myocardium of chickens in group (1) and in group (2) showing edema and infiltration of heterophils between the muscle fibers (→) (H and E) 40x.

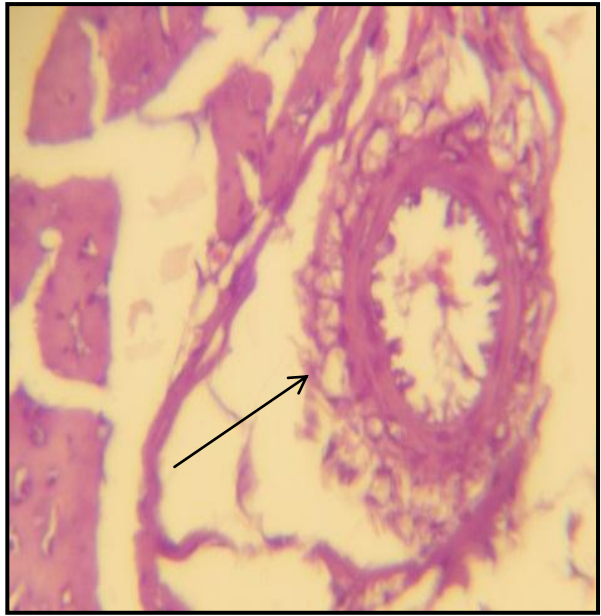


Fig. (6) Histopathological section of myocardium of chickens in group (1) and in group (2) showing hypertrophy of tunica media and proliferation of endothelial cells (→) of myocardial blood vessel (H and E) 40x.

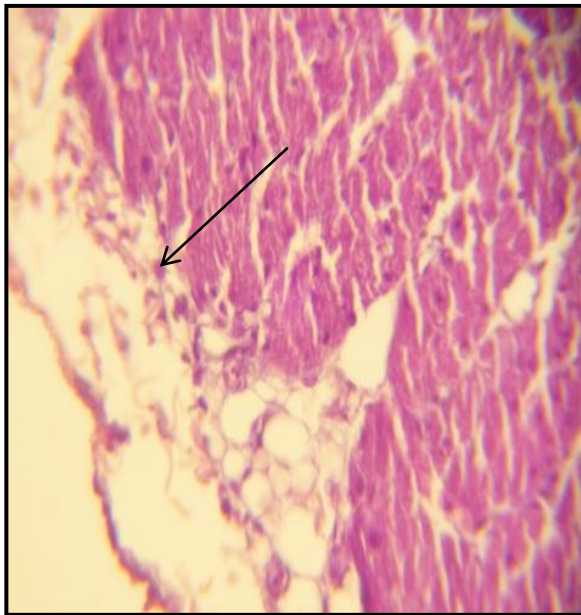

Fig. (7) Histopathological section of Heart of chickens in group (1) and in group (2) showing thickening edema and infiltration of inflammatory cells(→) (H and E) 40x.

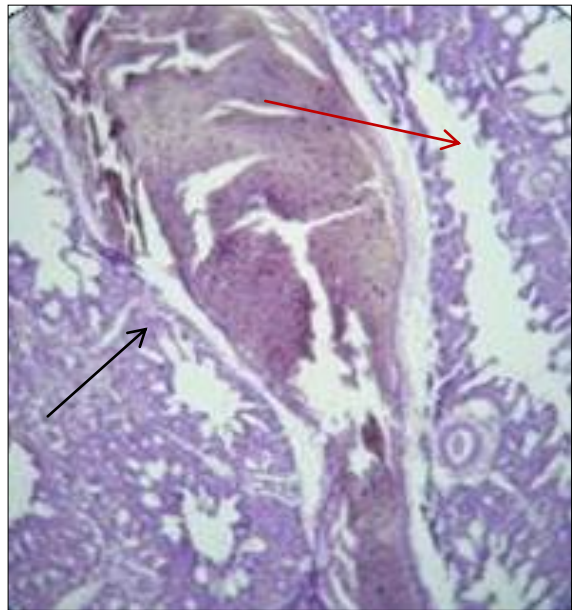


Fig. (8) Histopathological section of lung of chickens in group (1) and in group (2) showing dilation and congestion of pulmonary artery (→) with emphysematous area(→) (H and E) 40x.

References

1. Van der merwe, K. J.; Steyn, P. S. & Fourie, L. (1965). Mycotoxins. part II. The constitution of J. Chem., Soc. PP. 7083-7088.
2. Krogh, P. (1987). Ochratoxin. In: Mycotoxin in food, edited by krogh, P. Academic press. London, PP. 97-121.
3. Creppy, E. E.; Eoschenthaler, R. & Dirheimer, G. (1984). Inhibition of protein synthesis in mice by Ochratoxin A and its prevention by phenylalanine. Food Chem. Toxicol., 22: 883- 886.
4. Creppy, E. E.; Iugnier, A. A. J.; Fasolo, F.; Lteller, K.; Rosch enthaler, R. & Dirheimer, G. (1979). In vitro inhabitation of yeast phenylalanyl- tRNA syn-thetase by Ochratoxin A interactions, 24:257-262.
5. Rahimtula, A. D.; Bereziatj, C.; Bussacchini-Griot, V. & Bartsch, H. (1988). Lipid peroxidation as a possible cause of Ochratoxin toxicity. Biochem. Pharmacol., 37:4469-4477.
6. Belmadani, A.; Tramu, G.; Betbeder, A. M.; Steyn, P. S. & Creppy, E. E. (1998). Regional selectivity to Ochratoxin A, distribution and cytotoxicity in rat brain. Archives of Toxicology, 72: 656- 662.
7. Faraj, M. K. (1990). Regulation of mycotoxin formation in zea mays. Ph.D. Thesis, Department of Bioscience and Biotechnology university of Strathclyde, Glasgow. U.K.
8. Blazer, I.; Boddanic, C. and Pepijujak, S. (1978). Rapid thin layer chromatogram- phic method for determining Aflatoxin B1, Ochratoxin A, and Zearalenone in corn. J. Assoc. Off. Anal. Chem., 61:584-585.
9. Luna, L. G. (1968). Manual of histological staining methods. 3rd ed., MC Graw itll Book, company. New York.
10. Stoycho D. S. (2010). Studies on carcinogenic and toxic effects of Ochratoxin A in chicks. Toxins Journal.
11. Doerr, J. A.; Huff, W. E.; Hamilton, B. P. & Lillehoj, E. B. (1981). Sever coagulopathy in young chickens produced by Ochratoxin A. Toxicol. Appl. Pharm., 59:157-163.
12. Prior, M. C. & Sisodia, C. S. (1978). Ochratoxicosis in white Leghorn hens. Poult. Sci., 57:619-623.
13. Donald, M.; Carlton, W. & Zachary, F. (2001). Special Veterinary Pathology. 3rd ed. London, Mosby, Inc. P.113.
14. Prasanna Krishnamurthy, A. K.; Sharma, P. D. W. & Tandan, S. K. (2006). Behavioural and neurotoxic effects in wistar rats. induced by low doses of Ochratoxin A. Toxicol. Int., 2(13): 99-104.
15. Shenouda, M. G.; Eman, M. H. & Azzat, B. A. (2006). Effect of dietary honey on intestinal microflora and toxicity of mycotoxins in mice. BMC complement Altern. Med., 6:6.
16. Peter, G. M. & Christophe, C. N. (2010). Pathological outcomes in kidney and brain in male fischer rats given dietary Ochratoxin A, commencing at one year of age. Toxins Journal.
17. Belmadani, A.; Betbeder, A. M. & Creppy, E. E. (2011). Subchronic effects of Ochratoxin A on young adult rat brain and partial prevention by aspartame, asweetener. Toxicology and Applied hygiene., 30(3).
18. Mohiuddin, S. M.; Reddy, M. V. & Ahmed, S. R. (1992). Studies on Ochratoxicosis in broiler chicks. Indian Vet. J., 69: 1011-1014.
19. Huseyin, O.; Gulsen, A. & Nurten, O. (2004). Protective role of melatonin in Ochratoxin A toxicity in rat heart and lung. J. of Appli. Toxicol., 24: 505-512. (Abstract).