

# Comparative study between ultrasound findings and intra-operative findings in non-traumatic Abdominal Pain:

Basim R. Gadban\* FICMS

## Summary:

**Background:** acute abdominal pain is one of the most common presentations in surgical wards. Ultrasound has been grown in popularity as an easy, quick and non-invasive imaging the abdomen. US is very useful means of non-invasively, modality for assessment of acute abdominal pain.

**Objective:** Study of the most common acute none traumatic abdominal diseases in adult patients admitted to Baghdad Teaching Hospital in department of surgery .Correlate the operative findings with sonographic features as to make the initial diagnosis of the diseases included in this study. Compare the diagnostic yield of abdominal ultrasound with that of computed tomography (CT).

**Methods :**The present study included eighty nine consecutive adult patients with non traumatic abdominal pain as their chief complaint were admitted in the department of surgery at Baghdad Teaching Hospital during the period from April 2009 to January 2010.Ultrasound was performed in all patients in addition to CT scan as the first techniques

**Results:** The results showed that acute non traumatic abdominal pain was more frequently in female patients(73.46%) than male (26.53%).Gall bladder disease was the most common cause of upper abdominal surgeries (n= 45). No differences were observed between surgeries for intestinal obstruction or acute appendicitis(n=6) at  $P < 0.05$  High accuracy of using of US, CT scan in the diagnosis of acute abdominal pain ,the compatibility with the operative finding was %89.79 , 83.33% respectively

**Conclusion:** Sonography should be the first imaging technique in adult patients for the diagnosis of acute abdominal pain. CT scan should be used as a complementary study for suspected abdominal cases.

**Key ward:** abdominal pain, Acute, diagnosis, ultrasound

*Fac Med Baghdad  
2011; Vol. 53, No. 4  
Received Sept., 2011  
Accepted Dec., 2011*

## Introduction:

Acute abdomen refers to presence of severe abdominal pain developing suddenly or over a period of several hours. (1).The sudden onset of severe abdominal pain requiring emergency medical or surgical treatment and can be a symptom of various disease processes. Some of these processes can be life-threatening and several of these require rapid diagnosis and surgical intervention to avoid significant morbidity and mortality. (2) .the diseases were divided into four subdivisions: Lower abdominal pain: Acute Appendicitis, Mesenteric adenitis, Inflammatory bowel disease Gastroenteritis and Diverticulitis Upper abdominal pain: Cholecystitis, peptic Ulcer perforation, and Pancreatitis. Gynecological emergencies: Ectopic pregnancy ,Corpus luteum rupture ,Tubo ovarian abscess ,Pelvic inflammatory disease ,Endometriosis Pelvic, adhesions and Ovarian cyst ICU patient pathology: A calculus cholecystitis , pancreatitis and Mesenteric ischemia (2) Abdominal US has been largely used in clinical practice and in protocol of investigation of acute abdomen pain .It has revolutionized the diagnosis of many intra-abdominal conditions. (3). Inappropriate use of ultrasound in the assessment of acute abdominal pain can lead to an increase in the workload of the personnel involved, prolonged inpatient stay, possible delay in treatment, and increased hospital costs (4) CT scan has been

shown to increase the referring physician's level of certainty in the diagnosis, reduce hospital admission rates, and help guide the therapeutic strategy, including surgical intervention (5, 6)

## Patients & methods:

Eighty nine consecutive adult patients were admitted to surgical wards in Baghdad Teaching Hospital in Department of Surgery with non traumatic abdominal pain as their chief complaint during a period of April 2009 to January 2010. Provisional diagnosis made depending on history of the patient and physical examination .Ultrasound was performed to all patients as initial diagnostic tool, US and CT scan were done for these patients. All patients included in this study had abdominal surgeries and divided into three groups based on the site of the surgery as the following: Upper abdominal surgeries: for gall bladder disease(Cholecystitis ,Choletolithiasis) complicated hydiated cyst, obstructive jaundice ,spherocytosis, volvulus of stomach ,cancer of esophagus, simple hepatic cyst lower abdominal surgeries for intestinal obstruction ,retroperitoneal tumor ,liposarcoma , acute Appendicitis ,pelvic teratoma, colorectal carcinoma.pelvi-ureteric obstruction Gynecological emergencies :ovarian tumor and Pelvic Endometriosis, Statistical AnalysisParametric data were statistically analyzed using Fischer Exact Probability test at significant level  $P < 0.05$ .

\*Baghdad Teaching Hospital

# Results:

Acute non traumatic abdominal pain was more frequent in female patients 72 (73.46%) than male 26 (26.53%). In this study no significant difference observed between male and female age (Female mean  $\pm$  SE, Male mean  $\pm$  SE,  $33.38 \pm 3.2$ ) Table (1) shows the final diagnosis following surgeries, gall bladder disease was most frequent among upper abdominal surgeries (n= 45) (figure 1). Statically, no significant differences was observed between intestinal obstruction and acute appendicitis (n=6) that tabulated under lower abdominal disease at  $P < 0.05$  using Fischer Exact Probability test (figure 2) Regularly, gynecological emergencies, final diagnosis established that ovarian tumors were more frequent than Endometriosis pelvic at  $P < 0.05$  using Fischer Exact Probability test (figure 3) Table( 2) showed high accuracy of US, CT scan in the diagnosis of the exact cause of abdominal pain , the compatibility with the operative finding was %89.79 , 83.33% respectively. Of the patients studied (n=100%) using Fischer Exact Probability test (at  $P < 0.05$ )

**Table (1) distribution of abdominal diseases and number of cases as diagnosed by operative**

1-Upper abdominal pain	No.
Gall bladder disease	45 a
hydrated cyst	4 c
Obstructive jaundice	6 b
Spherocytosis	2 c
volvulus of stomach	1 c
cancer of esophagus	2 c
acute nephritis	3 c
simple hepatic cyst	2 c
Sum	65
2-Lower abdominal diseases	No
intestinal obstruction	6a
retroperitoneal tumor	4b
Liposarcoma	2c
acute Appendicitis	6a
pelvic teratoma	1c
colorectal carcinoma	4b
pelvi-ureteric obstruction	1c
Sum	24
3-Gynecological emergencies	No
ovarian tumor	7a
Endometriosis Pelvic	2b
Sum	9

## surgeries

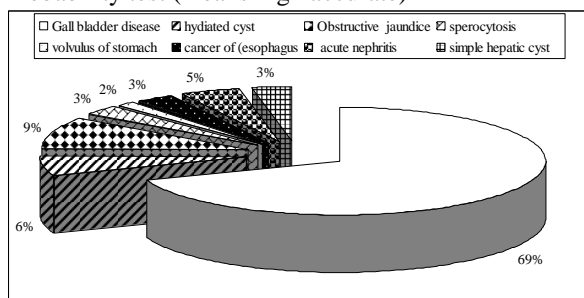
a, b,c: insufficient different between similar litter within the same group using Fischer Exact Probability test at  $P < 0.0$

a = high frequency, b= moderate frequency, c= low frequency

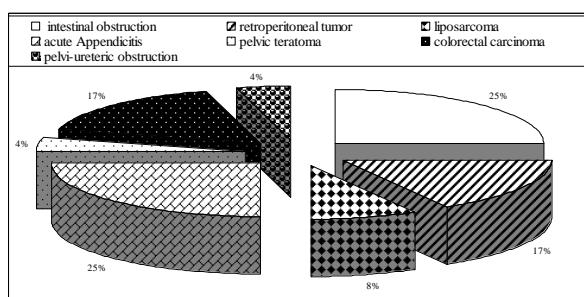
**Table (2) Compatibility between operative finding of the studied patients and image techniques included in this study.**

Compatibility between US and operative finding - n (%)	88 (89.79)*
Compatibility between CT and operative finding - n (%)	5 (83.33)*
Compatibility between US and CT - n (%)	3 (50)

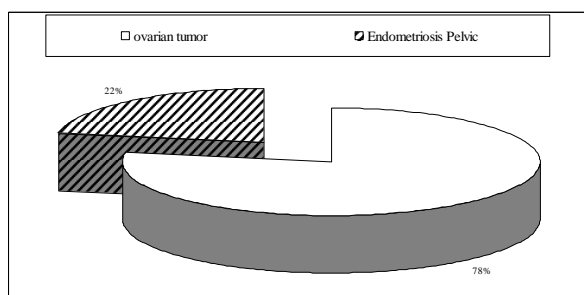
\* Significant at  $P < 0.05$  using Fischer Exact Probability test (means high accurate)



**Figure (1) chart showing the frequency distribution of upper abdominal pain of the patients studied.**



**Figure (2) chart showing the frequency distribution of lower abdominal pain of the patients studied**



**Figure (3) chart showing the frequency distribution of Gynecological emergencies of the patients included in this study.**

### Discussion:

The accurate clinical assessment of acute abdominal pain remains one of the more challenging areas of medicine. The variety of conditions that require emergent medical management, and often surgical management, vary widely in clinical presentation and physical examination (4) Diagnosis of many acute abdominal conditions relies on a good history and physical examination and the appropriate use of radiological investigations. (8). There is no single radiological test that is uniformly effective in identifying the cause of acute abdominal pain (9). Various factors, including age, sex and the suspected clinical diagnosis determine the choice of radiological investigation (9) Ultrasound is being used increasingly in the assessment of acute non-traumatic abdominal pain as it is non-invasive and does not carry

the risk of radiation. However, the inappropriate use of ultrasound can lead to a delayed or incorrect diagnosis, more work for the personnel involved, and increased hospital costs (3) The results of this study suggested that ultrasound is useful in the investigation of patients with acute non-traumatic abdominal pain. Other previous study suggested that the yield of ultrasound diagnosis of abdominal pain is significantly higher in patients with localised abdominal pain and tenderness (10) Gall bladder diseases were diagnosed in our study in 45 patients that was proved during surgery, the result was in agreement with Raman et al (10) who documented that ultrasound is considered the imaging study of first choice for the assessment of suspected gallbladder disease. It is the imaging modality of choice for visualization of gallstones (cholelithiasis). The most sensitive criteria for diagnosis of acute cholecystitis on ultrasound is the presence of gall stones in association with focal gall bladder tenderness (11) Gupta et al (1) documented in study of patients with non-traumatic acute abdominal pain that US is especially valuable in diagnosing hepatobiliary pathology and gynaecological conditions. However, its value in other scenarios, such as suspected acute appendicitis, remains controversial (12) In a retrospective study of 1000 patients with nontraumatic acute abdominal pain, Ahn et al (13) concluded that abdominal radiographs are not sensitive in the evaluation of adult patients with nontraumatic abdominal pain other study by Malone (14) suggested that CT is a very accurate in the diagnosis of common disorders such as acute appendicitis, renal colic, and diverticulitis. The present study documented that Ultrasound with CT scan showed high accuracy in the diagnosis of the exact cause of abdominal pain in patients studied, the result was agreement with Abdul Khair et al (15) Andrew et al (4) documented that any examination that would be substituted for US as the initial imaging study in patients with acute abdominal pain should have many characteristics: It should be more accurate than US and equally as fast in the diagnosis of common abdominal processes (16). It should require no particular preparation, (17). Ideally it would involve equal or less radiation exposure to the patient (18).

### References:

- 1- Gupta, K.; Bhandari, RK.; Chander, R. Comparative study of plain abdomen and ultrasound in non-traumatic acute abdomen *Gastrointestin.radiol.* 2005; 5(1) 109-115.
- 2- Smith, J.T.; Mbchb, M.; and Parachemant, C. The role of imaging in the management of adults with non-traumatic acute abdominal pain. 2009; vol. 21 : 1-19
- 3- Walsh P.F, Crawford D and Crossling F.T. The value of immediate ultrasound in acute abdominal conditions: a critical appraisal. *Clin Radiol* 1990; 42:47-9.

- 4- Andrew B.;M.;Michael J. Lane;. Robert T. G.;.Harry A.;Claypool , S. K.;Douglas , S. K. and Jonathan E. T.. Nontraumatic Acute Abdominal Pain: Unenhanced Helical CT Compared with Three View Acute Abdominal Series *Radiol.* 2005 ; 237:114-122.
- 5- Siewert B, Raptopoulos V, Mueller M.F, Rosen M.P and Steer M. Impact of CT on diagnosis and management of acute abdomen in patients initially treated without surgery. *AJR Am J Roentgenol*; 1997; 168:173–178.
- 6- Rosen MP, Sands D.Z, Longmaid HE , Reynolds K.F, Wagner M, and Raptopoulos V .Impact of abdominal CT on the management of patients presenting to the emergency department with acute abdominal pain. *AJR Am J Roentgenol* 2000; 174:1391–1396.
- 7- SPSS 14: “Statistical Package for Social Science, SPSS for windows Release 14.0.0, 12 June, 2006.” Standard Version.
- 8- Bohner H,Yang Q and Franke, C. Simple data from history and physical examination help to include bowel obstruction and to avoid radiographic studies in patients with acute abdominal pain. *Eur J Surg*; 1998;164:777–84
- 9- Mayo-Smith WW. Imaging the patient with acute abdominal pain: current concepts. *Med Health* ,1999; 82:202–6
- 10-Raman, S.; Somasekar .; Winter R.K .;Lewis M.H 2004 .Are we overusing ultrasound in non-traumatic acute abdominal pain? *Postgrad Med J* . 2004; 80:177-179
- 11-Ralls PW, Colletti PM, Lapin SA. Real time sonography in suspected acute cholecystitis. *Radiology* 1985;155, 767-771,.
- 12-Manish ,C.;Patrick J. M. and Guy F N. ( 2007).A Simple Case of Appendicitis? An Increasingly Recognised Pitfall *Ann R Coll Surg Engl*; 89(7): 708
- 13-Ahn S.H.;Mayo-Smith W.;Murphy ,B.L.;Reinert S.E.;Cronan,J.(2002) Acute nontraumatic abdominal pain in adult patients: abdominal radiography compared with CT evaluation. *Radiol.*225: 159–164.
- 14-Malone AJ. Unenhanced CT in the evaluation of the acute abdomen: the community hospital experience.*Semin Ultrasound CT MR*; 1999; 20:68–76.
- 15-Abdul Khair, Mahmond H, Mohammed M..Ultrasonography and liver abscesses. *Am Surg* 1981;193: 221-226.
- 16-Diana G, Nira Beck-R.:David Mor.Y., Doron F.:Ofer B.;, M. K.and Ahuva E.(2008).Diagnosing Acute Appendicitis in Adults. Accuracy of Color Doppler Sonography and MDCT Compared with Surgery and Clinical Follow-Up; *Amer.Roentgen Ray Soc.*190:1300-1306.
- 17- Hastings RS, Powers RD Abdominal pain in the ED: a 35 year retrospective. *Am J Emerg Med.* 2010 [Abstract]
- 18-Radwan M,M and Abu- Zidan ,F.M(2006) .Focused assessment sonograph (FAST) and CT scan in blunt trauma : surgeon s prospective 6(3) 187-190 .