

Clinical Report

The effect of 1.2mg/Kg.BW of Sodium selenite solution dosed orally daily to Awassy male lambs

S. A. G. Al-Sammarraie, W. A. G. Al-Dulimy and A. M. Al-Judi
College of Veterinary Medicine\ University of Baghdad

10 Awassy male cross breed lambs aged 4-6 months and their weights ranged between 16-26 Kg, were divided into two groups 5 lambs each. The first group was treated with 1.2 mg/KgBW of Sodium selenite solution (10g/L solution) orally daily for 8 weeks (1) to study the clinical symptoms of Selenium toxicity.

The second group was left as control. All lambs were inspected and watched daily for 4-6 hr. , two weeks pre- and eight weeks during dosing. Clinical signs, pulse rate, respiratory rate, heart rate and rectal temperature , were recorded, as well as body weights every two weeks. Wool samples were collected monthly from an area of nine cm² on the left mid-side at the level of the last rib of each lamb, and delineated with a hair- pin caliper, and wool within this area was removed to establish wool physical traits of lambs in both groups.

Lambs of the treated group showed clinical signs started after two weeks of administration of Sodium selenite include: decrease in weight gain to reach a mean of 18 Kg on the eighth week, accompanied by increased pulse rate 91/min, and tachycardia, and increased respiratory rate 40/min ,while means of temperature remain within normal 38.9-40C°. On the other hand, the control group showed means of body weight 31Kg, pulse rate 76/min, respiratory rate 28/min, which were significantly differ ($P < 0.05$) from the treated group, and the mean temperature was 39.6 C°.

The coat of lambs in the treated group gradually became poor and rough, the wool was easily detached, and in advanced cases loss of coat (Pictures 1 and 2), as well as the physical traits of the wool changed significantly ($P < 0.05$) as the means of fiber diameter, fiber length and number of crispation (crispate) were 30.4µm, (4.6) cm and 2 crispate respectively after eight weeks, however, these traits in the control group were 48.6µm, 8.6cm and 9 crispate (Table 1). These results were in agreement with (2,3,4,5,6). These results were due to the ability of selenium to replace sulphur in the amino acids, so selenium has a high affinity to wool and epithelial structures.

Abnormal growth of the hooves (Pic. 3) and deformities were prominent in the toxicated group which led to increasing lameness due to erosion of the articular surfaces of long bones and in severe cases rings appear on the hoof below the coronary band (Pic. 4), so cracking appear (3,4,7). Eight weeks of Selenium selenite dosage to Awassy male lambs were enough to show clinical signs of sub-acute form of selenium toxicity.

Table (1) means of Awassy male lamb's wool changes

Parameters (means)	Groups							
	Treated				Control			
	April	May	June	LSD	April	May	June	LSD
Fibers diameter	48.2	40.1	30.4	2.06*	47.3	47.9	48.6	2.60ns
Fibers Length	7.8	5.3	4.6	0.82*	8.1	8.4	8.6	0.93ns
Number of crispate	6	3	2	0.78*	6	7	9	-

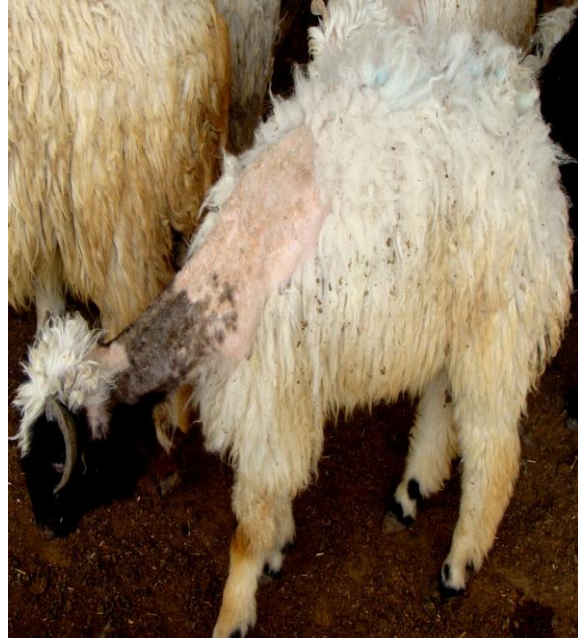
* **P<0.05****ns = not significant**

References


1. Marrow, D. A. (1986). Acute selenium toxicosis in lambs. *J. Am. Vet. Assoc.*, 152: 1625– 1629.
2. O'Toole, D. & Raisbeck, M. F. (1997). Experimentally induced selenosis of adult mallard ducks: Clinical signs, lesions, and toxicology. *Vet. Pathol.*, 34:330-340.
3. Wilber, G. G. (1980). Toxicology of selenium. *Clin. Toxicol.*, 17: 171– 230.
4. Smyth, J. B. A.; Wang, J. H.; Barlow, R. M.; Humphreys, D. J.; Robins, M. & Stodulski, J. B. J. (1990). Experimental acute selenium intoxication in lambs. *J. Comp. Pathol.*, 102:197-209.
5. Van Metre, D. C. & Callan, R. J. (2001). Selenium and vitamin E. *Vet. Clin. North Am. Food Anim. Pract.*, 17 (2): 373 – 402.
6. VanRyssen, J. B. J.; VanMalsen, P. S. M. & Hartmann, F. (1998). Contribution of dietary sulphur to the interaction between selenium and copper in sheep. *J. Agric. Sci.*, 130:107-114.
7. Radostits, O. M.; Gay, C. C.; Hincheliff, K. W. & Constable, P. D. (2007). *Veterinary Medicine. A textbook of the diseases of cattle, horses, sheep, pigs and goats.* 10th ed., Elsevier Health Sciences, Kennedy. Boulevard, Philadelphia, USA.



Pic.(1) Easily detached wool in lambs of the 1st group



Pic.(2) Loss of coat in lambs of the 1st group



Pict. (3) Abnormal growth of the hooves



Pict. (4) Rings appeared on the hoof below the coronary band