

Impact of Brix 3000 and conventional restorative treatment on pain reaction during caries removal among group of children in Baghdad city

Mafaz Mahdi Muhsin Ismail B.D.S. ⁽¹⁾

Aseel Haidar M.J. Al Haidar B.D.S., M.Sc. ⁽²⁾

ABSTRACT

Background: Pain and the usage of local anesthetic agents are still real problem in pediatric dentistry, for these reasons, the use of minimal invasive dentistry (MID) in regard to the patient comfort is important especially for children, anxious and uncooperative patients. Chemomechanical caries removal (CMCR) methods involve the selective removal of the carious dentine hence it avoided the painful removal of the sound dentine and the anxiety resulted due to the vibration of the hand piece which is also decreased thus it appears to be more acceptable and comfortable to the patient.

Aims of this study: This study was conducted among group of children to assess and compare the anxiety rating scale (during and after treatment) between the use of a recent chemomechanical caries removal method (by using Brix 3000) and the use of rotary instruments (using the ceramic bur).

Materials and methods: Thirty pediatric patients aged between 8-12years, with bilateral occlusal carious permanent molars (extending into dentin) were selected for this study. Carious lesions were removed using Brix 3000 (CMCR) on one side and rotary instruments on the contra lateral side. Both cavities were restored with light cured composite filling. Anxiety scores were determined using Frankle rating scale (1962) during and after the period of caries removal.

Results: The anxiety rating scale during the period of treatment showed the percentage of the negative behavior in the CMCR method was less than the percentage of the ceramic bur reverse the positive and definitely positive, which means that the new CMCR agent (Brix 3000) was more comfortable than the conventional rotary instrument (ceramic bur), that reduced the need for local anesthesia and the use of the drill. While after the treatment there is no big difference in the acceptance of the patients in two groups.

Conclusion: Brix 3000 gel as a CMCR is an effective alternative method for caries removal, which appears to be more comfortable for the patients and more conservative.

Key words: anxiety, Brix 3000, ceramic bur, children. (Received: 1/10/2018; Accepted: 5/11/2018)

INTRODUCTION

Painless dentistry and the use of minimal intervention will aid in giving: relief, comfort, and solace to the patient thereby instilling a positive attitude toward dental treatments, which are some of the factors justifying the specialty of pediatric dentistry ⁽¹⁾. It is well known fact that the conventional method of caries removal by using the "drilling" is the most common technique in dental practice. However, this method is always associated with many disadvantages such as the perception by the patients that drilling is unpleasant, frequent requirement of local anesthesia, thermal effects caused by drilling can also cause pressure effects on the pulp meanwhile, the use of traditional method may results an excessive removal of sound tooth structure ⁽²⁾. Dental anxiety have shown that dental drill is the most highly stressful factor in producing pain

during treatment to many patients especially children ⁽³⁾. As a result, "search" for newer method and materials is going on in the field of caries treatment. An innovative approach called "chemomechanical caries removal" technique, which is minimally invasive and painless had been developed to overcome the shortcomings of the traditional approach of caries treatment. This method of caries removal involves the chemical softening of the carious dentin followed by its removal with gentle excavation ⁽⁴⁾.

Since 1975, various chemical composition- ns had been introduced for chemomechanical caries removal ⁽⁵⁻⁹⁾. Although these chemical agents appeared to be effective, each product had certain drawbacks ⁽¹⁰⁾. In 2003, a research project in Brazil led to the evolution of papain gel (papacarie) ⁽¹⁰⁻¹¹⁾. Then cariecare was developed in India, which was a papain based gel containing a purified enzyme with clove oil which are analgesic and antiseptic ⁽¹²⁾. In 2016, a new material had been found in Argentina,

(1) M.Sc. Student, ministry of health, Baghdad.

(2) Assist Professor, dep. of Pedodontics and Preventive Dentistry, College of Dentistry, University of Baghdad.

named Brix 3000, also papain-base, obtained from leaves latex and fruits of green papaya (*Carica Papaya*) that acts as a chemical debridant. The differential of this product from other is the amount of papain used (3,000 U/mg in a concentration of 10%) and the bioencapsulation by EBE technology (encapsulated buffer emulsion), which gives the gel the ideal pH to immobilize the enzymes and liberate them at the moment of exerting its proteolysis on the collagen⁽²⁰⁾, and the enzymatic activity supplied the Brix agent by many effective properties included the higher proteolysis effectiveness and greater antibacterial and antifungal potency with an increase in the antiseptic effect on tissue⁽¹³⁾.

In the mechanical removal of caries, ceramic bur with stabilized zirconia was introduced to the market (CeraBur, K1SM, Komet). It has highly efficient excavating ability on soft (cariou) dentin with minimal reduction of the sound (hard) tooth structure. Hence, ceramic burs should be suitable to minimally invasive caries excavating methods⁽¹⁴⁾.

This study was conducted to estimate and compare between the use a chemomechanical caries removal method (by using Brix 3000) and the use of rotary instruments (using the ceramic bur), including the anxiety rating scale (during and after treatment).

MATERIALS AND METHODS

This study was performed on a sample of 30 children aged 8-12 years old who had bilateral cavitated carious permanent molars and they attended the pedodontics clinic in the Pedodontics and Preventive Dentistry Department, Baghdad dental teaching hospital/Iraq. The study period extended from the beginning of December 2017 until the end of April 2018.

For each child included in this study, parents /guardians permission was obtained prior to the involvement of their children by a written consent to get rid of any obstacles and to get a full cooperation and attention from them after fully explanation the idea of this study and its objectives with the probable advantage. A total of 60 permanent molars formed the study sample which was divided into 2 groups (30 molars for each) according to the technique used for caries removal, Brix 3000 group and ceramic bur group.

Selection criteria

Children were eligible for the this study if they fulfilled the following criteria as reported by

Shivasharan et al. in 2016⁽¹⁵⁾, with some modifications;

1. No history of any oral or systemic diseases, nor a history of any medications being used at least in the past 2 weeks.
2. Each child should have two contralateral open carious permanent molars (occlusal cavities) with dentin involvement, but without pulp exposure, in which the carious cavities had as similar depth for standardization (by using a DIAGNOdent caries detection device).
3. Cavities were accessible to facilitate the penetration of a small size excavator.
4. No evidence of clinical signs and symptoms of pulp or periapical pathogens.
6. No clinical evidence of proximal caries (using the DIAGNOdent device to determine if there is a proximal caries).
7. Adequate child behavior that had been assessed by using Frankle scale (1962) to be a positive or definitely positive behavior during dental examination.

Assessment Procedure

For each patient, the same investigator recorded the behavior assessment: The degree of patient's cooperation was evaluated during and after the procedure of caries removal in each method based on the Frankl behavior rating scale which was scored in four points (1=definitive negative, 2=negative, 3=positive, 4=definitive positive)⁽¹⁶⁾.

Clinical procedure

- 1) The degree of the child's cooperation was recorded (during and after complete the treatment) according to the Frankle rating scale⁽¹⁶⁾.
- 2) Cotton rolls and saliva ejector were used for the isolated each tooth⁽¹¹⁾.
- 3) Caries removal was carried out using either one of the following techniques :
 - Brix 3000: Chemomechanical method for one side of the bilateral carious teeth (selected randomly).
 - Ceramic bur: Conventional method with ceramic bur for the other side of the bilateral carious teeth.
- 4) The cavity was examined using tactile sensation and visual inspection.
- 5) Caries removal was confirmed using a dental explorer by passing it gently over the hard sound dentin which did not "catch" 'or give a "tug-back" sensation⁽¹⁷⁾.

- 6) Make sure if the present of the remnant caries by using DIAGNOdent caries detection device ⁽³²⁾.
- 7) Then the cavity was finished and light cured composite filling (GC Corporation, Hongo, Bunkyo-ku; Tokyo, Japan) was used to restore the cavity, and supported the unsupported enamel ⁽³¹⁾.

Brix 3000 group:

Teeth in this group were treated, using chemomechanical agent (Brix3000, S.R.L. of Argentina), **Fig. (1)**. Application of the (Brix 3000), (**Fig.2**) by spoon excavator on the selected tooth was done for two minutes according to the manufacturer's instructions, then removal of the material with the softened decay would take place with spoon excavator by pendulum movement and without pressure. The gel was reapplied, if needed until it presented a light coloring, which was an indicative of nonexistence of the softened carious tissue. At the end, the cavity was wiped with a moistened cotton pellet and rinsed with water.

Ceramic bur group:

Caries removal was done, by drilling, with low speed hand piece using ceramic bur (Cera Bur), (Komet –Brasseler; Lemgo,Germany). Then the cavities were checked by the same criteria that were used in Brix 3000 group.

Statistical analysis

Statistical analysis was done using statistical package for social sciences (SPSS) version 25. Maximum values, minimum values, mean, standard deviation (SD), percentage, had been used to analyze the main results.

RESULTS

In the present study, boys represented 23% of the study sample and the mean age of children was 10.8 years, Table (1).

Results, concerning the behavior rating scale, showed that (during the treatment period) the percentage of negative behavior scale by using Brix 3000 method was only 20% of cases, While, 76.6% positive and 3.3% definitely positive, compared to 93.3% of cases was recoded negative in using ceramic bur and 6.6% of cases had positive score as shown in Table (2). However,

after the treatment period the percentage of negative behavior in the brix 3000 was 0% while 33.3%

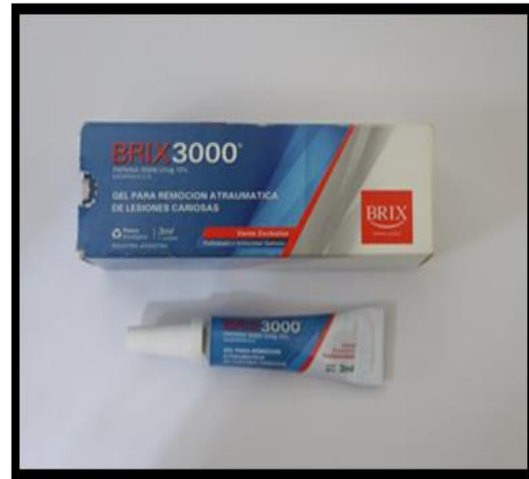

Fig. (1): Brix 3000

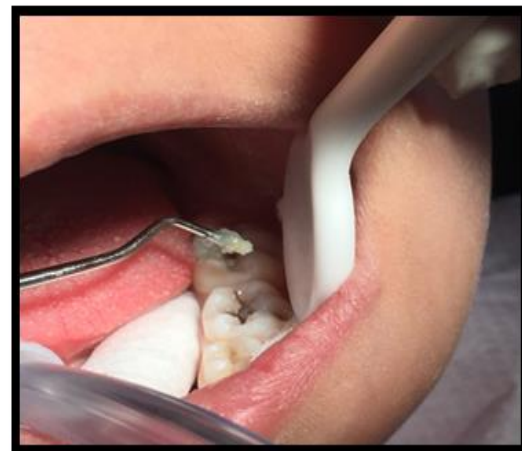

Fig. (2): Removal of carious dentine

had a positive behavior and 66.6% were with definitely positive behavior. In ceramic bur group, the percentage of the negative behavior was decreased to 3.3%, while positive and definitely positive was increased (90% and 6.6% respectively), Table 3, Fig. 3.

Table (1): Distribution of the sample by age and gender

Age (year)	Min ± Max	8-12
	Mean ± SD	10.8± (1.47)
Gender	Boys: No. (%)	7 (23.33)

	Girls: No. (%)	23 (76.67)
--	----------------	------------

Table 2: Distribution of the samples during the treatment period in the Brix 3000 and ceramic bur method

Treatment method	Rating behavior scale during treatment			Total
	Negative (2)	Positive (3)	Definitely positive(4)	
Brix3000	6 (20%)	23(76.6%)	1 (3.3%)	30
Ceramic bur	28 (93.3%)	2 (6.6%)	0 (0%)	30
Total	34	25	1	60

Table3: Distribution of the samples after the treatment period in Brix 3000 and ceramic bur method.

Treatment method	Rating behavior scale after treatment			Total
	Negative (2)	Positive (3)	Definitely positive(4)	
Brix 3000	0 (0%)	10(33.3%)	20(66.6%)	30
Ceramic bur	1 (3.3%)	27(90%)	2 (6.6%)	30
Total	1	37	22	60

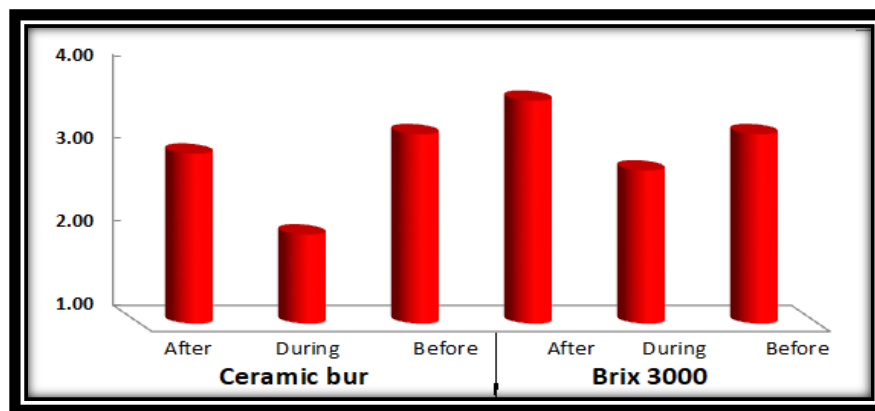


Fig. (3): Bar charts of mean score values concerning (Behaviour) scaling for Brix 3000 and ceramic method.

DISCUSSION

In restrictive dentistry, caries removal methods were developed to be more conservative and in biological direction. The CMCR method became an area of concern, because of its conception of tissue preservation, by which only the carious dentin is removed while the painful removal of the hard (sound) dentin is avoided, and hence, the need for local anesthesia is reduced (8, 15, 18-19). Brix 3000, introduced CMCR agent, was

preferred in this study as it was a gel prepared from papain that prepares the cavity with maximum preservation of the healthy tooth structure. It provides a synergistic action to facilitate the removal of the caries with highly antimicrobial effect (13, 20). The results of the previous studies had proofed that the CMCR method was effective and more comfortable for the patients than the conventional treatment with the rotary instruments or excavator (4, 21).

In this study, there was no difference in child behavior rating scale before treatment between the two groups, by which all the patients had positive or definitely positive rating behavior scale. However, during the treatment with the rotary instrument (ceramic bur), children exhibited deterioration in their behavior from positive to negative (most of the observations were reluctant to accept the treatment until they given local anesthesia). Meanwhile, in Brix 3000 group there was no change in the behavior of children during the treatment. The reasons for the positive behavior regarding the patients concern to CMCR this may be due to the lack of vibrations, sound and pain. This finding was agreed with the results of other studies^(22, 23). In addition, Kleinknecht et al. in 1973 reported that dental anxiety was mainly associated with the highly invasive procedures such as "injections" and "drilling", while neither of these procedures is usually needed with the papain gel approach for caries removal⁽²⁴⁾. After the treatment period most of the patients in two groups was accepted to the treatment but the percentage of positive and definitely positive was increased in the brix 3000 group and the child appeared more relaxed and happy as compared to the ceramic bur who accepted the treatment after take him/her local anesthesia. This result was agreed with many studies⁽²⁵⁻²⁷⁾, but disagreed with other^(28, 30), which found no difference in the anxiety levels during and after treatment in both CMCR and rotary groups.

Patient's worry about several side effects of rotary decay excavation including pain/discomfort, requirement of local anesthesia, noise and vibrations of the drill, etc.⁽¹⁸⁾. The Brix 3000 method was more comfortable for the patients than the conventional method (ceramic bur), in which only 20% of the patients in the Brix 3000 group used anesthetic agent compared to 93.3% of the patients from the (ceramic bur).

Conclusion

Encouraging out cases can be obtained from the utilization of Brix 3000 as a mean for CMCR in opened carious lesions .It is an effective method to treat pediatric patients especially those who presented with nursing caries or those who have behavior problems.

From the results of the present study, the followings were concluded:

1. Brix 3000 is a new CMCR agent. It is an excellent option for the minimally invasive removal of carious tissue, with the same effectiveness as that of the conventional method by the ceramic bur.
2. Relaxed behavior was found to be associated with the use of Brix 3000 approach treatment as compared to the rotary approach that helps to introduce pain free dental environment and instilling a positive dental attitude.
3. CMCR with Brix 3000 provides a lesser degree of pain in comparison to the conventional caries removal method, the painful removal of sound dentine is avoided and the need for local anesthesia is minimized.

REFERENCES

1. Nagaveni NB, Radhika NB, Satisha TS, Ashwini KS, Neni S, Gupta S. Efficacy of new chemomechanical caries removal agent compared with conventional method in primary teeth: An *in vivo* study. *Int J Oral Health Sci* 2016; 6:52-8.
2. Kotb RM, Abdella AA, El Kateb MA, Ahmed AM. Clinical evaluation of Papacarie in primary teeth. *J Clin Pediatr Dent* 2009; 34:117-23.
3. Ten Berge M, Veerkamp JS, Hoogstraten J, Prins PJ. Behavioural and emotional problems in children referred to a centre for special dental care. *Community Dent Oral Epidemiol* 1999; 27:181-6.
4. Elkholy NR, Abdelaziz KM, Zaghoul NM, Aboulene N. Chemo-mechanical method: A valuable alternative for caries removal. *J Minim Interv Dent* 2009; 2(4):248-259.
5. Habib CM, Kronman J, Goldman M. A chemical evaluation of collagen and hydroxyproline after treatment with GK 101 (N-Chloroglycine). *Pharmacol Ther Dent* 1975; 2:209-215.
6. Schutzbank SG, Galaini J, Kronman JH, Goldman M, Clark RE. A comparative *in vitro* study of GK-101 and GK-101E in caries removal. *J Dent Res* 1978; 57:861-4.
7. Ericson D, Zimmerman M, Raber H, Gotrick B, Bornstein R, Thorell J. Clinical evaluation of efficacy and safety of a new method for chemo-mechanical removal of caries. A multi-centre study. *Caries Res* 1999;33:171-7
8. Beeley JA, Yip HK, Stevenson AG. Chemochemical caries removal: A review of the techniques and latest developments. *Br Dent J* 2000; 188:427-30.
9. Azrak B, A Callaway, A Grundheber, E Stender, B Willershausen: A comparison of the efficacy of chemo-mechanical caries removal (Carisolv) with that of conventional excavation in reducing

- cariogenic flora. *Int J Pediatr Dent*; 2004, 14:182-91.
10. Kohli A, Sahani S. Chemicomechanical Caries Removal; A Promising Revolution: Say No to Dental Drills. *Int J Dent Med Res* 2015; 1(5):158-161.
 11. Bussadori SK, Castro LC, Galvao AC. Papain gel: A new chemo-mechanical caries removal agent. *J Clin Pediatr Dent* 2005; 30:115-9.
 12. Hegde AM, Preethi VC, Shetty A, Shetty S. Clinical evaluation of chemo-mechanical caries removal using Carie-care system among school children. *Nitte Univ J Health Sci* 2014; 4:80-4.
 13. Torresi FN, Besereni L. Effectiveness method of chemomechanical removal of dental caries as papain in adults. *J. Rev Assoc Paul Cir Dent* 2017; 71(3):266-9.
 14. Aline de Almeida Neves, Eduardo Coutinho, Marcio Vivan Cardoso, Paul Lambrechts, Bart Van Meerbeek. Current Concepts and Techniques for Caries Excavation and Adhesion to Residual Dentin. *The Journal of Adhesive Dentistry* 2011; 13(1):7-22.
 15. Shivasharan PR, Farhin AK, Wakpanjar MM, Shetty A. Clinical Evaluation of Caries Removal in Primary Teeth Using Carie-care and SmartPrep Burs: An *In vivo* Study. *Indian J Oral Health Res* 2016; 2:27-31.
 16. Frankl SN. Should the parent remain with the child in the dental operator? *J Dent Child* 1962; 29: 150-163.
 17. Watson TF, Banerjee A, Kidd EA. Dentine caries excavation: A review of current clinical techniques. *Br Dent J* 2000; 188:476-482
 18. Movan C, Lynch E, Folwacny M, Hickel R. Comparison of Caries removal using Carisolv or a conventional slow speed rotary instrument. *Caries Res* 1999; 33(46th ORCA Congress): 281- 330.
 19. Balčiuniënė I., Sabalaitė R., Juškienė I. Chemomechanical Caries Removal for Children. *Stomatologija, Baltic Dental and Maxillofacial Journal*, 2005, 7:40-44
 20. Romero K., Priscila N., fernanda G., Conceicao FA., Baena M. Use of BRIX -3000 enzymatic gel in mechanical chemical removal of caries :clinical case report. *journal of health sciences* 2018; 20(2):87-89.
 21. Cecchin D, Farina AP, Orlando F, Brusco EH, Carlini-Júnior B. Effect of carisolv and papacárie on the resin-dentin bond strength in sound and caries-affected primary molars. *Braz J Oral Sci* 2010; 9:25-9.
 22. Heyeraas KJ, Svein OB, Mjor IA. Pulp-dentin biology in restorative dentistry. Part 3: pulpal inflammation and its sequelae. *Quintessence Int* 2001; 32:611-625
 23. Mhatre S, Kumar SVK, Sinha S, Ahmed BMN, Thanawala EA. Chemo-Mechanical Method Of Caries Removal: A Brief Review. *Int J Clin Dent Sci* 2011; 2(2):52-57.
 24. Kleinknecht RA, Klepac RK, Alexander LD. Origins and characteristics of fear of dentistry. *J Am Dent Assoc.* 1973; 86:842-8. [[PubMed](#)]
 25. Ansari G, Beeley JA, Fung DE. Chemomechanical caries removal in primary teeth in-group of anxious children. *J Oral Rehabil.* 2003; 30:773-9.
 26. Bergmann J, Leitão J, Kultje C, Bergmann D, Clode MJ. Removing dentine caries in deciduous teeth with Carisolv: A randomised, controlled, prospective study with six-month follow-up, comparing chemomechanical treatment with drilling. *Oral Health Prev Dent.* 2005; 3:105-11.
 27. Lozano-Chourio MA, Zambrano O, González H, Quero M. Clinical randomized controlled trial of chemomechanical caries removal (Carisolv) *Int J Paediatr Dent.* 2006; 16:161-7.
 28. Inglehart MR, Peters MC, Flamenbaum MH, Eboda NN, Feigal RJ. Chemomechanical caries removal in children: An operator's and pediatric patients' responses. *J Am Dent Assoc.* 2007; 138:47-55.
 29. Peters M. C., Flamenbaum M. H., Eboda N. M., Feigal R. J., and Inglehart M. R., "Chemomechanical caries removal in children: efficacy and efficiency," *Journal of the American Dental Association*, , 2006; 137(12): 1658-1666. [View at Google Scholar](#) · [View at Scopus](#)
 30. Attari N, Roberts GJ, Ashley P. Children's anxiety during caries removal: Carisolv compared with dental drill. *J Dent Res.* 2001; 80:674
 31. ahlavan A, Taheri A H. Role of cusp coverage in the protection of unsupported enamel in posterior composite restorations. *The Journal of Islamic Dental Association of IRAN (JIDA).* 2004; 16(3):15-20.
 32. Bhat SS, Shaniya Sain, Sundeep K Hegde, Vidya Bhat.S. Efficacy of chemomechanical caries removal. *International Journal of Applied Dental Sciences* 2015; 1(3): 27-30.

المستخلص:

الخلفية: لا يزال الألم واستخدام مواد التخدير الموضعية مشكلة حقيقية في طب أسنان الأطفال ، ولهذه الأسباب ، فإن استخدام تقنية ال (MID) فيما يتعلق براحة المريض أمر مهم خاصة للأطفال والمرضى القلقين وغير المتعاونين. تتضمن طرق إزالة التسوس بالطريقة الكيموميكانيكية (CMCR) إزالة انتقائية للعلاج المتسوس ، حيث يتم إلغاء الإزالة المؤلمة للعلاج السليم والقلق الناتج عن اهتزاز اداة الحفر التي تنخفض أيضًا وبالتالي فإن هذه الطريقة أكثر قبولاً وراحة للمريض.

أهداف هذه الدراسة: أجريت هذه الدراسة بين مجموعة من الأطفال لتقييم ومقارنة مقياس تقييم القلق (أثناء وبعد العلاج) بين طريقتين لإزالة التسوس كيميوميكانيكية حديثة (باستخدام Brix 3000) واستخدام اداة الحفر التقليدية (باستخدام ceramic bur).

المواد والطرق: تم اختيار ثلاثين مريضاً من الأطفال لهذه الدراسة ، تتراوح أعمارهم بين 8-12 سنة ، مع أضرار دائمية متسوسة على جانبي الفك (يمتد فيها التسوس إلى العاج). تمت إزالة التسوس باستخدام Brix 3000 (CMCR) على جانب واحد و اداة الحفر التقليدية على الجانب الاخر. تم علاج هذه الاسنان بعد الانتهاء من عملية ازالة التسوس باستخدام مادة ال (light cured composite filling). تم تحديد درجات القلق باستخدام مقياس تصنيف فرانكل (1962) أثناء وبعد فترة إزالة تسوس الأسنان.

النتائج: أثناء البدء بأزالة التسوس وقبل اعطاء التخدير لاي من المجموعتين كانت نسبة المرضى الراضين للعلاج كبيرة في مجموعة (ceramic bur) وهذا عكسه في الطريقة الكيموميكانيكية (Brix 3000) حيث كان سلوك المرضى ايجابي ومتقبل للعلاج. مما يعني أن طريقة CMCR الجديدة باستخدام (Brix 3000) كانت أكثر راحة من استخدام أدوات الحفر التقليدية (ceramic bur). بالإضافة إلى ذلك ، خفض ال Brix 3000 بشكل كبير الحاجة إلى التخدير الموضعي واستخدام اداة الحفر الاعتيادية.

الاستنتاج: ان استخدام Brix 3000 كطريقة CMCR هو طريقة بديلة فعالة لإزالة تسوس ، والتي تبدو أكثر راحة للمرضى وأكثر محافظة. الكلمات الرئيسية: القلق ، Brix 3000 ، ceramic bur ، الأطفال.