

## **Effect of garlic and vitamin E-selenium on the histological picture of duodenum, liver and bursa of fabricius of broiler**

**تأثير فيتامين هـ – السلينيوم والثوم على الصورة النسجية لكل من الاثني عشر والكبد وجراب فابريشيا لفروج اللحم**

**\*Lec. Dr. Hayder Nadhim Alitaqi Alkhalissi**

**\*University of Kerbala- Veterinary Medicine College- Anatomy, Histology and Embryology Department**

### **Abstract**

Feeding makes up the major cost of production and good nutrition is reflected in the bird's performance and its products. The present research has been designed to study the effect of garlic with vitamin E-selenium and vitamin E-selenium on the histological picture of duodenum, liver and bursa of fabricius of broiler chickens. Sixty (60) broiler chick of commercial strain (Ross 308) divided into three groups with twenty (20) chicks for each group. In present study, it was found that the garlic with vitamin E-selenium was effective on the immunity of bursa of fabricius which led to increase in lymphocytes. There was a significant increase ( $P \leq 0.05$ ) in the diameter of follicles of bursa of fabricius, while the vitamin E-selenium significant ( $P \leq 0.05$ ) increase the activity of duodenum and liver which increase in the villi height of duodenum. However there was a significant decrease ( $P \leq 0.05$ ) in the epithelial thickness of these villi with crypt depth of the submucosa of duodenum lead to increase the surface area of the duodenum and decrease the distance between the absorbed material and the villi. Otherwise there was no strong effect of garlic with vitamin E-selenium on the duodenum and liver.

### **الخلاصة**

تشكل التغذية تكلفة الإنتاج الرئيسية وتنعكس التغذية الجيدة في أداء الطيور ومنتجاتها. صمم البحث الحالي لدراسة تأثير الثوم مع فيتامين هـ - سلينيوم وفيتامين هـ - سلينيوم على الصورة النسجية للأثني عشر والكبد وجراب فابريشيا لفروج اللحم. ستون (60) كتكوت لحم للسلالة التجارية (Ross 308) قسمت الى ثلاثة مجاميع بواقع عشرون (20) كتكوت لكل مجموعة. وجد في الدراسة الحالية بأن تأثير الثوم مع فيتامين هـ - سلينيوم على مناعة جراب فابريشيا حيث يؤدي الى زيادة في اللمفاويات حيث ان هنالك زيادة معنوية عند مستوى 0.05 في قطر بصيلات جراب فابريشيا، بينما فيتامين هـ - سلينيوم يزيد فعالية الاثني عشر والكبد حيث ان هناك زيادة معنوية عند مستوى 0.05 في ارتفاع الزغابات للأثني عشر لكن هنالك انخفاض معنوي عند مستوى 0.05 في سمك الطبقة الطلائية لهذه الزغابات مع قلة عمق السرداب في الطبقة تحت المخاطية للأثني عشر مما يؤدي الى زيادة المساحة السطحية للأثني عشر وقلة المسافة بين المواد الممتصة والزغابات. من جانب آخر لا يوجد تأثير ملموس للثوم مع فيتامين هـ - سلينيوم على كل من الاثني عشر والكبد.

### **Introduction**

Broiler chickens were a gallinaceous domesticated fowl, bred and raised specifically for meat and egg production (1). Chicken were one of the most common and widespread domestic animals, and with a population of 19 billion in 2011, (2), Over the last four decades there has been rapid growth in livestock production and a rapid change in how animal products are produced, processed, consumed and marketed. Growth in livestock production in both developed and developing countries has been led by poultry. From the 1990s to 2005, consumption of poultry meat in developing countries increased by 35 million tonnes – almost double the increase that occurred in developed countries (3; 4; 5; 6).

Garlic was a strongly aromatic bulb crop that had been cultivated for thousands of years. It was renowned throughout the world for its distinctive flavor as well as its health-giving properties (7), and it improves the immune system by increasing the cellular immune parameters (8), also to

reduce the blood pressure, lower high cholesterol, prevent heart attacks, cancer and inhibit microbe growth (9; 10).

Dietary vitamin E was found to improve reproduction and antioxidant capability of breeder chickens, but very few information was currently available on the effect of vitamin E supplement on the immune response (11; 12; 13), so the aim of this research was to study the effect of garlic with vitamin E-selenium and vitamin E-selenium on the histological picture of duodenum, liver and bursa of fabricius of broiler chickens for supporting in immunity and activity of broiler chickens.

### **Materials and methods**

The study was carried out in the poultry farm in the holy city of Karbala from January 2015 to March 2015. Sixty (60) broiler chick of commercial strain (Ross 308), birds divided into three groups with twenty (20) chicks for each group, gave 0.5ml garlic/1liter drinking water while vitamin E-selenium added 1mml/1liter to drinking water as in the prescription of these drugs, the treatment in drinking water for all raising period of broiler which was (39 days). The first group kept as (control group), the second group was supplied with garlic and vitamin E-selenium in drinking water while the third group was given or supplied with vitamin E-selenium only in drinking water.

The birds had no developmental disorders and detectable disease that may cause any problem in the histological picture of studied organs, they were killed by cervical subluxation method and bursa of fabricius with liver and part of duodenum were collected through ventral abdominal dissection and incision in the body which were free from pathological lesions. Samples were flushed with normal saline and were fixed in a 10% formalin solution. Histological examinations were carried out according to the method of (14) in order to perform histological slides which stained with Hematoxylin and Eosin stain (H&E). Images were captured with digital camera (canon) attached to light microscope (Olympus).

Data statistically were analyzed by using analysis of variance (ANOVA). Means of treatment that showed significances differences using least significant difference (L.S.D) test, a computer program by using SPSS program (15).

### **Results and Discussion**

The results of the present study showed the effect of garlic and vitamin E-selenium in drinking water on the histological picture of duodenum which was no significantly difference ( $p \leq 0.05$ ) in villi height between control group and group with garlic and vitamin E-selenium which was ( $124.25 \pm 3.49$ ,  $118.25 \pm 4.59 \mu\text{m}$ ) respectively, while there was significantly increase ( $p \leq 0.05$ ) in villi height between control group and group with vitamin E-selenium which was ( $124.25 \pm 3.49$ ,  $185.5 \pm 4.94 \mu\text{m}$ ) respectively table (1), (fig.1&2&3), the elongation of villi due to increase the activity of duodenum when give vitamin E-selenium increase activity also the vitamin E act as antioxidant and regeneration of intestinal mucosa this lead to increase the duodenal surface area to assist the intestinal activity and absorption, which was the same observation of (16) that the garlic enhanced the villi height and lead to increase of intestinal activity. There was a significant increase ( $p \leq 0.05$ ) in epithelial thickness of villi between control group and group with garlic and vitamin E-selenium which was ( $5.25 \pm 0.23$ ,  $12.12 \pm 1.14 \mu\text{m}$ ) respectively, while there was no significant difference ( $p \leq 0.05$ ) between control group and group with vitamin E-selenium which was ( $5.25 \pm 0.23$ ,  $4 \pm 0.13 \mu\text{m}$ ) respectively table (1), (fig.2&3), because the increasing in the epithelia of villi lead to decrease the absorption rate and the garlic when combined with vitamin E-selenium increase the immunity and this led to increase the thickness of epithelia to increase the distance between the absorbed materials and the villi. On the otherhand there was a significantly decrease at  $p \leq 0.05$  in the crypt depth between control group and group with vitamin E-selenium which was ( $24 \pm 1.5$ ,  $17.25 \pm 0.87 \mu\text{m}$ ), while there was no significantly difference ( $p \leq 0.05$ ) in crypt depth between control group and group with garlic and vitamin E-selenium which was ( $24 \pm 1.5$ ,  $27 \pm 1.69 \mu\text{m}$ ) respectively table (1), (fig.2&3), this thought to increase the secretion of the intestinal glands and also to let the villi take the hole diameter of the duodenum due to increase the intestinal

activity and absorption rate, and this disagreed with (16) who observed that the garlic as a feed additive significantly enhanced villus height and decreased epithelial thickness and goblet cell numbers in duodenum, jejunum and ileum of birds, but agreed with the researcher by the garlic as a feed additive significantly enhanced crypt depth.

There was a hypertrophy of hepatocytes in liver of group with vitamin E-selenium in compared with control group and group with garlic and vitamin E-selenium causing a foamy or a honey comb appearance of hepatocytes (fig.4&5&6), on the otherhand there was disorganization of hepatic cords, due to the hepatocytes filled with glycogen or lipid inclusions for maintained the sugar level in the blood when added vitamin E-selenium, this thought due to the increase the activity of liver, while the garlic affection on increasing the immunity, otherwise the vitamin E-selenium increase the activity of the digestive system this agreed with (17; 18) who observed that the GIT development, activity and health were the key to productivity in all farm animals and poultry, also agreed with (19) who showed that the GIT of the birds possesses the functions of food content storage, secretion digestion, and absorption of nutrients, likewise the structure and function of the digestival associated glands, had the highest turnover rate of all the tissues of the body when added vitamin E supplementation in the diet of broiler chickens.

However the effect of garlic and vitamin E-selenium in drinking water on the histological picture of bursa of fabricius showed significant increase ( $p \leq 0.05$ ) in the diameters of follicles of bursa of fabricius in group with garlic and vitamin E-selenium in compare with control group which was ( $50.5 \pm 3.63$ ,  $28.9 \pm 2.08 \mu\text{m}$ ) respectively, while there was significantly decrease ( $p \leq 0.05$ ) in the diameters of follicles of bursa of fabricius in group with vitamin E-selenium in compare with control group which was ( $20.4 \pm 1.52$ ,  $28.9 \pm 2.08 \mu\text{m}$ ) respectively table (1), on the otherhand the follicles from group with garlic and vitamin E-selenium showed elongation in these follicles, and the trabeculae were thin (fig.7&8), and the cortex of these follicles was distinct while the medulla was pale and their cells were distributed with spaces between them (fig.9), otherwise the follicles with adding vitamin E-selenium had thin cortex the hole follicle was medulla also the trabeculae were thickened occupied the most of folds this due to not enhancing of immunity without adding garlic and led to reducing in the small lymphocytes in the cortex of follicles and the germinal centers in the medulla act to compensate this decreasing in the lymphocytes. Likewise the increasing in the diameter of follicles due to increasing in the immunity level because of increasing in number of lymphocytes when adding garlic in drinking water instead of vitamin E-selenium only, this agreed with (20) who observed that the vitamin E and E-selenium combination were not affecting on performance of production factors without garlic.

**Table (1) the parameters of duodenal villi and crypt with follicles of burse of fabricius.**

Parameters Group	Villi height -VH-	Epithelium thickness -ET-	Crypt depth -CD-	Follicles of bursa fabricius -F-
Control group	$124.25 \pm 3.49$ B	$5.25 \pm 0.23$ B	$24 \pm 1.5$ A	$28.9 \pm 2.08$ B
Group with vitamin E-selenium	$185.5 \pm 4.94$ A	$4 \pm 0.13$ B	$17.25 \pm 0.87$ B	$20.4 \pm 1.52$ C
Group with garlic and vitamin E- selenium	$118.25 \pm 4.59$ B	$12.12 \pm 1.14$ A	$27 \pm 1.69$ A	$50.5 \pm 3.63$ A

Means with the same letters are not significantly different in the same column.

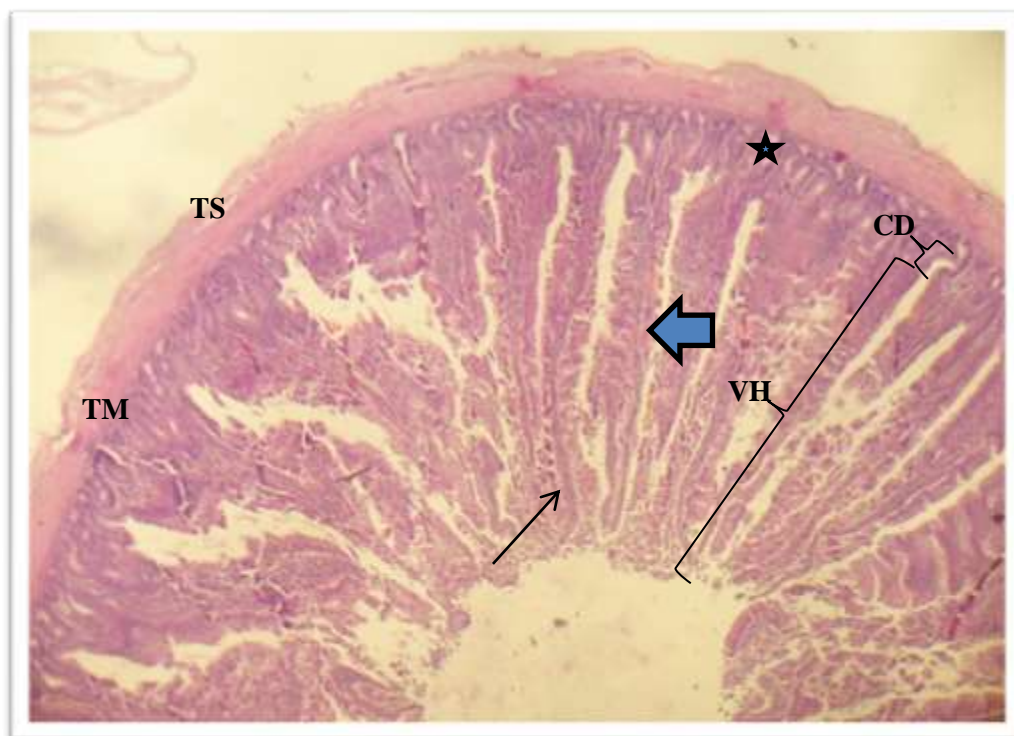


Figure (1) histological cross section of normal duodenum which appear, tunica serosa (TS), tunica muscularis (TM), intestinal glands ( ★ ), crypt depth (CD), villus ( ➡ ), lamina propria of villus ( —➡ ) and villi height (VH), H&E X100

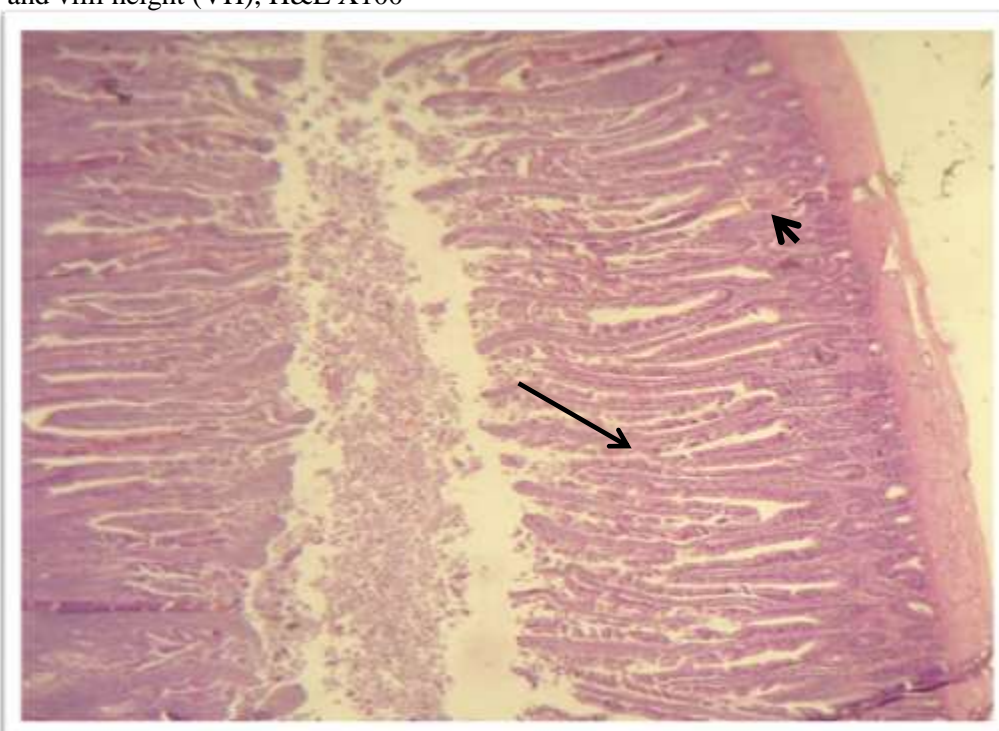


Figure (2) histological longitudinal section of duodenum with adding garlic and vit. E-selenium which showed the normal elongation of villi with thickening epithelia ( —➡ ) with normal crypt depth ( ➡ ), H&E X100



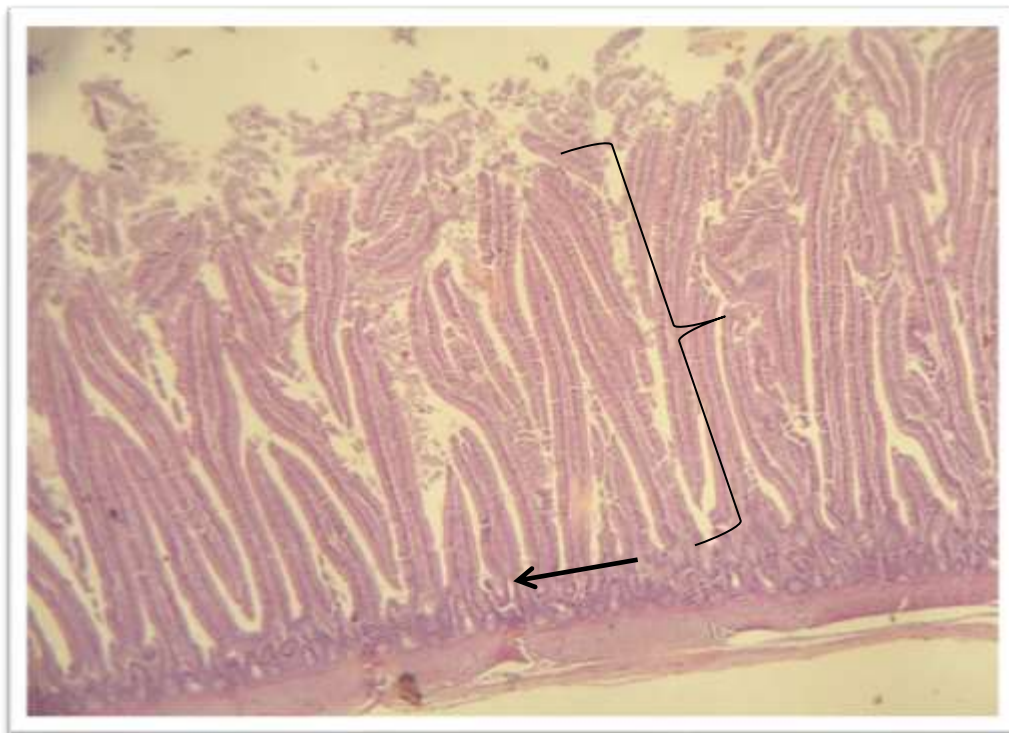

Figure (3) histological longitudinal section of duodenum with adding vit. E-selenium which showed the long villi ( } ) with normal thickness of epithelia and decrease of crypt depth ( ← ), H&E X100

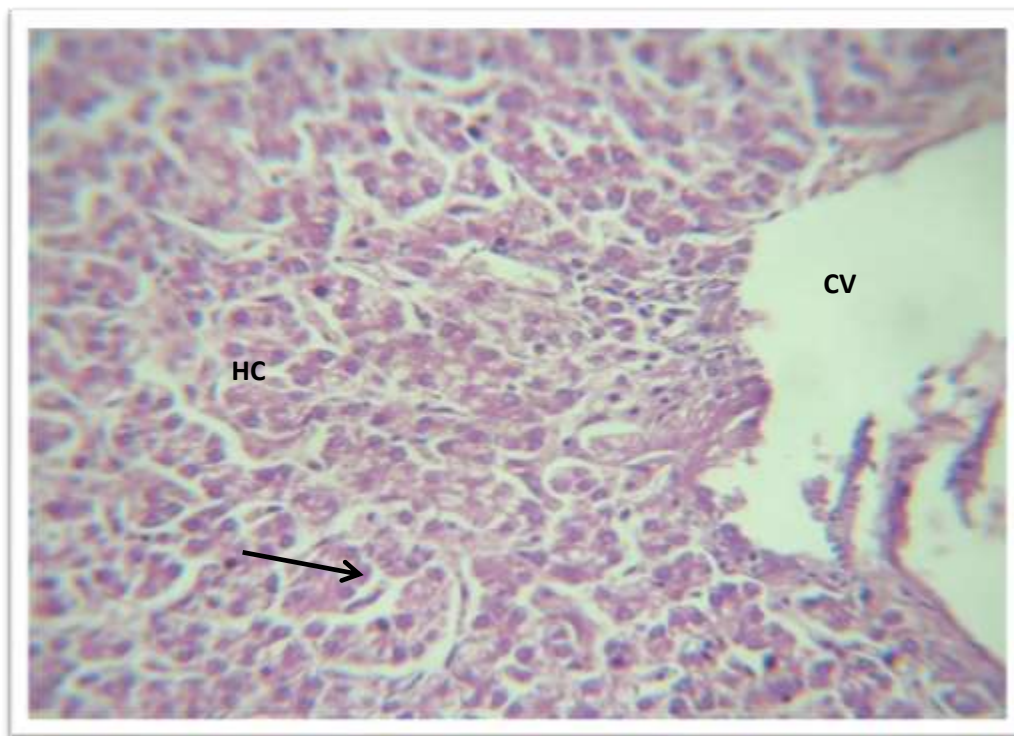


Figure (4) histological cross section of normal structure of liver which appear central vein (CV), hepatocyte (HC), sinusoid ( → ), H&E X400

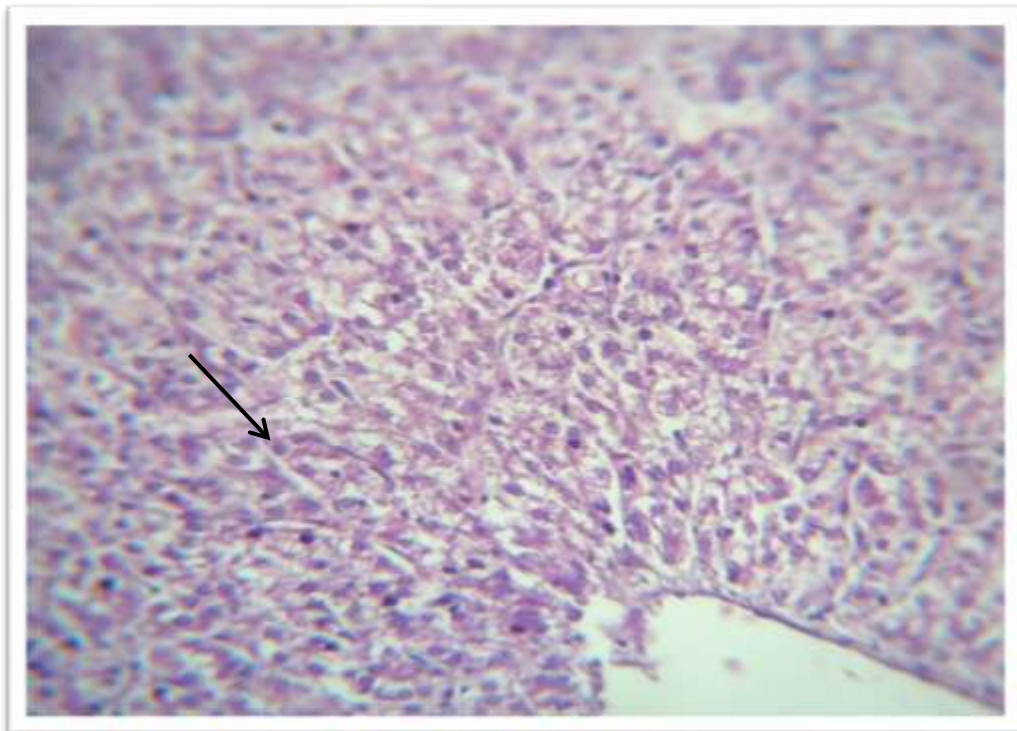


Figure (5) histological cross section of liver with adding garlic and vit. E-selenium which showed the normal organization of hepatic cords ( —————→ ), H&E X400

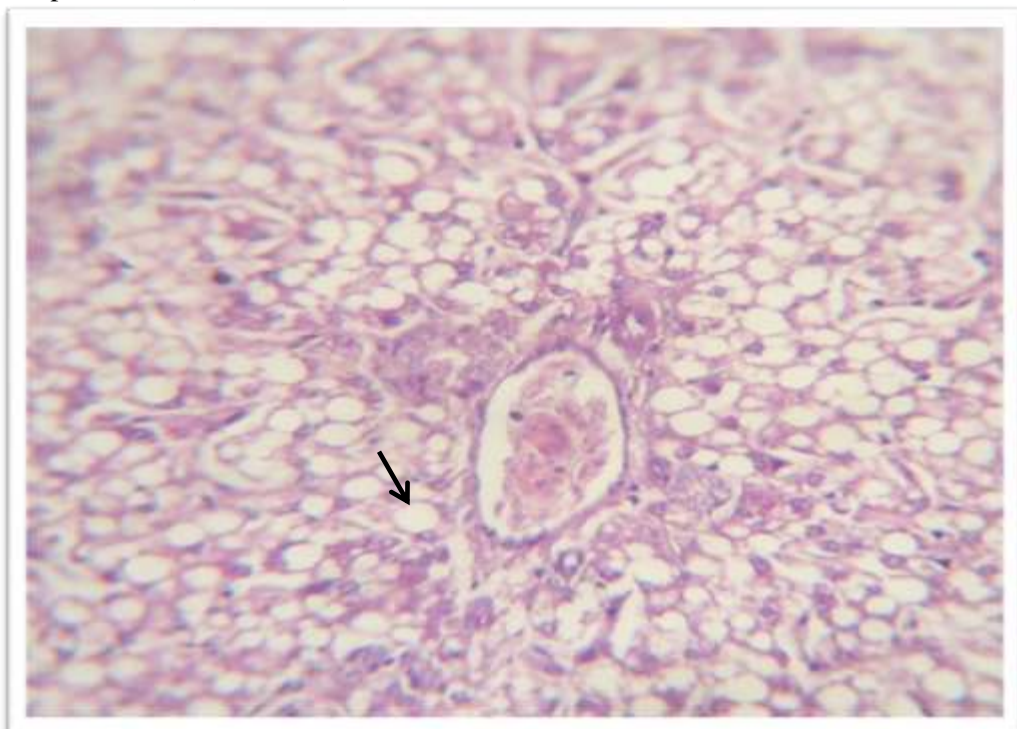

Figure (6) histological cross section of liver with adding vit. E-selenium which showed the disorganization of hepatic cords and the foamy shape of hepatocytes ( —————→, H&E X400



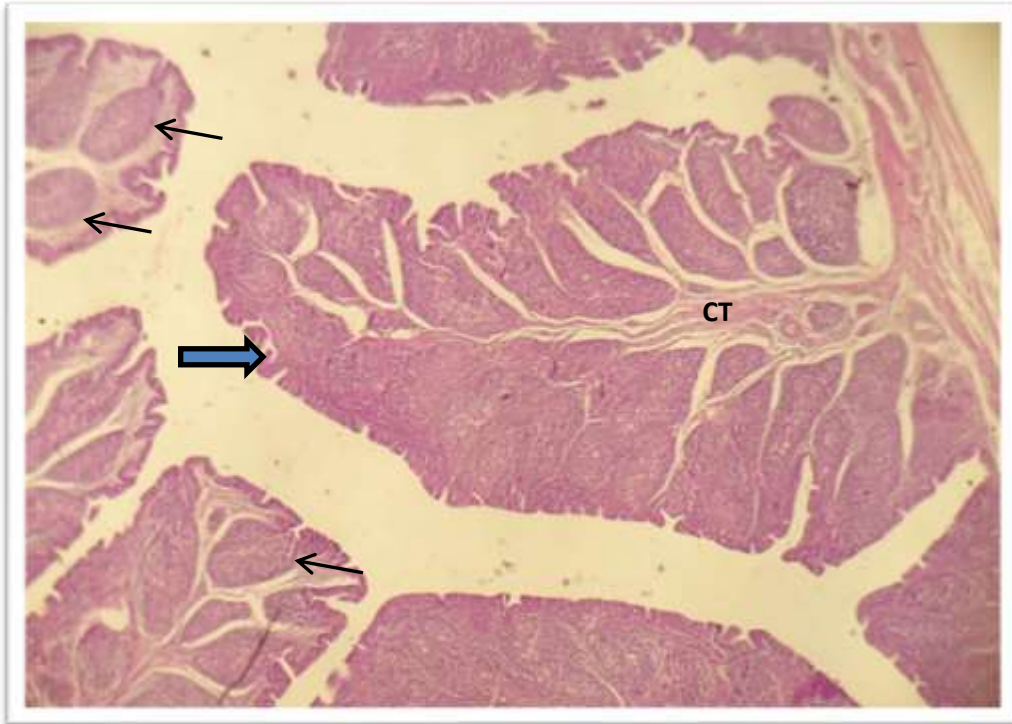




Figure (7) histological cross section of normal structure of bursa of fabricius which appear mucosal fold (  ), follicles (  ), connective tissue (CT), H&E X100

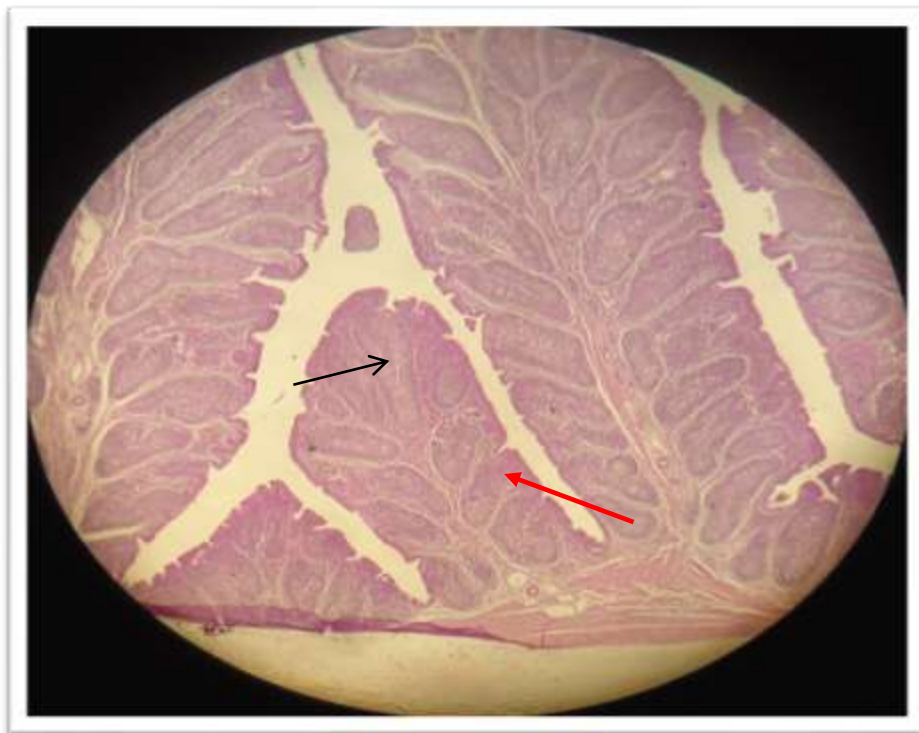




Figure (8) histological cross section of bursa of fabricius with adding garlic and vit. E-selenium which showed the large long follicle (  ) and thin trabeculae (  ) H&E X100

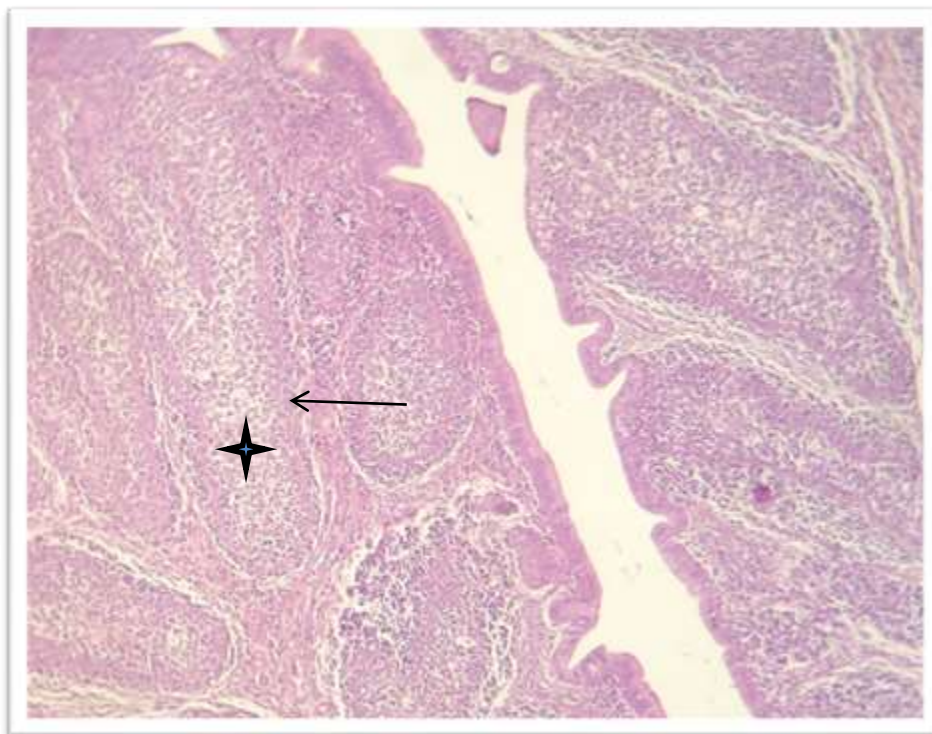


Figure (9) histological cross section of bursa of fabricius with adding garlic and vit. E-selenium which showed the distinct cortex of follicles ( ← ) and the pale medulla with spaces between cells ( ★ ) H&E X400

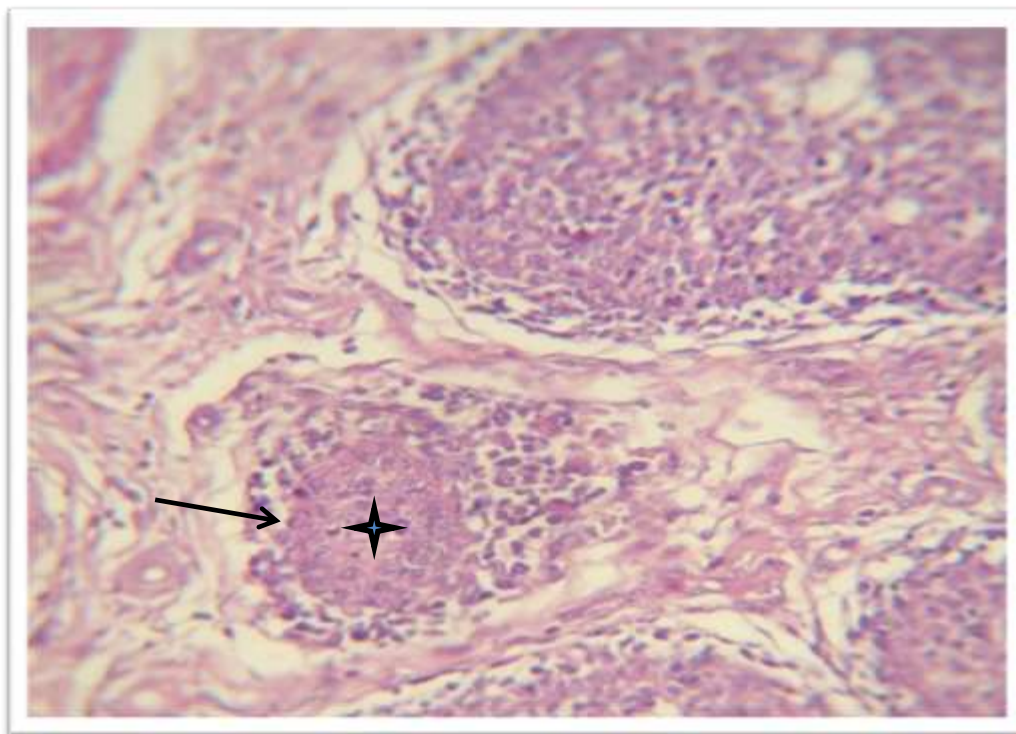


Figure (10) histological cross section of bursa of fabricius with adding vit. E-selenium which showed the narrow cortex of follicles ( → ) and the condense medulla ( ★ ) H&E X400



**REFERENCES**

- 1- Van Emous R. A., (2010). Innovative housing in broiler breeder production. Proc. 2nd Int. Symp. Highlights in Nutrition and Welf. in Poultry Production Wageningen, The Netherlands Lelystad, The Netherlands. Animal Science Group. p. 37-44.
- 2- Zuidhof M. J., (2007). Reproductive efficiency and metabolism of female broiler breeders as affected by genotype, feed allocation and age at photostimulation.3. Reproductive efficiency. Poultry Science. 86:2278-2286.
- 3- Narrod, C. (1997). Technology transfer in the poultry industry: an examination of supply factors and externalities associated with increased production. University of Pennsylvania, Philadelphia, USA. (PhD Dissertation).
- 4- Narrod, C. & Fuglie, K. (2000). Private-sector investment in livestock breeding. Agribusiness: An International Journal, 4(6): 457–470.
- 5- Martinez, S.W. (2002). Vertical coordination of marketing systems: lessons from the poultry egg, and pork industries. Agricultural Research Report No. 807. Washington DC, Economic Research Service, United States Department of Agriculture.
- 6- Morrison Paul, C., Nehring, R., Banker, D. & Somwaru, A., (2004). Scale economies and efficiency in U.S. agriculture: are traditional farms history. Journal of Productivity Analysis, 22(3): 185–205.
- 7- Cardelle-Cobas A.; Soria A.C.; Corzo-Martinez M.; Villamiel M. (2010). A comprehensive Survey of Garlic Functionality. Nova Science Publishers, Inc. 1-60.
- 8- Wang D., Feng Y., Liu J. *et al.*, (2010). Medicinal and Aromatic Plant Science and Biotechnology. Global Science Books. 4(1), 37-40.
- 9- Tsai Chia-Wen; Chen Haw-Wen, Sheen Le-Yen; Lii Chong-Kuei, (2012). Garlic: Health benefits and actions. China Medical University Published by Elsevier Taiwan LLC. BioMedicine2 (2012) 17-29.
- 10- Gebreyohannes Gebreselma and Gebreyohannes Mebrahtu, (2013). Medicinal Values of Garlic: A Review. International Journal of Medicine and Medical Sciences. Vol. 5(9), pp. 401-408.
- 11- Lin, Y. F., Chang S. J. and Hsu A. L., (2004). Effects of supplemental vitamin E during the laying period on the reproductive performance of Taiwan native chickens. British Poultry Science. 45:807-814.
- 12- Lin, Y. F., Tsai H. L., Lee Y. C. and Chang S. J., (2005a). Maternal vitamin E supplementation affects the antioxidant capability and oxidative status of hatching chicks. Journal Nutrition. 135:2457-2461.
- 13- Lin, Y. F., Chang S. J., Yang J. R., Lee Y. P. and Hsu A. L., (2005b). Effects of supplemental vitamin E during the mature period on the reproduction performance of Taiwan Native Chicken cockerels. British Poultry Science. 46:366-373.
- 14- Luna, L. G., (1968). Manual of histology staining methods of armed forces institute of pathology. 3rd ed. New York, U. S. A. PP; 39-110.
- 15-Niazi, A.D.(2000). Statistical Analysis in Medical research. Republic of Iraq. Al\_Nehrien University. P. 148.
- 16- Masoud Adibmoradi; Bahman Navidshad; Jamal Seifdavati and Maryam Royan, (2006). Effect of Dietary Meal on Histological Structure of Small Intestine in Broiler Chickens. The Journal of Poultry Science, 43:378-383.
- 17- Jin LZ; Ho YW; Abdullah N. and Jalaludin S., (1998). Growth performance, intestinal microbial populations, and serum cholesterol of broilers fed diets containing Lactobacillus cultures. Poultry Science Journal, 77: 1259-1265.

- 18- Iji PA., (1999). The impact of cereal non-starch polysaccharides on intestinal development and function in broiler chickens. *World's Poultry Science Journal*, 55: 375-387.
- 19- Lin, Y. F. and Chang S. J., (2006). Effects of dietary vitamin E on growth performance and immune response of breeder chickens. *Asian-Aust. Journal Animal Science*. 19 (6):884-891.
- 20- Taghizadeh, A.; Zakeri, A.; Rezapour A. (2012). Comparative Effect of Vitamin E and Vitamin E-Selenium Compound on T4-Induced Ascites Syndrome (By T4-Supplementation of the Diet) in Broiler Chickens, *Global Veterinaria*. 9 (3): 262-265,