



IRAQI  
Academic Scientific Journals



العراقية  
المجلات الأكاديمية العلمية

**TJAS**

Tikrit Journal for  
Agricultural

ISSN:1813-1646 (Print); 2664-0597 (Online)

Tikrit Journal for Agricultural Sciences

Journal Homepage: <http://www.tjas.org>

E-mail: [tjas@tu.edu.iq](mailto:tjas@tu.edu.iq)

## Effect of carotenoids of *Rhodotorula glutinis* and probiotic of *Lactobacillus acidophilus* on some physiological and histological variables of the pancreas and liver in male rats exposed to ultraviolet radiation

Wijdan I. Abd-alwahab<sup>1</sup> , Roaa J. Al-Assie<sup>2</sup> , Ashraf K. Azeez<sup>3</sup>, and Ghadir K. Ghadir<sup>4</sup>

<sup>1,2</sup>Department of Biology, College of Education, University of Samarra, Iraq

<sup>3</sup>Department of Animal Production, College of Agriculture, Tikrit University, Iraq

<sup>4</sup>College of Pharmacy, Al-Farahidi University, Baghdad 00965, Iraq

Correspondence email: [wijdan80@uosamarra.edu.iq](mailto:wijdan80@uosamarra.edu.iq)

### ABSTRACT

This study was conducted in the laboratory animal house at the College of Education/University of Samarra to establish and evaluate and treatment the effect of ultraviolet radiation (UV) on the health and functions of the pancreas and liver by use the carotenoids extracted from *Rhodotorula glutinis* yeast and *Lactobacillus acidophilus* as probiotic. 28 male laboratory rats were used and divided into four groups with 7 animals in each group, the experiment period was 28 days, including 24 hours representing the period of exposure to ultraviolet radiation before treatment. The results showed a significant increase ( $P<0.05$ ) in concentrations of glucose, cholesterol, triglycerides, bilirubin and activity of ALT, AST and ALP in the group exposed to ultraviolet radiation compared with the healthy control group, whereas, a significant decrease of all previous parameters in the groups that treated with probiotic and the carotenoids in comparison with ultraviolet radiation group, and repair of the damage that occurs in tissues of pancreas and liver result from the effect of ultraviolet rays.

### KEY WORDS:

Ultraviolet (UV) ;  
Carotenoids ; Probiotic

**Received:** 12/04/2024  
**Revision:** 20/05/2024  
**Proofreading:** 28/05/2024  
**Accepted:** 10/06/2024  
**Available online:** 30/06/2024

© 2024. This is an open access article under the CC by licenses <http://creativecommons.org/licenses/by/4.0>



## تأثير الكاروتينات من *Rhodotorula glutinis* والمعزز الحيوي من *Lactobacillus acidophilus* في بعض المتغيرات الفسلجية والنسجية للبنكرياس والكبد في ذكور الجرذان المعرضة للأشعة فوق البنفسجية

وجدان ابراهيم عباس عبدالوهاب ، رؤى جعفر جاسم العاصي ، اشرف كامل عزيز ، غدير كامل قادر  
1-2- قسم علوم الحياة ، كلية التربية ، جامعة سامراء ، العراق.  
3- قسم الانتاج الحيواني - كلية الزراعة - جامعة تكريت  
4- كلية الصيدلة، جامعة الفراهيدي، بغداد 00965، العراق

### الخلاصة

اجريت هذه الدراسة في البيت الحيواني في كلية التربية-جامعة سامراء لتقييم ومعالجة تأثير الأشعة فوق البنفسجية على صحة ووظائف البنكرياس والكبد باستخدام الكاروتينات المستخلصة من خميرة *Rhodotorula glutinis* والمعزز الحيوي لبكتريا *Lactobacillus acidophilus*. تم استخدام 28 من ذكور الجرذان المختبرية قسمت إلى أربع مجموعات بواقع 7 حيوانات في كل مجموعة، ومدة التجربة 28 يوماً منها 24 ساعة والتي تمثل فترة التعرض للأشعة فوق البنفسجية قبل المباشرة بالعلاج. أظهرت النتائج ارتفاعاً معنوياً ( $P<0,05$ ) في تراكيز الكلوكوز والكوليسترول والدهون الثلاثية والبيليبروبين وفعالية انزيمات ALT , AST و ALP في المجموعة المعرضة للأشعة فوق البنفسجية مقارنة بمجموعة السيطرة السليمة، في حين لوحظ انخفاض معنوي في جميع المعايير السابقة في المجاميع المعرضة للإشعاع ومعاملة بالمعزز الحيوي والكاروتينات مقارنة بالمجموعة المعرضة للأشعة فوق البنفسجية، كما لوحظ إصلاح الضرر الحاصل في أنسجة البنكرياس والكبد نتيجة تأثير التعرض للأشعة فوق البنفسجية.

الكلمات الافتتاحية: الاشعة فوق البنفسجية ، الكاروتينات ، المعزز الحيوي.

### INTROUCTION

Ultraviolet rays are one of the most important types of low-energy non-ionizing rays. They are used in disinfection and eliminating microorganisms. The effects of radiation on humans and living organisms result from cell damage, leading to cell death and preventing or delaying cell division or increasing the rate of cell division and causing changes that may appear in The same person is exposed to these rays, or they may be genetically transmitted to the children or generations following the exposed person (Güerci *et al.*, 2004 ; Tang *et al.*, 2024). Ultraviolet rays have wavelengths ranging between (290-330 nm) and a small amount of them reaches the surface of the earth due to the presence of the ozone layer that filters them and absorbs them in the outer parts of the atmosphere, but the small percentage of these rays that can reach the cells of living organisms can destruction and destruction of cells and their contents (Ansary *et al.*, 2021; Naji and Hussein, 2023). In order to identify the harmful and dangerous effects of ultraviolet rays on the efficiency and functions of the liver and pancreas, this study was conducted.

Carotenoids are among the most widespread pigments in nature, and are specifically manufactured by plants and microorganisms (Vachali *et al.*, 2012). Carotenoids have great importance and wide uses. They are useful as food additives and effective components of antioxidants and vitamins that have anti-tumour activity and protect humans from heart diseases, diseases of aging and the production of drugs and nutritional supplements (Johnson and Schroeder, 1996). *Lactobacillus acidophilus*, which is a type of gram-positive bacteria that is found in the digestive system, provides a group of benefits to the body, such as improving digestion, especially for people who suffer from lactose intolerance. It also contributes to maintaining the balance of beneficial bacteria in the digestive system, in addition to promoting health and the immune system (Wen *et al.*, 2023).

## **MATERIAL AND METHODS**

### **Study design:**

28 male albino rats were used of the strain (Sprague Dawely) whose ages ranged between (2-2.5) months and weighed (200-250 g), The animals were left for two weeks to adapt to the new conditions and to ensure they were free of diseases, then divided into four groups with 7 animals in each group (G1 as Healthy control group, G2 refer to UV exposed group, G3 as bacterial probiotic group, and G4 group represent that treated with carotenoids extract). They were given water and food continuously throughout the experiment period, which amounted to 28 days that expanded between February and April 2023, including 24 hours representing the period of exposure to ultraviolet radiation before treatment. The animals were exposed to an ultraviolet radiation at a wavelength of 300 nm by ultraviolet lamp 30 W in 90 cm length was placed on the up to cover of the animal cage, and this study was conducted with the guidelines of the Institutional Animal care and use committee at the University of Samarra

An isolate of *Rhodotorula glutinis* yeast was obtained and previously identified from the laboratories of the College of Agriculture - Kirkuk University. The carotenoid pigment was extracted from the isolate of yeast after growing it on Sabouraud glucose agar (SGA), according to the method of (Park *et al.*, 2005) which was modified by (Ali, 2013) for carotenoid extraction. The dye was kept in opaque bottles and in dark conditions at -18 °C to avoid oxidation and damage to the dye. 2.39 mg of the prepared carotene was dissolved, and the carotenoid dose was used based on the recommended daily requirement of beta-carotene for rats, which is 2.39 mg/kg of body weight. The animals were dosed orally by using a gavage.

The bacterial suspension of *L. acidophilus* as a probiotic supplement results from emptying the contents of a ready-made bag (Lacteol fort) containing *L. acidophilus* in a dried powder form, which was manufactured by a (Rameda Pharma company, Egypt, with permission from Axcan Pharma - France). The contents of the bag were mixed in 10 ml of skimmed milk and then given to the animals at a dose of 2.5 ml/kg of body weight.

#### **Physiological and Biochemical test:**

Glucose, Cholesterol, Triglycerides, Alanine aminotransferase (ALT), Aspartate aminotransferase (AST), Alkaline phosphatase (ALP) and Bilirubin were determined depending on the enzymatic colourimetric method by kits supplied by (BIOLABO Company, France).

#### **Histological study:**

After anesthetized the animal by chloroform and take the blood from each animal, laparotomy was to open the abdominal cavity and chest (sternum) in form (T) inverted shape, then, quickly extirpate the liver and pancreas from each rat, then, carrying out a series of processes to the preparation of histological sections (tissue slices) (Suvik and Effendy, 2012 ; Bancroft and Layton, 2018).

#### **Statistical Analysis**

The results were performed and underwent by SAS Statistical program (SAS, 2001). One-way analysis of variance (ANOVA) was used to compare between the means of the variables. Also, significant variances were estimated by using Duncan's test (Duncan, 1955), and the significance level is based on the probability level ( $P < 0.05$ ).

### **RESULTS AND DISSCUSSION**

The results in tables (1 , 2) showed a significant increase ( $P < 0.05$ ) in concentrations of glucose, cholesterol, triglycerides, bilirubin and activity of ALT, AST and ALP in the group exposed to ultraviolet radiation compared with the healthy control group, whereas, observed significantly decrease ( $P < 0.05$ ) in groups that treated with bacterial probiotic and the carotenoids that extracted from *Rhodotorula glutinis* in comparison with ultraviolet radiation group, except the concentrations of glucose and bilirubin in group that treated with bacterial probiotic showed no significant differences ( $P > 0.05$ ) compared with UV exposed group.

**Table 1:** Effect of carotenoids and probiotics on glucose, cholesterol, and triglycerides in the blood serum of male rats exposed to ultraviolet radiation.

Parameters	Glucose mg\ dL	Cholesterol mg\ dL	Triglycerides mg\ dL
Groups	Mean $\pm$ SE, n= 7		
G1	117.70 $\pm$ 2.25 c	94.00 $\pm$ 10.14 c	145.00 $\pm$ 7.00 c
G2	166.13 $\pm$ 12.23 a	160.00 $\pm$ 17.32 a	187.33 $\pm$ 2.30 a
G3	152.33 $\pm$ 2.30 ab	116.33 $\pm$ 0.57 bc	156.66 $\pm$ 2.88 bc
G4	113.33 $\pm$ 7.15 c	95.87 $\pm$ 3.90 c	138.56 $\pm$ 2.48 c

The different letters vertically mean there is a significant difference at  $p \leq 0.05$ .

G1= Healthy control group, G2= UV exposed group, G3= Bacterial probiotic group, G4= extracted carotenoids group.

**Table 2:** Effect of carotenoids and probiotics on ALT, AST, ALP and Bilirubin in the blood serum of male rats exposed to ultraviolet radiation.

Parameters	ALT U\L	AST U\L	ALP U\L	Bilirubin mg\ dL
Groups	Mean $\pm$ SE, n= 7			
G1	29.33 $\pm$ 0.57 b	52.00 $\pm$ 3.46 c	42.92 $\pm$ 1.49 c	0.28 $\pm$ 0.11 c
G2	58.33 $\pm$ 4.61 a	78.00 $\pm$ 2.33 a	74.06 $\pm$ 6.65 a	0.88 $\pm$ 0.06 a
G3	33.66 $\pm$ 5.13 b	64.00 $\pm$ 3.15 b	56.43 $\pm$ 3.23 b	0.73 $\pm$ 0.05 ab
G4	26.80 $\pm$ 2.77 b	47.90 $\pm$ 6.27 c	41.56 $\pm$ 5.61 c	0.19 $\pm$ 0.02 c

The different letters vertically mean there is a significant difference at  $p \leq 0.05$ .

G1= Healthy control group, G2= UV exposed group, G3= Bacterial probiotic group, G4= extracted carotenoids group.

The damage effects of ultraviolet radiation on organisms may occur directly or indirectly. Free radicals are released as a result of the radiolysis of water molecules when they are exposed to UV and these radicals lead to changes in the structures and functions of various molecules by interacting with them (Jagetia and Reddy, 2005 ; Türker, 2015), and thus may lead to damage in pancreas and liver cells as in the present study and subsequently this affects the functions and efficiency of these organs which is the reason for the high concentration of some of the studied parameters, such as glucose, cholesterol, triglycerides, ALT, AST, ALP and bilirubin.

The therapeutic effect of carotenoids on the above parameters and organs in current research may be due to the transformation of metabolites, such as free radicals formed in the organism

or carcinogenic factors coming from the external environment, such as ultraviolet rays, into substances that are less harmful and highly soluble in some liquid substances for neutralisation or removal by converting these substances to polar substances that are soluble in aqueous solutions by providing hydrogen ions, which in turn bind to free radicals or to single oxygen and convert them to less harmful or removal (FSA, 2006). It has been shown through research that carotenoids, which act as antioxidants, can prevent liver cancer or damage by reducing the levels of free radicals that can cause damage to DNA (Dawson, 2000 ; Vardi *et al.*, 2010). Also, Lycopene is a common carotenoid and one of the most effective antioxidants that can be used to prevent many diseases, lycopene also inhibits cholesterol synthesis and contributes to the breakdown of low-density lipoprotein (LDL-C) (Hsiao *et al.*, 2004).

Carotenoids are important for oxidative stress and lipid peroxidation inhibition, and participating in apoptosis (Do Nascimento *et al.*, 2020). Furthermore, carotenoids are considered as precursors to retinoids, which block the formation of lipids and reduce fat accumulation (Lobo *et al.*, 2010). Also, the causes of improved functions and health of the pancreas and liver may be due to the use of *L. acidophilus* probiotic to increase normal flora in the gut, which in returns improve digestion and increase absorption of food and supplements. Also, probiotic help activate the immune system, improve skin complexion and supports overall well-being (Vemuri *et al.*, 2022 ; Mani-López *et al.*, 2022). In addition, the effects of *Lactobacillus acidophilus* probiotic on the number and affinity of glucose transporters in the intestinal epithelial cell, that the absorption rate of the intestinal glucose depends on the SGLT-1 affinity and density in the membrane height affinity, SGLT-1 is a primary transporter for glucose absorption that has been found to increase in small intestines of pigs treated with probiotics (Al-Qayim and Abass, 2014).

The specimens were within the histological section (Fig. 1) show a section in the pancreas from the ultraviolet exposed group that illustrates the damage in tissue as a thickening wall of blood vessels with present fibrocytes. The histological present study for the carotenoids extract group in (Fig. 2), explains the effect of giving carotenoids to male rats daily for (28) days when compared with the pancreas sections of the control group clearly showed the treatment effect of extract to the effect of radiation and observed the cells of islet Langerhans and acini cells.

Furthermore, the histological picture (Fig. 3) shows a section in the liver from the group that was exposed to ultraviolet illustrating the damage in tissue as thickening wall, congestion of

blood vessels and infiltration of lymphocytes with present fibrocytes. The histological section for the group that treat with bacterial probiotic of *L. acidophilus* in (Fig. 4), explain the effect of giving probiotic to male rats daily for (28) days when compared with the liver sections of the control group clearly showed the effect of treatment on the UV effect, and observed the healing effect to probiotic on the damage and only congestion remains in the tissue, in addition to the hepatocytes and sinusoids.

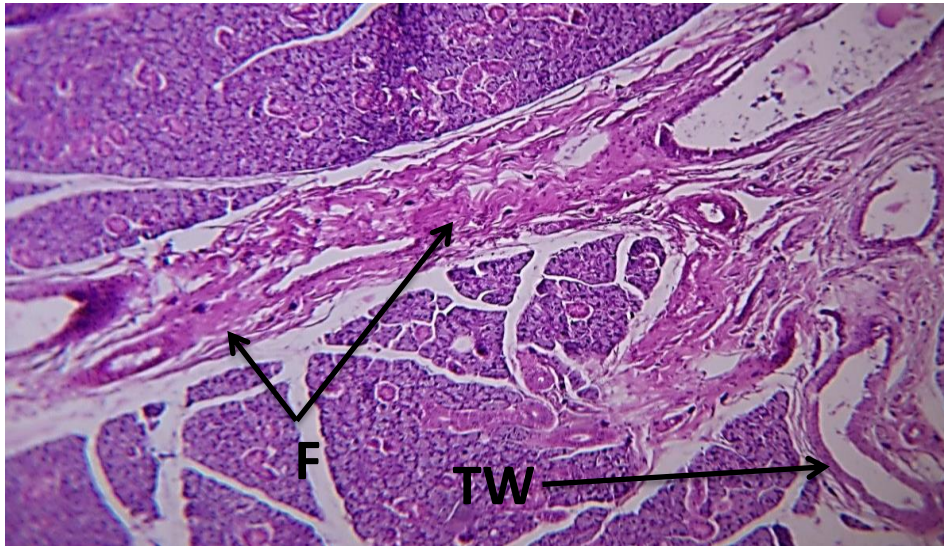


Figure (1): Pancreas of ultraviolet exposed group show thickening wall (TW) of blood vessels with present fibrocytes (F) H&E X100.

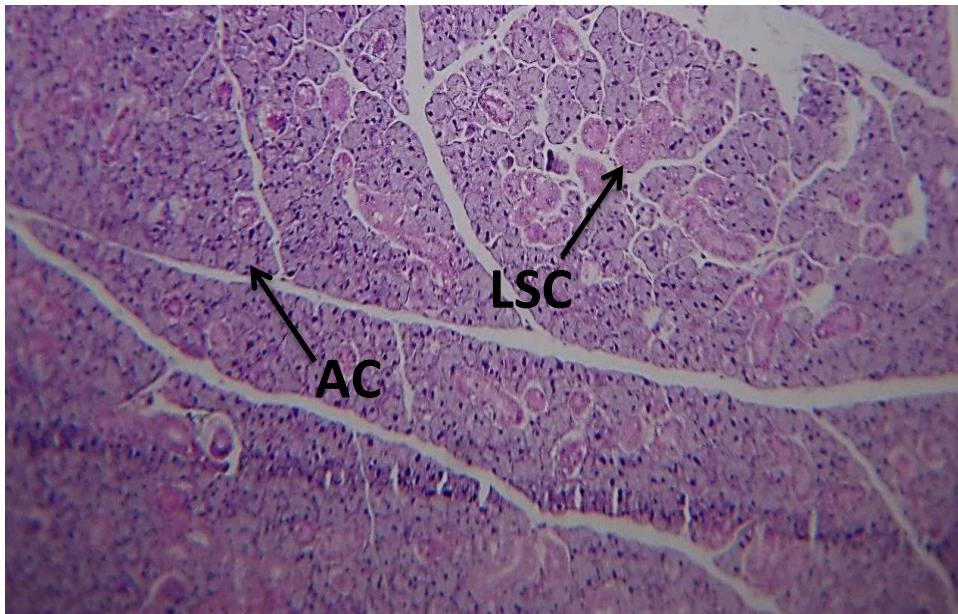


Figure (2): Pancreas of the carotenoids extract group show cells of islet Langerhans (LSC) and acini cells (AC) H&E X100.

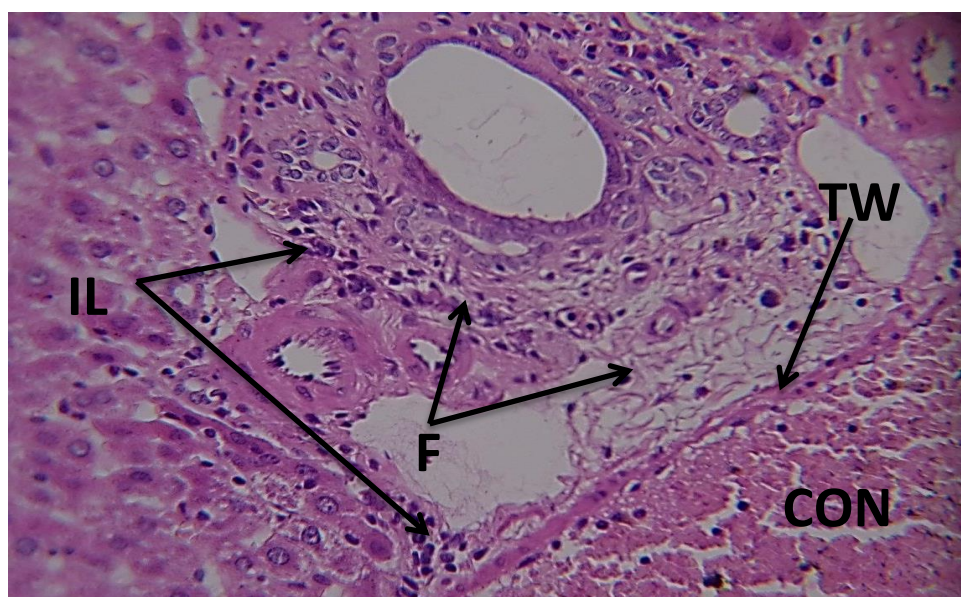


Figure (3): Liver of ultraviolet exposed group show thickening wall (TW), congestion (CON) of blood vessels and infiltration of lymphocytes (IL) with present fibrocytes (F) H&E X400.

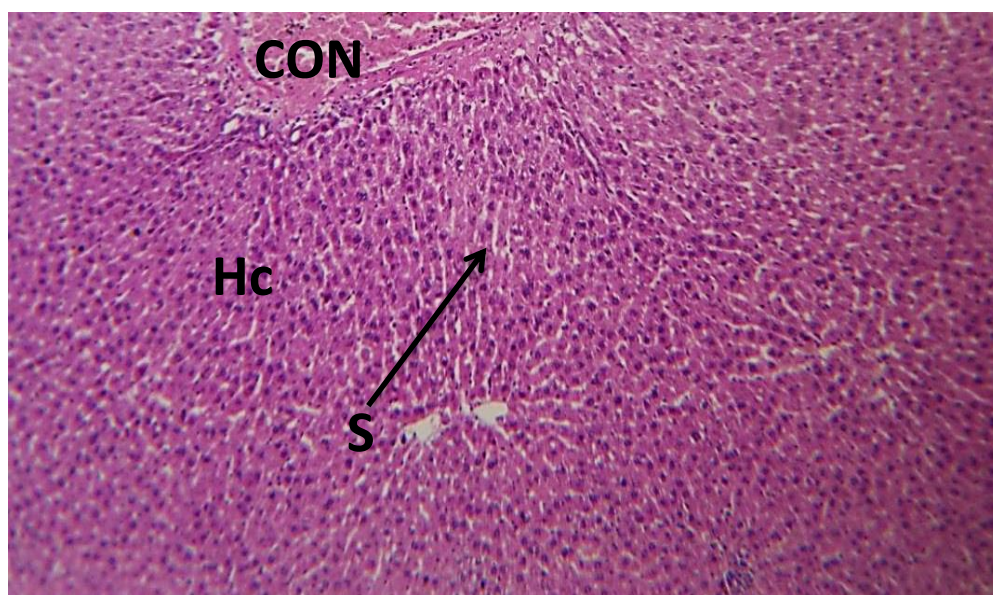


Figure (4): Liver of the group that treat with bacterial probiotic show Hepatocytes (Hc), Sinusoids (S) and congestion (CON) of blood vessels H&E X100.

The causes of this physiological and histological damage might result from an increase in the process of lipid peroxidation and a decrease in the activity of antioxidant enzymes of the body accompanied by damage of the cellular membranes (Saada and Azab, 2001 ; Singh *et al.*, 2022). While, the improvement the health and recovery of the liver cells may due to the carotenoids that important as the antioxidant level and activity, are also precursors for vitamin

A, which can help regenerate the shape of hepatic stellate cells, preventing the progression of fibrosis of the liver (Senoo *et al.*, 2010). Furthermore, Supplementation of *L. acidophilus* probiotic may due to increased erythrocyte glutathione peroxidase (GSH-Px), superoxide dismutase (SOD) activities and total antioxidant status in body (Ejtahed *et al.*, 2012), thus, this maybe lead to a decrease and treatment of the effect of oxidative stress that resulting from exposure to ultraviolet radiation.

## CONCLUSION

The current study concludes that exposure to UV rays leads to damage to the pancreas and liver, and their functions are impaired, while administration of probiotics and carotenoids leads to an improvement in the functions of the pancreas and liver and repair of the damage that could occur in tissues of these organs because the effect of ultraviolet rays.

## CONFLICT OF INTEREST

The authors declare no conflicts of interest associated with this manuscript.

## ACKNOWLEDGMENTS

The authors gratefully acknowledge the staff of the Department of Biology, College of Education and University of Samarra for their technical and general support.

## REFRANCES

- Ali, D. F. (2013). *Studies on carotenoids production from some yeasts*. (Doctoral dissertation, Mansoura University).
- Al-Qayim, M. A. & Abass, D. E. (2014). Effects of probiotics (*Lactobacillus acidophilus*) on liver functions in experimental colitis in rats. *The Iraqi Journal of Veterinary Medicine*, 38(2), 48-54.
- Ansary, T. M., Hossain, M. R., Kamiya, K., Komine, M. & Ohtsuki, M. (2021). Inflammatory molecules associated with ultraviolet radiation-mediated skin aging. *International journal of molecular sciences*, 22(8), 3974.
- Bancroft, J. D. & Layton, C. (2018). *Bancroft's theory and practice histological technique*, 8<sup>th</sup> ed, Elsevier health science, P: 153-176.
- Dawson, M. I. (2000). The importance of vitamin A in nutrition. *Current Pharmaceutical Design*, 6(3), 311-325.

- Do Nascimento, T. C., Cazarin, C. B., Maróstica, M. R., Mercadante, A. Z., JacobLopes, E. & Zepka, L. Q. (2020). Microalgae carotenoids intake: influence on cholesterol levels, lipid peroxidation and antioxidant enzymes. *Food Research International*, 128, 108770.
- Duncan, D. B. (1955). Multiple range and F-test . *Biomertic*, 11, 42.
- Ejtahed, H. S., Mohtadi-Nia, J., Homayouni-Rad, A., Niafar, M., Asghari-Jafarabadi, M. & Mofid, V. (2012). Probiotic yogurt improves antioxidant status in type 2 diabetic patients. *Nutrition*, 28(5), 539-543.
- Food Standards Agency (FSA). (2006). Eat well, be well. Annual Report, food.gov.London.
- Güerci, A. M., Dulout, F. N., & Seoane, A. I. (2004). DNA damage in Chinese hamster cells repeatedly exposed to low doses of X-rays. *Cytogenetic and Genome Research*, 104(1-4), 173-177.
- Hsiao, G., Fong, T. H., Tzu, N. H., Lin, K. H., Chou, D. S. & Sheu, J. R. (2004). A potent antioxidant, lycopene, affords neuro-protection against microglia activation and focal cerebral ischemia in rats. *In Vivo*, 18(3), 351–356.
- Jagetia, G. C. & Reddy, T. K. (2005). Modulation of radiation induced alteration in the antioxidant status of mice by naringin. *Life Sciences*, 77(7), 780-794.
- Johnson, E. A. & Schroeder, W. A. (1996). Microbial carotenoids. *Advances in biochemical engineering. Biotechnology*, 53, 119-178.
- Lobo, G. P., Amengual, J., Li, H. N., Golczak, M., Bonet, M. L. & Palczewski, K. (2010). Beta,beta-carotene decreases peroxisome proliferator receptor gamma activity and reduces lipid storage capacity of adipocytes in a beta,beta-carotene oxygenase 1-dependent manner. *Journal of Biological Chemistry*; 285(36), 27891–27899
- Mani-López, E., Arrijoa-Bretón, D. & López-Malo, A. (2022). The impacts of antimicrobial and antifungal activity of cell-free supernatants from lactic acid bacteria in vitro and foods. *Comprehensive Reviews in Food Science and Food Safety*. 21(1), 604–641.
- Naji, H. S., & Hussein, F. F. (2023). Health effect of using alkaline diet in the prevention and treatment of diabetic ketoacidosis and disruption of serum electrolytes of experiment rats. *Anbar Journal of Agricultural Sciences*, 21(1), 188-204.
- Park, P. K., Cho, D. H., Kim, E. Y. & Chu, K. H. (2005). Optimization of carotenoid production by *Rhodotorula glutinis* using statistical experimental design. *World Journal of Microbiology and Biotechnology*, 21(4), 429-434.
- Saada, H. N. & Azab, K. S. (2001). Role of lycopene in recovery of radiation induced injury to mammalian cellular organelles. *Europe PMC (Die Pharmazie)*, 56(3), 239-241.

- SAS. (2001). *SAS Users-Guide*. SAS Institute Inc. Cary NC. USA
- Senoo, H., Yoshikawa, K., Morii, M., Miura, M., Imai, K. & Mezaki, Y. (2010). Hepatic stellate cell (vitamin A-storing cell) and its relative-past, present and future. *Cell Biology International*, 34, 1247-1272.
- Singh, A., Kukreti, R., Saso, L. & Kukreti, S. (2022). Mechanistic insight into oxidative stress triggered signaling pathways and type 2 diabetes. *Molecules*, 27(3), 950.
- Suvik, A. & Effendy, A. W. (2012). The use of modified masson's trichrome staining in collagen evaluation in wound healing study. *Malaysian Journal of Veterinary Research*, 3(1), 39-47.
- Tang, X., Yang, T., Yu, D., Xiong, H. & Zhang, S. (2024). Current insights and future perspectives of ultraviolet radiation (UV) exposure: Friends and foes to the skin and beyond the skin. *Environment International*, 185, 108535.
- Türker, H. (2015). The effect of ultraviolet radiation of pancreatic exocrine cells in mole rats: An ultrastructural study. *Journal of Radiation Research and Applied Sciences*, 8(1), 49-54.
- Vachali, P., Bhosale, P. & Bernstein, P. S. (2012). Microbial carotenoids. In *Microbial Carotenoids from Fungi*, Barredo, J. L. (ed.), Humana Press, USA. P: 41-59.
- Vardi, N., Hakan, P., Asl, C., Ali, E. & Cetin, O. (2010). Protective effect of carotene on methotrexate-induced oxidative liver damage. *Journal of Toxicologic Pathology*, 38, 592-597.
- Vemuri, R., Martoni, C. J., Kavanagh, K. & Eri, R. (2022). *Lactobacillus acidophilus* DDS-1 Modulates the Gut Microbial Co-Occurrence Networks in Aging Mice. *Nutrients*, 14(5), 977.
- Wen, J., Ma, X. & Liu, Y. (2023). The latest research progress on application of *Lactobacillus acidophilus*. *Advances in Bioscience and Biotechnology*, 14(6), 298-307.